Concomitant carotid-carotid-axillary bypass with zone 0 branched endograft and transcatheter aortic valve-in-valve replacement via retroperitoneal access

Kareem Bedeir, MD, MSc,[a] Chad McRee, MD, FACC,[b] and William E. Johnson, MD,[a] Mobile, Ala

From the [a]Cardiothoracic and Vascular Surgery Associates, Infirmary Health System, Mobile, Ala; and [b]Cardiology Associates, Mobile, Ala.

Disclosures: The authors reported no conflicts of interest.

The *Journal* policy requires editors and reviewers to disclose conflicts of interest and to decline handling or reviewing manuscripts for which they may have a conflict of interest. The editors and reviewers of this article have no conflicts of interest.

Received for publication July 12, 2023; revisions received July 21, 2023; accepted for publication July 25, 2023; available ahead of print Aug 11, 2023.

Address for reprints: Kareem Bedeir, MD, MSc, 1855 Springhill Ave, Mobile, AL 36607 (E-mail: kareembedeir@gmail.com).

JTCVS Techniques 2023;21:26-31

2666-2507

Copyright © 2023 The Author(s). Published by Elsevier Inc. on behalf of The American Association for Thoracic Surgery. This is an open access article under the CC BY-NC-ND license (http://creativecommons.org/licenses/by-nc-nd/4.0/).

https://doi.org/10.1016/j.xjtc.2023.07.025

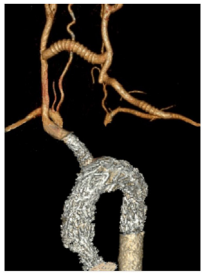

3D reconstruction: branched zone 0 TEVAR with carotid-carotid-axillary bypasses and TAVR.

CENTRAL MESSAGE

Endovascular solutions are expanding. Combining techniques and utilizing adjuncts can provide safe alternatives to very high-risk aortic procedures.

Redo aortic surgery can be complex. Complexity is increased with aortic proximity to the posterior sternal table in combination with severe aortic insufficiency. Re-entry in this situation requires deep hypothermic circulatory arrest (DHCA) before sternotomy. Ventricular fibrillation with cooling is inevitable, and severe myocardial distension from severe aortic insufficiency is known to be detrimental to myocardial protection.[1,2] Ventricular distension can be mitigated by endoaortic balloon occlusion and venting the central port, or via a counter thoracotomy incision and directly venting the apex. These approaches have their limitations related to cardioplegia with the former and recirculation with the latter. In addition, DHCA on re-entry should allow for expeditious freeing and possible limited repair of underlying structures, followed by resumption of circulation until further dissection is completed, in preparation of definitive repair, cerebral vessel control, and cardioplegia administration.

We present a case with dehiscence of a distal hemiarch anastomosis with multiple large pseudoaneurysms (PSAs) immediately under the sternum, together with severe aortic insufficiency from a degenerated bioprosthetic valve. Re-entry with DHCA would have been prolonged due to the inability to expeditiously repair the distal anastomosis nor to apply a clamp distal to it. As a result, resumption of circulation would have only been possible after definitive repair, which would entail an exceedingly long DHCA time that is associated with poor neurologic outcomes.[3,4] We present a nontraditional method to address this problem.

CASE REPORT

A 49-year-old female patient presented with a history of acute type A aortic dissection for which she underwent a supracoronary and hemiarch aortic replacement and a bioprosthetic aortic valve replacement. Her initial presentation was with paraparesis from static obstruction of her spinal arteries. Her first surgery was reportedly uneventful; however, her paraparesis persisted and required a diverting colostomy. She presented to us with chest pain. Acute coronary syndrome was ruled out, and computed tomography angiography (CTA) showed an 8-cm mass around her distal aortic anastomosis with multiple PSAs, the largest of which was an anterior 4-cm PSA from a dehisced long segment, and another 3-cm PSA from a defect along the aortopulmonary window (Figure 1). Her native arch was calcified (Figure 1, *B*). Echocardiogram showed severe insufficiency of her aortic valve bioprosthesis.

STRATEGY

We considered peripheral cannulation for cardiopulmonary bypass, cooling with apical venting through a minithoracotomy, and re-entry with DHCA. However, we had

FIGURE 1. A-C, Preoperative CTA and reconstruction showing multiple pseudoaneurysms arising from the dehisced distal hemiarch anastomosis and calcified true lumen of the native arch. *CTA*, Computed tomography angiography.

concerns regarding the duration of DHCA necessary before we could resume circulation (after cardiac dissection, head vessel control, myocardial protection, and definitive aortic repair). Moreover, the densely and circumferentially calcified arch may have caused significant difficulty with a surgically constructed anastomosis. Consequently, we pursued alternative strategies.

We considered thoracic endovascular aortic repair (TEVAR) of the dehisced anastomosis and a valve-in-valve (ViV) transcatheter aortic replacement (TAVR). Challenges encountered included that coverage of the dehisced anastomosis necessitated coverage of her bovine trunk. Her available inflow for extra-anatomic revascularization of the head would have been her femoral vessels, which are known to have very poor patency rates. Moreover, CTA of her iliofemoral vessels showed her external iliac arteries to be 48 mm in maximum diameter, prohibiting femoral access for TEVAR.

As a result, we decided to use a thoracic branched endoprosthesis (TBE) with zone 0 coverage, with the side branch into the innominate artery, preceded by carotid-to-carotid bypass and carotid-to-left axillary bypass, and followed by ViV-TAVR. For access, we decided to use a retroperitoneal common iliac artery conduit.

TECHNIQUE

With the patient under general anesthesia and cerebral monitoring, bilateral carotid cutdowns were done along the anterior borders of the sternocleidomastoids. Carotid arteries were controlled and nerves protected. The left axillary artery was exposed in the deltopectoral groove and the brachial plexus protected. A tunnel was created in the retropharyngeal space using blunt dissection just anterior to the cervical vertebral bodies, and an 8-mm ringed polytetrafluoroethylene graft was routed. Another retroclavicular tunnel was created using blunt dissection and a 6-mm ringed polytetrafluoroethylene graft was routed (Figure E1, *A*). Heparin was given after tunneling. Carotids were sequentially clamped, and end-to-side anastomoses were constructed medial to the jugular veins. The left carotid anastomosis for the axillary bypass was more proximal and was constructed lateral to the jugular (jugular retracted medially). Axillary anastomosis was then constructed.

A temporary right ventricular pacer was placed through the right femoral vein for rapid pacing during TEVAR and TAVR deployments. Retroperitoneal exposure was achieved through an incision in the right iliac fossa with medial visceral rotation, identification of the aortic bifurcation, ureteral protection, and control of the common iliac. A 10-mm Dacron graft was sewn end to side and externalized through the abdominal wall muscles and through the skin of the right groin (Figure E1, *B*). The graft was then deaired and clamped. The graft was accessed proximal to the clamp and serially dilated in the standard fashion, and a 24-Fr sheath was inserted over a stiff wire (Figure E1, *C*).

Right upper limb arteries were too small for access so instead, we accessed the exposed right carotid, and a stiff glide wire was advanced into the descending aorta, snared, and externalized through the 24-Fr sheath. A TBE (W. L. Gore & Associates, Inc) was loaded on both wires and advanced avoiding wire wrap. Stent graft was deployed in zone 0. We then cannulated the portal with a 15 × 60-mm side branch stent graft over the glidewire and deployed

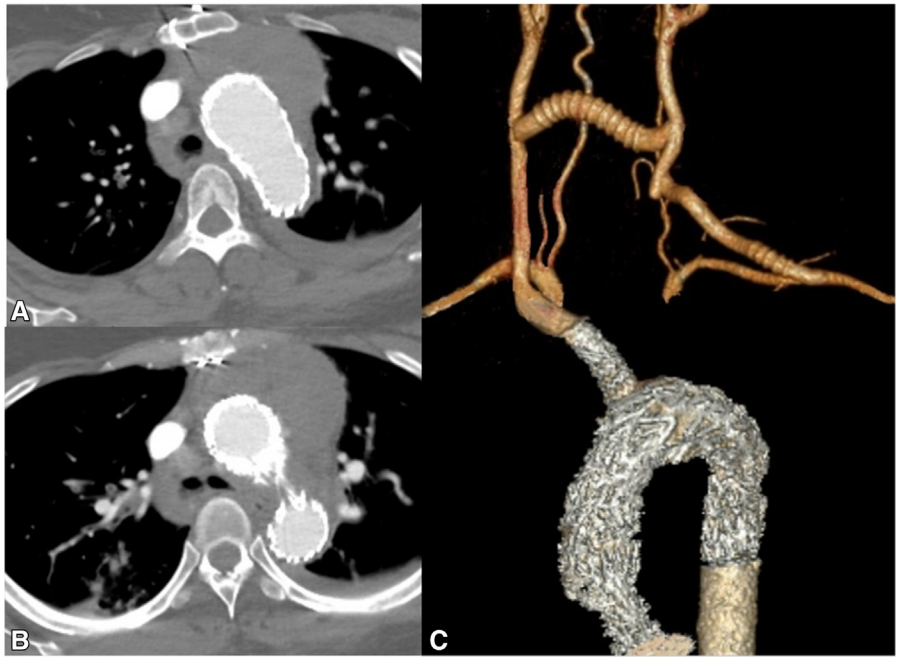

FIGURE 2. A-C, Postoperative CTA and reconstruction of the postoperative CT scan showing excluded pseudoaneurysms, no endoleaks and patent bypass grafts. *CTA*, Computed tomography angiography; *CT*, computed tomography.

it in the innominate artery. Then, this was ballooned with a compliant balloon. A proximal aortic extender was used to get more coverage proximal to the dehisced anastomosis. Angiograms showed no endoleaks and patent bypasses (Figure E2, *A*, *B* and *D*).

Through the same sheath, the bioprosthetic valve was crossed, and a 26-mm Evolut FX (Medtronic) valve was gently passed through the TEVAR endograft and deployed inside the degenerated bioprosthesis (Figure E2, *C*). The patient did not have heart block. Aortogram showed good coronary filling, and echocardiogram showed no paravalvular leak. The left carotid was ligated proximally. The iliac conduit was amputated with a short stump, and soft tissue layers were closed.

The patient's recovery was uneventful and without neurologic complications. The patient was discharged on postoperative day 8, and predischarge CTA showed and excellent result (Figure 2).

COMMENT

The endovascular toolkit is expanding, and familiarity with its applications allows for modifying and combining approaches to provide safer strategies for highly complex situations. Transapical TAVR and TEVAR have been previously reported.[5,6] The combination of zone 0 landing with a branched-TEVAR together with TAVR has, to our knowledge, not been previously reported. In this case, transapical approach was not considered because the ascending aorta was shorter than the shortest available TBE, prohibiting antegrade deployment. Retrograde advancement of the TAVR delivery system before the TEVAR would have been unsafe with the dehisced aorta. Advancement with the TEVAR in place involves cautious maneuvering to avoid migration of the newly deployed stent graft. The side-branch probably provides increased stability to the endograft during the TAVR delivery.

Endoconduits have been described, which entail controlled expansion and possibly rupture of the iliac vessels inside an oversized covered stent graft.[7] In this case, we found the femoral arteries to be prohibitively small, requiring a near-doubling in size, so we elected to proceed with a retroperitoneal approach with direct common iliac artery access.

We believe our strategy is safer for the patient compared with a standard operation; however, the main limitation is that the patient received another bioprosthetic valve, which will eventually degenerate. Her long-term plans will include either a surgical mechanical valve or a ViV-TAVR, depending on the age at which this happens. If re-entry was necessary, it will not be problematic with the PSA excluded.

References

1. Lucas SK, Gardner TJ, Elmer EB, Flaherty JT, Bulkley BH, Gott VL. Comparison of the effects of left ventricular distention during cardioplegic-induced ischemic arrest and ventricular fibrillation. *Circulation*. 1980;62:I42-9.
2. Lucas SK, Schaff HV, Flaherty JT, Gott VL, Gardner TJ. The harmful effects of ventricular distention during postischemic reperfusion. *Ann Thorac Surg*. 1981;32:486-94.
3. Svensson LG, Crawford ES, Hess KR, Coselli JS, Raskin S, Shenaq SA, et al. Deep hypothermia with circulatory arrest. Determinants of stroke and early mortality in 656 patients. *J Thorac Cardiovasc Surg*. 1993;106:19-28; discussion 31.

4. Kruger T, Weigang E, Hoffmann I, Blettner M, Aebert H, Investigators G. Cerebral protection during surgery for acute aortic dissection type A: results of the German Registry for Acute Aortic Dissection Type A (GERAADA). *Circulation*. 2011;124:434-43.
5. Allen KB, Johnson LM, Borkon AM, Aggarwal S, Davis JR, Cohen DJ, et al. Combined transcatheter aortic valve replacement and thoracic endovascular aortic repair using transapical access. *Ann Thorac Surg*. 2015;100:723-7.
6. Komlo CM, Vallabhajosyula P, Bavaria JE, Desai ND, Anwaruddin S, Giri JS, et al. Combined transaortic transcatheter valve replacement and thoracic endografting. *Ann Thorac Surg*. 2014;97:696-8.
7. Peterson BG, Matsumura JS. Internal endoconduit: an innovative technique to address unfavorable iliac artery anatomy encountered during thoracic endovascular aortic repair. *J Vasc Surg*. 2008;47:441-5.

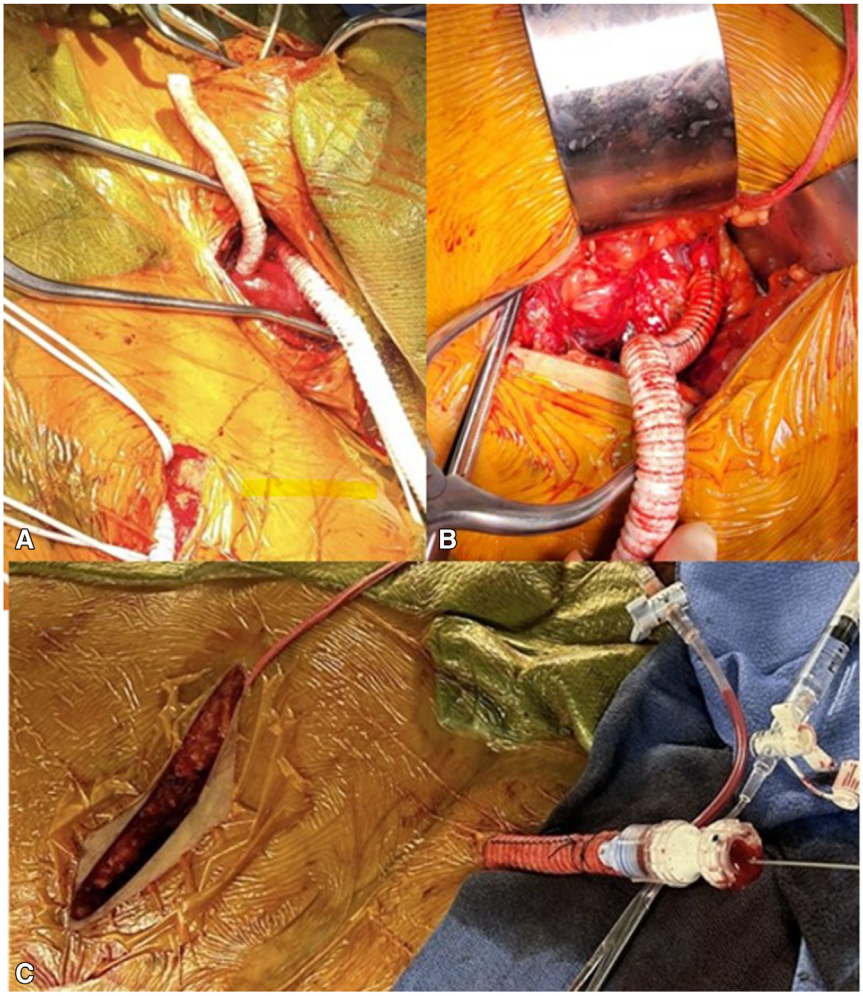

FIGURE E1. A, Ring-reinforced PTFE grafts routed in the retropharyngeal and retroclavicular routes before heparinization. B and C, retroperitoneal conduit construction to the right common iliac artery and externalization into the right groin for large bore sheath access. *PTFE*, Polytetrafluoroethylene.

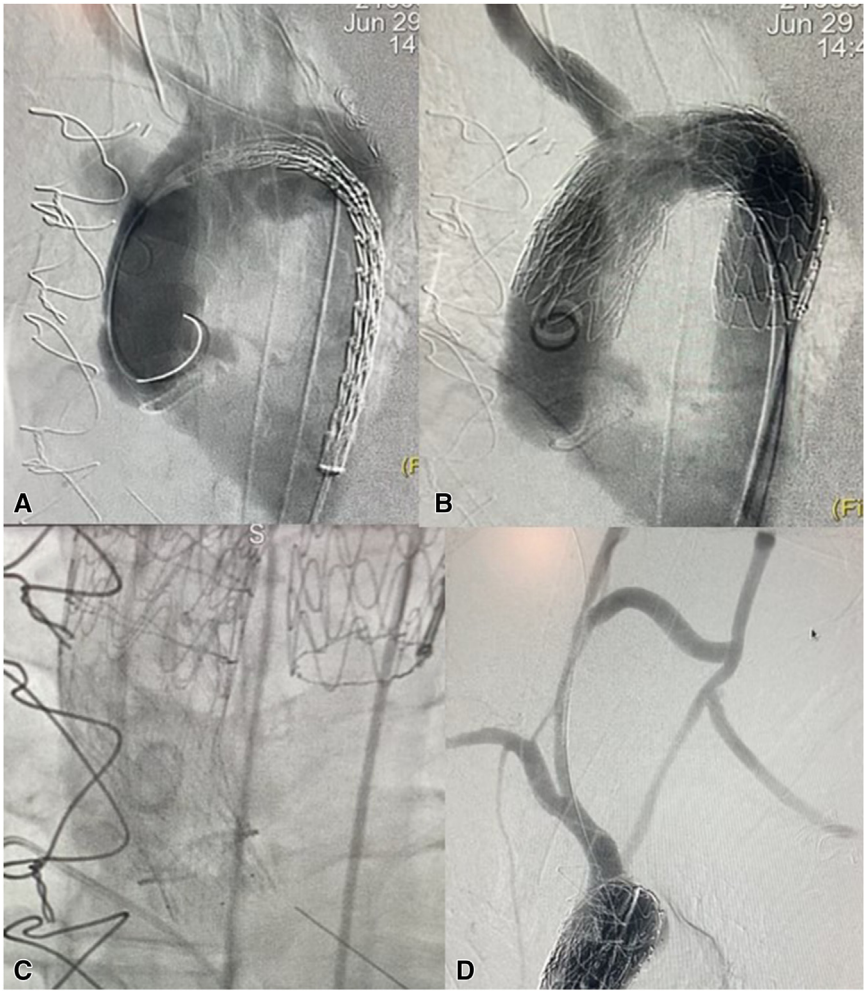

FIGURE E2. A, Aortogram shows circumferential pseudoaneurysms around the distal ascending aorta and evidence of severe AI. B, Shows the deployed TBE and side branch with exclusion of the pseudoaneurysms and occlusion of the native left carotid and left subclavian orifices. C, Evolut FX TAVR valve deployed in a ViV fashion. D, Carotid-to-carotid bypasses and left carotid to axillary bypasses (before proximal ligation). *AI*, Aortic insufficiency; *TBE*, thoracic branched endoprosthesis; *TAVR*, transcatheter aortic valve replacement; *ViV*, valve-in-valve.