



## Case Report

# Visualization of ictal networks using gamma oscillation regularity correlation analysis in focal motor epilepsy: Illustrative cases

Tomonobu Nakamura, Yosuke Sato, Yusuke Kobayashi, Yuta Kawauchi, Katsuyoshi Shimizu, Tohru Mizutani

Department of Neurosurgery, Showa University School of Medicine, Shinagawa-ku, Japan.

E-mail: Tomonobu Nakamura - tomonobu050505@gmail.com; \*Yosuke Sato - yanda2011@gmail.com; Yusuke Kobayashi - hiriyuu\_korosuke@yahoo.co.jp; Yuta Kawauchi - bitethebulletcannon@gmail.com; Katsuyoshi Shimizu - katsuyoshis@aol.com; Tohru Mizutani - mizutani.nsutky@gmail.com



### \*Corresponding author:

Yosuke Sato,  
Department of Neurosurgery,  
Showa University School of  
Medicine, Shinagawa-ku, Japan.  
yanda2011@gmail.com

Received : 21 February 2022

Accepted : 16 March 2022

Published : 25 March 2022

DOI

10.25259/SNI\_193\_2022

Quick Response Code:



## ABSTRACT

**Background:** Focal motor epilepsy is difficult to localize within the epileptogenic zone because ictal activity quickly spreads to the motor cortex through ictal networks. We previously reported the usefulness of gamma oscillation (30–70 Hz) regularity (GOR) correlation analysis using interictal electrocorticographic (ECoG) data to depict epileptogenic networks. We conducted GOR correlation analysis using ictal ECoG data to visualize the ictal networks originating from the epileptogenic zone in two cases — a 26-year-old woman with negative motor seizures and a 53-year-old man with supplementary motor area (SMA) seizures.

**Case Description:** In both cases, we captured several habitual seizures during monitoring after subdural electrode implantation and performed GOR correlation analysis using ictal ECoG data. A significantly high GOR suggestive of epileptogenicity was identified in the SMA ipsilateral to the lesions, which were connected to the motor cortex through supposed ictal networks. We resected the high GOR locations in the SMA and the patients' previously identified tumors were removed. The patients were seizure-free without any neurological deficits after surgery.

**Conclusion:** The GOR correlation analysis using ictal ECoG data could be a powerful tool for visualizing ictal networks in focal motor epilepsy.

**Keywords:** Epilepsy surgery, Gamma oscillation regularity, Ictal motor networks, Negative motor seizure, Supplementary motor area seizure

## INTRODUCTION

Focal motor epilepsy typically involves swift and complex motor behaviors,<sup>[14,18]</sup> and negative motor seizures (NMS) and supplementary motor area (SMA) seizures present with various symptoms.<sup>[10]</sup> These seizures often have an epileptogenic focus in the mesial or near-mesial frontal lobe.<sup>[2]</sup> In studies using electrocorticographic (ECoG) data, Ikeda *et al.*<sup>[8]</sup> and Ohara *et al.*<sup>[13]</sup> suggested that NMS and SMA seizures differ from other focal motor seizures involving the primary motor cortex and that these ictal discharges spread rapidly from the epileptogenic focus to the symptomatic zone, that is, the primary motor cortex. These features make it difficult to accurately diagnose epileptogenic foci in NMS and SMA seizures based on conventional electroencephalography (EEG) findings.<sup>[11]</sup>

This is an open-access article distributed under the terms of the Creative Commons Attribution-Non Commercial-Share Alike 4.0 License, which allows others to remix, transform, and build upon the work non-commercially, as long as the author is credited and the new creations are licensed under the identical terms.

©2022 Published by Scientific Scholar on behalf of Surgical Neurology International

In view of the context of epilepsy as a network disorder,<sup>[7]</sup> it has been challenging to depict epileptogenic networks using EEG methods such as stereo EEG (SEEG)<sup>[11]</sup> and magnetoencephalography.<sup>[5]</sup> In particular, in focal motor seizures, where seizure activity propagates quickly from the epileptogenic focus to the adjacent motor cortex,<sup>[3]</sup> visualization of the epileptogenic network enables accurate assessment of the epileptogenic focus and improves surgical treatment outcomes.<sup>[7]</sup> Recent studies have shown that gamma oscillation (30–70 Hz) regularity (GOR) in ECoG data is significantly associated with epileptogenicity in the epileptogenic focus.<sup>[15,16]</sup> Furthermore, researchers have reported successful intraoperative visualization of epileptogenic networks connecting the lateral temporal lobe to the ipsilateral hippocampus using GOR correlation analysis of ECoG data in a patient with dual foci in temporal lobe epilepsy.<sup>[9]</sup> In this context, we hypothesized that applying GOR correlation analysis to ictal ECoG data in focal motor epilepsy would make it possible to depict the ictal networks between the epileptogenic focus and the associated motor cortex.

## CLINICAL PRESENTATION

### Case 1

The patient was a 26-year-old woman who experienced an indescribable aura and subsequent atonic seizures in the right hemibody without loss of consciousness for more than 5 years, which was considered to be NMS. Contrast-enhanced magnetic resonance imaging (MRI) showed a 27 × 21 mm tumor within the left frontal lobe in contact with the SMA. The tumor comprised solid and cystic components and no calcification was observed [Figure 1a]. Iomazenil single-photon emission computed tomography (IMZ-SPECT) showed decreased accumulation in the left prefrontal cortex [Figure 1b]. Interictal scalp EEG revealed no significant epileptic discharge. To evaluate the epileptogenic focus accurately, we performed video/intracranial ECoG monitoring with subdural grid electrodes placed on the left frontal lobe [Figure 1c]. Interictal ECoG showed spikes at electrodes 12 and 13 [Figure 1d]. GOR analysis with interictal ECoG data revealed a significantly high GOR at electrodes 7, 8, 12, and 13 [Figure 1e]. Habitual seizures started with spike activity at electrode 12, followed by seizure activity spreading into electrodes 7, 8, and 13 [Figure 1f]. GOR correlation analysis with ictal ECoG data revealed ictal networks between the epileptogenic focus and the ipsilateral motor cortex [Figure 1g]. These results led us to the diagnosis of intractable NMS with an epileptogenic focus originating from the SMA.

The patient underwent cortical resection of the epileptogenic focus (electrodes 7, 8, 12, and 13) within the SMA and

subsequent tumor removal [Figure 1h]. The patient was seizure-free and had no complications. Postoperative pathological examination confirmed the diagnosis of ganglioglioma.

### Case 2

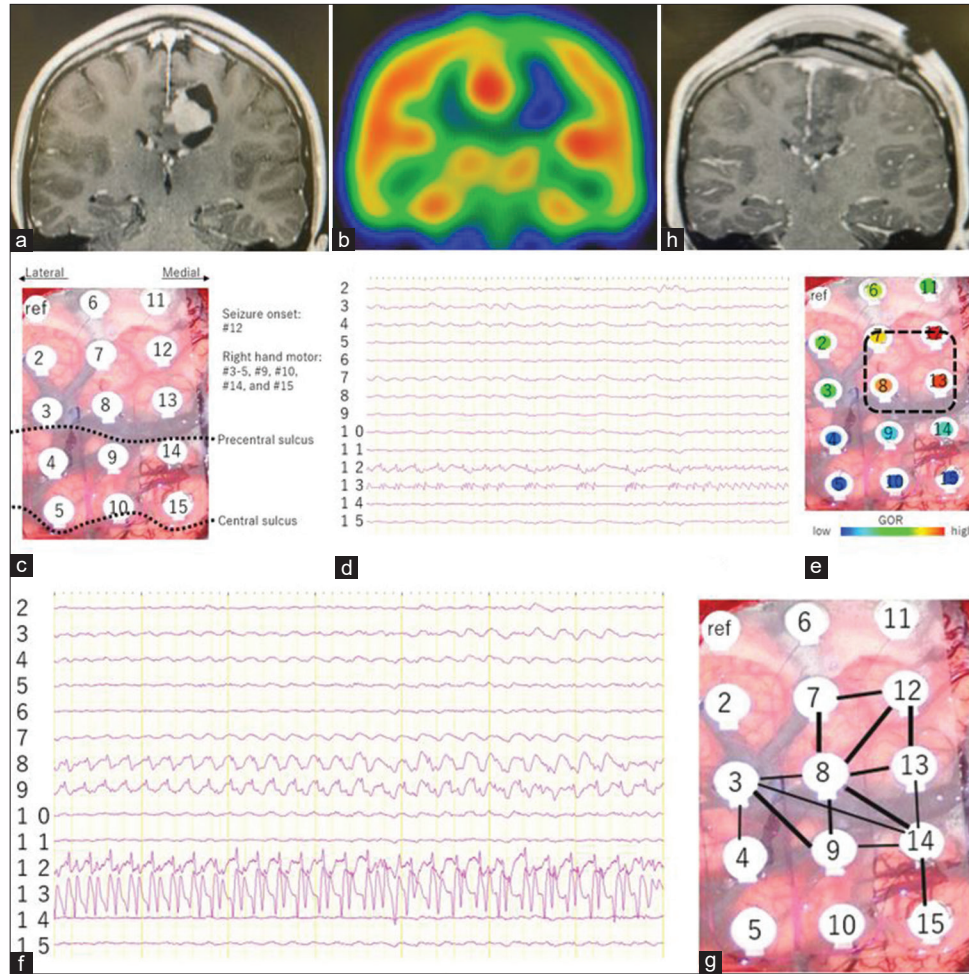
The patient was a 53-year-old man who experienced short tonic posturing of the left hand for over 2 years. Contrast-enhanced MRI showed a 9.2 × 9.4 mm tumor at the right mesial frontal lobe, and high intensity was seen in fluid-attenuated inversion recovery (FLAIR) images [Figure 2a]. IMZ-SPECT showed slightly decreased accumulation in the right mesial frontal cortex [Figure 2b]. Interictal scalp EEG revealed no significant epileptic discharge. We performed video/intracranial ECoG monitoring with subdural grid electrodes placed on the right mesial and lateral frontal lobes [Figure 2c]. Interictal ECoG showed fast activity and spikes at electrodes 21 and 22 on the right mesial frontal cortex [Figure 2d]. GOR analysis with interictal ECoG data revealed a significantly high GOR at electrodes 21 and 22 [Figure 2e]. Habitual seizures started with spike activity at electrodes 21 and 22, followed by seizure activity spreading into electrodes 12, 13, 14, 17, 18, and 19 [Figure 2f]. GOR correlation analysis with ictal ECoG data revealed ictal networks between the epileptogenic focus and the ipsilateral premotor and motor cortex [Figure 2g]. These results led us to diagnose intractable SMA seizures. The patient underwent cortical resection of the epileptogenic focus (electrodes 21 and 22) within the SMA with high intensity in FLAIR [Figure 2h]. The patient subsequently became seizure-free and had no complications. Postoperative pathological examination confirmed the diagnosis of anaplastic astrocytoma.

### ECoG data recordings

ECoG data were recorded using a Nihon Kohden Neurofax EEG system (Nihon Kohden, Tokyo, Japan) with a bandpass filter from 0.16 to 300 Hz with a sampling rate of 1 kHz. A 60-Hz notch filter was applied to all channels and the sensitivity was between 30 and 100  $\mu\text{V}/\text{mm}$  according to the amplitudes of the background activities and epileptic discharges. Recordings were obtained using a reference electrode placed on the forehead. All selected ECoG epochs were inspected to ensure that they were not contaminated by artifacts.

### GOR analysis

The detailed algorithm employed for GOR analysis using the sample entropy method has been described in the previous studies.<sup>[9,17]</sup> In each step of the GOR correlation analysis, we selected 20 s of ECoG data without any significant artifacts. ECoG data were down-sampled to 200 Hz, where the timescale factor ( $\tau$ ) = 3–7 corresponded to the gamma



**Figure 1:** Illustrative results of Case 1. (a) Preoperative contrast-enhanced magnetic resonance imaging shows a tumor in the left mesial frontal lobe. (b) Iomazenil single-photon emission computed tomography shows decreased accumulation in the left prefrontal cortex. (c) Intracranial electrocorticographic (ECoG) monitoring shows seizure onset zone (SOZ) at electrode 12, and right-hand motor areas at electrodes 3, 4, 5, 9, 10, 14, and 15. (d) Interictal ECoG shows spikes at electrodes 12 and 13. (e) Gamma oscillation (30–70 Hz) regularity (GOR) analysis with interictal ECoG data reveals significantly high GOR at electrodes 7, 8, 12, and 13. (f) Ictal ECoG shows spikes at electrode 12, which spread into electrodes 7, 8, and 13. (g) GOR correlation analysis with ictal ECoG data reveals ictal networks between the epileptogenic focus (electrodes 7, 8, 12, and 13) and ipsilateral motor cortex (electrodes 3, 9, and 14). (h) The epileptogenic focus (electrodes 7, 8, 12, and 13) within the supplementary motor area was resected, and the tumor was subsequently removed.

frequency (28.6–66.7 Hz). We defined the GOR as an average score with  $(\tau) = 3-7$ . The time-series GOR was then obtained by sweeping the 5-s analysis interval by 0.1 s over the entire 10 s (i.e., 51 time-series GOR). The correlation coefficient  $r_{ij}$  for the time series GOR at electrodes  $i$  and  $j$  was defined as:

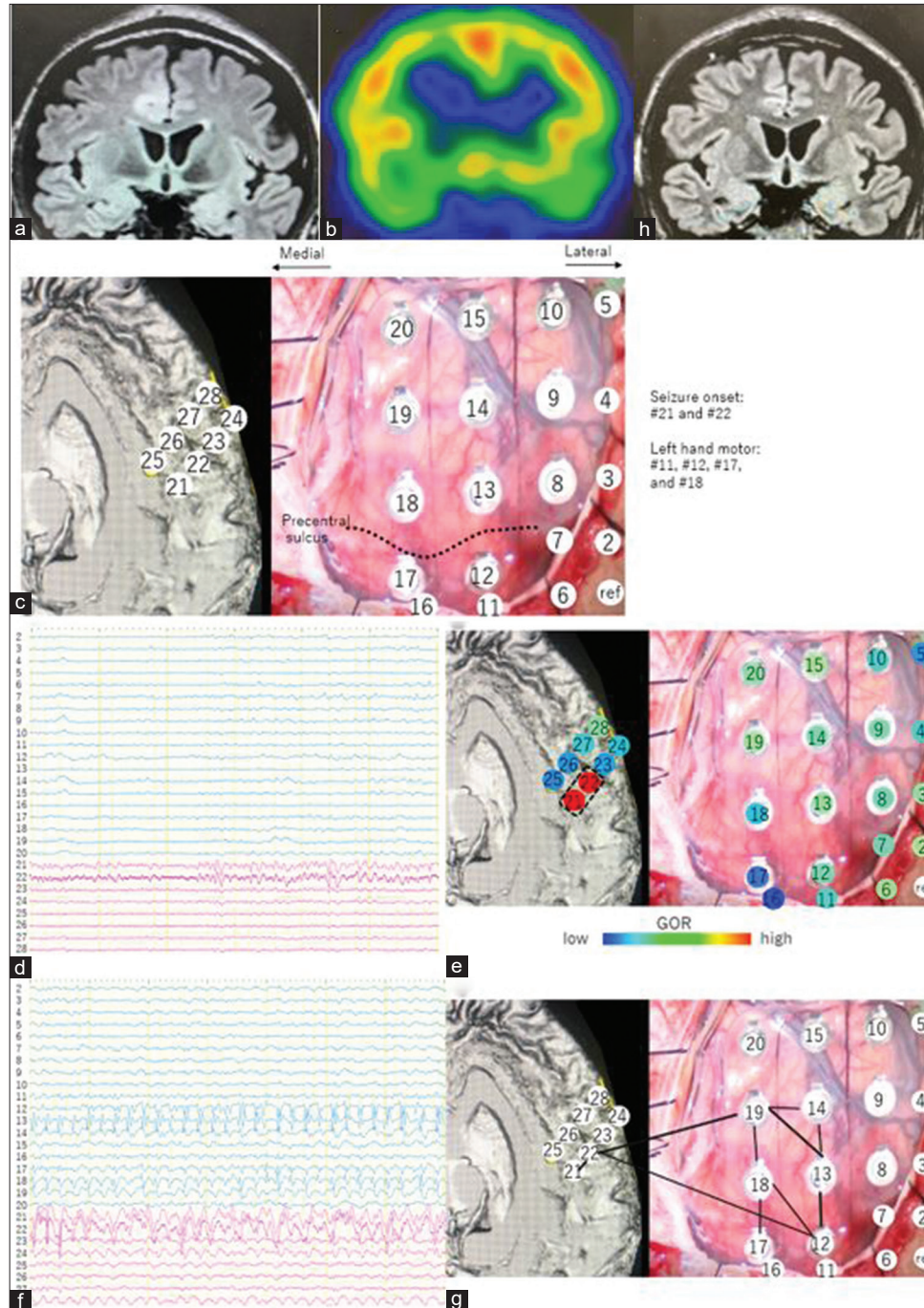
$$r_{ij} = \frac{S_{ij}}{S_i S_j}$$

$S_{ij}$  is the covariance of electrodes  $i$  and  $j$ , and  $S_i$  is the standard deviation of electrode  $i$ . In the network diagram, the threshold was set to 0.7 in this case. The edge was placed between nodes  $i$  and  $j$  when  $r_{ij} = 0.7$ . We weighted the threshold between 0.7 and 1 linearly with the thickness of the

edge. To visually assess the GOR, we color-coded the average GOR over 10 s. These procedures were performed using a custom program developed in cooperation with EFken Inc. (Tokyo, Japan).

## DISCUSSION

Focal motor epilepsy is difficult to diagnose because of its very rapid propagation, and abnormalities in scalp EEG often remain undetected.<sup>[14,18]</sup> Among focal motor epilepsies, SMA seizures and NMS are known to express various worrisome symptoms. The SMA is divided into two areas — the rostral part (pre-SMA) and the dorsal part (SMA-proper). The pre-SMA is connected to the prefrontal cortex. The SMA-proper



**Figure 2:** Illustrative results of Case 2. (a) Preoperative contrast-enhanced magnetic resonance imaging shows a tumor at the right mesial frontal lobe. (b) Iomazenil single-photon emission computed tomography shows slightly decreased accumulation in the right mesial frontal cortex. (c) Intracranial electrocorticographic (ECoG) monitoring shows SOZ at electrodes 21 and 22 on the right mesial frontal cortex and left-hand motor areas at electrodes 11, 12, 17, and 18 on the lateral frontal cortex. (d) Interictal ECoG shows spikes at electrodes 21 and 22. (e) Gamma oscillation (30–70 Hz) regularity (GOR) analysis with interictal ECoG data reveals significantly high GOR at electrodes 21 and 22. (f) Ictal ECoG shows spikes at electrodes 21 and 22, which spread into electrodes 12, 13, 14, 17, 18, and 19. (g) GOR correlation analysis with ictal ECoG data reveals ictal networks between the epileptogenic focus (electrode 22) and ipsilateral premotor cortex (electrode 19) and motor cortex (electrode 12). (h) The epileptogenic focus (electrodes 21 and 22) within the supplementary motor area was removed.

projects to the primary motor cortex, dorsal premotor cortex and spinal cord. Furthermore, the SMA is suggested to be

involved in other functions such as spatial and language processing<sup>[6]</sup> and is related to negative motor responses (e.g.,

atonic seizures and speech arrest) in addition to positive motor responses (e.g., convulsions).<sup>[13]</sup> The NMA is also separated into two subareas: the primary NMA and the supplementary NMA. These two subareas correspond to area 44 in Brodmann's map and pre-SMA, respectively.<sup>[8]</sup> These anatomical and functional complexities make the diagnosis of SMA seizures and NMS very difficult.

We previously reported the usefulness of GOR analysis in locating the epileptogenic focus<sup>[9,15-17]</sup> and showed that GOR correlation analysis is an effective method to depict the interictal epileptogenic network intraoperatively.<sup>[9]</sup> In the present study, we applied GOR correlation analysis to ictal ECoG data in two patients with NMS and SMA seizures and revealed the ictal networks between the SMA region corresponding to the epileptogenic focus and the motor areas, which has been difficult to assess using conventional methods. The ability to depict ictal networks in focal motor epilepsy, which is structurally and functionally complex, allows for reasonable and minimally invasive epilepsy surgery. Furthermore, our GOR correlation analysis may be applicable not only to epilepsy but also to the study of motor-related networks.

The brain's U-fibers, which connect the neighboring cortical regions,<sup>[12]</sup> play a major role in frontal cortex formation.<sup>[4]</sup> The fact that these U-fibers are tightly connected to the various motor-associated areas may be related to the very fast propagation of seizure activities in focal motor epilepsy. We assume that the ictal networks visualized with our GOR correlation analysis indicate the connection between the SMA/NMA and motor-associated areas through the U-fibers, although further studies are needed to confirm this.

A limitation of this study is that the networks are presented as an undirected graph; hence, the direction of the seizure propagation cannot be strictly evaluated. As we were able to show that there is a connection between the epileptogenic focus and the motor areas as symptomatic zones and that the removal of such epileptogenic foci resulted in liberation from seizures, we can only indirectly understand that seizure activities start from the epileptogenic focus and subsequently propagate to the motor areas. To solve this problem, we are currently developing a GOR correlation analysis to depict visualized networks as a directed graph. In addition, ECoG data can only be used for planar network analysis. Our goal is to use SEEG data with our GOR correlation analysis to enable three-dimensional network depiction for more minimally invasive epilepsy surgery.

## CONCLUSION

GOR correlation analysis using ictal ECoG data as described here could be a very useful method for visualizing ictal networks in focal motor epilepsy.

## Data availability statement

The raw data supporting this article will be made available by the authors, without undue reservation.

## Declaration of patient consent

Institutional Review Board (IRB) permission obtained for the study.

## Financial support and sponsorship

JSPS KAKENHI Grant Number JP 20K09356.

## Conflicts of interest

There are no conflicts of interest.

## REFERENCES

1. Bartolomei F, Lagarde S, Wendling F, McGonigal A, Jirsa V, Guye M, *et al.* Defining epileptogenic networks: Contribution of SEEG and signal analysis. *Epilepsia* 2017;58:1131-47.
2. Beleza P, Pinho J. Frontal lobe epilepsy. *J Clin Neurosci* 2011;18:593-600.
3. Bonini F, McGonigal A, Trébuchon A, Gavaret M, Bartolomei F, Giusiano B, *et al.* Frontal lobe seizures: From clinical semiology to localization. *Epilepsia* 2014;55:264-77.
4. Catani M, Dell'acqua F, Vergani F, Malik F, Hodge H, Roy P, *et al.* Short frontal lobe connections of the human brain. *Cortex* 2012;48:273-91.
5. Chavez M, Valencia M, Navarro V, Latora V, Martinerie J. Functional modularity of background activities in normal and epileptic brain networks. *Phys Rev Lett* 2010;104:118701.
6. Cona G, Semenza C. Supplementary motor area as key structure for domain-general sequence processing: A unified account. *Neurosci Biobehav Rev* 2017;72:28-42.
7. de Palma L, De Benedictis A, Specchio N, Marras CE. Epileptogenic network formation. *Neurosurg Clin North Am* 2020;31:335-44.
8. Ikeda A, Hirasawa KI, Kinoshita M, Hitomi T, Matsumoto R, Mitsueda T, *et al.* Negative motor seizure arising from the negative motor area: Is it ictal apraxia? *Epilepsia* 2009;50:2072-84.
9. Kobayashi Y, Sato Y, Sugiyama T, Mizutani T. Intraoperative epileptogenic network visualization using gamma oscillation regularity correlation analysis in epilepsy surgery. *Surg Neurol Int* 2021;12:254.
10. Lee JJ, Lee SK, Lee SY, Park KI, Kim DW, Lee DS, *et al.* Frontal lobe epilepsy: Clinical characteristics, surgical outcomes and diagnostic modalities. *Seizure* 2008;17:514-23.
11. Luders HO. Non-invasive electroencephalography evaluation of the irritative zone. In: *Textbook of Epilepsy Surgery*. London: Informa Healthcare, Taylor and Francis Distributor; 2008. p. 530-6.
12. O'Halloran R, Feldman R, Marcuse L, Fields M, Delman B, Frangou S, *et al.* A method for U-fiber quantification from 7T diffusion-weighted MRI data tested in subjects with

- non-lesional focal epilepsy. *Neuroreport* 2017;28:457-61.
13. Ohara S, Ikeda A, Kunieda T, Yazawa S, Taki J, Nagamine T, *et al.* Propagation of tonic posturing in supplementary motor area (SMA) seizures. *Epilepsy Res* 2004;62:179-87.
  14. Parker CS, Clayden JD, Cardoso MJ, Rodionov R, Duncan JS, Scott C, *et al.* Structural and effective connectivity in focal epilepsy. *Neuroimage Clin* 2018;17:943-52.
  15. Sato Y, Ochi A, Mizutani T, Otsubo H. Low entropy of interictal gamma oscillations is a biomarker of the seizure onset zone in focal cortical dysplasia type II. *Epilepsy Behav* 2019;96:155-9.
  16. Sato Y, Tsuji Y, Kawauchi Y, Iizuka K, Kobayashi Y, Irie R, *et al.* Epileptogenic zone localization using intraoperative gamma oscillation regularity analysis in epilepsy surgery for cavernomas: Patient series. *J Neurosurg Case Lessons* 2021;1:20121.
  17. Sato Y, Wong SM, Iimura Y, Ochi A, Doesburg SM, Otsubo H. Spatiotemporal changes in regularity of gamma oscillations contribute to focal ictogenesis. *Sci Rep* 2017;7:9362.
  18. Uehara T, Shigeto H, Mukaino T, Yokoyama J, Okadome T, Yamasaki R, *et al.* Rapidly spreading seizures arise from large-scale functional brain networks in focal epilepsy. *NeuroImage* 2021; 237:118104.

**How to cite this article:** Nakamura T, Sato Y, Kobayashi Y, Kawauchi Y, Shimizu K, Mizutani T. Visualization of ictal networks using gamma oscillation regularity correlation analysis in focal motor epilepsy: Illustrative cases. *Surg Neurol Int* 2022;13:105.