



Contents lists available at ScienceDirect

International Journal of Surgery Case Reports

journal homepage: www.casereports.com

Giant fibrokeratoma, a rare soft tissue tumor presenting like an accessory digit, a case report and review of literature

Mohammed Ali^{a,*}, C.A. Mbah^a, Ahmed Alwadiya^a, Mutaz Mohammed Nur^b, D. Sunderamoorthy^c^a Junior Clinical Fellow, Trauma and Orthopaedics, Royal Derby Hospital, United Kingdom^b Department of Histopathology, Cork University Hospital, United Kingdom^c FRCS, Consultant Orthopaedics Surgeon, Royal Derby Hospital, United Kingdom

ARTICLE INFO

Article history:

Received 19 January 2015

Received in revised form 19 March 2015

Accepted 22 March 2015

Available online 25 March 2015

Keywords:

Acquired digital fibrokeratoma

Great toe

Tumor

ABSTRACT

INTRODUCTION: Acquired digital fibrokeratoma is an uncommon, benign fibrous tumour that usually occurs in adults as a solitary lesion with a typical size of less than 1 cm.**CASE PRESENTATION:** A 48-year-old Afro-Caribbean man presented to our foot and ankle clinic with a long-standing growth over the plantar aspect of the distal phalanx of the left great toe. The growth was painful and affected the patient's mobility. It had gradually increased in size over a period of 17 years. The growth was completely excised, and the base was allowed to heal by secondary intention. The skin eventually healed, and the patient had a good outcome. The histological results confirmed that the growth was a digital fibrokeratoma.**CONCLUSION:** This case is of interest because of the rarity of digital fibrokeratoma and the unique morphological appearance of the tumor in this case. Additionally, we emphasise the importance of ruling out other causes of abnormal growths and considering fibrokeratoma during differential diagnoses.© 2015 The Authors. Published by Elsevier Ltd. on behalf of Surgical Associates Ltd. This is an open access article under the CC BY-NC-ND license (<http://creativecommons.org/licenses/by-nc-nd/4.0/>).

1. Introduction

Acquired digital fibrokeratoma is a rare benign fibrous tumor [1] that usually occurs in adults as a solitary lesion. The most frequent locations of these tumours are the fingers and toes [2–4]. The size of the tumour is generally small, approximately 3–5 mm. Although a precise standard size to define giant acquired digital fibrokeratoma has not been established, five cases of acquired digital fibrokeratoma larger than 1 cm have been reported as giant acquired digital fibrokeratomas in the literature [5–9]. Herein, we report a case of giant digital fibrokeratoma that presented like an accessory digit with nail-like changes.

2. Case report

A 48-year-old Afro-Caribbean man with a background of osteoarthritis and gout presented to our foot and ankle clinic with a growth that had developed over 17 years (Fig. 1).

On examination, a firm palpable elongated mass on the plantar aspect of the distal phalanx of the left hallux was observed. It was well-demarcated and non-pulsatile. It was approximately 3 cm in

length and had a broad base attached to the plantar aspect measuring 1.6 × 1.2 cm. The growth also showed nail-like changes at its distal end (Fig. 2).

The growth was painful and affected the patient's mobility. It had gradually increased in size over a period of 17 years. The patient had no history of trauma prior to the onset of the lesion (Fig. 3).

Under general anaesthesia, an incision was made around the base of the tumour. The incision was extended to the underlying soft tissues, which were dissected. No major blood vessels were observed, and the tumour was not attached to bone. The tumour appeared to have arisen from the superficial soft tissues of the left hallux. The growth was completely excised, and the base was allowed to heal by secondary intention. The skin eventually healed, and the patient had a good outcome (Fig. 4).

The histological report confirmed digital fibrokeratoma of the big toe (Figs. 5–7).

3. Discussion

In 1968, Bart et al. [10] described 10 cases of an uncommon acquired growth located on the fingers. Although this type of growth clinically resembled a cutaneous horn or rudimentary supernumerary digit, it had distinct histopathological findings. The authors named this growth acquired digital fibrokeratoma (ADFK). Subsequently, Pinkus [11] reported 28 more cases of ADFK; however, these lesions occurred not only on the fingers but also on the

* Corresponding author. Tel.: +44 7428210059.

E-mail addresses: Mohammedkhider84@hotmail.com (M. Ali), mutaznur@hotmail.com (M.M. Nur), dsundar6@hotmail.com (D. Sunderamoorthy).

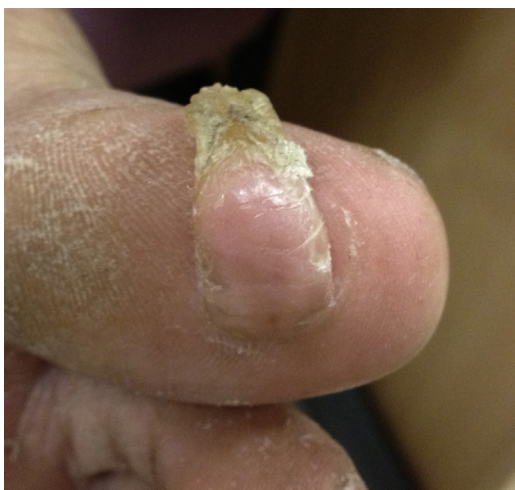

Fig. 1. Shows the site and the shape of the lump.

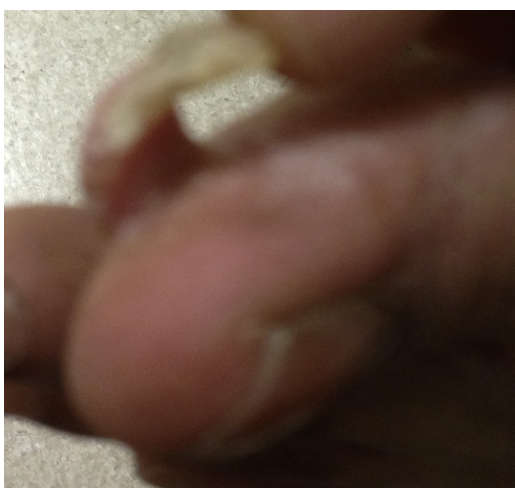

Fig.2. Shows nail like changes.

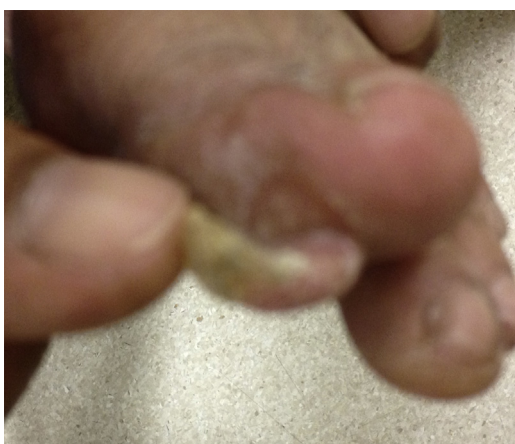


Fig. 3. Shows the base of the growth and nail like changes.

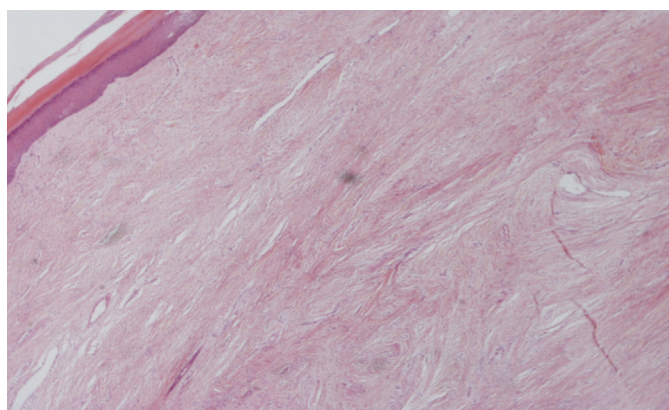


Fig. 5. Dense hyalinized and irregularly arranged collagen bundles.

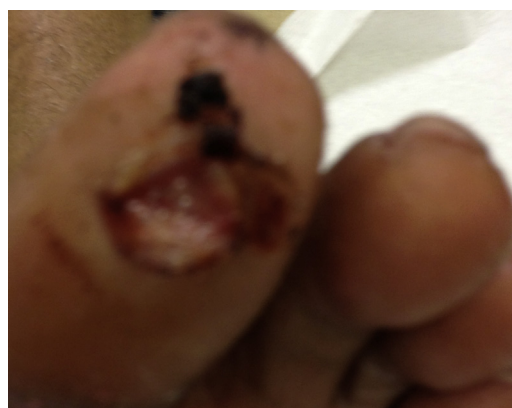

Fig. 4. After the excision.

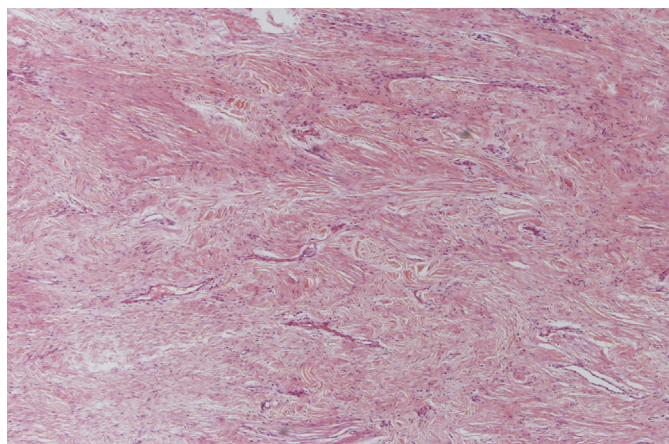


Fig. 6. Variable numbers of fibroblasts and numerous thin-walled vessels.

Table 1

Case	Sex and age	Site and size	Duration	History of trauma
Choi [5]	18 F	Lt great toe 2.5 × 1.6 × 1.4 cm	1 year	No
Bron et al. [6]	77 M	Heel 3 × 1.5 cm	Several years	unknown
Kakurai et al. [7]	33 F	Rt great toe 3.2 × 3.8 × 1.5 cm	8 years	Yes
Choe et al. [8]	62 M	Lt little toe 1 × 1 × 3 cm	5 years	No
De Freitas [9]	50 M	Heel right foot 3.0 × 2.2 × 1.0 cm	12 years	No
Present case	48 M	Lt great toe 3.0 × 1.6 × 1.2 cm	17 years	No

proximal hand, toes, sole, and the prepatellar region (one case). Thus, Verallo et al. [12] suggested that the entity may be more appropriately named acral fibrokeratoma Table 1.

Similar growths have been reported in the subungual and periungual [13,14] regions, some of which were reported in patients with tuberous sclerosis and leprosy [15,16]. These growths are

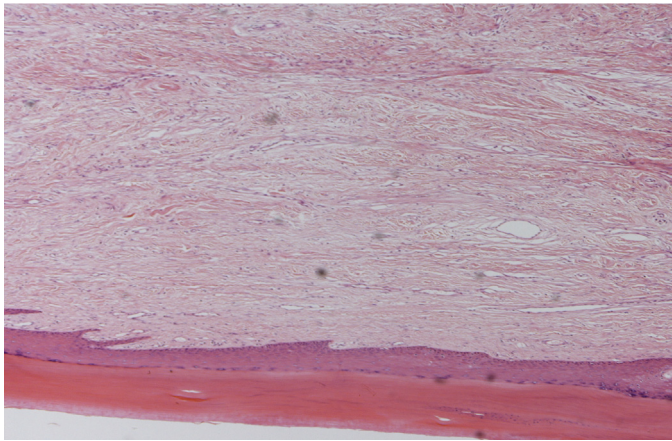


Fig. 7. The overlying epidermis is hyperkeratotic and acanthotic.

referred to as Koenen tumours or garlic clove fibromas. These growths differ from ADFK in that they tend to be multilobulated, involve several digits and, histologically, may have atypical stellate myofibroblasts [17].

Dupre et al., [18] described this tumour entity as slightly prominent, well-defined, surrounded by a hyperkeratotic collar, and protruding from the surface of the skin, much like a hernia.

Acquired digital fibrokeratomas have been reported in persons of all races, and cases have been reported in German [14], Polish [19], Japanese [20], French [21,22], and Indian [15,23] literatures. ADFK seems to have a slight predominance in males; however, currently, too few cases have been described to adequately assess the significance of any gender predilection of this tumour type [24]. Reported acquired digital fibrokeratoma cases have occurred in patients from 12 to 70 years of age, with most cases occurring in middle-aged adults. Clinically similar lesions that occur in young children are more likely to present on rudimentary supernumerary digits [25]. Most acquired digital fibrokeratoma patients present with an asymptomatic protuberance [26]; however, in our case, the patient presented with a painful growth that was affecting his mobility.

Acquired digital fibrokeratomas are almost always solitary, and only two case reports have described ADFK accompanied by another tumour. One report described a renal transplant patient on cyclosporine that developed an ADFK on a toe simultaneously with a gingival overgrowth, and the authors suggested that there may have been a causal association between these two growths [27]. Another report described an ADFK accompanied by a pyogenic granuloma [28]. In most reported cases, acquired digital fibrokeratoma presents on the fingers [29,15,30,14] and toes, while it occasionally occurs on the lower lip, nose, elbow, prepatellar area, nail bed, periungual area [13,31] and heel [5,32,33]. Additionally, ADFK does not show spontaneous regression [26].

Normally, the size of ADFK is relatively small, less than 1 cm. Kakurai et al. [7] and Choi [5] reported $3.2 \times 3.8 \times 1.5$ cm and $2.5 \times 1.6 \times 1.4$ cm acquired digital fibrokeratomas on the toe, respectively, and designated them as giant ADFKs. Bron et al. [6] reported a 3.0×1.5 cm acquired digital fibrokeratoma on the heel. Additionally, De Freitas reported a $3.0 \times 2.2 \times 1.0$ cm pedunculated firm nodule that protruded from the heel [9]. In our case, the size of the tumor was $3.0 \times 1.6 \times 1.2$ cm, and the tumor had nail-like changes; thus, we hypothesised that it was a rare case of giant ADFK.

The pathophysiology of an acquired digital fibrokeratoma is unknown. Trauma has often been proposed as a predisposing factor for ADFK, but case histories have not supported this hypothesis [7,34]. It is presumed that trauma or local factors result in an epidermo-dermal interaction and the development of

fibroepithelial tumours. The lesions are usually dome-shaped, although they may present as elongated finger-like projections, as in our case.

In this case, the histopathologic examination revealed hyperkeratosis and irregular acanthosis in the epidermis and thick collagen bundles with dilated capillaries oriented in the direction of the longitudinal axis of the dermis. Kint et al. [34] described 3 types of acquired digital fibrokeratomas by their clinical and histopathologic features. Type I acquired digital fibrokeratoma is a dome-shaped lesion that contains fibroblasts between collagen bundles, fine elastic fibres and numerous capillaries in the dermis. Type II ADFK is typically tall and is a hyperkeratotic lesion that contains many more fibroblasts and less elastic fibres than type I ADFK. Type III ADFK is a flat to dome-shaped lesion characterised by poorly cellular and edematous structures and no elastic fibres. The tumour in this case had the typical histopathologic findings of type II acquired digital fibrokeratoma.

Differential diagnoses include cutaneous horn, neurofibroma, pyogenic granuloma, and supernumerary digit. Although cutaneous horns resemble ADFKs clinically, they do not have a prominent core of outgrowing connective tissue and often have epidermal neoplasia at the base [35]. Neurofibromas are soft, polypoid skin-colored tumors. On histopathologic examination, the dermis of this tumour type is composed of loosely spaced spindle cells and wavy collagenous strands. Supernumerary digits, usually observed at the base of the 5th digit, are present at birth and may be bilateral. Pyogenic granulomas are more consistently related to trauma and are more friable than the other tumour types described here; they are also histologically distinct in their early stages. However, as a pyogenic granuloma matures, increased fibrosis and decreased vascularity may make histological differentiation difficult. C.C. Chi [36] reported a non-tender, firm nodule on the thumb that had been present for three years. The lesion clinically resembled acquired digital fibrokeratoma but was found to be an aggressive digital papillary adenocarcinoma after pathologic study of the excised specimens. Superficial acral fibromyxoma and angiofibroma can also be included in the differential diagnosis for ADFK; [37,38] however, they have different histological characteristics.

4. Conclusion

The diagnosis of lumps or abnormal growths can be challenging, especially if faced with an unusual presentation, as in this case. A thorough clinical and histopathological examination should be performed in all cases. We emphasise the importance of ruling out other causes of abnormal growths and considering fibrokeratoma during differential diagnoses. Excellent functional recovery is expected after surgical excision of ADFKs.

Conflicts of interest

No conflicts of interest.

Funding

No any sources of funding.

Consent

Written informed consent was obtained from the patient for publication of this case report and accompanying images. A copy of the written consent is available for review by the Editor-in-Chief of this journal on request.

Author contributions

Mohammed K.M. Ali – has contributed to Study concept, design data collection, data analysis and writing of the paper.

C.A. Mbah and A. Alwadiya – prepared the case report.

Mutaz Nur – contributed to histology description.

D. Sunderamoorthy – contributed toward the management and follow up of the patient.

References

- [1] R.P. Vinson, V.L. Angeloni, Acquired digital fibrokeratoma, *Am. Fam. Physician* 52 (October (5)) (1995) 1365–1367, PubMed PMID: 7572559.
- [2] T.J. Boffeli, K.W. Abben, Acral fibrokeratoma of the foot treated with excision trap door flap closure: a case report, *J. Foot Ankle Surg.* 53 (July–August (4)) (2014) 449–452, <http://dx.doi.org/10.1053/j.jfas.2013.09.018>, Epub 2013 Nov 20. PubMed PMID: 24268767.
- [3] D. Yu, R.F. Morgan, Acquired digital fibrokeratoma: a case report, *Ann. Plast. Surg.* 18 (September) (2013) [Epub ahead of print] PubMed PMID: 24051460.
- [4] Y.Y. Lu, C.C. Lu, C.H. Wu, Giant digital fibrokeratoma of the finger, *Int. J. Dermatol.* 53 (March (3)) (2013) e205–207, <http://dx.doi.org/10.1111/ijd.12130>, Epub 2013 May 15. PubMed PMID: 23675880.
- [5] J.H. Choi, Giant acquired digital fibrokeratoma occurring on the left great toe, *Ann. Dermatol.* 23 (February (1)) (2011) 64–66.
- [6] C. Bron, B. Noël, R.G. Panizzon, Giant fibrokeratoma of the heel, *Dermatology* 208 (2004) 271–272 [PubMed].
- [7] M. Kakurai, T. Yamada, T. Kiyosawa, M. Ohtsuki, H. Nakagawa, Giant acquired digital fibrokeratoma, *J. Am. Acad. Dermatol.* 48 (May Suppl. (5)) (2003) S67–68, PubMed. PMID: 12734480.
- [8] E.A. Cho, W.S. Lee, S.Y. Kim, A case of giant acquired digital fibrokeratoma resembling supernumerary digit, *Kor. J. Dermatol.* 45 (2007) 319–320.
- [9] P.M. de Freitas, M.H. de Sb Xavier, G.B. Pereira, M.C. Rochaël, J.L. de Oliveira Cortes, L.P. Quevedo, A.A. Araripe Jr., Acquired fibrokeratoma presenting as a giant pedunculated lesion on the heel, *Dermatol. Online J.* 14 (December (12)) (2008) 10, PubMed. PMID: 19265623.
- [10] R.S. Bart, R. Andrade, A.W. Kopf, M. Leider, Acquired digital fibrokeratomas, *Arch. Dermatol.* 97 (February (2)) (1968) 120–129 [Medline].
- [11] H. Pinkus, Discussion – acquired digital fibrokeratoma, *Arch. Dermatol.* 97 (1968) 128–129.
- [12] V.V. Verallo, Acquired digital fibrokeratomas, *Br. J. Dermatol.* 80 (November (11)) (1968) 730–736 [Medline].
- [13] R. Kumari, D.M. Thappa, A. Devi, Periungual acquired digital fibrokeratoma, *Indian J. Dermatol. Venereol. Leprol.* 75 (January–February (1)) (2009) 72 [Medline].
- [14] U. Bode, G. Burg, The acquired digital fibrokeratoma, *Hautarzt* 29 (December (12)) (1978) 659–660, German. PubMed PMID: 721475.
- [15] A.H. Patki, J.M. Mehta, Acquired digital fibrokeratoma in a patient with leprosy, *Indian J. Lepr.* 64 (April–June (2)) (1992) 205–208, PubMed. PMID: 1607722.
- [16] P. LoBuono, T. Jothikumar, L. Kornblee, Acquired digital fibrokeratoma, *Cutis* 24 (July (1)) (1979) 50–51, PubMed. PMID: 477378.
- [17] R.M. Carlson, K.M. Lloyd, T.E. Campbell, Acquired periungual fibrokeratoma: a case report, *Cutis* 80 (August (2)) (2007) 137–140 [Medline].
- [18] A. Dupré, B. Christol, M. Bories, Acquired fibro-keratoma. Report of 8 cases, *Ann. Dermatol. Venereol.* 104 (October (10)) (1977) 611–615, French. PubMed PMID: 016514.
- [19] J. Rubisz-Brzezińska, A. Smigla, D. Musialowicz, T. Zembracka, [Fibrokeratoma (acquired digital fibrokeratoma)], *Przegl. Dermatol.* 60 (May–June (3)) (1973) 347–352, Polish. PubMed PMID: 4748076.
- [20] K. Sakamoto, H. Kitamura, [2 cases of acquired digital fibrokeratoma], *Hifuka Kiyō* 65 (November (3)) (1970) 305–307, Japanese. PubMed PMID: 5535226.
- [21] J.D. Geiser, [Acquired digital fibrokeratoma], *Dermatologica* 143 (1) (1971) 21–28, French. PubMed PMID: 5131765.
- [22] M. de Sablet, I. Bernard, [Bart-Andrade acquired digital fibrokeratoma], *Bull. Soc. Fr. Dermatol. Syphiligr.* 76 (6) (1969) 836–837, French. PubMed PMID: 5384219.
- [23] T.R. Bedi, M. Mohindra, Acquired digital fibrokeratoma, *Indian J. Dermatol.* 20 (January (2)) (1975), 27–28 PubMed PMID: 1234865.
- [24] C. Baykal, N. Buyukbabani, K.D. Yazganoglu, E. Saglik, Acquired digital fibrokeratoma, *Cutis* 79 (February (2)) (2015) 129–132, PubMed PMID: 2588213.
- [25] <http://emedicine.medscape.com/article/1055825-overview#a0199>.
- [26] A.F. Frydman, S.E. Mercer, R. Kleinerman, V.R. Yanofsky, M.B. Birge, Acquired fibrokeratoma presenting as multiple plantar nodules, *Dermatol. Online J.* 16 (October (10)) (2010) 5, PubMed PMID: 21062599.
- [27] J. Qiao, Y.H. Liu, K. Fang, Acquired digital fibrokeratoma associated with ciclosporin treatment, *Clin. Exp. Dermatol.* 34 (March (2)) (2009) 257–259 [Medline].
- [28] D.R. Lee, J.Y. Lee, J.Y. Ahn, M.Y. Park, A case of acquired digital fibrokeratoma accompanied by pyogenic granuloma, *Dermatol. Online J.* 15 (January (1)) (2009) 8, PubMed PMID: 19281713.
- [29] S.K. Rathi, D. Dogra, N. Khanna, Acquired digital fibrokeratoma, *Indian J. Dermatol. Venereol. Leprol.* 64 (March–April (2)) (1998) 78–79, PubMed PMID: 20921721.
- [30] J.R. Hemric, H.B. Allen, Acquired digital fibrokeratoma, *Cutis* 23 (March (3)) (1979) 304–306, PubMed PMID: 421498.
- [31] R.M. Carlson, K.M. Lloyd, T.E. Campbell, Acquired periungual fibrokeratoma: a case report, *Cutis* 80 (August (2)) (2007) 137–140, PubMed PMID: 17944173.
- [32] A.K. Jaiswal, M. Chatterjee, Acquired (digital) fibrokeratoma, *Indian J. Dermatol. Venereol. Leprol.* 68 (March–June (3)) (2002) 179–180, PubMed PMID: 17656932.
- [33] P. Rubegni, S. Poggiali, A. Lamberti, A. Chiantini, M. De Paola, C. Peccianti, M. Fimiani, Dermoscopy of acquired digital fibrokeratoma, *Australas. J. Dermatol.* 53 (February (1)) (2011) 47–48, <http://dx.doi.org/10.1111/j.1440-0960.2011.00793.x>, Epub 2011 July 12. PubMed PMID: 22309331.
- [34] A. Kint, R. Baran, H. De Keyser, Acquired (digital) fibrokeratoma, *J. Am. Acad. Dermatol.* 12 (1985) 816–821.
- [35] T. Salim, C. Balachandran, Acquired digital fibrokeratoma, *Indian J. Dermatol. Venereol. Leprol.* 67 (2001) 273.
- [36] C.C. Chi, T.T. Kuo, S.H. Wang, Aggressive digital papillary adenocarcinoma: a silent malignancy masquerading as acquired digital fibrokeratoma, *Am. J. Clin. Dermatol.* 8 (4) (2007) 243–245, PubMed PMID: 17645380.
- [37] J.F. Fetsch, W.B. Laskin, M. Miettinen, Superficial acral fibromyxoma: a clinicopathologic and immunohistochemical analysis of 37 cases of a distinctive soft tissue tumor with a predilection for the fingers and toes, *Hum. Pathol.* 32 (July (7)) (2001) 704–714, PubMed PMID: 11486169.
- [38] L.M. Tisa, A. Iurcotta, Solitary periungual angiofibroma. An unusual case report, *J. Am. Podiatr. Med. Assoc.* 83 (December (12)) (1993) 679–680, PubMed PMID: 8283393.

Open Access

This article is published Open Access at sciedirect.com. It is distributed under the [IJSCR Supplemental terms and conditions](#), which permits unrestricted non commercial use, distribution, and reproduction in any medium, provided the original authors and source are credited.