

Received: 2018.04.05
Accepted: 2018.07.06
Published: 2018.09.21

e-ISSN 1941-5923
© Am J Case Rep, 2018; 19: 1121-1125
DOI: 10.12659/AJCR.910426

Insulinoma: A Rare Cause of Hypoglycemia in Childhood

Authors' Contribution:
Study Design A
Data Collection B
Statistical Analysis C
Data Interpretation D
Manuscript Preparation E
Literature Search F
Funds Collection G

ABCDEF 1 **Rocío Escartín**
ABD 2 **Nuria Brun**
BD 3 **M. Nieves García Monforte**
BD 4 **Joan Carles Ferreres**
ABCDEFG 1 **Raquel Corripio**

1 Department of Pediatric Endocrinology, Parc Taulí Hospital Universitari, Research and Innovation Institute Parc Taulí I3PT, Autonomous University of Barcelona, Sabadell, Spain
2 Department of Pediatric Surgery, Parc Taulí Hospital Universitari, Research and Innovation Institute Parc Taulí I3PT, Autonomous University of Barcelona, Sabadell, Spain
3 Department of Surgery, Parc Taulí Hospital Universitari, Research and Innovation Institute Parc Taulí I3PT, Autonomous University of Barcelona, Sabadell, Spain
4 Department of Pathology, Parc Taulí Hospital Universitari, Research and Innovation Institute Parc Taulí I3PT, Autonomous University of Barcelona, Sabadell, Spain

Corresponding Author: Raquel Corripio, e-mail: raquelcorripio@gmail.com, rcorripio@tauli.cat
Conflict of interest: None declared

Patient: Male, 11
Final Diagnosis: Insulinoma
Symptoms: Dizziness • psychological issues
Medication: —
Clinical Procedure: —
Specialty: Endocrinology and Metabolic





Objective: Rare disease
Background: Insulinomas are pancreatic neuroendocrine tumors that cause non-ketotic hypoglycemia due to hyperinsulinism; they are extremely rare, especially in children.

Case Report: We present a case of a sporadic insulinoma in an 11-year-old boy who had episodes of self-limited drowsiness and behavior changes over a 3-month period, thought to be caused by psychological issues. Non-ketotic hypoglycemia was confirmed at our center. A fasting blood test found inappropriately elevated insulin levels during hypoglycemia, undetectable β -hydroxybutyrate, and increased C-peptide levels in line with insulin levels. Anti-insulin antibodies were negative and antidiabetic drugs untraceable. The glucagon-stimulation test was positive. Growth hormone, adrenocorticotropin hormone, and phosphorus and calcium metabolism were normal. Dual-phase computed tomography detected a lesion compatible with an insulinoma. Endoscopic ultrasound showed a homogenous lesion at the junction of the body and tail of the pancreas. Histologic analysis of a fine-needle aspiration biopsy was compatible with neuroendocrine neoplasia. Preoperatively, a fractional diet avoiding fast-absorbing carbohydrates maintained normal glucose blood levels. Enucleation was not possible, so the lesion was resected along with portions of the body and tail of the pancreas. The well-differentiated tumor measured 15×13 mm. Postoperative blood glucose levels were correct, allowing a normal diet.

Conclusions: In children with unspecific symptoms compatible with hypoglycemia, blood glucose must be evaluated to confirm low blood glucose levels. Determining blood ketone levels is important for the differential diagnosis. The diagnostic approach to pediatric insulinoma represents a challenge for multidisciplinary teamwork.

MeSH Keywords: Child • Endoscopic Ultrasound-Guided Fine Needle Aspiration • Hyperinsulinism • Hypoglycemia • Insulinoma

Full-text PDF: <https://www.amjcaserep.com/abstract/index/idArt/910426>

 1400   4  27



Background

Insulinomas are extremely rare, with an estimated incidence of 1 to 4 cases per million persons per year [1–3]; most insulinomas are diagnosed in adults [4].

Insulinomas are insulin-producing neuroendocrine pancreatic tumors that cause non-ketotic hypoglycemia due to endogenous hyperinsulinism [5]. The initial diagnosis is based on Whipple's triad: symptoms compatible with hypoglycemia, low blood glucose levels measured at the time of symptoms, and improvement in symptoms after carbohydrates administration [6]; the diagnosis is confirmed by the demonstration of inadequately high serum insulin levels during hypoglycemia [7].

Insulinomas are usually benign, isolated lesions, but malignant insulinomas have been reported in children [8]. About 10% of insulinomas are associated with multiple endocrine neoplasia type 1 (MEN-1) [1,2,9]. MEN-1 is an autosomal dominant syndrome in which tumors develop in the parathyroid, anterior pituitary, and pancreas. In more than 85% of patients, parathyroid tumors are the first manifestation, resulting in primary hyperparathyroidism [10].

Case Report

An 11-year-old white boy was admitted to our pediatric emergency room for an episode of fainting lasting a few seconds. Blood tests revealed hypoglycemia (42 mg/dL); intravenous infusion 10% glucose normalized his blood sugar levels and his symptoms resolved.

His family explained that over the previous 3 months, coinciding with his parents' recent separation, he had had self-limiting episodes of dizziness, sometimes needing to lie down for a few seconds, almost always in the morning before going to school. During the last few weeks, he also showed a change of character, with moments of agitation alternating with drowsiness. His parents thought that the symptoms were psychological and related to his family situation, and the boy had an upcoming appointment at a mental health center.

Blood glucose returned to normal after intravenous glucose infusion. The boy was discharged home on a Saturday evening and was scheduled for a follow-up visit at our pediatric Endocrinology Department 2 days later. He was given a glucometer to check his blood sugar if symptoms reappeared.

He returned to the Emergency Department 48 h after discharge, before his scheduled appointment, for a self-limited episode of diplopia with capillary glycemia 45 mg/dL measured at home. On arrival at the hospital, the boy was asymptomatic,

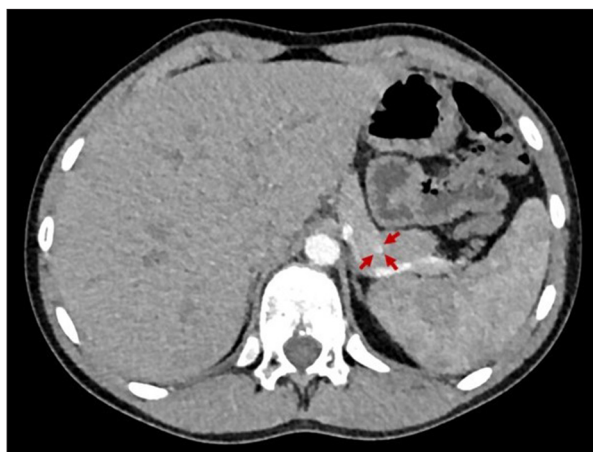

Figure 1. Dual-phase abdominal CT. Enhancing lesion measuring 10 mm in diameter in the junction of the body and tail of the pancreas.

but capillary glycemia was 44 mg/dL without ketonemia. His hypoglycemia was treated, and he was admitted for observation.

A fasting glucose test found hypoglycemia (21 mg/dL) within 2 h in the presence of inappropriately elevated insulin concentrations (10.6 μ U/mL) and C-peptide levels (1.77 ng/mL). Tests for anti-insulin antibodies and oral antidiabetic drugs were negative. β -hydroxybutyrate was undetectable in the blood. Cortisol, ACTH, GH, and phosphorus and calcium metabolism were normal; together with the absence of a family history, these findings made the diagnosis of MEN1 highly unlikely. The glucagon test was positive: glycemia increased from 45 mg/dL to 104 mg/dL, pointing to endogenous hyperinsulinism.

Findings of an abdominal ultrasound were normal. Dual-phase computed tomography (CT) within 24 h of admission showed an isolated enhancing lesion measuring 11 mm in diameter in the junction of the body and tail of the pancreas, compatible with insulinoma (Figure 1).

Endoscopic ultrasound showed a homogeneous isoechoic lesion measuring 11 mm x 13 mm in the junction of the body and tail of the pancreas that lacked the "salt-and-pepper" pattern characteristic of normal pancreatic tissue. Histologic examination of the fine-needle aspiration (FNA) biopsy specimen found large cytoplasmic cells with large, eccentric nuclei containing granular chromatin, findings compatible with neuroendocrine neoplasia. Immunohistochemistry was positive for synaptophysin and chromogranin, and the estimated proliferation index was 5% (Figure 2).

The Surgical Committee opted for laparoscopic partial pancreatectomy.

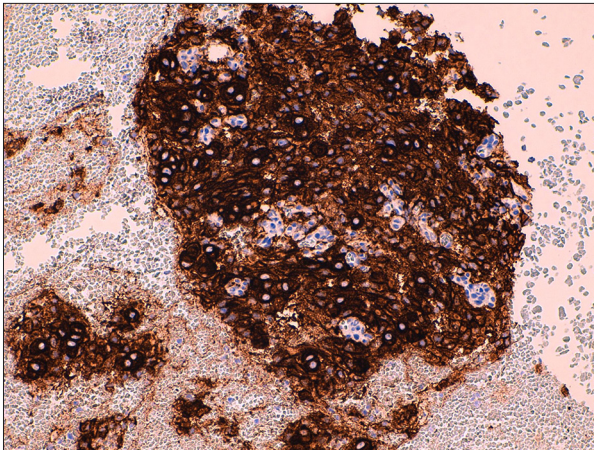


Figure 2. Fine-needle aspiration biopsy. Large cytoplasmic cells with large nuclei, positive for chromogranin (brown) in immunohistochemistry.

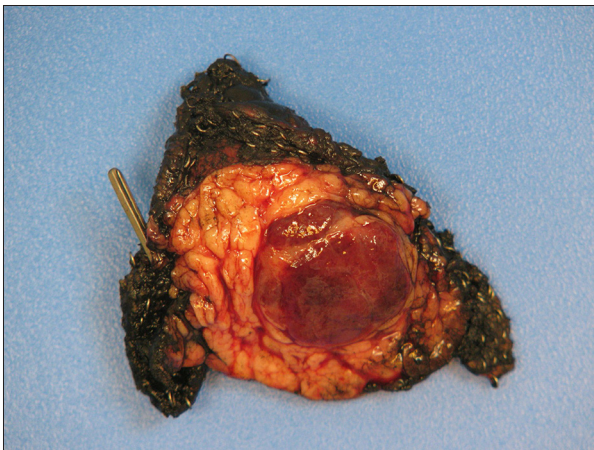


Figure 3. Surgical specimen. The insulinoma, a round lesion measuring 15×13 mm with free margins, is located in the center of a triangular fragment of resected pancreas measuring 40×32×16 mm.

Preoperatively, our patient had a severe tendency to hypoglycemia; his blood glucose levels dropped below 50 mg/dL after ingesting fast-absorbing carbohydrates or during fasting longer than 3 hours. Blood glucose levels normalized with adherence to a diet consisting of frequent meals with small portions and avoiding fast-absorbing carbohydrates. The tumor location precluded enucleation, so the tumor was resected with part of the body and tail of the pancreas under intraoperative ultrasound guidance. No complications occurred during the procedure.

A histologic study showed a well-differentiated pancreatic neuroendocrine tumor measuring 15×13 mm (Figure 3) made up of large trabeculae and solid nests of cells larger than the islet cells in the rest of the pancreas; the tumor cells had round central nuclei with thick chromatin and prominent nucleoli.

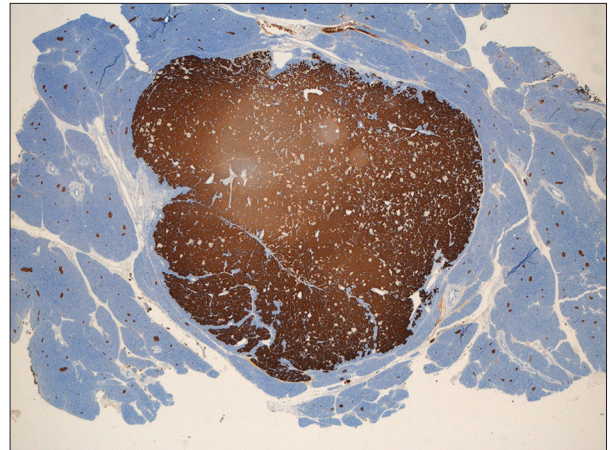


Figure 4. Microscopic image showing the synaptophysin-positive cells in brown. A well-delimited, non-encapsulated lesion resembling a giant Langerhans islet can be identified. In the rest of the pancreatic parenchyma, normal-appearing Langerhans islets can be observed.

No necrosis or mitotic figures were seen. Immunohistochemistry showed diffuse and intense expression of synaptophysin and heterogeneous expression of chromogranin (Figure 4).

After surgery, blood glucose levels remained within the normal range, allowing the patient to have a normal diet. He presented no further symptoms of hypoglycemia, and subsequent follow-ups were normal. He has not developed carbohydrate intolerance to date.

Discussion

This case illustrates how insulinomas may be initially mistaken for a psychological or neurological disorder [1,9,11]. Unspecific symptoms such as dizziness, drowsiness, or behavioral changes in children – especially in the mornings, after fasting through the night – might be due to hypoglycemia [11–13], and it is important to check Whipple's triad to rule out an insulinoma.

In the differential diagnosis of hypoglycemia in children, it is fundamental to determine whether ketonemia is present. Ketonemia is present in hypoglycemia caused by a wide range of conditions, such as substrate deficiency, deficiency of counterregulatory hormones, abnormal liver glycogen metabolism, or ketotic hypoglycemia [9]. Ketonemia is not present in fatty-acid metabolism disorders (in which blood levels of fatty acids are elevated) or in hyperinsulinemic hypoglycemia. In hyperinsulinism, C-peptide levels in line with elevated insulin levels, together with negative screening for antidiabetic drugs, help rule out exogenous causes and direct the diagnosis toward an insulinoma or congenital hyperinsulinism [9]. Given that congenital hyperinsulinism usually manifests in the neonatal

period [3], we reasoned that the endogenous hyperinsulinism in this 11-year-old boy was most likely due to an insulinoma.

Abdominal CT located the lesion, endoscopic ultrasound confirmed its presence and enabled its biopsy, and histologic analysis confirmed that it was a neuroendocrine tumor.

Although some authors recommend MRI as the first-line imaging test because it does not use ionizing radiation and has a higher sensitivity than CT [9,14,15], the sensitivity of dual-phase CT is also high (85–100%) [16,17]. In some reported cases, abdominal ultrasonography identified an insulinoma [3,12], but not in our case. The sensitivity of 18F-DOPA PET/CT is inconsistent [15,18]. When other techniques fail to demonstrate an insulinoma in cases with strong suspicion, intra-arterial calcium stimulation yields good results [19]. Intraoperative ultrasound has multiple advantages that optimize treatment [19].

Endoscopic ultrasound combined with FNA is a new strategy for diagnosing pancreatic neuroendocrine tumors. This technique is believed to have better sensitivity than CT or MRI [20–23], although some authors disagree [15]. It is important to remember that endoscopic ultrasound is operator-dependent and that the technique is evolving [15,24]. A small, homogenous lesion, as in our case, suggests a benign endocrine tumor [20,22]. Furthermore, endoscopic ultrasound can guide FNA biopsy, which can confirm the diagnosis of neuroendocrine tumors, although additional studies are required to grade malignant lesions [22]. Further investigations are needed to establish recommendations on the diagnostic approach to pediatric insulinoma.

The standard treatment of insulinoma is surgery, but endoscopic-ultrasound-guided ethanol ablation of pancreatic neuroendocrine tumors has proven safe and efficacious in adult patients in whom surgery is contraindicated [25–27].

References:

1. Service FJ, McMahon MM, O'Brien PC, Ballard DJ: Functioning insulinoma – incidence, recurrence, and long-term survival of patients: A 60-year study. *Mayo Clin Proc*, 1991; 66(7): 711–19
2. Abu-Zaid A, Alghuneim LA, Metawee MT et al: Sporadic insulinoma in a 10-year-old boy: A case report and literature review. *JOP*, 2014; 15(1): 53–57
3. Miron I, Diaconescu S, Aprodu G et al: Diagnostic difficulties in a pediatric insulinoma: A case report. *Medicine (Baltimore)*, 2016; 95(11): e3045
4. Patel S, Narwari M, Parekh D, Shah V: Insulinoma: Case report and review of diagnostic and treatment modalities. *J Assoc Physicians India*, 2013; 61(6): 423–26
5. Palladino AA, Bennett MJ, Stanley CA: [Hyperinsulinism in infancy and childhood: when an insulin level is not always enough]. *Ann Biol Clin (Paris)*, 2009; 67(3): 245–54
6. Whipple AO, Frantz VK: Adenoma of islet cells with hyperinsulinism: A review. *Ann Surg*, 1935; 101(6): 1299–335
7. Hirshberg B, Livi A, Bartlett DL et al: Forty-eight-hour fast: The diagnostic test for insulinoma. *J Clin Endocrinol Metab*, 2000; 85(9): 3222–26
8. Chaturvedi D, Khadgawat R, Kanakamani J et al: Management challenges in a child with hyperinsulinemic hypoglycemia. *Clin Pediatr Endocrinol*, 2008; 17(3): 61–64
9. Gozzi Graf T, Brändle M, Clerici T, l'Allemand D: Insulinoma: Only in adults? case reports and literature review. *Eur J Pediatr*, 2014; 173(5): 567–74
10. Thakker RV: Multiple endocrine neoplasia type 1 (MEN1) and type 4 (MEN4). *Mol Cell Endocrinol*, 2014; 386(1–2): 2–15
11. Kao KT, Simm PJ, Brown J: Childhood insulinoma masquerading as seizure disorder. *J Paediatr Child Health*, 2014; 50(4): 319–22
12. Odagiri S, Tokuhara D, Nishigaki S et al: Double pancreatic tumors in an adolescent: Imaging features. *Pediatr Int*, 2016; 58(11): 1239–42
13. Mann JR, Rayner PH, Gourevitch A: Insulinoma in childhood. *Arch Dis Child*, 1969; 44(236): 435–44
14. Jaksic T, Yaman M, Thorner P et al: A 20-year review of pediatric pancreatic tumors. *J Pediatr Surg*, 1992; 27(10): 1315–17
15. Padidela R, Fiest M, Arya V et al: Insulinoma in childhood: Clinical, radiological, molecular and histological aspects of nine patients. *Eur J Endocrinol*, 2014; 170(5): 741–47

We considered ethanol ablation of the lesion in our patient, because endoscopic ultrasound was performed and our center is experienced in this technique; however, we found no reports of ethanol ablation in children and our patient had no contraindications for surgery. In this case, our team opted for the classic surgical treatment, although it is not risk free [26]; nevertheless, ethanol ablation is a promising management strategy that we will consider in the future.

A fractional diet avoiding fast-absorbing carbohydrates was sufficient for our patient to maintain normal glucose blood levels without having to resort to medications with known adverse effects [3] and that are not always efficacious [15].

Conclusions

In children with unspecific symptoms compatible with hypoglycemia, blood glucose must be evaluated to confirm the existence of low blood glucose levels. This simple procedure can allow the diagnosis of severe but treatable diseases. After hypoglycemia is confirmed, another simple test, determining blood ketone levels, is very useful for differential diagnosis.

The diagnostic approach to pediatric insulinoma encompasses a wide range of possibilities and represents a challenge for multidisciplinary teamwork.

Acknowledgements

We thank John Giba for his assistance in language editing.

Conflict of interest

None.

16. Das CJ, Debnath J, Gupta AK, Das AK: MR imaging appearance of insulinoma in an infant. *Pediatr Radiol*, 2007; 37(6): 581–83
17. Chung EM, Travis MD, Conran RM: Pancreatic tumors in children: Radiologic-pathologic correlation. *Radiographics*, 2006; 26(4): 1211–38
18. Kauhanen S, Seppänen M, Minn H, Nuutila P: Clinical PET imaging of insulinoma and beta-cell hyperplasia. *Curr Pharm*, 2010; 16(14): 1550–60
19. Peranteau WH, Palladino AA, Bhatti TR et al: The surgical management of insulinomas in children. *J Pediatr Surg*, 2013; 48(12): 2517–24
20. Lee LS: Diagnosis of pancreatic neuroendocrine tumors and the role of endoscopic ultrasound. *Gastroenterol Hepatol (N Y)*, 2010; 6(8): 520–22
21. Pais SA, Al-Haddad M, Mohamadnejad M et al: EUS for pancreatic neuroendocrine tumors: A single-center, 11-year experience. *Gastrointest Endosc*, 2010; 71(7): 1185–93
22. Fujimori N, Osoegawa T, Lee L et al: Efficacy of endoscopic ultrasonography and endoscopic ultrasonography-guided fine-needle aspiration for the diagnosis and grading of pancreatic neuroendocrine tumors. *Scand J Gastroenterol*, 2016; 51(2): 245–52
23. Bonfig W, Kann P, Rothmund M, Schwarz HP: Recurrent hypoglycemic seizures and obesity: Delayed diagnosis of an insulinoma in a 15-year-old boy – final diagnostic localization with endosonography. *J Pediatr Endocrinol Metab*, 2007; 20(9): 1035–38
24. Druce MR, Muthuppalaniappan VM, O’Leary B et al: Diagnosis and localisation of insulinoma: The value of modern magnetic resonance imaging in conjunction with calcium stimulation catheterisation. *Eur J Endocrinol*, 2010; 162(5): 971–78
25. Qin SY, Lu XP, Jiang HX: EUS-guided ethanol ablation of insulinomas: Case series and literature review. *Medicine (Baltimore)*, 2014; 93(14): e85
26. Paik WH, Seo DW, Dhir V, Wang HP: Safety and efficacy of EUS-guided ethanol ablation for treating small solid pancreatic neoplasm. *Medicine (Baltimore)*, 2016; 95(4): e2538
27. Levy MJ, Thompson GB, Topazian MD et al: US-guided ethanol ablation of insulinomas: A new treatment option. *Gastrointest Endosc*, 2012; 75(1): 200–6