

## Management of a case of *Candida albicans* endogenous endophthalmitis with intravitreal caspofungin

Harshali Manish Yadav, Boben Thomas<sup>1</sup>,  
Cherian Thampy<sup>1</sup>, Tandava Krishnan Panaknti<sup>2</sup>

We report a case of *Candida albicans* endogenous endophthalmitis treated with intravitreal caspofungin. The patient was a known case of acute lymphoblastic leukemia on chemotherapy and presented to us with features suggestive of endogenous endophthalmitis. He was treated initially with intravenous (IV) caspofungin and intravitreal amphotericin B. Patient's condition worsened after IV caspofungin was replaced by amphotericin B necessitating a core vitrectomy. The patient was given the option of off-label caspofungin intravitreal injection for which the patient consented. There was a gradual improvement in the clinical picture. The situation worsened after the injections were stopped necessitating a re-vitrectomy. The study demonstrates the clinical efficacy of intravitreal caspofungin for the first time in human eyes.

**Key words:** *Candida albicans*, caspofungin, endogenous endophthalmitis, intravitreal injections

Endogenous endophthalmitis in cases of fungal sepsis is a rare but sight-threatening complication.<sup>[1,2]</sup> *Candida albicans* is the most commonly isolated organism (52%) and majority of the cases have a compromised immunity.<sup>[2,3]</sup> The limited therapeutic options available make the management challenging. We report a case of fungal endophthalmitis managed using intravitreal caspofungin. To the best of our knowledge, this is the first case of candida endophthalmitis managed by intravitreal caspofungin.

### Case Report

A 21-year-old male patient presented to us with complaints of pain and redness in the left eye. On examination, his best-corrected visual acuity was 6/9 in the right eye and 6/18 in the left eye. Right eye examination was within normal limits. Left eye examination revealed ciliary congestion, with 3+ cells and 1+ flare in the anterior chamber (AC). Fundus examination

revealed left eye chorioretinitis with preretinal exudates and moderate vitritis [Fig. 1]. He was a known case of T-cell acute lymphoblastic leukemia (ALL) who had undergone induction chemotherapy 1 month ago for the same with signs of bone marrow remission. He developed high-grade fever with myalgia 1 week prior. *C. albicans* was detected on blood culture which was sensitive to amphotericin, caspofungin, and flucytosine and resistant to fluconazole and voriconazole. Blood tests for leptospira, dengue, malaria, hepatitis B, Hepatitis C, HIV, and typhus were all negative. Based on the sensitivity report, he was started on intravenous (IV) caspofungin 70 mg once a day. AC tap was done and patient was given intravitreal amphotericin injection (50µg/0.01ml) which was repeated two more times every 48 h. The AC tap did not reveal any growth. At this juncture IV caspofungin was replaced with IV amphotericin B 300 mg due to financial reasons. The ocular condition deteriorated with decrease in best-corrected visual acuity (BCVA) (6/36). The patient also had subretinal exudates and localized exudative retinal detachment (RD). The patient underwent core vitrectomy and intravitreal amphotericin B injection. Vitreous tap at this juncture was negative for all growth. However, the condition worsened and BCVA deteriorated to counting finger 1 m. In view of the deteriorating clinical situation, after discussion with the hospital medical board, the patient was given an option of intravitreal caspofungin after explaining the off-label use, lack of literature regarding the usage of the same in human eyes and therefore the possible risk of toxicity involved. The patient consented for the same and an alternate day regime of intravitreal caspofungin (50 µg/0.1 ml) and amphotericin B was given. The patient who was also continued on IV amphotericin B showed gradual reduction in the size of subretinal lesion and resolution of exudative RD with BCVA improving to 6/36 [Fig. 2a and b]. A total of 8 intravitreal injections (4 each) were given. The patient was started on the second cycle of chemotherapy which resulted in generalized weakness, vomiting, and thrombocytopenia. The patient also developed hypokalemia and altered renal function due to nephrotoxicity caused by use of IV amphotericin B. The patient at this point refused further intravitreal injections. The subretinal fluid recurred after cessation of intravitreal therapy. One week after cessation of intravitreal treatment, he developed vitreous hemorrhage (precipitated by thrombocytopenia) which was treated by vitrectomy, silicone oil injection, and intravitreal caspofungin. His ocular condition then stabilized with progressive reduction in subretinal fluid and fibrosis of the preretinal exudates. He developed hard exudates at posterior pole following resolution of exudative detachment [Fig. 3]. His BCVA 1 month postsurgery in left eye was 6/24.

### Discussion

*C. albicans* is the most common cause of fungal endogenous endophthalmitis. It is usually seen in immunocompromised

Access this article online	
Quick Response Code:	Website: www.ijjo.in
	DOI: 10.4103/ijjo.IJO_781_16

Department of Ophthalmology, <sup>1</sup>Department of Cancer Care, Kerala Institute of Medical Science, P.B.No.1, Anayara P.O, Trivandrum, Kerala, <sup>2</sup>Neoretina Eye Care Institute, Dr.P.Ramchander House, 5-9-83/B, Nampally, Hyderabad, Telangana, India

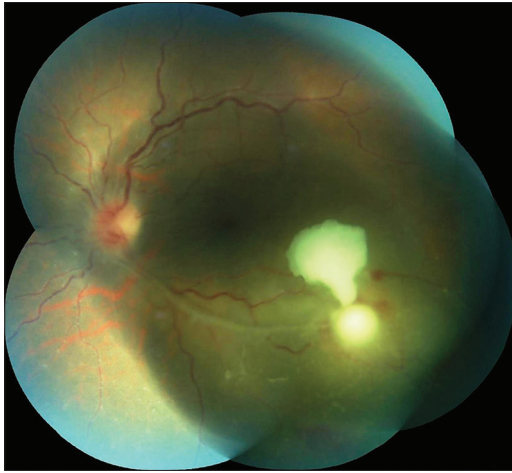
**Correspondence to:** Dr. Harshali Manish Yadav, Department of Ophthalmology, Kerala Institute of Medical Sciences, P. No. 1, Anayara P., Thiruvananthapuram - 695 029, Kerala, India. E-mail: kamatharshali@yahoo.com

Manuscript received: 13.12.16; Revision accepted: 18.05.17

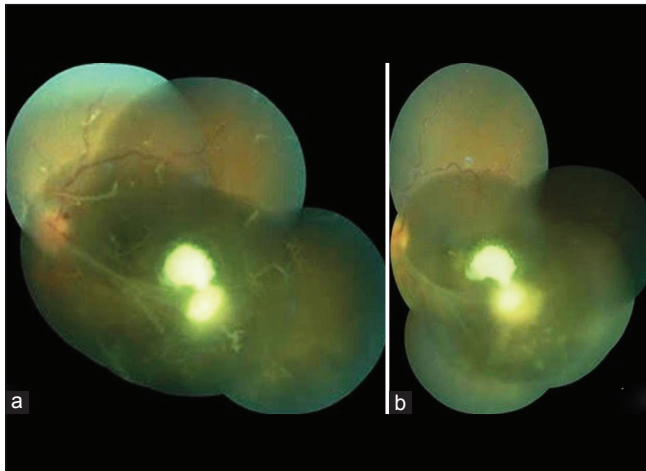
This is an open access article distributed under the terms of the Creative Commons Attribution-NonCommercial-ShareAlike 3.0 License, which allows others to remix, tweak, and build upon the work non-commercially, as long as the author is credited and the new creations are licensed under the identical terms.

**For reprints contact:** reprints@medknow.com

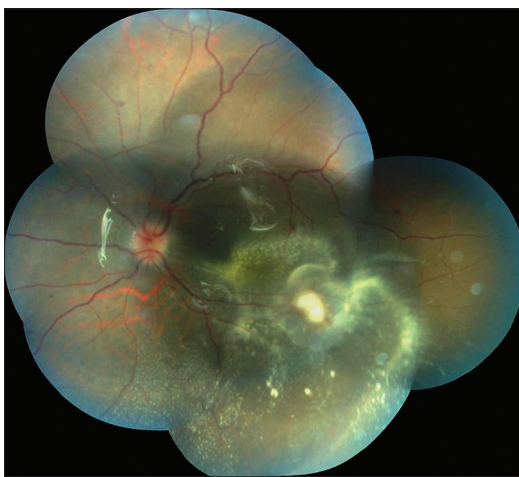
**Cite this article as:** Yadav HM, Thomas B, Thampy C, Panaknti TK. Management of a case of *Candida albicans* endogenous endophthalmitis with intravitreal caspofungin. Indian J Ophthalmol 2017;65:529-31.



**Figure 1:** Fundus examination at initial visit showed preretinal exudates with chorioretinitis



**Figure 2:** (a) Preretinal exudates are noted before commencing intravitreal caspofungin therapy; (b) improvement in the clinical picture with reduction in the size of active lesion after the injection



**Figure 3:** Fundus picture shows silicone oil filled globe with resolution of activity and subretinal remnant exudates

patients with candidemia.<sup>[2-4]</sup> Patients with candidemia are advised at least one dilated retinal examination.<sup>[5]</sup> Systemic

fluconazole with good ocular penetration is the drug of choice in the management of such cases.<sup>[4]</sup> Our patient is a known case of ALL. *C. albicans* was detected on blood culture but the organism was resistant to fluconazole. Amphotericin B has been the most frequently used drug. However, it carries the risk of nephrotoxicity when given IV for prolonged periods as noted in our case.<sup>[2]</sup> Similarly, it also carries a risk of retinal necrosis when given intravitreally.<sup>[4]</sup> Caspofungin is an echinocandin antifungal drug which inhibits  $\beta$ -D-glucan synthase an enzyme needed for fungal cell wall synthesis.<sup>[1,2]</sup> Caspofungin exhibits potent antifungal activity against *Candida* and aspergillus species.<sup>[6]</sup> It has been known to act synergistically with azoles and polyenes.<sup>[1]</sup> It is efficacious even against pathogens resistant to azoles and amphotericin B. Our patient had resistance to azoles and showed response to IV caspofungin. It undergoes nonenzymatic degradation and needs no dose adjustment for renal insufficiency.<sup>[5]</sup> Systemic caspofungin therefore does not carry the risk of renal impairment which may be noted with long-term administration of amphotericin B. However, due to high molecular weight and high level of protein binding it has minimal ocular penetration after IV administration.<sup>[5,6]</sup> When tested in rabbit eyes, intravitreal caspofungin injection was not associated with any signs of toxicity either histologically or on electroretinogram.<sup>[6]</sup> We injected intravitreal caspofungin at the lowest dose tested in rabbit eyes (50  $\mu$ g/0.1 ml). The clinical improvement noted suggests that intravitreal caspofungin did benefit the patient. While reports have established the efficacy of systemically administered caspofungin, a PubMed search has not revealed the usage of the drug intravitreally in *Candida* endophthalmitis. The control of infection with the usage of intravitreal caspofungin augmented by intravitreal amphotericin B and systemic antifungals suggests an encouraging role for the drug. Silicone oil also might have helped in the ultimate recovery of the patient. However, the efficacy of caspofungin as a standalone mode of treatment needs to be established. Moreover, the cost of the medicine precludes its usage as a first line therapy. Our case is anecdotal in nature and is limited by a short duration of follow-up. More number of cases with longer duration of follow up are needed to fill in the lacunae to our understanding of caspofungin and its clinical application as an intravitreal drug.

#### Financial support and sponsorship

Nil.

#### Conflicts of interest

There are no conflicts of interest.

#### References

1. Breit SM, Hariprasad SM, Mieler WF, Shah GK, Mills MD, Grand MG. Management of endogenous fungal endophthalmitis with voriconazole and caspofungin. *Am J Ophthalmol* 2005;139:135-40.
2. Khan FA, Slain D, Khakoo RA. *Candida* endophthalmitis: Focus on current and future antifungal treatment options. *Pharmacotherapy* 2007;27:1711-21.
3. Ness T, Pelz K, Hansen LL. Endogenous endophthalmitis: Microorganisms, disposition and prognosis. *Acta Ophthalmol Scand* 2007;85:852-6.

- 
4. Sallam A, Lynn W, McCluskey P, Lightman S. Endogenous *Candida* endophthalmitis. *Expert Rev Anti Infect Ther* 2006;4:675-85.
  5. Pappas PG, Kauffman CA, Andes D, Benjamin DK Jr., Calandra TF, Edwards JE Jr., *et al.* Clinical practice guidelines for the management of candidiasis: 2009 update by the Infectious Diseases Society of America. *Clin Infect Dis* 2009;48:503-35.
  6. Shen YC, Liang CY, Wang CY, Lin KH, Hsu MY, Yuen HL, *et al.* Pharmacokinetics and safety of intravitreal caspofungin. *Antimicrob Agents Chemother* 2014;58:7234-9.
-