

A Rare Case of Xanthomatous Meningioma

Sultan Deniz Altindag, Fulya Cakalagaoglu¹, Gokay Karaca², Nurullah Yuceer³

Department of Pathology, Nevsehir State Hospital, Nevsehir, ¹Department of Pathology, Izmir Katip Celebi University Ataturk Research and Training Hospital, ²Department of Neurosurgery, Izmir Katip Celebi University Ataturk Research and Training Hospital, Izmir, ³Department of Radiology, Samandag State Hospital, Hatay, Turkey

Abstract

Xanthomatous meningioma is an extremely rare subtype of metaplastic meningiomas with few cases reported in the literature. Histopathologically, it is composed of oval-shaped cells that have central nuclei and cytoplasm with lipid-filled vacuoles, resembling macrophages. Here, the authors present a case of xanthomatous meningioma and discuss the hypotheses related to its origin and the differential diagnosis. A 40-year-old woman presented with an increased headache complaint over the past month. A computed tomography scan revealed a heterogeneous mass on the right parietal lobe, following which a right craniotomy was done. Microscopic examination showed neoplastic meningothelial cells with whorl formation and areas of xanthomatous changes. Both meningothelial and xanthomatous cells were positive with vimentin, progesterone, and epithelial membrane antigen. CD68 and lysozyme were expressed only in the xanthomatous component, and there was no expression with periodic acid-Schiff (PAS) stain and PAS–diastase. As the diagnostic criteria of atypical meningioma were not observed, a diagnosis of xanthomatous meningioma, WHO grade I, was made. Owing to the characteristic xanthomatous changes, its differential diagnosis includes grade II clear cell meningioma, Rosai–Dorfman disease, and hemangioblastoma. To avoid misidentifying these cells as macrophages, a high degree of awareness of this unique subtype of meningioma is required.

Keywords: Histogenesis, lipid-filled, Meningioma, meningeal neoplasms, metaplastic, xanthomatous

Address for correspondence: Dr. Sultan Deniz Altindag, Department of Pathology, Nevsehir State Hospital, 15 Temmuz Mahallesi, 148. Sokak No: 1 Merkez, Nevsehir, Turkey.

E-mail: altindagdeniz@hotmail.com

Submitted: 18-Sep-2020 **Revised:** 11-Feb-2021 **Accepted:** 01-Dec-2021 **Published:** 12-Jan-2022

INTRODUCTION

Meningiomas are among the most common tumors of the central nervous system.^[1] They originate from arachnoid cap cells and can present a variety of epithelial and mesenchymal-like characteristics.^[2] Metaplastic meningioma is a variant of meningioma with focal or diffuse mesenchymal components including osseous, cartilaginous, lipomatous, myxoid, and xanthomatous tissue, according to the World Health Organization (WHO) Classification of Tumors of the Central Nervous

System.^[2] However, it is not a true metaplasia itself but rather contains cytoplasmic fat accumulation, vacuolization, or other changes in meningothelial cells.^[1] Xanthomatous meningioma is an extremely rare subtype of metaplastic meningioma that is composed of oval-shaped cells that have central nuclei and cytoplasm with lipid-filled vacuoles. To the best of the authors' knowledge, only 17 such cases have been reported in the literature,^[3-13] and thus there is a paucity of knowledge regarding the same. This case report is presented with the aim of discussing the hypotheses

This is an open access journal, and articles are distributed under the terms of the Creative Commons Attribution-NonCommercial-ShareAlike 4.0 License, which allows others to remix, tweak, and build upon the work non-commercially, as long as appropriate credit is given and the new creations are licensed under the identical terms.

For reprints contact: WKHLRPMedknow_reprints@wolterskluwer.com

How to cite this article: Altindag SD, Cakalagaoglu F, Karaca G, Yuceer N. A rare case of xanthomatous meningioma. Saudi J Med Sci 2022;10:63-6.

Access this article online	
Quick Response Code:	Website: www.sjmms.net
	DOI: 10.4103/sjmms.sjmms_705_20

related to origin of xanthomatous meningioma and the differential diagnosis of this extremely rare subtype.

CASE REPORT

A 40-year-old woman was admitted to our neurosurgical clinic due to increasing headache complaints over the past month. A computed tomography scan revealed a heterogeneous mass on the right parietal lobe [Figure 1a and b]. After obtaining informed consent, a right craniotomy was done with a preliminary diagnosis of space-occupying lesion, and an intraoperative consultation was performed. The frozen material was in the volume of 1 cc, and after the frozen procedure was completed, a diagnosis of meningeal tumor was made. The remaining gross material was described as 7 × 6 × 6 cm, irregularly shaped with soft consistency, partially hemorrhagic appearance, and partly processed. On histopathological examination, neoplasm comprising monotonous cells with eosinophilic and transparent cytoplasm was observed under the light microscope. Whorl formation was observed occasionally. Mitotic count was 1–2 on 10 high-power fields. Round cells with foamy cytoplasm were suggestive of xanthomatous changes [Figure 2]. In addition, cholesterol clefts were seen in some areas.

In immunohistochemical analysis, both meningothelial and xanthomatous cells were positive with vimentin and progesterone and showed mild positivity with epithelial membrane antigen (EMA). CD68 and lysozyme were expressed only in the xanthomatous component [Figure 3a-d], and there was no expression with periodic acid-Schiff (PAS) stain and PAS–diastase. In addition, the Ki-67 index was <5%. The diagnostic criteria of atypical meningioma were not observed, such as necrosis, brain invasion, macronucleoli, small cell formation, high nucleus/cytoplasm ratio, patternless, or sheet-like growth. Mitotic activity was very low. Based on these findings, a diagnosis of xanthomatous meningioma, WHO grade I, was made. The patient did not have any postoperative complications in the 4 years of follow-up at the time of reporting this case.

DISCUSSION

Meningiomas are slow-growing neoplasms that are composed of meningothelial cells of the arachnoid layer.^[2] They are classified into three-tiered grading according to the WHO: grades I, II, and III. Most meningiomas have benign histopathology and thus correspond to grade I. Grades II and III meningiomas are associated with worse clinical outcomes. Xanthomatous meningioma, which

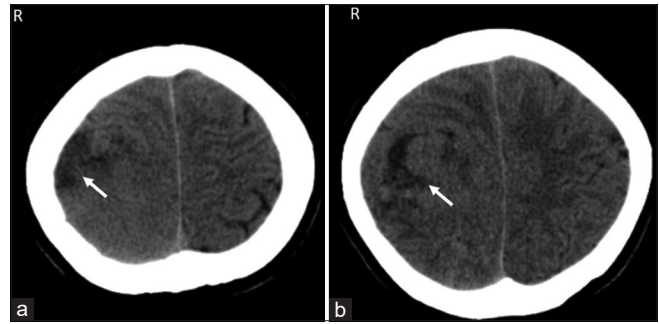


Figure 1: (a and b) Axial head computed tomography scan revealing heterogeneous mass starting from the right parietal region and extending toward the midline, brain parenchyma has been pushed, and the mass causes compression in the lateral ventricle

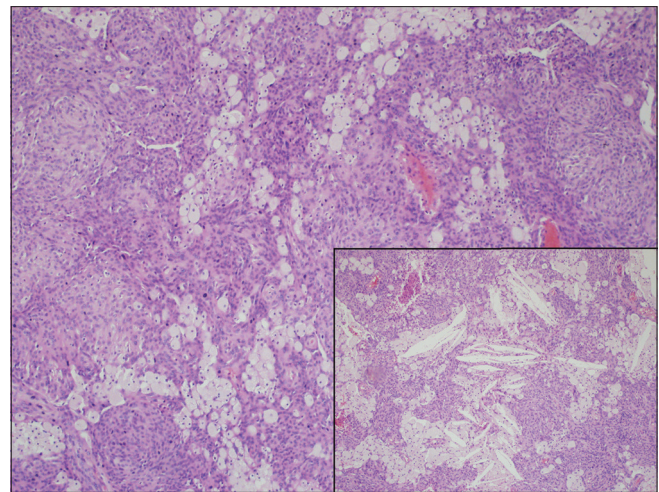


Figure 2: Meningothelial tumor cells with xanthomatous changes (H and E, ×100), inset: Cholesterol clefts with meningothelial and xanthomatous cells (H and E, ×100)

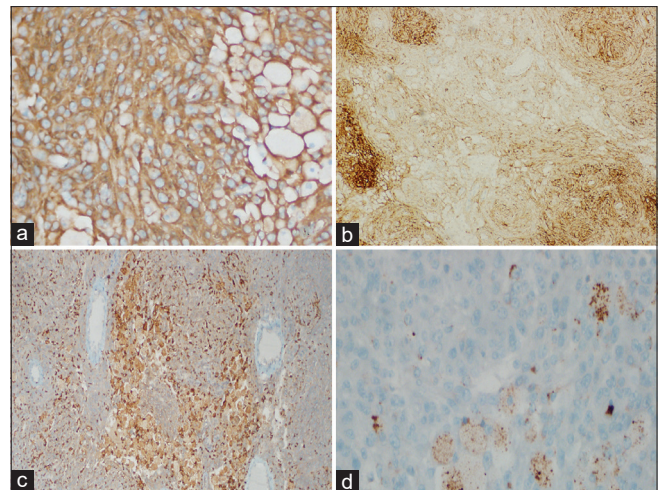


Figure 3: Immunohistochemical features: (a) Vimentin (×200) and (b) epithelial membrane antigen (×100) were expressed both meningothelial and xanthomatous components. (c) CD68 (×100) and (d) lysozyme (×400) were expressed in the xanthomatous component

is a subtype of metaplastic meningioma, is classified as grade I. It was described by Kepes in 1994,^[3] and to the

best of the authors' knowledge, only 17 cases have been recorded in the literature.^[3-13] The clinicopathological comparison of these cases and the present case was made in Table 1. Although xanthomatous meningioma is considered as grade I, Taraszewska *et al.*^[14] reported three atypical meningiomas and two anaplastic meningiomas with xanthomatous changes. In our case, the diagnostic criteria of atypical meningioma are absent and graded as WHO grade I meningioma. In another case, Ijiri *et al.*^[5] reported xanthomatous meningioma in a 10-year-old child with a history of radiotherapy for ependymoma. There was no reported history of radiotherapy in any of the other cases in the literature, including our case.

The most important finding that helps in diagnosis is xanthomatous cells. While its appearance is similar to blood-borne macrophages, xanthomatous cells were identified as meningeothelial by ultrastructural characteristics of complex plasmalemmal interdigitations bound by desmosomes and hemidesmosome-like intercellular junctions on electron microscopic investigations.^[3,5,6,14] Macrophages are not known to display complex plasmalemmal interdigitations or connect through desmosomes and hemidesmosomes to neighboring cells.^[3] Immunohistochemical staining is also helpful in diagnosis. Xanthomatous cells are immunohistochemically positive with EMA and vimentin. This indicates that it is of meningeothelial origin, also given its ultrastructural features.

In our case, CD68 and lysozyme, which are histiocytic markers, were also expressed. This expression was also seen in several cases in the literature and made it open to interpretation about the origin of xanthomatous

cells.^[3,5,7,8,11-13] When resolving the mechanism of xanthomatous cells in meningioma, the positivity of histiocytic markers does not always mean histiocytic differentiation. CD68 positivity may indicate metabolic abnormality associated with histogenesis in xanthomatous meningioma, besides it may reflect the presence of abundant lysosomes in the cytoplasm of the xanthomatous cells.^[7,8,12] Liu *et al.*^[15] could not clarify whether histiocytic infiltration is neoplastic or inflammatory in their case; therefore, they proposed the term "histiocytic meningioma." They argued that it may classify separately because not all histiocytes in this tumor have the same biological features as meningeothelial cells. For confirming this, electron microscopy is necessary; however, no electron microscopy was done in our case. Xanthomatous cells have also been reported to be positively stained with adipophilin.^[8,11] Adipophilin demonstrates cells containing lipid droplets.^[16] Ishida *et al.*^[8] observed adipophilin positivity in both xanthomatous and conventional areas, while Ersoz *et al.*^[11] only observed it in xanthomatous areas.

Xanthomatous changes manifest focally or diffusely and occur alone or in combination with other mesenchymal components.^[2] Roncaroli *et al.*, in their study regarding lipomatous meningiomas, reported 6 cases of xanthomatous cells admixed with adipocyte-like cells.^[6] As transitions between xanthomatous and lipomatous areas were found in some cases, the authors proposed the term "lipidized meningioma" for these lipid-containing tumors, both xanthic and lipoma-like. Besides having been observed together, lipomatous meningioma was included in the differential diagnosis of xanthomatous meningioma. Lipomatous meningioma is composed of meningeothelial

Table 1: Clinicopathological comparison of xanthomatous meningioma cases

Case number	Age (Years)	Gender	Location	Immunohistochemistry findings	Reference number
1	24	Male	Right parietal	CD68 (+), vimentin (+)	[3]
2	2	Female	Posterior pyramid	EMA (+)	[4]
3	10	Male	Right frontal	CD68 (+), HAM56 (+), vimentin (+)	[5]
4	58	Female	Right frontal	EMA (+), Ki-67 (<5%)	[6]
5	27	Female	Right petrous bone	EMA (+), S100 (-), Ki-67 (<5%)	[6]
6	49	Female	Left parietal	EMA (+), S100 (-), Ki-67 (<5%)	[6]
7	59	Female	Right frontal	EMA (+), S100 (-), Ki-67 (<5%)	[6]
8	70	Female	Left sphenoid, small wing	EMA (+), S100 (-), Ki-67 (<5%)	[6]
9	79	Male	Left occipital	EMA (+), S100 (-), Ki-67 (<5%)	[6]
10	61	Female	Right occipital to parietal	EMA (+) CD68 (+) vimentin (+) lysozyme (+) Ki-67 (2.2%)	[7]
11	76	Male	Left parasagittal to frontal	EMA (+) CD68 (+) vimentin (+) lysozyme (+) adipophilin (+) Ki-67 (2.1%)	[8]
12	22	Male	Sinus region	EMA (+), vimentin (+), GFAP (-), Ki-67 (1%)	[9]
13	68	Male	Right frontal	EMA (+), vimentin (+), GFAP (±), Ki-67 (1%)	[9]
14	24	Female	Tempora-parieto-occipital region	EMA (+), Ki-67 (3.2%)	[10]
15	32	Male	Right frontal to parietal	EMA (+), CD68 (+) adipophilin (+) (xanthomatous area), Ki-67 (3%)	[11]
16	61	Male	Right parietal	EMA (+), vimentin (+), CD68 (+), GFAP (-), Ki-67 (1%)	[12]
17	83	Female	Left fronto-temporal region	EMA (+), PR (+), Vimentin (+), S-100 (+), CD68 (+), CD11c (+), p53 (weak+), CK (-), CD34 (-), Ki-67 (< 1%)	[13]
18.	40	Female	Right parietal	EMA (+), CD68 (+), vimentin (+), PR (+), lysozyme (+) Ki-67 (<5%)	Present case

EMA – Epithelial membrane antigen; PR – Progesterone; GFAP – Glial fibrillary acidic protein; PR – Progesterone receptor; CK – Cytokeratin

neoplastic cells with adipocyte-like cells.^[13] These adipocyte-like cells contain large round, eccentrically located nuclei with large lipid vacuoles resembling mature adipocytes, in contrast to xanthomatous cells with central nuclei resembling histiocytes. In addition, these adipocyte-like cells have been reported to be stained with S100 positively.^[17] As no lipoblast-like or adipocyte-like cells were observed in our case, S100 staining was not performed.

Another differential diagnosis is microcystic meningioma, which is another variant of grade I meningiomas. Its intercellular spaces sometimes mimic fat accumulation but contain edematous clear fluid collections surrounded by “cobweb-like” meningotheial neoplastic cells.^[1] Moreover, the neoplastic cells of microcystic meningiomas are EMA positive and CD68 negative. Clear cell meningioma, which has clear cytoplasm caused by glycogen accumulation, also resembles xanthomatous meningioma, but due to its prominent interstitial and perivascular hyalinization and PAS positivity, it is distinguishable. In our case, there was no interstitial and perivascular hyalinization and xanthomatous cells showed no PAS positivity.

In differential diagnosis, it should be distinguished from intracranial histiocytic disorders such as Rosai–Dorfman disease (RDD). RDD is composed of a mixed infiltrate that often includes plasma cells, histiocytes (positive for CD68 and S100 protein, negative for CD1a), and lymphocytes. Emperipolesis is present in most of the cases. With the presence of foamy stromal cells, hemangioblastoma also may be morphologically mistaken with xanthomatous meningioma. The foamy stromal cells commonly show degenerative nuclear atypia and express inhibin alpha and brachyury by immunohistochemistry.

CONCLUSION

This report presents a rare case of xanthomatous meningioma diagnosed based on its characteristic xanthomatous changes. As its differential diagnosis includes grade II clear cell meningioma, RDD, and hemangioblastoma, a high degree of awareness of this unique subtype of meningioma is required for making a correct diagnosis.

Declaration of patient consent

The authors certify that they have obtained all appropriate patient consent forms. In the form, the patient has given her consent for her images and other clinical information to be reported in the Journal. The patient understands that her name and initials will not be published and due efforts

will be made to conceal identity, but anonymity cannot be guaranteed.

Peer review

This article was peer-reviewed by two independent and anonymous reviewers.

Financial support and sponsorship

Nil.

Conflicts of interest

There are no conflicts of interest.

REFERENCES

- Perry A. Meningiomas. In: Perry A, Brat DJ, editors. Practical Surgical Neuropathology: A Diagnostic Approach. Netherlands: Elsevier; 2010. p. 185-218.
- Perry A, Louis DN, Budka H, Von Deimling A. Meningiomas. In: Louis DN, Ohgaki H, Wiestler OD, Cavenee WK, editors. WHO Classification of Tumours of the Central Nervous System. Revised 4th ed. Lyon: IARC; 2016. p. 231-46.
- Kepes JJ. Lipidized meningotheial tumor cells in “xanthomatous” meningioma express macrophage antigen. *J Neuropathol Exp Neurol* 1994;53:384-8.
- Germanò A, Galatioto S, La Rosa G, Caffo M, Cardia E. Xanthomatous posterior pyramid meningioma in a 2-year-old girl. *Childs Nerv Syst* 1997;13:406-11.
- Ijiri R, Tanaka Y, Hara M, Sekido K. Radiation-associated xanthomatous meningioma in a child. *Childs Nerv Syst* 2000;16:304-8.
- Roncaroli F, Scheithauer BW, Laeng RH, Cenacchi G, Abell-Aleff P, Moschopoulos M. Lipomatous meningioma: A clinicopathologic study of 18 cases with special reference to the issue of metaplasia. *Am J Surg Pathol* 2001;25:769-75.
- Ikota H, Nakazato Y. A case of metaplastic meningioma with extensive xanthomatous change. *Neuropathology* 2008;28:422-6.
- Ishida M, Fukami T, Nitta N, Iwai M, Yoshida K, Kagotani A, et al. Xanthomatous meningioma: A case report with review of the literature. *Int J Clin Exp Pathol* 2013;6:2242-6.
- Tang H, Sun H, Chen H, Gong Y, Mao Y, Xie Q, et al. Clinicopathological analysis of metaplastic meningioma: Report of 15 cases in Huashan Hospital. *Chin J Cancer Res* 2013;25:112-8.
- Chougule M, Pawar V, Chivate SD, Jagtap SV. Xanthomatous meningioma – A rare case report. *Int J Health Sci Res* 2015;5:445-8.
- Ersoz S, Yilmaz ZS, Eyuboglu I, Yazar U. Xanthomatous meningioma: A case report. *Turk Neurosurg* 2019;29:141-4.
- Al-Diab JM, Almohammed HH, Al-Namil SA. Xanthomatous meningioma; a rare histological variant. *Med J Basrah Univ* 2018;36:66-70.
- Wong YP, Tan GC, Kumar R. Xanthomatous meningioma: A metaplastic or degenerative phenomenon? *Neuropathology* 2018;38:619-23.
- Taraszevska A, Matyja E, Bogucki J. Xanthomatous changes in atypical and anaplastic meningiomas. Light and electron microscopic investigations. *Folia Neuropathol* 2000;38:125-34.
- Liu L, Stone J, Hoffpauir JT, Xiong Z. Histiocytic meningioma: A distinctive subtype of meningioma? *Intractable Rare Dis Res* 2014;3:57-9.
- Heid HW, Moll R, Schwetlick I, Rackwitz HR, Keenan TW. Adipophilin is a specific marker of lipid accumulation in diverse cell types and diseases. *Cell Tissue Res* 1998;294:309-21.
- Gasparinho MG, Ferreira M, Lavrador JP, Livraghi S. Revisiting lipomatous meningioma: A case report and review of an unusual entity. *Int J Surg Pathol* 2015;23:399-403.