

Developing a novel meatal areolar tissue autograft for minimally invasive tympanoplasty

Yen-Chi Chen^a, Chii-Yuan Huang^{a,b}, Ying-Ju Kuo^{c,d}, Hsiu-Lien Cheng^e, Yen-Fu Cheng^{a,b,f,*}, Wen Huei Liao^{a,b,*}

^aDepartment of Otolaryngology-Head and Neck Surgery, Taipei Veterans General Hospital, Taipei, Taiwan, ROC; ^bDepartment of Otolaryngology-Head and Neck Surgery, School of Medicine, National Yang-Ming University, Taipei, Taiwan, ROC; ^cDepartment of Pathology, Taipei Veterans General Hospital, Taipei, Taiwan, ROC; ^dSchool of Medicine, National Yang-Ming University, Taipei, Taiwan, ROC; ^eDepartment of Biomedical Engineering, National Yang-Ming University, Taipei, Taiwan, ROC; ^fDepartment of Medical Research, Taipei Veterans General Hospital, Taipei, Taiwan, ROC

Abstract

Background: We developed an easy and minimally invasive method of transmeatal tympanoplasty using meatal areolar tissue (MAT) grafts to achieve less postoperative morbidity or surgical scarring. We compared the functional and anatomical results of the developed method with conventional endaural tympanoplasty with a temporalis fascia (TF) graft.

Methods: In this retrospective cohort study, 58 patients (59 ears) with simple chronic otitis media who underwent type I tympanoplasty between January 2016 and August 2018 were included. All surgeries were performed in a tertiary referral hospital and by the same senior surgeon. The tympanic membrane (TM) was repaired with either a TF or an MAT graft.

Results: Healing of the perforated TM and improvement in a hearing test by air-bone gap (ABG) closure were identified. Postoperative wound conditions were also evaluated. Twenty-eight ears were grafted with MAT, and 31 ears were grafted with TF. Graft success was observed in 26 patients (92.9%) in the MAT group and 28 patients (90.3%) in the TF group. Both groups showed functional improvement compared with the preoperative measurements. The postoperative pure tone audiogram ($p = 0.737$), ABG closure ($p = 0.547$), and graft success rate ($p = 0.726$) were not significantly different between the two groups. Neither wound dehiscence nor keloid formation was observed in our patients.

Conclusion: Both MAT and TF grafts revealed satisfactory surgical and functional results. Compared with the conventional endaural approach with TF grafts, the new transmeatal approach method with an MAT graft causes relatively minimal trauma and results in better wound cosmetics. This method represents an easy, minimally invasive surgery and shows comparatively good results.

Keywords: Endaural approach; Meatal areolar tissue graft; Minimally invasive surgery; Temporalis fascia; Tympanoplasty

1. INTRODUCTION

Chronic otitis media is defined as a recurrent infection of the middle ear with the presence of a tympanic membrane (TM) perforation. Tympanoplasty was introduced by Wullstein in 1952 and successfully performed with remarkable outcomes.¹ In addition to repair of the TM, the restoration of middle ear ventilation has also been reported.² Temporalis fascia (TF), areolar tissue, perichondrium, or cartilage are the most commonly used autograft materials for perforation repair.^{3,4} Several types of incisions are used to access the middle ear and mastoid cavity for tympanoplasty.⁵ According to the surgeon's preference, a posterior auricular incision and an endaural incision are two

main methods used in conventional microscopic ear surgery, while a transmeatal (transcanal) incision is widely used in endoscopic ear surgery.⁶

The endaural approach is preferred by many surgeons when tympanoplasty with little atticotomy or meatoplasty is decided.⁷ In addition, it causes less scarring and discomfort than the postauricular approach.⁸ However, similar to the postauricular approach, some endaural incisions may result in visible postoperative surgical scars and significant pain to the patients, occurring in 15% and 2% of cases, respectively, according to one study.⁸ Moreover, severe morbidities, such as keloid formation, perichondritis, and even postoperative infection, could occur after surgery regardless of the surgery type.^{9,10}

In this study, we developed a transmeatal approach with meatal areolar tissue (MAT) reconstruction, modified from the canonical endaural tympanoplasty, to avoid external skin wounds for better cosmetics and reduced morbidity. The phrase "transmeatal approach with meatal areolar tissue reconstruction" was coined, and the procedure was applied to patients with TM perforation. Our goal was to compare the functional and anatomical results in patients treated with either the conventional endaural approach with a TF graft or the designed transmeatal approach with an MAT graft to reconstruct TM perforations. The areolar tissue from the external auditory meatus can be easily harvested and grafted to the perforated eardrum. There was no need for an extended or additional excision

*Address correspondence: Dr. Yen-Fu Cheng and Dr. Wen Huei Liao, Department of Otolaryngology-Head and Neck Surgery, Taipei Veterans General Hospital, 201, Section 2, Shi-Pai Road, Taipei 112, Taiwan, ROC. E-mail address: yfcheng2@vghtpe.gov.com (Y.-F. Cheng); whliao@vghtpe.gov.tw (W.H. Liao).

Conflicts of interest: The authors declare that they have no conflicts of interest related to the subject matter or materials discussed in this article.

Journal of Chinese Medical Association. (2020) 83: 956-961.

Received February 12, 2020; accepted April 8, 2020.

doi: 10.1097/JCMA.0000000000000392.

Copyright © 2020, the Chinese Medical Association. This is an open access article under the CC BY-NC-ND license (<http://creativecommons.org/licenses/by-nc-nd/4.0/>)

to create a pocket under the temporalis or postauricular area for the autograft harvest. The surgical results were as good as those of the conventional endaural approach with a TF graft, and no external surgical scar was developed. In addition, there was no need for a mastoid bandage for these surgeries. We propose this innovative and alternative method for tympanoplasty.

2. METHODS

2.1. Participants

A retrospective cohort study was carried out that included patients with chronic otitis media who underwent tympanoplasty. A total of 58 participants with 59 diseased ears were enrolled in this study from January 2016 to July 2018. Patients were divided into two groups according to the type of surgery: repair with TF or MAT. TF-based repair was performed from January 2016 to January 2017, and MAT-based repair was performed from February 2017 to July 2018. The characteristics of the patient profiles, including age, sex, size of perforation, confounding factors (diabetes mellitus or hypertension), and side of the diseased ear were recorded.^{1,11-13} Detailed operative data were collected, including the method of operation (repaired with TF or MAT) and the duration of the surgery. Patients diagnosed with cholesteatoma or ossicle chain dislocation or undergoing revision surgery were excluded; only patients with tympanic perforation were included. All of the tympanic perforations were central perforations, and the procedures were performed by the same surgeon (W.H.L.), a senior faculty member at the tertiary referral hospital. The superfluous specimens of MAT and TF were reviewed after hematoxylin and eosin staining by a pathologist.

2.2. Ethical considerations

The trial was approved by the Institutional Review Board of Taipei Veterans General Hospital (2019-06-004AC).

2.3. Surgical techniques

1. Xylocaine plus epinephrine (1:100,000) is locally injected into the external auricle canal for vasoconstriction and hydrodissection.
2. Then, a small longitudinal or parallel incision is made along the external ear canal at approximately the 12 o'clock position (Fig. 1A, B).
3. Another incision is made along the posterior canal, connecting the first incision to make a meatal flap in the shape of a rectangle or with an obtuse angle (over 90°) (Fig. 1C, D).
4. The MAT is harvested by careful separation of the dermis and hypodermis (Fig. 1E, F).
5. Under microscopy, the edge of the perforation in the eardrum is denuded; the tympanomeatal flap is then elevated, and the middle ear is clearly visualized.
6. Fibrotic bands or granulation tissue in the middle ear are then removed. Further canaloplasty is performed if needed.
7. The graft is then placed medially onto the perforation. The residual skin of the tympanomeatal flap is replaced at the end of the procedure.
8. A silicon sheet is placed on the eardrum and external auricle canal to facilitate the growth of the graft.
9. The intrameatal incision wound is sutured with 2-3 stitches, and then the canal is packed with antibiotic-soaked gelfoam. No mastoid bandages are applied.

2.4. Outcome measures

All patients were regularly followed once a week for 1-month postoperatively until removal of the external ear packing.

Pure tone audiometry and endoscopic photography were performed preoperatively and at least 3 months postoperatively. The air conduction (AC) and bone conduction (BC) hearing thresholds and the air-bone gap (ABG) at 0.5, 1, 2, and 3 kHz were recorded and documented in accordance with the guidelines suggested by the American Academy of Otolaryngology in 1995. The size of the TM perforation is represented as a percentage of the entire area determined by endoscopic imaging. The primary outcome measure was the graft success rate. Success was defined as full, intact healing of the graft without perforation for at least 3 months postoperatively. The secondary outcomes were the AC hearing threshold, the BC hearing threshold, and the ABG.

2.5. Statistical analysis

Data were entered into Excel and analyzed using SPSS (version 21 for Windows, IBM Company, Chicago, IL). Categorical confounding variables were compared between the groups by a chi-squared test. The success rate and the incidence of postoperative ear discharge were compared by Fisher's exact test. Continuous variables were compared by analysis of variance. Efficacy (AC, BC, and ABG) was compared between the groups by the generalized estimating equation approach.¹⁴ Outcomes were considered significantly different if $p < 0.05$.

3. RESULTS

Fifty-eight patients met their criteria, and 59 ears were enrolled in the study. The mean patient ages were 63.2 and 65.8 in the MAT and TF groups, respectively. The mean follow-up duration was 4.6 months. The demographic data and clinical findings of each group (TF, $n = 31$; MAT, $n = 28$) are presented in Table 1.

The preoperative demographic data and hearing thresholds were compared, and there were no differences between the two groups. The age and perforation size were considered continuous variables and are presented in Table 2. The rates of successful grafting and perforation closure were 92.9% and 90.3% in the MAT and TF groups, respectively, without a significant difference ($p = 0.726$).

The functional outcomes in the TF, MAT, and the combined TF-MAT groups are presented in Table 3. The mean preoperative AC hearing threshold in the TF and MAT groups was 62.6 and 59.8 dB, respectively, and the preoperative ABG in the TF and MAT groups was 20.6 and 20.0 dB, respectively. The ABG improved by 3.4 and 5.4 dB postoperatively. Compared with the preoperative values, the AC hearing threshold and the ABG improved in both the TF and MAT groups after the surgery. However, there was no significant difference in the AC hearing threshold improvement or the ABG closure between the two groups ($p = 0.737, 0.547$). No postoperative complications, such as keloid formation or wound dehiscence, were reported.

In the histological review, the MAT graft revealed a rich collagen fiber and glandular structure. Similar to MAT, the TF graft also contained collagen fibers (Fig. 2). Linear, dense collagen fibers were observed throughout the TF samples. Collagen fiber rearrangement and fibroblast ingrowth may contribute to the strength and texture of the reconstructed fascia. The postoperative images revealed good healing with neovascularization. In addition, the external wound was barely visible 3 months after the operation (Fig. 3), and there was no wound dehiscence or scar formation in this series. There was no need for postoperative mastoid bandages due to the minimal surgical incision. There were also no reported cases of periauricular hematoma or bleeding.

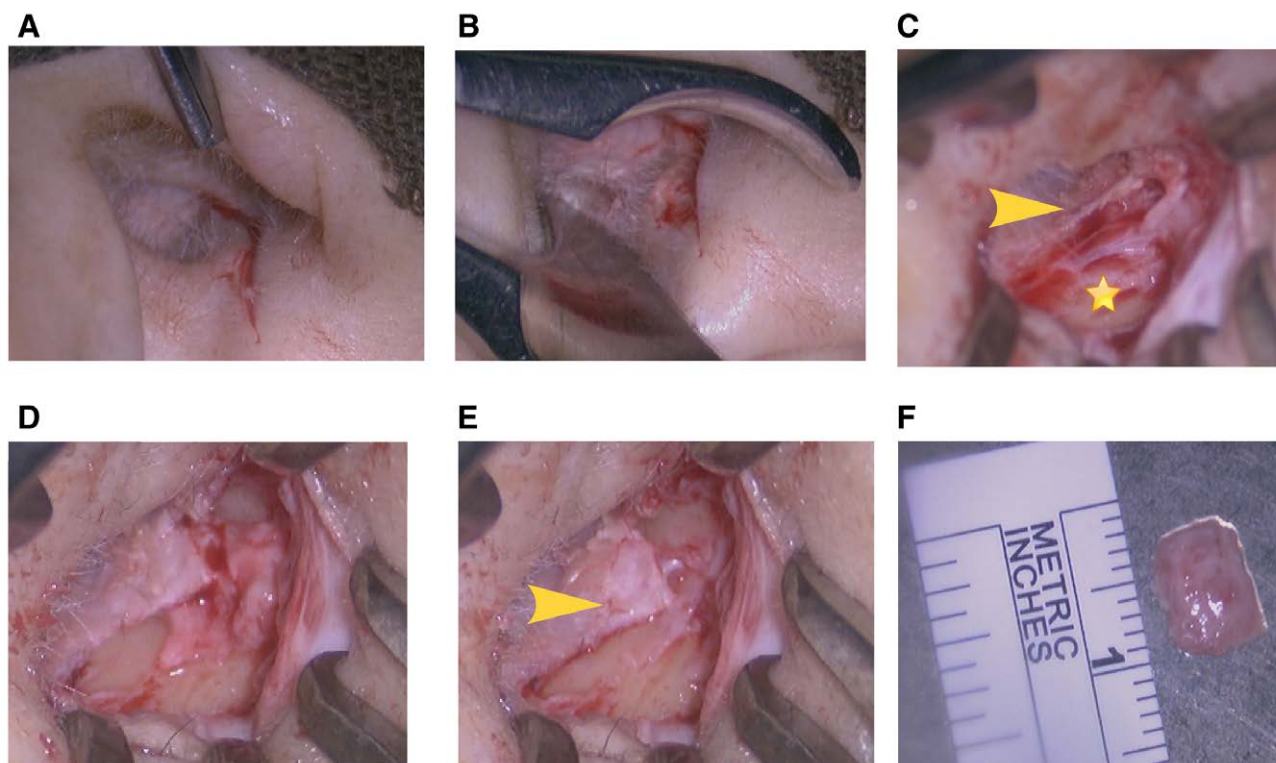


Fig. 1. Harvesting the meatal areolar tissue (MAT) graft during the surgery. (A) A linear incision is made over the inner surface of the external ear canal. (B) The underlying soft tissue beneath the skin. (C) The areolar tissue can be fully visualized using a mastoid retractor. (D) The MAT graft is separated from the adjacent tissue. (E) The remaining meatal skin after harvesting the areolar tissue graft. (F) The graft is trimmed to a customized size and thickness. The yellow arrow indicates the meatal skin, and the star indicates the intrameatal graft.

Table 1

Comparison of categorical confounding variables between the MAT and TF groups

Variables	No. (%)	No. (%)	χ^2 value	<i>p</i>
	MAT (n = 28)	TF (n = 31)		
Sex (male)	13 (46.4)	16 (51.6)	0.019	0.891
DM (yes)	5 (17.9)	5 (16.1)	0.000	1.000
HTN (yes)	8 (28.6)	13 (41.9)	0.637	0.425
Side (right)	13 (46.4)	12 (38.7)	0.112	0.737

DM = diabetes mellitus; HTN = hypertension; MAT = meatal areolar tissue; TF = temporalis fascia.

Table 2

Comparison of continuous variable between MAT and TF Groups

Variables	Mean \pm SD	95% CI (lower~ upper)
Age (y)		
MAT group	63.2 \pm 16.0	57.0~69.4
TF group	65.8 \pm 17.8	59.3~72.4
TM perforation (%)		
MF group	37.0 \pm 20.0	29.2~44.7
TF group	40.6 \pm 27.2	33.9~53.8

MAT = meatal areolar tissue; MF = meatal fascia; TF = temporalis fascia; TM = tympanic membrane.

4. DISCUSSION

The concept of tympanoplasty using autografts was first introduced in the early 1960s.¹⁵ The advantages of grafting fascia include the presence of mucopolysaccharides and

Table 3

Comparison of intervention effects between the two groups

Variables	Coefficient	SE
AC (dB)		
Pre-op MAT	59.8	
Pre-op (TF-MAT)	2.8	6.7
MAT (post-op/pre-op)	-6.7	6.6
Difference in slopes between two groups	3.2	9.5
BC (dB)		
Pre-op MAT	39.8	
Pre-op (TF-MAT)	2.2	5.4
MAT (post-op/pre-op)	-1.3	5.3
Difference in slopes between two groups	0.5	7.6
ABG (dB)		
Pre-op MAT	20.0	
Pre-op (TF-MAT)	0.6	3.1
MAT (post-op/pre-op)	-5.3	3.0
Difference in slopes between two groups	2.7	4.4

ABG = air-bone gap; AC = air conduction; BC = bone conduction; MAT = meatal areolar tissue; TF = temporalis fascia.

collagen, which provide strength to the fascia and can attract fibroblasts by chemotaxis.¹⁶ To date, TF has remained the most popular graft material in tympanoplasty. However, the conventional endaural or postauricular approach requires a relatively large incision to harvest the fascia. Several other graft materials have been studied, including TF muscle, perichondrium, dura mater, vein tissue, fat, and skin.¹⁵ Most studies have shown no significant differences between

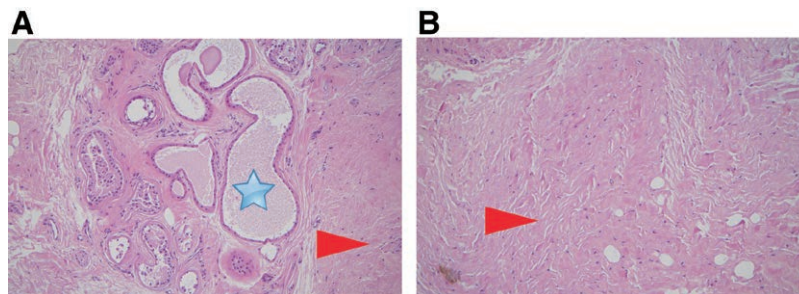


Fig. 2. Histomorphology of the meatal areolar tissue (MAT) (A) and temporalis fascia (TF) (B) grafts. Collagen fibers can be seen in both grafts, while glandular tissues are rich in MAT. The star indicates ceruminous glands, and the arrow indicates collagen fibers.

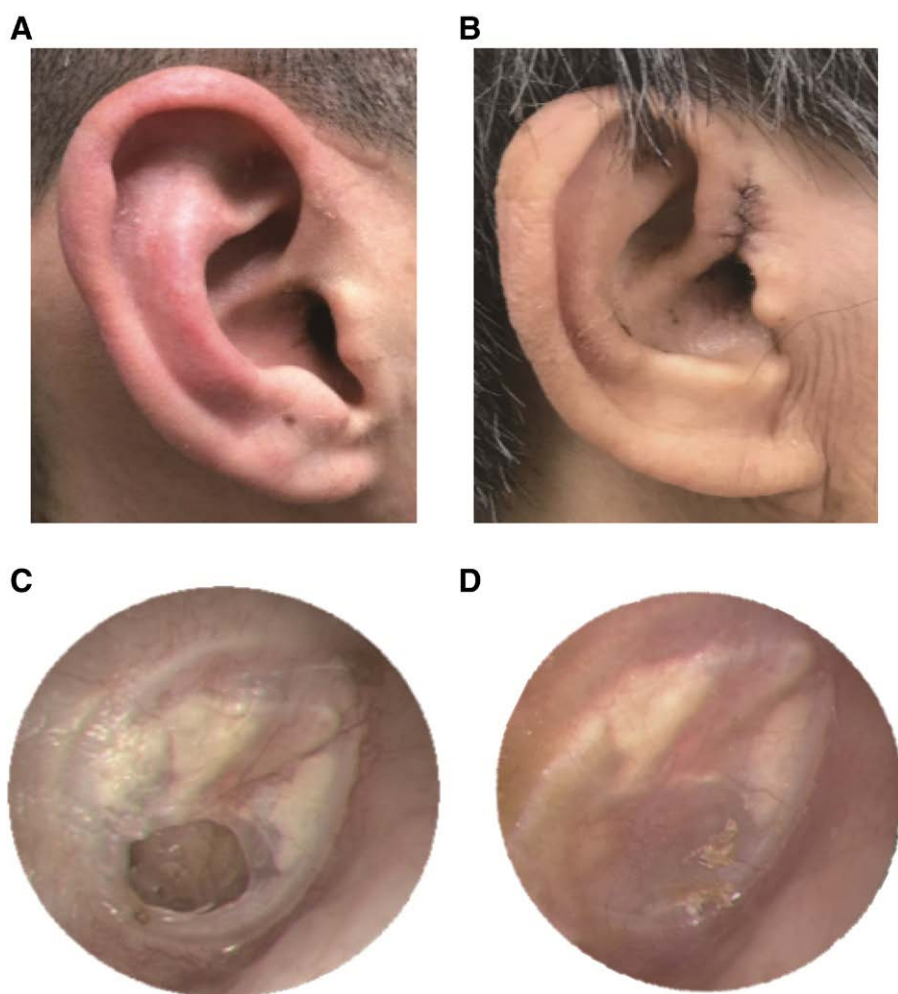


Fig. 3. Preoperative and postoperative pictures. (A) Two weeks after the surgery. There is no external skin wound. (B) Two weeks after the traditional surgery. Note the scar between the tragus and helix. (C) Endoscopic view before the surgery and (D) 3 months after the surgery. Note the neovascularization of the meatal areolar tissue (MAT) graft and the well-pneumatized middle ear.

fascia and cartilage in terms of hearing outcomes and success rates.¹⁷

The transmeatal approach for tympanoplasty was first described in 1930.¹⁸ This approach was found to be somewhat interchangeable with the transcanal approach in several articles.^{19,20} One of the advantages of the transmeatal approach is reduced injury to periauricular tissue and thus

fewer postoperative morbidities. Other advantages, such as a short operation time, less discomfort, and less chance of postoperative wound infection, have also been reported. However, large or anterior perforations are thought to be difficult to be performed by this method. Allograft and anterior tympanomeatal flap technique have been discussed to solve these problem.²⁰

To avoid making an external incision for graft harvesting when performing the conventional transmeatal approach, which still requires another incision for grafting, we sought to trim and use the areolar tissue beneath the meatal skin as the autograft material and test its efficacy in perforation repair. Although we used this graft material for the treatment of chronic otitis media with tympanic perforation, MAT grafts as large as $1.0 \times 1.0 \text{ cm}^2$ can be harvested, which may be used in most eardrum perforation cases with ease. MAT is generally extensible and can be placed by either the wet or dry method.²¹

The external auditory canal is covered by squamous epithelium with hair follicles and sebaceous glands. Histological analysis of the MAT used for the eardrum graft revealed that this tissue, which lies between the temporal bone and dermis of the external ear canal and is also called the hypodermis or superficial fascia, is full of collagen fibers and connective tissue. In our study, collagen fibers and fibroblasts were observed in both MAT and TF specimens, which is compatible with the results of a previous study.^{22,23} However, the glands were present only in the meatal fascia, while the TF showed more connective tissue.

There are some advantages of performing tympanoplasty using MAT. The first is the enlargement of the external meatus by the concurrent meatoplasty and graft harvesting. In this meatoplasty approach, compared with conventional surgical approaches, such as the endaural and postauricular approaches, the underlying soft tissue is separated from the cartilage or bony wall beneath, and the redundant soft tissue is abandoned or excised due to its fragmental size. Our method is inspired by the meatoplasty with tympanoplasty technique reported previously.²⁴ There is no need for another external skin excision for grafting. In addition, we obtain a smaller wound.

Second, the incisional wound shows a good cosmetic result, and there are no wound issues during the postoperative follow-up. Without a postoperative mastoid bandage, the patients do not complain of sensations of head tightness or wound pain.²⁵ There are also no reported cases of periauricular hematoma or bleeding.

Third, while the developed MAT showed good surgical and functional results, TF can be used for cases requiring revision or involving total eardrum perforations. According to several meta-analysis and case-control studies, 12%–18% of patients who undergo repair with autologous soft tissue still have a residual perforation and may need further surgery.^{26–29} In this case, either TF or the tragal perichondrium can be retrieved by extending the previous incision.³⁰

Furthermore, in elderly patients under treatment with antiplatelet or anticoagulant agents that cannot be withdrawn due to comorbidities, the developed MAT method can still be easily performed.³¹ Only minimal bleeding was observed when dissecting this avascular area and there was therefore no need for the use of compression bandages on the incision wound.²⁵

Finally, better visualization of the TM under a microscope can be achieved through our method. It has been reported that 80% and 83% of the TM can be completely visualized by microscopy and endoscopy, respectively, using the transcanal (transmeatal) method.³² The main cause of reduced visualization is a bulging of the external ear canal.^{5,32} In addition, the possibility of fully scrutinizing pathophysiological changes over the TM and middle ear cannot be overemphasized.³³ The transmeatal approach allows better visualization by debulking the heavy amount of subcutaneous tissue in the membranous canal and arranging the meatoplasty in suitable patients. Additionally, gelfoam compression and suture are used to ensure no changes in restenosis.

There are some limitations to this study. First, we only used this method for the treatment of chronic otitis media with relatively small perforations.¹¹ The feasibility of using this method for larger perforations or other middle ear conditions requires further investigation. Second, the follow-up duration for some

patients was relatively short, which might reflect the good surgical results in that the patients did not feel the need to return. Third, most of the patients were older in our study. Thus, these results may not be representative of the general population.³⁴ In conclusion, our results show that tympanoplasty with an MAT graft achieved a highly successful perforation closure rate with good hearing and cosmetic results. For chronic otitis media patients requiring simple tympanoplasty, the transmeatal approach with an MAT graft can be a good alternative treatment choice to the endaural approach with a TF graft.

ACKNOWLEDGMENTS

This study was supported by grants from Taipei Veterans General Hospital (V108C-145 and V108C-178). The authors acknowledge Shang-Liang Wu, PhD, for the statistical analyses.

REFERENCES

- Pinar E, Sadullahoglu K, Calli C, Oncel S. Evaluation of prognostic factors and middle ear risk index in tympanoplasty. *Otolaryngol Head Neck Surg* 2008;139:386–90.
- Merchant SN, Ravicz ME, Puria S, Voss SE, Whittemore KR Jr, Peake WT, et al. Analysis of middle ear mechanics and application to diseased and reconstructed ears. *Am J Otol* 1997;18:139–54.
- Perkins R. Human homograft otologic tissue transplantation buffered formaldehyde preparation. *Trans Am Acad Ophthalmol Otolaryngol* 1970;74:278–82.
- Awad OG, Hamid KA. Endoscopic type 1 tympanoplasty in pediatric patients using tragal cartilage. *JAMA Otolaryngol Head Neck Surg* 2015;141:532–8.
- Ayache S, Beltran M, Guevara N. Endoscopic classification of the external auditory canal for transcanal endoscopic ear surgery. *Eur Ann Otorhinolaryngol Head Neck Dis* 2019;136:247–50.
- Sun WH, Kuo CL, Huang TC. Transcanal endoscopic ear surgery for congenital cholesteatoma: a preliminary report. *Arch Otolaryngol Head Neck Surg*. 2017;1:2.
- Farrior JB. Incisions in tympanoplasty: anatomic considerations and indications. *Laryngoscope* 1983;93:75–86.
- Inwood JL, Wallace HC, Clarke SE. Endaural or postaural incision for myringoplasty: does it make a difference to the patient? *Clin Otolaryngol Allied Sci* 2003;28:396–8.
- Bermueller C, Rettinger G, Keck T. Auricular keloids: treatment and results. *Eur Arch Otorhinolaryngol* 2010;267:575–80.
- Tseng CC, Shiao AS. Postoperative auricular perichondritis after an endaural approach tympanoplasty. *J Chin Med Assoc* 2006;69:423–7.
- Lee P, Kelly G, Mills RP. Myringoplasty: does the size of the perforation matter? *Clin Otolaryngol Allied Sci* 2002;27:331–4.
- Caylan R, Titiz A, Falcioni M, De Donato G, Russo A, Taibah A, et al. Myringoplasty in children: factors influencing surgical outcome. *Otolaryngol Head Neck Surg* 1998;118:709–13.
- Emir H, Ceylan K, Kizilkaya Z, Gocmen H, Uzunkulaoglu H, Samim E. Success is a matter of experience: type 1 tympanoplasty: influencing factors on type 1 tympanoplasty. *Eur Arch Otorhinolaryngol* 2007;264:595–9.
- Zeger SL, Liang KY. Longitudinal data analysis for discrete and continuous outcomes. *Biometrics* 1986;42:121–30.
- Nicholas BD, O'Reilly RC. Is cartilage preferable to fascia myringoplasty in children? *Laryngoscope* 2010;120:2136–7.
- Pohlman ME. The artificial ear drum. *Ann Otol Rhinol Laryngol* 1951;60:117–21.
- Mohamad SH, Khan I, Hussain SS. Is cartilage tympanoplasty more effective than fascia tympanoplasty? A systematic review. *Otol Neurotol* 2012;33:699–705.
- Lewis ML Jr. The transmeatal approach to middle ear and mastoid surgery in cholesteatoma. *Laryngoscope* 1967;77:550–8.
- Halim A, Borgstein J. Pediatric myringoplasty: postaural versus transmeatal approach. *Int J Pediatr Otorhinolaryngol* 2009;73:1580–3.
- de Savornin Lohman EAJ, Borgstein J. Transmeatal tympanoplasty of subtotal and anterior perforations: a single-institution experience including 94 patients. *Clin Otolaryngol* 2017;42:920–3.
- Alkan S, Baylançicek S, Sözen E, Başak T, Dadaş B. Effect of the use of dry (rigid) or wet (soft) temporal fascia graft on tympanoplasty. *J Otolaryngol Head Neck Surg* 2009;38:126–32.

22. Knutsson J, Bagger-Sjöbäck D, von Unge M. Collagen type distribution in the healthy human tympanic membrane. *Otol Neurotol* 2009;**30**:1225–9.
23. Trakimas DR, Ishai R, Ghanad I, Black NL, Kozin ED, Cheng JT, et al. Otopathologic evaluation of temporalis fascia grafts following successful tympanoplasty in humans. *Laryngoscope* 2018;**128**:E351–8.
24. Chen Y, Zhang T. Modified meatoplasty for external auditory canal stenosis with endoaural-conchal incision. *Otol Neurotol* 2015;**36**:1–3.
25. Khan I, Mohamad S, Ansari S, Iyer A. Are head bandages really required after middle-ear surgery? A systematic review. *J Laryngol Otol* 2015;**129**:740–3.
26. Jalali MM, Motasaddi M, Kouhi A, Dabiri S, Soleimani R. Comparison of cartilage with temporalis fascia tympanoplasty: a meta-analysis of comparative studies. *Laryngoscope* 2017;**127**:2139–48.
27. Lin YC, Wang WH, Weng HH, Lin YC. Predictors of surgical and hearing long-term results for inlay cartilage tympanoplasty. *Arch Otolaryngol Head Neck Surg* 2011;**137**:215–9.
28. Gersdorff M, Garin P, Decat M, Juantegui M. Myringoplasty: long-term results in adults and children. *Am J Otol* 1995;**16**:532–5.
29. Bhat NA, De R. Retrospective analysis of surgical outcome, symptom changes, and hearing improvement following myringoplasty. *J Otolaryngol* 2000;**29**:229–32.
30. Khan MM, Parab SR. Comparative study of sliced tragal cartilage and temporalis fascia in type I tympanoplasty. *J Laryngol Otol* 2015;**129**:16–22.
31. Bailey JH. Symposium: Contraindications to tympanoplasty. I. Absolute and relative contraindications. *Laryngoscope* 1976;**86**:67–69.
32. Harugop AS, Mudhol RS, Godhi RA. A comparative study of endoscope assisted myringoplasty and microscope assisted myringoplasty. *Indian J Otolaryngol Head Neck Surg* 2008;**60**:298–302.
33. Vartiainen E, Nuutinen J. Success and pitfalls in myringoplasty: follow-up study of 404 cases. *Am J Otol* 1993;**14**:301–5.
34. Gyo K, Yanagihara N, Saiki T, Hinohira Y. Chronic otitis media and tympanoplasty in aged patients. *Auris Nasus Larynx* 1990;**17**:141–8.