

Mixed Infection of *Mycobacterium abscessus subsp. abscessus* and *Mycobacterium tuberculosis* in the Lung

Sungmin Sohn, M.D.¹, Sungho Wang, M.D.¹, Hyejin Shi, M.D.¹,
Sungrock Park, M.D.¹, Sangki Lee, M.D.¹, Kyoung Taek Park, M.D.²

¹Division of Pulmonary, Allergy and Critical Care Medicine, Department of Internal Medicine, Kangdong Sacred Heart Hospital, Hallym University College of Medicine, ²Department of Thoracic and Cardiovascular Surgery, Inje University Busan Paik Hospital, Inje University College of Medicine

A mixed infection of *Mycobacterium abscessus subsp. abscessus* (Mab) and *Mycobacterium tuberculosis* (MTB) in the lung is an unusual clinical manifestation and has not yet been reported. A 61-year-old woman had been treated for Mab lung disease and concomitant pneumonia, and was diagnosed with pulmonary tuberculosis (PTB). Despite both anti-PTB and anti-Mab therapy, her entire left lung was destroyed and collapsed. She underwent left pneumonectomy and received medical therapy. We were able to successfully treat her mixed infection by pneumonectomy followed by inhaled amikacin therapy. To the best of our knowledge, thus far, this is the first description of a mixed Mab and MTB lung infection.

Key words: 1. Inhaled amikacin therapy
2. Coinfection
3. *Mycobacterium abscessus*
4. *Mycobacterium tuberculosis*
5. Pneumonectomy

Case report

Mycobacterium abscessus subsp. abscessus (Mab) lung disease is the most important cause of a non-tuberculous mycobacterium (NTM) infection, as it is considered a chronic infection that is incurable with current antibiotic therapy [1]. Moreover, the simultaneous detection of *Mycobacterium tuberculosis* (MTB) and NTM in patients with presumptive pulmonary tuberculosis (PTB) at the time of diagnosis is not considered uncommon, although patients treated for NTM lung disease co-infected with MTB are very rare [2]. Herein, we describe a case of the successful treatment of a mixed lung infection with Mab and

MTB by pneumonectomy followed by inhaled amikacin therapy.

In March 2011, a 59-year-old woman was referred to Busan Paik Hospital because of intermittent hemoptysis. She had no history of smoking or alcoholism, and no medical history other than that of PTB cured 27 years ago.

On examination, she appeared well and the other symptoms were unremarkable. Laboratory results, including a human immunodeficiency virus antibody test, were normal. Chest computed tomography (CT) revealed bronchiectasis and bronchiolitis mainly in the left upper lung (LUL) and right upper lobe (RUL) (Fig. 1A). NTM was isolated 3 times from consecutive

Received: April 11, 2016, Revised: September 26, 2016, Accepted: September 30, 2016, Published online: February 5, 2017

Corresponding author: Kyoung Taek Park, Department of Thoracic and Cardiovascular Surgery, Inje University Busan Paik Hospital, Inje University College of Medicine, 75 Bokji-ro, Busanjin-gu, Busan 47392, Korea
(Tel) 82-51-890-6834 (Fax) 82-51-891-1297 (E-mail) ktpark@paik.ac.kr

© The Korean Society for Thoracic and Cardiovascular Surgery. 2017. All right reserved.

© This is an open access article distributed under the terms of the Creative Commons Attribution Non-Commercial License (<http://creativecommons.org/licenses/by-nc/4.0>) which permits unrestricted non-commercial use, distribution, and reproduction in any medium, provided the original work is properly cited.

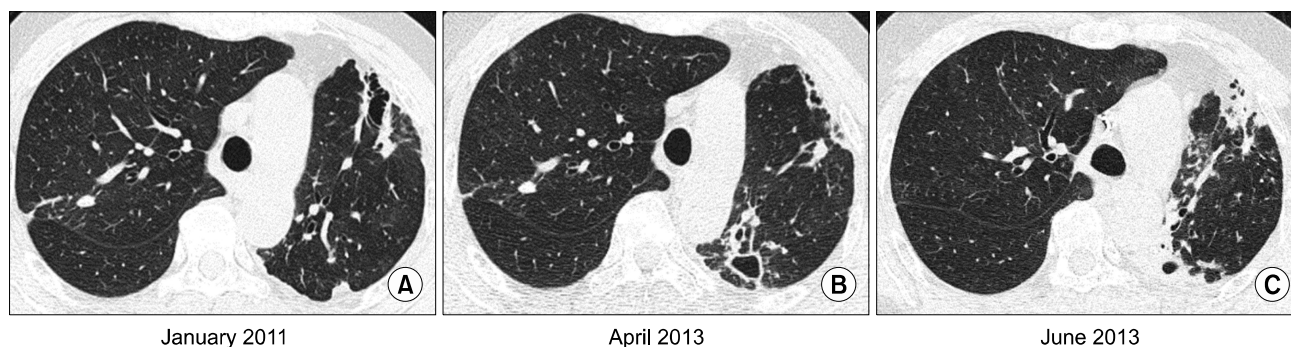


Fig. 1. A 59-year-old woman had bronchiectasis and nontuberculous mycobacterial lung disease caused by *Mycobacterium abscessus*. (A) A transverse chest CT scan at the time of presentation reveals bronchiectasis and bronchiolitis in the left upper, left lower, and right upper lobe. (B) A CT scan of the same patient at 3 years after diagnosis reveals the progression of the peri-bronchial infiltration and new cavitation in the left upper and lower lobes. (C) A CT scan obtained after 4 weeks of the initial antibiotic treatment shows mild regression of peribronchial and pericavitary infiltration. CT, computed tomography.

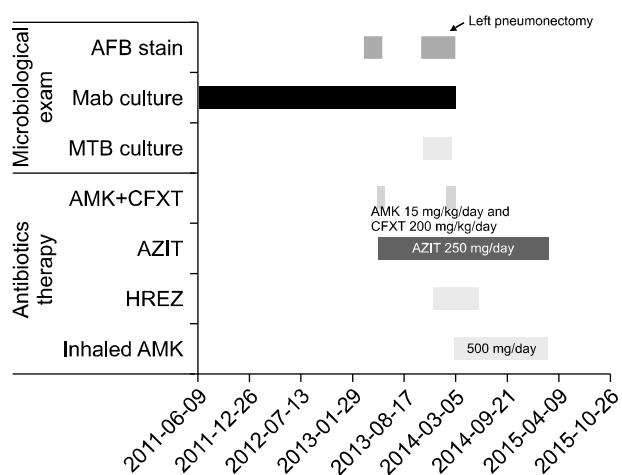


Fig. 2. Clinical course of this case. AFB, acid-fast bacilli; Mab, *Mycobacterium abscessus* subsp. *abscessus*; MTB, *Mycobacterium tuberculosis*; AMK, amikacin; CFXT, cefoxitin; AZIT, azithromycin; H, isoniazid; E, ethambutol; R, rifampicin; Z, pyrazinamide.

sputum specimens, and identified as Mab in all the isolates. She was diagnosed with Mab lung disease on the basis of the appropriate diagnostic guidelines [1].

She was followed up without antibiotic therapy because of her mild symptoms. During the 2 years after the diagnosis of Mab lung disease, her cough gradually worsened, with an increase in the quality of purulent sputum and intermittent hemoptysis. Moreover, the sputum smear status changed from negative to positive with radiological progression on chest CT (Fig. 1B and Fig. 2). She received oral azithromycin along with an initial 4-week course of intravenous

amikacin and cefoxitin. During the initial antibiotic treatment, her symptoms and CT lesions improved and the sputum smear changed to negative at weeks 3 and 4 of the treatment, although Mab was consistently cultivated (Fig. 1C and Fig. 2). Antibiotic treatment via oral azithromycin was continued after 4 weeks of the combination therapy. Follow-up sputum cultures remained persistently positive for Mab, and the smear status of the sputum again changed to positive after 4 months.

In November 2013, 6 months after the initial combination therapy, she revisited our clinic because of fever and worsened sputum. She was diagnosed with pneumonia in the LUL and treated with oral moxifloxacin, which led to some improvement in her condition (Fig. 3A). Surprisingly, however, both MTB and Mab were identified from 2 consecutive sputum samples. We treated her with isoniazid, rifampicin, ethambutol, and pyrazinamide, while assessing the possibility of a combined infection of Mab and MTB in the repeated sputum and bronchial washing samples. These tests yielded the same result; unfortunately, a drug sensitivity test could not be conducted because of the mixed colonies of mycobacteria.

We decided to treat her with a 4-week course of intravenous amikacin and cefoxitin once more, along with oral azithromycin and anti-tuberculosis (TB) medication. Despite the add-on therapy, her follow-up sputum smears remained consistently positive, and eventually, her entire left lung was destroyed and collapsed (Fig. 2 and Fig. 3B, C). She underwent left pneumonectomy because of the persis-

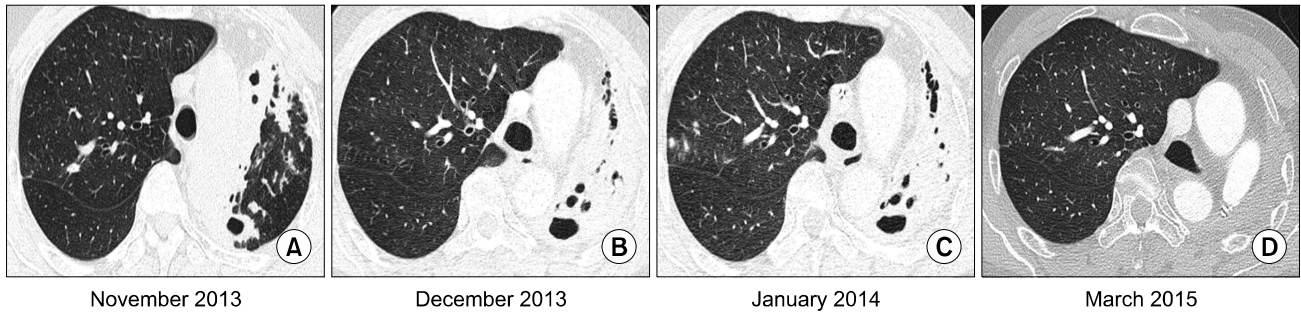


Fig. 3. Serial changes in the same patient during therapy for Mab lung disease. (A) A CT scan 6 months after initial combination antibiotic therapy shows new peri-bronchial infiltration and cavities compared with a previous CT taken in June 2013. (B) A CT scan taken at the commencement of anti-tuberculosis and repeated anti-Mab therapy shows the destruction and collapse of the entire left lung. (C) A CT scan obtained after 4 weeks of full antibiotic therapy shows little change. (D) A chest CT scan taken 1 year after left pneumonectomy, followed by inhaled amikacin therapy, shows an improvement in the small bronchiolitis lesion in the right lung. Mab, *Mycobacterium abscessus subsp. abscessus*; CT, computed tomography.

tent positive smear in the acid-fast bacilli stain and resistance to the antibiotic therapy. Pathological examinations of the surgically resected specimen showed chronic granulomatous inflammation, and a mixed infection of MTB and Mab was confirmed in a subsequent mycobacterial culture of the lung tissue.

Antibiotics targeting Mab were continued for a week after surgery, followed by inhaled amikacin (500 mg/day) along with oral azithromycin for 12 months, as she had another small lung lesion suggesting a Mab infection in the RUL. Anti-TB therapy was maintained for a total of 6 months. A completely negative sputum smear and culture conversion of MTB and Mab were achieved immediately after surgery and maintained until the completion of the antibiotic treatment (Fig. 2). The patient remained well, without relapse of the Mab lung disease, at a 1-year follow-up after the completion of therapy.

Discussion

A mixed infection involving NTM and MTB in the lung is a very rare clinical manifestation, although polyclonal and mixed infections of NTM and MTB have been reported [2,3]. However, the simultaneous detection of NTM species in respiratory specimens with underlying PTB can occur, and such an infection is not considered a true concurrent infection because NTM is ubiquitous in the environment [1]. Thus, most studies have focused on distinguishing NTM lung disease from PTB at the time of the initial diagnosis, at the recurrence of PTB, and during follow-up

examinations while treating PTB [4]. Moreover, there is only one previous report in the literature about a concurrent infection of NTM and MTB in an immune-compromised host, while none involving immune-competent hosts have been published [3].

In our case, the patient had pneumonia in the LUL during the therapy for NTM. We treated her pneumonia with moxifloxacin. She showed improvement clinically and radiologically after a week of therapy. However, at 4 weeks after pneumonia, we noticed the concurrent MTB infection from the repeated results of the cultures conducted to assess Mab lung disease, which was unexpected because of its rarity. Previous studies dispute whether the use of fluoroquinolone in pneumonia contributes to delays in the diagnosis of PTB [5]. The 2009 Korean Guideline for Community-Acquired Pneumonia (CAP), not yet revised, recommended that the use of fluoroquinolone as the first-line therapy for CAP be avoided in the setting of PTB, because South Korea has an intermediate TB burden. However, these conditions cannot easily be distinguished in real clinical practice. Our patient already had multiple bronchiectasis; hence, we treated her with moxifloxacin, based on her structural lung disease.

Moreover, the management of her concurrent NTM and MTB infection was further complicated, as she already had a history of PTB and had been treated with several antibiotics for the Mab lung disease. Further, the possibility of drug-resistant (DR) MTB required investigation. However, we could not conduct a drug sensitivity test by either the phenotypic

or the genotypic method, because the colonies of MTB were mixed with those of NTM. Her left lung continued to deteriorate over time, despite anti-TB and anti-Mab medication; fortunately, her right lung was relatively conserved. Thus, we decided to perform left pneumonectomy. Many previous studies have reported that surgical resection has played an important role in the treatment of refractory NTM and DR-MTB infections of the lung [6,7]. In our case, surgical resection was also an effective treatment of her concurrent MTB infection with a suspected DR pathogen and medically refractory Mab lung disease with a unilateral destruction of the lung.

It is recommended that Mab lung disease be treated with oral macrolide therapy in combination with intravenous amikacin and cefoxitin for 2 to 4 months, according to the revised guidelines for NTM [1]; however, the prolonged use of systemic amikacin is limited because of its adverse effects [4]. A recent study showed an effective outcome of negative culture conversion in 62% of refractory NTM lung disease cases when inhaled amikacin therapy was added [8]. Moreover, a study evaluating the effectiveness of inhaled amikacin for Mab lung disease is currently ongoing [4]. We treated the patient in this study with oral azithromycin, along with inhaled amikacin, for 12 months after pneumonectomy, and she has remained culture-negative to date.

In conclusion, we successfully treated a patient with combined Mab lung disease and PTB by pneumonectomy followed by inhaled amikacin therapy. To the best of our knowledge, thus far, this is the first description of a mixed lung infection involving Mab and MTB in an immune-competent individual.

Conflict of interest

No potential conflict of interest relevant to this article was reported.

References

1. Griffith DE, Aksamit T, Brown-Elliott BA, et al. *An official ATS/IDSA statement: diagnosis, treatment, and prevention of nontuberculous mycobacterial diseases*. Am J Respir Crit Care Med 2007;175:367-416.
2. Hwang SM, Lim MS, Hong YJ, et al. *Simultaneous detection of Mycobacterium tuberculosis complex and nontuberculous mycobacteria in respiratory specimens*. Tuberculosis (Edinb) 2013;93:642-6.
3. Huang HC, Yu WL, Shieh CC, Cheng KC, Cheng HH. *Unusual mixed infection of thoracic empyema caused by Mycobacterium tuberculosis, nontuberculous mycobacteria and Nocardia asteroides in a woman with systemic lupus erythematosus*. J Infect 2007;54:e25-8.
4. McShane PJ, Glassroth J. *Pulmonary disease due to nontuberculous mycobacteria: current state and new insights*. Chest 2015;148:1517-27.
5. Chen TC, Lu PL, Lin CY, Lin WR, Chen YH. *Fluoroquinolones are associated with delayed treatment and resistance in tuberculosis: a systematic review and meta-analysis*. Int J Infect Dis 2011;15:e211-6.
6. Kang HK, Park HY, Kim D, et al. *Treatment outcomes of adjuvant resectional surgery for nontuberculous mycobacterial lung disease*. BMC Infect Dis 2015;15:76.
7. Madansein R, Parida S, Padayatchi N, et al. *Surgical treatment of complications of pulmonary tuberculosis, including drug-resistant tuberculosis*. Int J Infect Dis 2015;32:61-7.
8. Olivier KN, Shaw PA, Glaser TS, et al. *Inhaled amikacin for treatment of refractory pulmonary nontuberculous mycobacterial disease*. Ann Am Thorac Soc 2014;11:30-5.