


# Response to Anti-HER2-Based Treatment in a Patient with Bladder Adenocarcinoma Harboring *HER2* Amplification and S310F Mutation Discovered by Next-Generation Sequencing: A Case Report

This article was published in the following Dove Press journal:  
*OncoTargets and Therapy*

Xiaolu Wang 

Wenjing Hu

Li Xie

The Comprehensive Cancer Centre of Drum Tower Hospital, Medical School of Nanjing University, Clinical Cancer Institute of Nanjing University, Nanjing, People's Republic of China

**Purpose:** *HER2* overexpression has been identified in approximately 14% of bladder adenocarcinomas. However, until now, there has been no approved standard targeted therapy for bladder adenocarcinoma patients harboring *HER2* genetic alteration.

**Case Presentation:** We presented a case of a 64-year-old man who was diagnosed with bladder adenocarcinoma, and lung metastasis was confirmed less than one year after initial bladder surgery. The patient received systemic chemotherapy and antiangiogenic treatment, but the tumor continued to progress. The patient underwent next-generation sequencing (NGS) to seek potential treatment opportunities. *HER2* amplification, approximately 7 times, was discovered together with the S310F mutation (mutant abundance 90%). The patient then received late-line treatment with trastuzumab and albumin-bound paclitaxel. A partial response was confirmed two months later. Trastuzumab-based therapy was continued for 8 cycles, and the progression-free survival period was 6 months. NGS was performed on a rebiopsy, and the result showed no amplification of *HER2*, and the S310F mutant abundance was reduced to 27.9%.

**Conclusion:** This is the first case report describing a bladder adenocarcinoma patient harboring *HER2* amplification who responded to trastuzumab. NGS is of great potential in the selection of bladder adenocarcinoma patients suitable for anti-*HER2* therapy. The genetic change after treatment also implied possible mechanisms of resistance to trastuzumab-based therapy, which requires more investigation.

**Keywords:** bladder adenocarcinoma, human epidermal growth factor receptor 2, next-generation sequencing, trastuzumab

## Introduction

Bladder adenocarcinoma is a rare histology of bladder cancer that accounts for only approximately 0.5–2% of bladder cancers.<sup>1</sup> Bladder adenocarcinoma is derived from the bladder urothelium but exhibits a histologically pure glandular phenotype. Most patients with primary bladder adenocarcinoma have muscle invasive disease, and a minority may present with non-muscle invasive disease. Some retrospective studies have revealed that the clinical outcome of bladder adenocarcinoma is worse than that of urothelial carcinoma.<sup>2,3</sup> There is no standard treatment for metastatic bladder adenocarcinoma, especially for patients who receive multiple lines of treatment. The regimens effective for metastatic urothelial carcinoma have limited efficacy for

Correspondence: Li Xie; Wenjing Hu  
The Comprehensive Cancer Centre of Drum Tower Hospital, Medical School of Nanjing University, Clinical Cancer Institute of Nanjing University, 321 Zhongshan Road, Nanjing 210008, People's Republic of China  
Tel +8613605169652; +8613405848364  
Email sherry01130@163.com; hwj19987@sina.com

patients with advanced bladder adenocarcinoma. The identification of new therapeutic targets is urgently needed.

The human epidermal growth factor receptor 2 (*HER2*) gene, also known as *ERBB2*, is amplified in a variety of malignancies. Normally, *HER2* gene amplification is detected in malignancies with epithelial sources rather than tumors derived from other tissue sources.<sup>4</sup> *HER2* amplification could act as a major driver mutation and has been confirmed as an important treatment target in breast and gastric cancers. Recent studies have found that the rate of *HER2* amplification in bladder cancer follows only that in breast and gastric cancers.<sup>5</sup> However, reports on *HER2* expression in bladder adenocarcinoma tissue are lacking, and anti-*HER2*-targeted therapy has not been applied in bladder adenocarcinoma treatment.

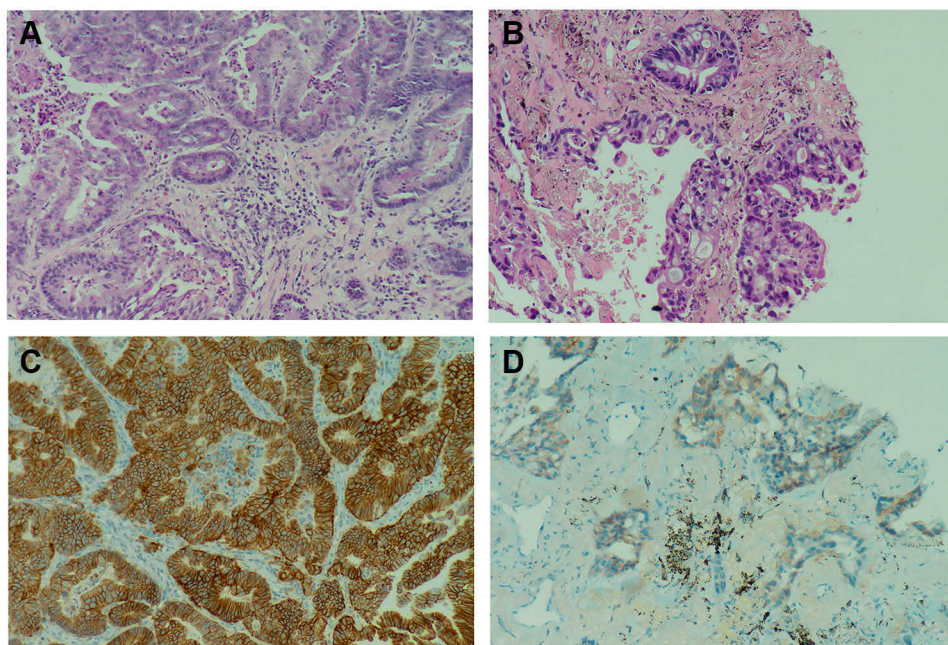
To date, personalized cancer medicine based on next-generation sequencing (NGS) data has produced exciting results. According to a variety of studies, urothelial carcinoma can be classified into at least four to five molecular subtypes for personalized diagnosis, treatment, and prognosis.<sup>6</sup> However, few data on bladder adenocarcinoma have been obtained. Torenbeek et al found that *HER2* was present in 14% of bladder adenocarcinomas, with 2/21 partial expression and 1/21 total expression.<sup>7</sup> To our knowledge, no anti-*HER2*-targeted therapy has been reported in bladder adenocarcinoma.

In addition, various methods for *HER2* assessment are used in bladder cancer, and there is no consistent definition of *HER2* positivity as in breast and gastric cancers. The value of NGS in *HER2* detection and the selection of patients for anti-*HER2* therapy in bladder adenocarcinoma remains to be explored.

Here, we present a patient with metastatic bladder adenocarcinoma harboring *HER2* amplification who achieved a partial response (PR) after late-line treatment with trastuzumab and albumin-bound paclitaxel under the guidance of NGS.

## Case Presentation

A 64-year-old male patient presented with hematuria and underwent three transurethral resection of bladder tumors (TURBTs) between November 4, 2014, and March 18, 2015. The pathological diagnosis was bladder adenocarcinoma (Figure 1A), with immunohistochemistry (IHC) showing CK7 (+), CK20 (+), CDX2 (+), GATA-3 (±), L1-cad (+), PSA (-), P63 (-), P53 (+), *HER2* (3+), and the Ki-67 proliferation index was 80% (Figure 1C). The initial clinical stage was stage I (T1N0M0), and repeated TURBTs were carried out without any residual tumor identified. This patient received regular intravesical chemotherapy with gemcitabine after TURBTs.



**Figure 1** Pathologic findings of the primary tumor and the pulmonary lesion specimen after trastuzumab-based therapy. (A) Hematoxylin and eosin staining of the primary tumor revealed bladder adenocarcinoma (magnification ×200). (B) Hematoxylin and eosin staining of the pulmonary lesion specimen after trastuzumab-based therapy revealed adenocarcinoma, indicating that it was a metastasis of bladder adenocarcinoma (magnification ×200). (C) The primary tumor exhibited strong positive immunohistochemical staining for *HER2* (3+) (magnification ×200). (D) The pulmonary lesion specimen after trastuzumab-based therapy exhibited positive immunohistochemical staining for *HER2* (2+) (magnification ×200).

In October 2015, two new lesions in the lungs were discovered by surveillance CT scans and were confirmed as metastatic adenocarcinoma on further biopsy. Four cycles of paclitaxel (135mg/m<sup>2</sup> every 3 weeks) and oxaliplatin (130mg/m<sup>2</sup> every 3 weeks) were administered beginning on November 17, 2015, and stable disease (SD) was achieved. Radiation therapy for the two lesions, with a total dose of 48 Gy (BED=86.4 Gy), was delivered concomitantly with chemotherapy (paclitaxel and oxaliplatin) from January 1, 2016, to April 16, 2016. This treatment was previously found to be well-tolerated, with mild adverse events, including grade 1 transaminitis and grade 1 thrombocytopenia. Then, the CT scan showed a PR, and capecitabine was given to the patient orally beginning on April 30, 2016. To determine potential treatment opportunities, NGS of the primary bladder tumor was conducted on March 23, 2016, and the results showed that the *HER2* gene was amplified approximately 7 times, with an S310F mutant abundance of 90% (Table 1).

Lung lesion progression was identified by a CT scan on August 8, 2016, and apatinib was administered at a dose of 500 mg every day. The best response to apatinib was PR, and progression-free survival (PFS) reached as long as 20 months. The CT scan revealed progressed disease (PD), with new lesions identified on March 30, 2018 (Figure 2A). Then, fourth-line treatment with trastuzumab and albumin-bound paclitaxel was administered beginning on April 11, 2018. The regimen comprised trastuzumab (8 mg/kg first dose and then 6 mg/kg every 3 weeks) and albumin-bound paclitaxel (250 mg/m<sup>2</sup> every 3 weeks). A PR was achieved after two cycles of treatment (Figure 2B) according to the Response Evaluation Criteria in Solid Tumors (RECIST) (version 1.1) and confirmed two months later. Trastuzumab-based therapy was continued for 8 cycles until CT scans revealed enlargement of the lesions (Figure 2C), with a PFS period of 6 months. During the treatment, he periodically performed echocardiography (every 3-6 months) to monitor the potential cardiotoxicity of the biological drug but no sign of cardiomyopathy was revealed and the ejection fraction maintained an excellent value (55–65%). No signs of adverse events were identified except for mild thrombocytopenia and decreased hemoglobin (both are grade 0). Then, a rebiopsy of a pulmonary metastatic lesion was carried out. Pathological and histopathological examination revealed metastasis of bladder adenocarcinoma (Figure 1B), with IHC showing HER2 (2+) (Figure 1D). NGS was conducted again on October 25, 2018. The results showed no amplification of *HER2*, and the S310F mutant abundance was

**Table 1** Mutations Revealed by NGS in the Primary Bladder Tumor and Pulmonary Metastatic Lesion

Gene	Primary Bladder Tumor (March 23, 2016)	Pulmonary Metastatic Lesion (October 25, 2018)
<i>HER2</i>	Gene amplification, approximately 7 times; S310F mutation (mutant abundance 90%)	S310F mutation (mutant abundance 27.9%)
<i>TP53</i>	C238Y mutation (mutant abundance 76%)	C238Y mutation (mutant abundance 36.3%)
<i>ARID2</i>	Q68X truncation mutation (mutant abundance 35%), T909fs missing frameshift mutation (mutant abundance 35%)	Q68 mutation (mutant abundance 17.1%) T909fs mutation (mutant abundance 17.4%)
<i>BIM</i>	Heterozygous deletion polymorphism	—
<i>CDK12</i>	Gene amplification, approximately 5.2 times	—
<i>RARA</i>	Gene amplification, approximately 3 times	—
<i>TOP2A</i>	Gene amplification, approximately 2.3 times	—
<i>APC</i>	—	R1742H mutation (mutant abundance 20.8%)
<i>AKT2</i>	—	R731H mutation (mutant abundance 16.2%)

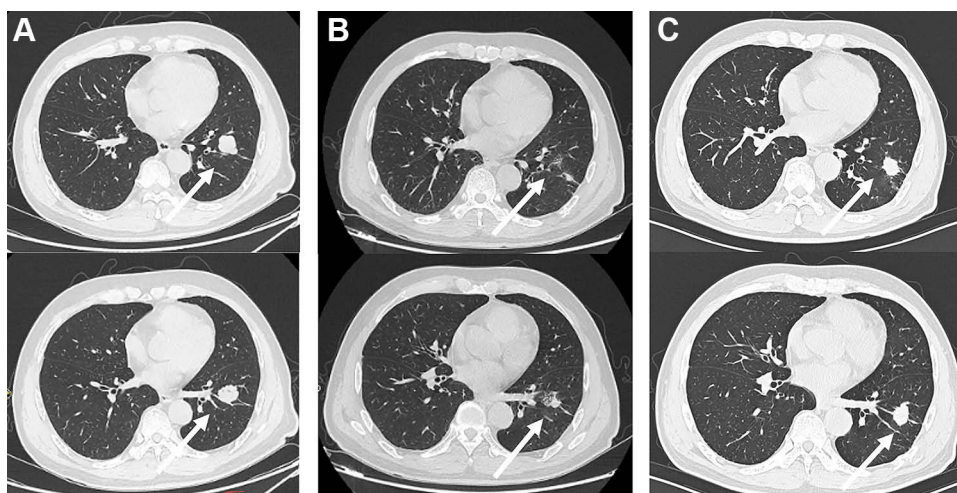
reduced to 27.9% (Table 1). The gene correlation analysis is shown in Figure 3.

This study was approved by the Medical Ethics Committee of Drum Tower Hospital. Written informed consent was also provided by the patient for publishing the case details and accompanying images in the case study.

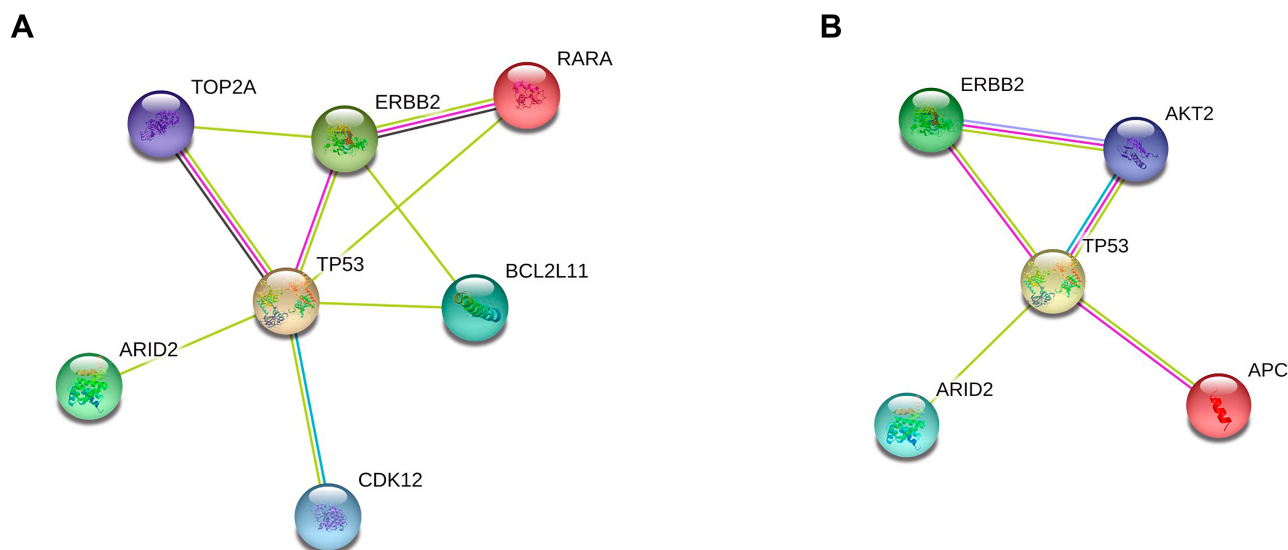
## Discussion

In this case report, we presented a 64-year-old male diagnosed with stage I bladder adenocarcinoma, and lung metastasis was confirmed less than one year after the first operation. The patient was found to harbor *HER2* amplification and the S310F mutation by NGS of the primary bladder tumor. After failing three lines of antitumor treatments, the patient then received fourth-line treatment with trastuzumab and albumin-bound paclitaxel. The patient responded very





**Figure 2** Chest CT scans before and after trastuzumab-based therapy. **(A)** Before trastuzumab-based therapy (March 30, 2018), a CT scan showed a lesion in the left lower lung lobe (white arrow). **(B)** The disease reached partial remission after 2 cycles of trastuzumab-based treatment (May 25, 2018), the mass was reduced significantly (white arrow). **(C)** Disease progression after trastuzumab-based therapy for six months, enlargement of the mass (white arrow) was observed on October 23, 2018.



**Figure 3** Analysis results from the STRING website. **(A)** Relationship of seven mutant genes before trastuzumab-based therapy. **(B)** Relationship of five mutant genes after trastuzumab-based therapy.

well to trastuzumab-based treatment, with a PFS period of 6 months, suggesting that trastuzumab-based therapy may be a potential treatment option for bladder adenocarcinoma patients harboring *HER2* amplification. After tumor progression, NGS was conducted again and showed no *HER2* amplification, and the S310F mutant abundance was reduced to 27.9%. These genetic changes imply possible mechanisms of resistance to trastuzumab.

The incidence of *HER2* in bladder cancer ranges from 0% to 59% for highly variable *HER2* gene amplification and from 21% to 89% for *HER2* receptor protein overexpression.<sup>8,9</sup> *HER2* amplification leading to protein overexpression has

been reported in 0–25% of bladder cancer patients heterogeneously.<sup>10</sup> This large difference is partly due to a lack of a consistent definition of *HER2* positivity. There is also controversy about the significance of IHC and fluorescence in situ hybridization (FISH) concordance, as gene amplification may not be a potential mechanism of protein overexpression.<sup>11</sup> Recently, Kiss et al claimed that only FISH or IHC is not enough to select patients and reported an algorithm to molecularly stratify bladder cancer for anti-*HER2* therapy considering gene expression, amplification, polysomy, and somatic mutations.<sup>12</sup> For bladder adenocarcinoma, 2/21 samples with partial *HER2* expression and 1/21 sample with

total HER2 expression were reported.<sup>7</sup> Data are extremely limited; thus, it is difficult to define HER2 positivity in bladder adenocarcinoma.

NGS, as a new genetic alteration detection approach, cannot only uncover various types of mutations but also comprehensively analyze the genetic changes of malignancy, which may help identify new therapeutic targets. Based on this concept, the Phase II NCI-MATCH trial (NCT02465060) is enrolling pretreated patients who will be treated with targeted therapies tailored by NGS. This trial involves patients with *HER2* amplification or mutation who were treated with anti-HER2 therapies, but the final results are still pending.<sup>13</sup> A treatment subprotocol of the NCI-MATCH trial studied the efficacy of ado-trastuzumab emtansine (T-DM1) in patients with *HER2*-amplified tumors excluding breast and gastric/gastro-esophageal junction (GEJ) adenocarcinomas based on NGS. The results showed that T-DM1 was well tolerated, while the primary endpoint, overall response rate (ORR), was not met.<sup>14</sup> Based on the evidence mentioned above, NGS has shown great potential in the selection of patients suitable for anti-HER2 therapy.

Trastuzumab is a targeted therapy for patients with evidence of HER2 overexpression.<sup>15</sup> It was first approved for the treatment of HER2-positive metastatic breast cancer in 1998 and has led to the establishment of a new standard of care treatment for HER2-positive disease.<sup>16–19</sup> Trastuzumab remains one of the most promising HER2-targeted therapeutics and is being applied in the first-line treatment of HER2-positive breast and gastric cancers. Recently, a few successful cases of anti-HER2 treatment in bladder cancer have been reported.<sup>4</sup> A phase II trial testing trastuzumab in a combination regimen in HER2-positive urothelial carcinoma had a 70% response rate.<sup>20</sup> In another phase II trial, afatinib demonstrated significant activity in patients with platinum-refractory urothelial carcinoma with *HER2* or *ERBB3* alterations.<sup>21</sup> An open-label phase IIa basket study (NCT02091141) also reported that a few patients with urothelial carcinoma showed noted responses after receiving dual anti-HER2 therapy (trastuzumab/pertuzumab).<sup>22</sup> The above clinical trials all demonstrated the potential of anti-HER2 treatment in bladder cancer. However, various methods are used for HER2 assessment and their anti-HER2 treatment regimens are different. Limitations in design methods have also weakened the validity of the conclusion. Besides, a randomized phase II trial in urothelial carcinoma failed to demonstrate the effectiveness of trastuzumab.<sup>23</sup> Thus, more research is required to investigate the efficacy of anti-HER2 therapy in bladder cancer. Regarding bladder adenocarcinoma,

there has been no reports of anti-HER2 treatment to our knowledge. In this case, NGS-guided trastuzumab-based therapy demonstrated efficiency in metastatic bladder adenocarcinoma as the fourth-line treatment.

In the current case, the *HER2* gene was altered after trastuzumab-based therapy and we suspected that the tumor highly depended on the HER2 pathway. NGS of the primary tumor showed that *HER2* was amplified approximately 7 times, with an S310F mutant abundance of 90%. Both *HER2* amplification and S310F mutations are believed to be associated with the effectiveness of anti-HER2 treatment.<sup>24</sup> As a result, the anti-HER2-based treatment was effective. Notably, the efficacy in our case is the result of combination treatment. The contribution of albumin-bound paclitaxel cannot be ruled out. The choice of albumin-bound paclitaxel is mainly due to the efficacy of first-line treatment. Paclitaxel combined with anti-HER2 therapy is considered to be the most effective first-line treatment for metastatic breast cancer. Trastuzumab also requires to be combined with chemotherapy in other cancers. Therefore, the combination of trastuzumab and chemotherapy (albumin-bound paclitaxel) is rational. After tumor progression, the second NGS analysis showed no *HER2* amplification, and the abundance of the S310F mutation was reduced to 27.9%. Trastuzumab is targeting the HER2 pathway. The genetic change in the HER2 pathway implied the value of anti-HER2 treatment. Thus, we are inclined to propose that changes in the HER2 pathway are due to the patient's response to trastuzumab.

This genetic change also suggested the clonal evolution of the tumor at different time points and implied possible mechanisms of resistance to trastuzumab. In the present case, gene correlation analysis suggested that the *TP53* mutation was the central node of mutant genes in the two NGS analyses (Figure 2A and B). *HER2* was another key gene in the first NGS analysis, as it was associated with four mutant genes (Figure 2A). However, the relationship between other mutant genes and *HER2* decreased after treatment (Figure 2B). Notably, the *HER2* gene and two other amplified genes, *RARA* and *TOP2A*, are all located on chromosome 17. The disappearance of *HER2* amplification may cause the disappearance of *RARA* and *TOP2A* amplification. The reduced relationship indicates the attenuated role of the *HER2* pathway, which may partly lead to the failure of trastuzumab-based therapy.

The current case has shown the potential of anti-HER2 therapy in bladder adenocarcinoma, but there are still some limitations during treatment. Although this patient's primary

tumor specimen had a genetic alteration in *HER2*, the initial treatment was a conventional treatment plan following the guidelines. After disease progression, there was no standard treatment. Then we chose apatinib, which was more cost-effective and accessible at the time. Despite the multi-line treatments, the patient still benefited from the combination of trastuzumab and albumin-bound paclitaxel, implying that trastuzumab-based therapy can be one of the optimized selections for patients with *HER2* amplification. Recently, many “basket” studies have focused on gene guided treatments, ignoring tumor types. The results were inconsistent, with some studies showing benefits of treatment and others showing poor results. The main reason may be that the tumor is a polygenic disease with complicated interaction of signal pathways, which may affect the outcome of gene guided treatments. Whether such a regimen can be used at an earlier stage requires further exploration.

## Conclusion

We reported a case of bladder adenocarcinoma with *HER2* amplification and activating mutations by NGS that was effectively treated with trastuzumab-based therapy. Based on this finding, trastuzumab-based therapy might be considered an optimal treatment for bladder adenocarcinoma patients harboring *HER2* amplification. NGS seems to be an important tool in the selection of bladder adenocarcinoma patients suitable for anti-*HER2* therapy. In addition, the current case also implied possible mechanisms of resistance to trastuzumab and the significance of real-time mutation detection, which needs further exploration.

## Abbreviations

*HER2*, the human epidermal growth factor receptor 2; TURBTs, transurethral resection of bladder tumors; NGS, next-generation sequencing; PR, partial response; SD, stable disease; PFS, progression-free survival; PD, progressed disease; ORR, overall response rate.

## Ethics and Consent Statement

Written informed consent was provided by the patient for the publication of images and details of the case.

## Acknowledgments

Many thanks for the great help from colleagues at the Comprehensive Cancer Centre of Drum Tower Hospital.

## Disclosure

The authors declare that they have no conflicts of interest to disclose.

## References

- Roy S, Pradhan D, Ernst WL, et al. Next-generation sequencing-based molecular characterization of primary urinary bladder adenocarcinoma. *Mod Pathol*. 2017;30(8):1133–1143. doi:10.1038/modpathol.2017.33
- Lughezzani G, Sun M, Jeldres C, et al. Adenocarcinoma versus urothelial carcinoma of the urinary bladder: comparison between pathologic stage at radical cystectomy and cancer-specific mortality. *Urology*. 2010;75(2):381.
- Gilligan T, Dreicer R. The Atypical Urothelial Cancer Patient: management of Bladder Cancers of Non-Transitional Cell Histology and Cancers of the Ureters and Renal Pelvis. *Semin Oncol*. 2007;34(2):145–153. doi:10.1053/j.seminoncol.2006.12.005
- Yan M, Schwaederle M, Arguello D, Millis SZ, Gatalica Z, Kurzrock R. *HER2* expression status in diverse cancers: review of results from 37,992 patients. *Cancer Metastasis Rev*. 2015;34(1):157–164. doi:10.1007/s10555-015-9552-6
- Network CGA. Comprehensive molecular characterization of urothelial bladder carcinoma. *Nature*. 2014;507(7492):315–322.
- Robertson AG, Kim J, Al-Ahmadie H, Bellmunt J, Zwarthoff EC. Comprehensive Molecular Characterization of Muscle-Invasive Bladder Cancer. *Cell*. 2017;171(3):540–556.e25. doi:10.1016/j.cell.2017.09.007
- Torenbeek R, Lagendijk JH, Van Diest PJ, Bril H, Van De Molengraft FJ, Meijer CJ. Value of a panel of antibodies to identify the primary origin of adenocarcinomas presenting as bladder carcinoma. *Histopathology*. 1998;32(1):20–27. doi:10.1046/j.1365-2559.1998.00328.x
- Ehsani L, Osunkoya AO. Human epidermal growth factor receptor 2 expression in urothelial carcinoma of the renal pelvis: correlation with clinicopathologic parameters. *Int J Clin Exp Pathol*. 2014;7(5):2544–2550.
- Lae M, Couturier J, Oudard S, Radvanyi F, Beuzebec P, Vieillefond A. Assessing *HER2* gene amplification as a potential target for therapy in invasive urothelial bladder cancer with a standardized methodology: results in 1005 patients. *Ann Oncol*. 2010;21(4):815–819. doi:10.1093/annonc/mdp488
- Moktefi A, Pouessel D, Liu J, et al. Reappraisal of *HER2* status in the spectrum of advanced urothelial carcinoma: a need of guidelines for treatment eligibility. *Mod Pathol*. 2018;31(8):2631–2632. doi:10.1038/s41379-018-0023-9
- Coogan CL, Estrada CR, Kapur S, KJ B. *HER-2/neu* protein overexpression and gene amplification in human transitional cell carcinoma of the bladder. *Urology*. 2004;63(4):790.
- Kiss B, Wyatt AW, Douglas J, et al. *Her2* alterations in muscle-invasive bladder cancer: patient selection beyond protein expression for targeted therapy. *Sci Rep*. 2017;7(3):42713. doi:10.1038/srep42713
- Mendiratta P, Grivas P. Emerging biomarkers and targeted therapies in urothelial carcinoma. *Ann Transl Med*. 2018;6(12):250. doi:10.21037/atm.2018.05.49
- Jhaveri KL, Wang XV, Makker V, et al. Ado-trastuzumab emtansine (T-DM1) in patients with *HER2* amplified tumors excluding breast and gastric/gastro-esophageal junction (GEJ) adenocarcinomas: results from the NCI-MATCH Trial (EAY131) Sub-protocol Q. *Ann Oncol*. 2019;30:1821–1830. doi:10.1093/annonc/mdz291
- De Laurentiis M. Targeting *HER2* as a therapeutic strategy for breast cancer: a paradigmatic shift of drug development in oncology. *Ann Oncol*. 2005;16.
- Marty M. Randomized Phase II trial of the efficacy and safety of trastuzumab combined with docetaxel in patients with human epidermal growth factor receptor 2-positive metastatic breast cancer administered as first-line treatment: the M77001 study group. *J Clin Oncol*. 2005;23(19):4265–4274.

17. Slamon DJ, Leyland-Jones B, Shak S, et al. Use of chemotherapy plus a monoclonal antibody against HER2 for metastatic breast cancer that overexpresses HER2. *N Engl J Med.* 2001;344(11):783–792. doi:10.1056/NEJM200103153441101
18. Witzel I, Müller V, Abenhardt W, et al. Long-term tumor remission under trastuzumab treatment for HER2 positive metastatic breast cancer – results from the HER-OS patient registry. *BMC Cancer.* 2014;14(1):806. doi:10.1186/1471-2407-14-806
19. Gradishar WJ, Anderson BO, Balassanian R, Blair SL, Shear DA. Breast cancer, version 4.2017, NCCN clinical practice guidelines in oncology. *J Natl Compr Canc Netw.* 2018;16(3):310–320. doi:10.6004/jncn.2018.0012
20. Hussain MH, MacVicar GR, Petrylak DP, et al. Trastuzumab, paclitaxel, carboplatin, and gemcitabine in advanced human epidermal growth factor receptor-2/neu-positive urothelial carcinoma: results of a multicenter phase II National Cancer Institute trial. *J Clin Oncol.* 2007;25(16):2218–2224. doi:10.1200/JCO.2006.08.0994
21. Choudhury NJ, Campanile A, Antic T, et al. Afatinib activity in platinum-refractory metastatic urothelial carcinoma in patients with ERBB alterations. *J Clin Oncol.* 2016;34(18):2165–2171. doi:10.1200/JCO.2015.66.3047
22. Hainsworth J, Meric-Bernstam F, Swanton C, et al. Targeted therapy for advanced solid tumors on the basis of molecular profiles: results from mypathway, an open-label, Phase IIa multiple basket study. *J Clin Oncol.* 2018;36:JCO2017753780. doi:10.1200/JCO.2017.75.3780
23. Stéphane O, Stéphane C, Yann V, et al. Multicentre randomised phase II trial of gemcitabine+platinum, with or without trastuzumab, in advanced or metastatic urothelial carcinoma overexpressing Her2. *Eur J Cancer.* 2015;51(1):45–54. doi:10.1016/j.ejca.2014.10.009
24. Kavuri SM, Jain N, Galimi F, Cottino F, Bose R. HER2 activating mutations are targets for colorectal cancer treatment. *Cancer Discov.* 2015;5(8):832–841. doi:10.1158/2159-8290.CD-14-1211

## OncoTargets and Therapy

Dovepress

### Publish your work in this journal

OncoTargets and Therapy is an international, peer-reviewed, open access journal focusing on the pathological basis of all cancers, potential targets for therapy and treatment protocols employed to improve the management of cancer patients. The journal also focuses on the impact of management programs and new therapeutic

agents and protocols on patient perspectives such as quality of life, adherence and satisfaction. The manuscript management system is completely online and includes a very quick and fair peer-review system, which is all easy to use. Visit <http://www.dovepress.com/testimonials.php> to read real quotes from published authors.

Submit your manuscript here: <https://www.dovepress.com/oncotargets-and-therapy-journal>