



Mucoid degeneration of the cruciate ligaments in osteoarthritis under primary total knee arthroplasty

Kohei Kawaguchi^{*}, Kazuhiko Michishita, Takeshi Manabe, Yoshiyuki Akasaka, Takahiro Arakawa, Junya Higuchi

Orthopaedic Department, Japan Community Healthcare Organization, Yugawara Hospital, Japan



ARTICLE INFO

Article history:

Received 11 September 2017

Received in revised form

9 November 2017

Accepted 5 December 2017

Keywords:

Mucoid degeneration

Posterior cruciate ligament

Anterior cruciate ligament

Osteoarthritis

Total knee arthroplasty

ABSTRACT

Mucoid degeneration of the anterior cruciate ligament (ACL) and posterior cruciate ligament (PCL) with osteoarthritis is rarely reported. We experienced two knee osteoarthritic patients who had symptomatic mucoid degeneration of their ACL, and their PCL was also diagnosed as mucoid degeneration in histological evaluation. Preoperative radiological evaluation could not reveal precisely whether the degeneration had extended to the PCL. We obtained good clinical results treating them with posterior-stabilized (PS) total knee arthroplasty (TKA) sacrificing both ligaments. In cases of osteoarthritis with mucoid degenerated ACL, PS TKA should be considered, sacrificing both cruciate ligaments, because mucoid degeneration might expand both cruciate ligaments.

© 2018 Asia Pacific Knee, Arthroscopy and Sports Medicine Society. Published by Elsevier (Singapore) Pte Ltd. This is an open access article under the CC BY-NC-ND license (<http://creativecommons.org/licenses/by-nc-nd/4.0/>).

Introduction

Mucoid degeneration of the anterior cruciate ligament (ACL) was first reported by Kumar et al.¹ Mucoid degeneration of the ACL is rarely reported, but it has recently been suggested that its incidence may in fact be higher than initially thought.² Mucoid degeneration sometimes seems to be misdiagnosed as partial ligament tears.^{3,4} It occurs mainly after 40 years old, and its cause is unclear, but some reports have mentioned that its cause may be related to aging.^{3,5} Some osteoarthritis (OA) patients with mucoid degeneration of the ACL may be treated as simple worsened OA or partially damaged ACL and receive total knee arthroplasty (TKA). In such cases, for example cruciate-retaining (CR) TKA, retaining a degenerated cruciate ligament might be risk factor for post-operative dissatisfaction.⁶

Aggarwal et al. revealed a relationship between ACL and posterior cruciate ligaments (PCL) in OA by histological examination and mentioned that ACL degeneration was often correlated to the degeneration of PCL, even when the PCL was macroscopically intact.⁷ However, it has been unknown what the microscopic condition of the PCL may be in mucoid degeneration of the ACL.

Identically, we have a few reports about the mucoid degeneration of PCL^{8,9}, but it has been unknown what the microscopic condition of the ACL, because they didn't have a histologic evaluation. We couldn't find any previous reports on mucoid degeneration of both cruciate ligaments macroscopically or microscopically. We hereby report 2 cases of PS TKA patients with OA and symptomatic mucoid degeneration of the ACL in whom histologic survey later revealed mucoid degeneration of their PCL.

Case presentation

Case 1

A 68-year-old male had an open wedge high tibial osteotomy for the right medial knee OA 5 years ago. He could gain pain relief, and his active knee range of motion was -5° for extension and 130° for flexion after the operation. But 5 years later, he presented with a 2-month history of right posterior and medial knee pain during terminal knee flexion and long walking. His active knee range of motion was -15° for extension and 115° for terminal flexion with pain. No ligament antero-posterior instability of the knee was identified by the Lachman, and anterior/posterior drawer tests. Plain radiograph showed medial OA Kellgren-Lawrence grade 3,¹⁰ but no rapid progression in comparison with three months earlier. MRI demonstrated intermediate signal in T1-weighted and

^{*} Corresponding author. 438 Miyakami, Yugawara, Kanagawa 259-0396, Japan.
E-mail address: kkohei0602@yahoo.co.jp (K. Kawaguchi).

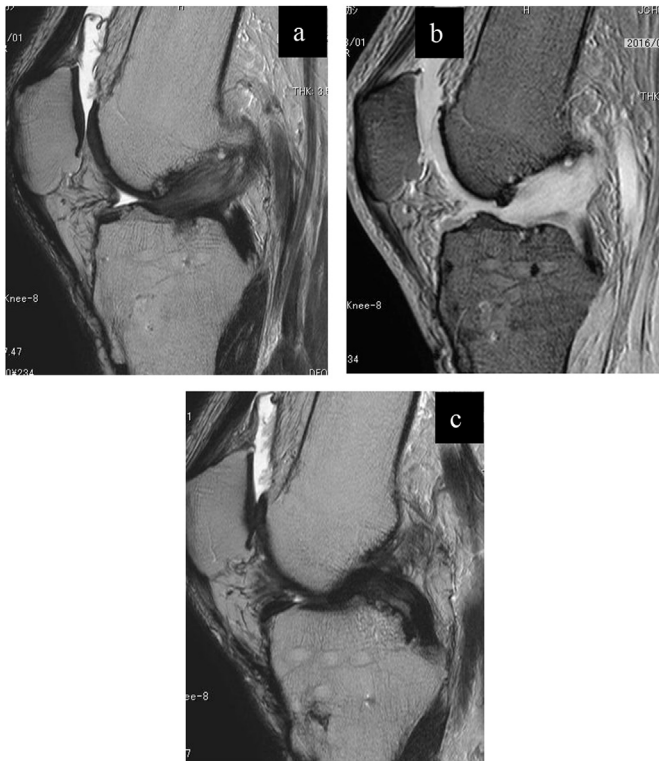

Fig. 1. T1WI Sagittal (a) and T2WI fat-suppressed Sagittal (b) show increased intraligamentous signal intensity of the bulky anterior cruciate ligament (ACL) with intact ACL fiber. T2WI Sagittal (C): The posterior cruciate ligament (PCL) appears intact.

increased signal in T2-weighted images diffuse within the ACL so-called “celery stalk” sign,³ but no typical mucoid change within the PCL (Fig. 1a–c). We decided to perform a posterior-stabilized (PS), because both medial OA and mucoid degeneration were the causes of pain. We assumed that the medial knee pain was from OA; and posterior knee pain and its acute limited range of motion were from the mucoid degeneration. The surgical findings showed that both cruciate ligaments were thickened without synovial coverage and discolored with yellowish substance. PS TKA was performed with Vanguard PS (Zimmerbiomet Warsaw USA) as the preoperative planning. Histologic examination revealed loose fibrocollagenous tendinous tissue containing fibrin deposit and myxedematous changes indicative of mucoid degeneration in both cruciate ligaments (Fig. 2a–e).

Three weeks after the operation, knee active range of motion was improved to -5° for extension and 120° for flexion, and additionally medial and posterior knee pain had disappeared. At 1 year after the operation, the patient had gained complete pain relief and improvement of Knee Society Score (KSS) from 45 in preoperatively to 95.

Case 2

A 78-year-old female had suffered from a left knee medial pain for several years because of medial knee OA. Two months ago, her left knee pain worsened from not only at the medial but also at the posterior, and she experienced increased difficulty in knee flexion and extension. Her knee active range of motion was -10° for extension and 75° for terminal flexion with pain. No ligamentous antero-posterior instability was identified. Plain radiograph showed medial OA Kellgren-Lawrence grade 3¹⁰ and no rapid progression

in comparison with three months ago. The MRI demonstrated mucoid degeneration of ACL like Case 1, but no clearly mucoid change within the PCL (Fig. 3a–c). We decided to perform PS TKA, because we had to treat the ACL mucoid degeneration and medial OA to gain a complete pain relief. The surgical findings showed that both cruciate ligaments were thickened without synovial coverage and discolored with yellowish substance. PS TKA was performed with Vanguard PS sacrificing both cruciate ligaments. Histologic examination revealed a loose fibrocollagenous tendinous tissue containing fibrin deposit and myxedematous changes indicative of mucoid degeneration of both cruciate ligaments, the same as in Case 1 (Fig. 4a and b).

Three weeks after the operation, active knee range of motion had improved to -5° for extension and 120° for flexion, and additionally medial and posterior knee pain had disappeared. At 1 year after the operation, the patient had gained complete pain relief and improvement of KSS score from 48 in preoperatively to 95.

After being informed that their data would be submitted for publication, both patients provided their consent. This report was granted ethical approval for publication.

Discussion

The most important finding in this report was that the mucoid degeneration in the ACL with OA histologically expanded to the PCL, which appeared to be almost intact radiologically preoperatively in our 2 cases.

In our 261 cases over the past two years, we suspected only two cases which had a ACL mucoid degeneration with OA from clinical and radiological findings before surgery. There were no cases which were suspected only of PCL mucoid degeneration with OA from radiological findings. In general, mucoid degeneration of cruciate ligaments is rare. Bergin et al. performed a retrospective study on 4221 consecutive knees referred for MRI which they screened systematically for ACL mucoid lesions, and they found only 74 (1.8%) knees.² In our facility, a frequency of ACL mucoid degeneration with OA was not so higher compared to other reports. But if we ignore its existence, we couldn't have good postoperative clinical outcomes in TKA retaining mucoid degenerated ligaments.

Mucoid degeneration of cruciate ligaments should be diagnosed by a combination of MRI, clinical and histological findings.¹¹ But Fernandez et al. diagnosed mucoid degeneration only by MRI. Their MRI criteria consist of diffusely thickened cruciate ligaments in which intact fibers are spread apart by a material with signal intensity-low to intermediate in T1-weighted images and intermediate to high in T2-weighted images, always higher than the expected signal for a given sequence (the so-called “celery stalk” pattern).³ In our two cases, while both ACL met the mucoid criteria on MRI, neither PCL met the criteria. However surgical and histological findings showed a mucoid generation of PCL in both cases. In previous reports, there were no histological examinations of the other cruciate ligament in case of either mucoid cruciate ligament degeneration. There have been only reports in which mucoid degeneration existed only isolated to the ACL or PCL.^{1–5,9,11,12} Additionally, the cruciate ligament might appear normal macroscopically, this did not always correlate with histological integrity,^{13,14} and Aggarwal et al. mentioned that degenerated ACL correlated positively with PCL histological degeneration.⁷ Therefore we hypothesized that ACL mucoid degeneration related to PCL mucoid degeneration to some extent. Wang et al. mentioned that knee extension pain was related to an impingement between mucoid PCL and ACL¹⁵. In our two cases, we could observe the impingement between thickened ACL and PCL. The PCL could be degenerated

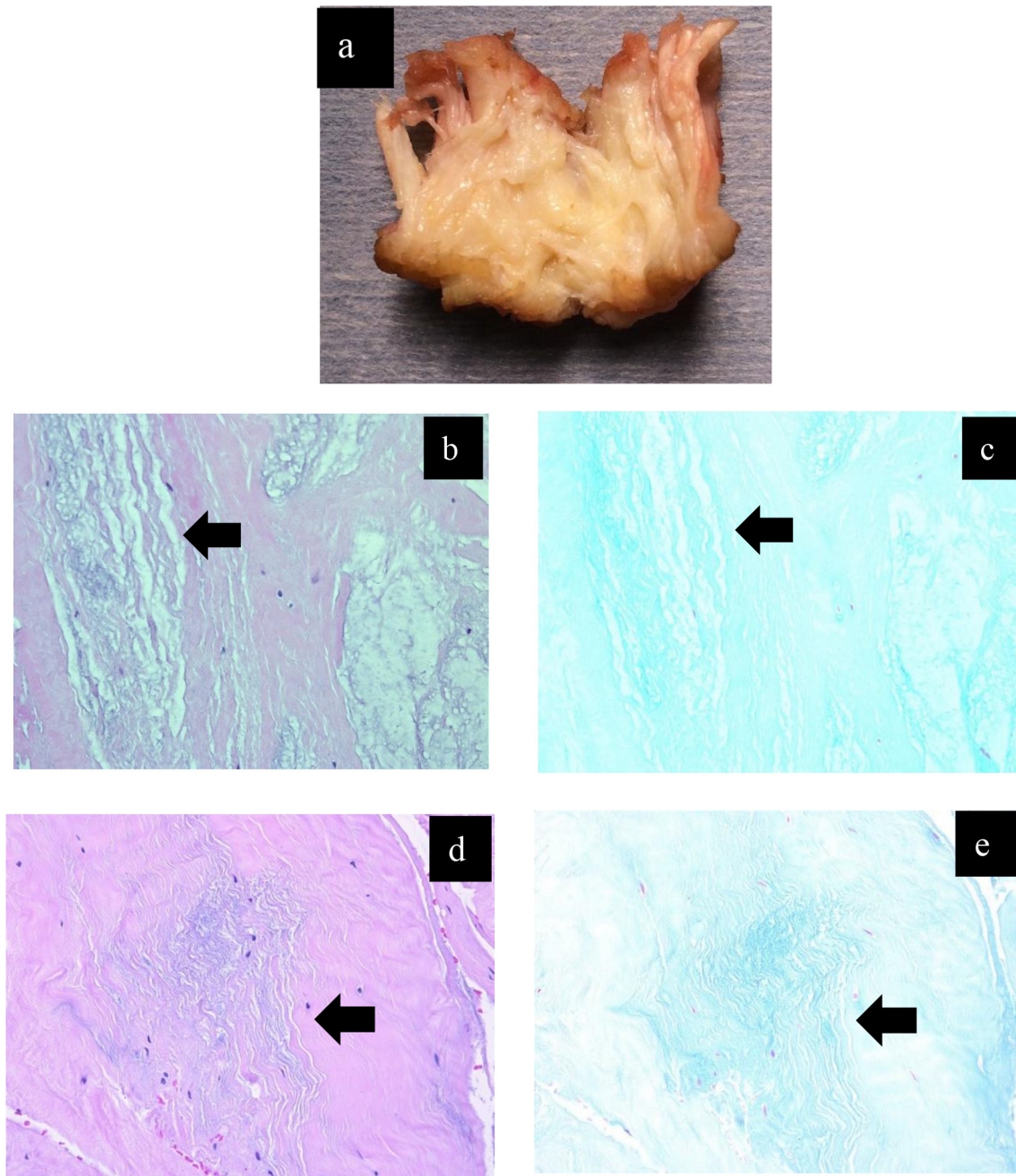


Fig. 2. Macroscopic view of anterior cruciate ligament (ACL) that was longitudinally cut showed yellow degenerative tissue among ACL fibers (a). Histological evaluation of ACL with hematoxylin and eosin (b) and allucian blue (c) Black arrow showing distorted collagen fibers with multifocal mucoid degeneration. Histological evaluation of posterior cruciate ligament (PCL) with hematoxylin and eosin (d) and allucian blue (e) Black arrow showing mucoid change same as ACL.

because of mechanical irritation with the mucoid ACL. Additionally, they had posterior knee pain and knee flexion and extension pain, the pain may be due to an impingement between thickened and mucoid degenerated cruciate ligaments, therefore the pain disappeared after the surgery.

Currently, there is only one case report in the literature about OA with a mucoid degeneration of the cruciate ligaments.⁵ Needless to say there is no consensus about its treatment. Standard treatment for ACL or PCL mucoid degeneration without OA is arthroscopic partial excision of the cruciate ligament.¹² But the resection can be partial or complete,^{1,4,11} when the lesion concerns the whole ACL,

from tibial to femoral insertion and both bundles. Adhesions between the ACL and PCL or the impingement are also released. There is no evidence in the literature of any recurrence after treatment of mucoid degeneration by incomplete resection of the ACL. In our two cases, both patients had a medial OA for several years, and they had clinical symptoms of both OA and ACL mucoid degeneration. Accordingly, we decided to perform PS TKA as the treatment for both medial OA and ACL mucoid degeneration to gain complete pain relief, therefore we concerned about the postoperative ligament instability and abnormal kinematics due to remained degenerated mucoid PCL. For the TKA, we chose the PS type

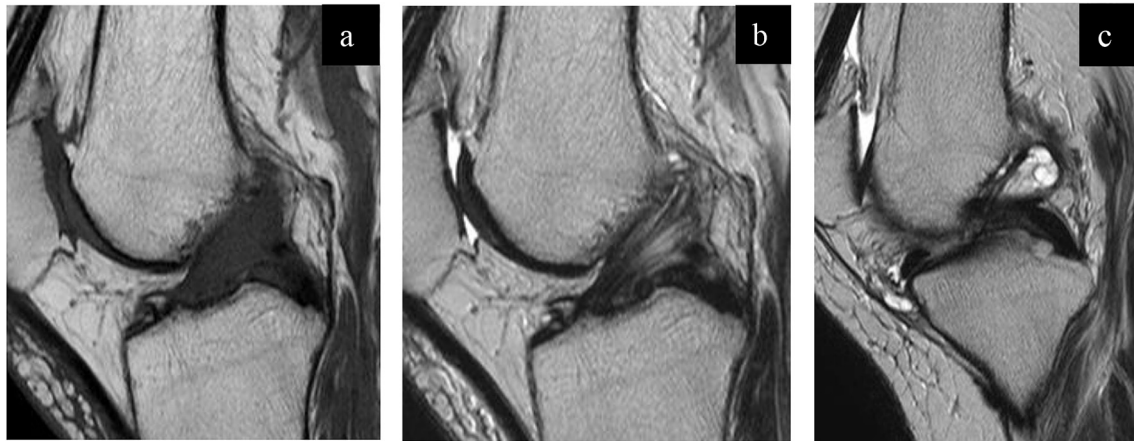


Fig. 3. T1WI Sagittal (a) and T2WI fat-suppressed Sagittal (b) show increased intraligamentous signal intensity of the bulky anterior cruciate ligament (ACL) with intact ACL fiber. T2WI Sagittal (c) shows intact posterior cruciate ligament (PCL) with a ganglion cyst originating from ACL.

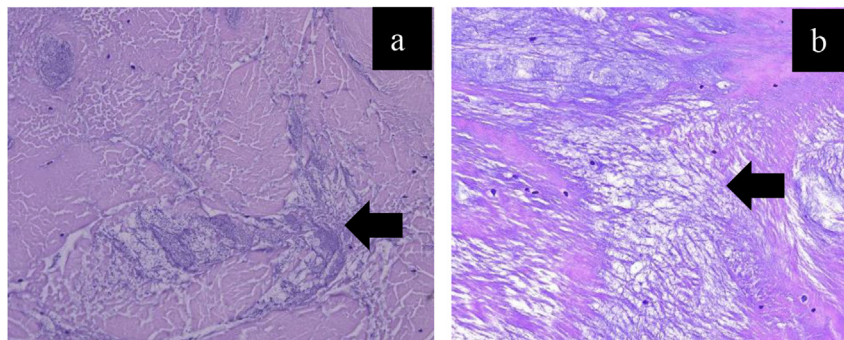


Fig. 4. Histological evaluation of anterior cruciate ligament (ACL) (a) and posterior cruciate ligament (PCL) (b) with hematoxylin and eosin. Black arrow showing distorted collagen fibers with multifocal mucoid degeneration.

sacrificing both cruciate ligaments, so there was no need to consider longevity and strength of the mucoid degenerated cruciate ligaments. But an additional randomized comparative study confirming our theory seems to be difficult, because of its ethical reason.

Conclusion

In cases of osteoarthritis with mucoid degenerated ACL, even where the PCL might be almost negative on radiographic evaluation, PS TKA should be considered, sacrificing both cruciate ligaments, because mucoid degeneration may extend to both cruciate ligaments.

Conflicts of interest

No benefit in any form has been received or will be received from a commercial party related directly to the subject of this article.

References

1. Kumar A, Bickerstaff DR, Grimwood JS, Suvarna SK. Mucoid cystic degeneration of the cruciate ligament. *J Bone Joint Surg.* 1999;81:304–305.
2. Bergin D, Morrison WB, Carrino JA, Nallamshetty SN, Bartolozzi AR. Anterior cruciate ligament ganglia and mucoid degeneration: coexistence and clinical correlation. *AJR Am J Roentgenol.* 2004;182:1283–1287.
3. Fernandes JL, Viana SL, Mendonça JL, et al. Mucoid degeneration of the anterior

4. Narvekar A, Gajjar S. Mucoid degeneration of the anterior cruciate ligament. *Arthroscopy.* 2004;20:141–146.
5. Kim TH, Lee DH, Lee SH, Kim JM, Kim CW, Bin SI. Arthroscopic treatment of mucoid hypertrophy of the anterior cruciate ligament. *Arthroscopy.* 2008;24:642–649.
6. Matsuda S, Kawahara S, Okazaki K, Tashiro Y, Iwamoto Y. Postoperative alignment and ROM affect patient satisfaction after TKA. *Clin Orthop Relat Res.* 2013;471:127–133.
7. Aggarwal AK, Goel A, Radotra BD. Predictors of posterior cruciate ligament degeneration in osteoarthritic knees. *J Orthop Surg.* 2013;21:15–18.
8. Okazaki K, Deguchi S, Katai K, Iwamoto Y. Mucoid degeneration of the posterior cruciate ligament: a case report. *Knee Surg Sports Traumatol Arthrosc.* 2011;19:105–107.
9. Shoji T, Fujimoto E, Sasashige Y. Mucoid degeneration of the posterior cruciate ligament: a case report. *Knee Surg Sports Traumatol Arthrosc.* 2010;18:130–133.
10. Kellgren JH, Lawrence JS. Radiological assessment of osteoarthritis. *Ann Rheum Dis.* 1957;157(16):494–502.
11. Lintz F, Pujol N, Boisrenoult P, Bargoin K, Beaufile P, Dejour D. Anterior cruciate ligament mucoid degeneration: a review of the literature and management guidelines. *Knee Surg Sports Traumatol Arthrosc.* 2011;19:1326–1333.
12. Cha JR, Lee CC, Cho SD, Youm YS, Jung KH. Symptomatic mucoid degeneration of the anterior cruciate ligament. *Knee Surg Sports Traumatol Arthrosc.* 2013;21:658–663.
13. Mont MA, Elmallah RK, Cherian JJ, Banerjee S, Kapadia BH. Histopathological evaluation of the anterior cruciate ligament in patients undergoing primary total knee arthroplasty. *J Arthroplasty.* 2016;31:284–289.
14. Kleinbart FA, Bryk E, Evangelista J, Scott WN, Vigorita VJ. Histological comparison of posterior cruciate ligaments from arthritic and age-matched knee. *J Arthroplasty.* 1996;11:726–731.
15. Wang JH, Jangir RR. Mucoid degeneration of posterior cruciate ligament with secondary impingement of anterior cruciate ligament: a rare case report. *J Orthop Case Rep.* 2015;5:44–46.