



Contents lists available at ScienceDirect

International Journal of Surgery Case Reports

journal homepage: www.casereports.comTerrible triad of the hip: A case report[☆]Hussain Alyousif, Hasan Aleisawi^{*}, Hussain Alkaff, Nora Albusayes

Department of Orthopedic Surgery, King Saud Medical City, Riyadh, Saudi Arabia

ARTICLE INFO

Article history:

Received 7 February 2021

Received in revised form 6 March 2021

Accepted 7 March 2021

Available online 14 March 2021

Keywords:

Closed reduction

Femoral head fracture-dislocation

Iatrogenic femoral neck fracture

Irreducible hip dislocation

Pipkin type-III

ABSTRACT

INTRODUCTION: Pipkin-III femoral head fracture dislocation is a rare injury and its outcome is guarded. Some authors believe femoral neck fracture of Pipkin-III injury is largely iatrogenic. Recent literature showed none of these injuries had excellent outcome, and most patients end up with hip replacement.

PRESENTATION OF CASE: A 34-year-old man sustained a traumatic hip injury with fracture-dislocation and an iatrogenic femoral neck fracture during reduction. A modified Gibson approach was performed to reduce and fix the femoral head and neck fractures in a retrograde fashion. Follow-up at 26 months assessment showed viable femoral head, and excellent functional outcome.

DISCUSSION: Iatrogenic femoral neck fracture in the setting of femoral head dislocation is not uncommon. Clinical and radiological signs of irreducible dislocation can easily be missed which might lead to devastating complications like iatrogenic femoral neck fracture. Recognition of this unique injury, timely intervention, and meticulous dissection might positively alter the patient's outcome.

CONCLUSION: This case serves to enlighten orthopedists about the risk of iatrogenic femoral neck fracture, methods to avoid such complication, and the proper management.

© 2021 The Author(s). Published by Elsevier Ltd on behalf of IJS Publishing Group Ltd. This is an open access article under the CC BY-NC-ND license (<http://creativecommons.org/licenses/by-nc-nd/4.0/>).

1. Introduction

Only 5–15% of posterior hip dislocations are accompanied by a femoral head fracture [1,2]. In addition to hip dislocation, the combination of a femoral head and neck fracture is classified as type-III femoral head fracture-dislocation according to the Pipkin classification [3]. This injury pattern is the least common femoral head injury pattern reported in the literature, and its outcome has been reported to be poor, with the majority of cases requiring total hip replacement (THR) [4–6].

Recently, only a few researchers have explored and documented the occurrence of femoral neck fractures after closed reduction (CR) for Pipkin type-I and type-II fractures. Unfortunately, due to the rarity of such injuries, recommendations for treatment cannot be made; there are few relevant studies, and the existing studies have short follow-up periods [7–9].

This case report describes the pitfalls that we encountered when dealing with the case in the emergency department (ED), the surgical treatment, and the outcome. The work has been reported in line with the SCARE 2020 criteria [10].

2. Case report

A 34-year-old male sustained a traumatic right hip injury as a result of a motor vehicle accident. When he was first evaluated in the ED, the lower limb was flexed and internally rotated. The motor and sensory examination findings were normal. The radiographs and CT scans demonstrated right hip posterior dislocation accompanied by a Pipkin type-I femoral head fracture with impaction of femoral head (Fig. 1A–C). CR under conscious sedation was performed in the ED. An audible “crack” was heard and felt by the senior orthopedic physician. Then, the procedure was terminated, and new radiographs were obtained; the images showed an iatrogenic femoral neck fracture in addition to the previously recognized femoral head fracture-dislocation (Pipkin type-III) (Fig. 2). Due to the complexity of the injury, care was transferred to an orthopedic traumatologist.

After clinical and radiological evaluations, the patient was brought to the operating room within 8 h of the injury for open reduction internal fixation (ORIF). He was placed in a lateral decubitus position on a radiolucent table with access for C-arm imaging. The surgeon decided to use a modified Gibson approach [11]. The suprafoveal piece of the femoral head and femoral neck were found to be buttonholed posteriorly at the capsulo-labral junction, with the remaining capsule partially torn. The fragment was gently freed from the capsulo-labral tissue, without extending the buttonhole or further injuring the femoral head. The lower limb was then manipulated to visualize the hip joint. The infrafoveal piece of the femoral head was retrieved from the hip joint. Visualization of the femoral

[☆] Investigation performed at King Saud Medical City, Riyadh, Saudi Arabia.

^{*} Corresponding author at: Department of Orthopedic Surgery, King Saud Medical City, Riyadh, 12746, Saudi Arabia.

E-mail address: alanazihasan@gmail.com (H. Aleisawi).

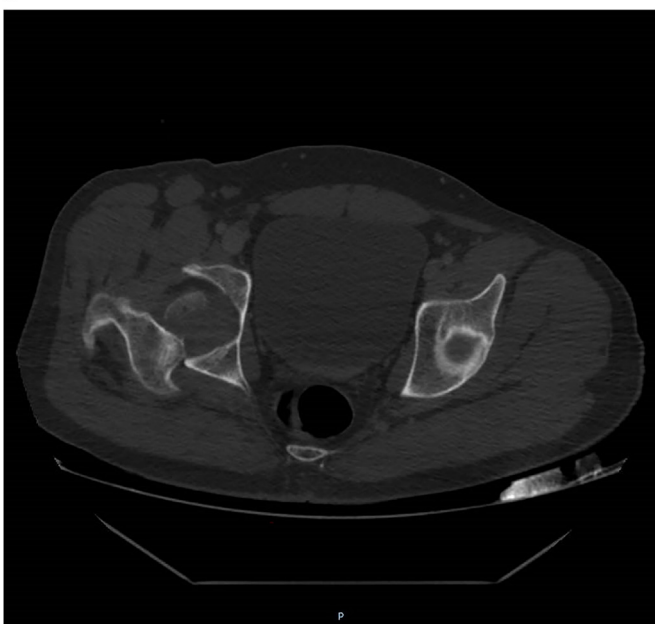
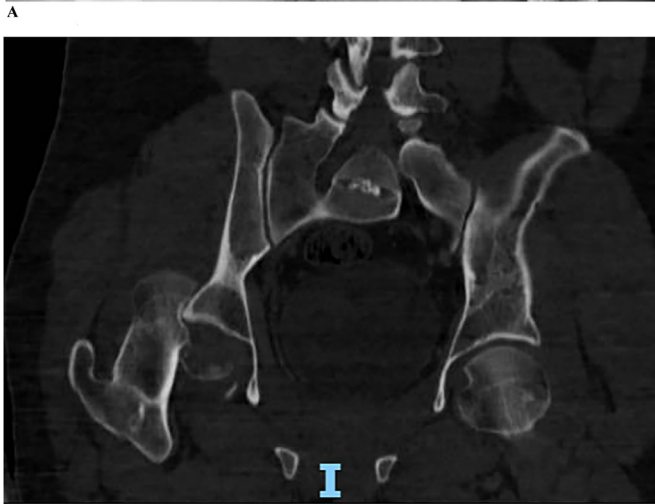
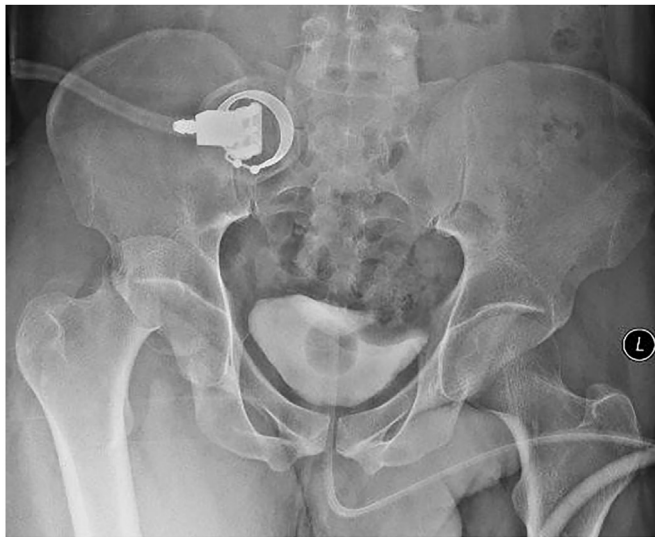
Fig. 1. A. Anteroposterior radiograph of the pelvis demonstrating a posterior dislocation of the right hip and a femoral head fracture. The infrafoveal piece of the femoral head is retained in the acetabulum. B. Coronal CT demonstrating impaction, and perching of the femoral head on the edge of the acetabulum. C. Axial CT demonstrating perching of the femoral head on the edge of the acetabulum, and the retained infrafoveal of femoral head in the acetabulum.

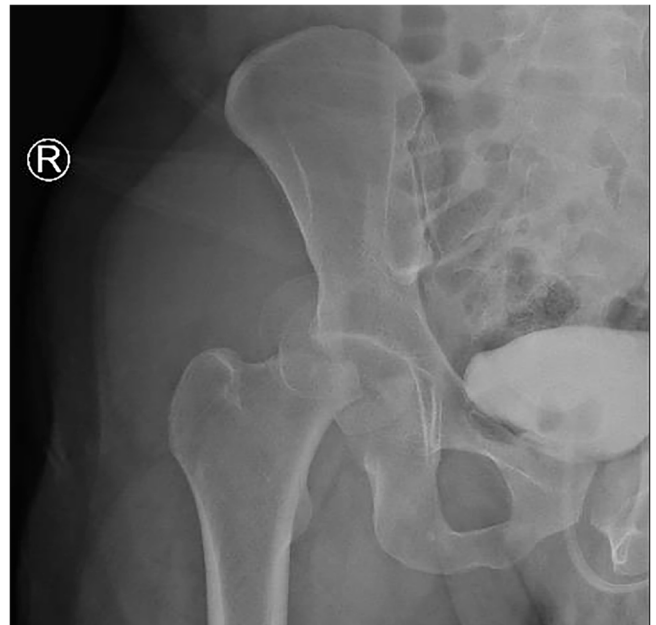


Fig. 2. Anteroposterior radiograph of the pelvis after closed reduction attempted. In addition to the hip dislocation and femoral head fracture, a new fracture line through the neck is clear.

neck was limited; however, that of the femoral head was clear. Therefore, reduction of the femoral head fragments was attempted first. The two pieces of the femoral head were debrided to remove clots, reduced toward each other, and provisionally fixed with k-wires. Three cannulated, partially threaded 2.0 mm headless screws were used to fix the femoral head component (Fig. 3A). The femoral head was then reduced toward the femoral neck. Then, attention was shifted to the femoral neck fracture component. The femoral neck was provisionally fixed with k-wires in a retrograde fashion, passing from the femoral head through the neck, and were pulled through the lateral skin of the thigh. K-wires were positioned appropriately under the subchondral bone. The hip joint was reduced. Posterior capsule was repaired. Layered closure of the wound was performed in a standard fashion. Then, the patient was positioned supine. Utilizing the percutaneous technique, the lengths of the guide wires were measured. The neck fracture was fixed in a typical manner using three cannulated, partially threaded 7.3 mm screws in an inverted triangle (Fig. 3B). The procedure was performed by the senior author (Alyousif).

Postoperatively, deep vein thrombosis prophylaxis was administered, and the patient was encouraged to perform toe-touch weight-bearing for 12 weeks. Heterotopic ossification (HO) prophylaxis was not administered. At six weeks, the patient stated that he had been bearing full weight on the injured hip and did not adhere to our instructions; however, there were no signs of infection, and the radiographs showed anatomic reduction and no evidence of osteonecrosis (Fig. 4A). At fifteen months, the patient was able to walk pain-free with only minimal and occasional pain every 2–3 weeks after prolonged walking. The radiographs showed minimal subchondral lucency of the femoral head without collapse or arthritic changes (Fig. 4B). The patient was informed about the findings, and he was monitored closely. At 26 months, he presented to our clinic for an evaluation. The patient was happy about the outcome, and resumed his work duty 6 months after the injury. The clinical examination showed full range of motion of the involved right hip compared to the normal left hip with no antalgic gait. The radiological evaluation showed good bony healing with a viable

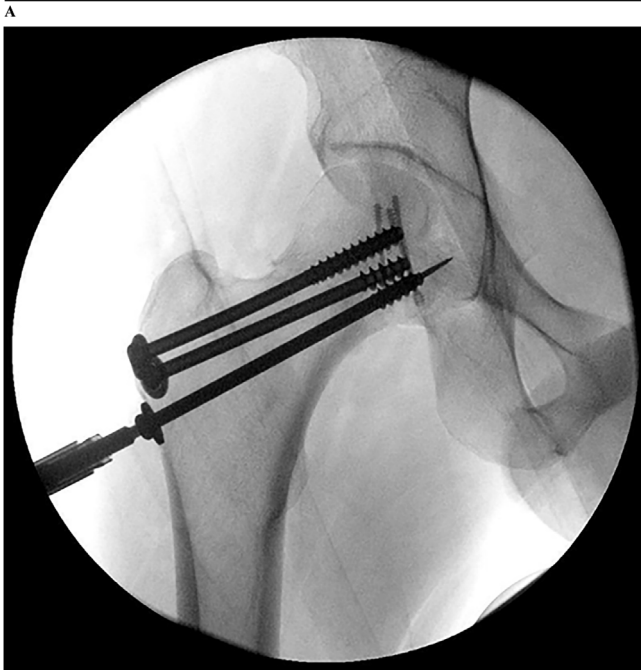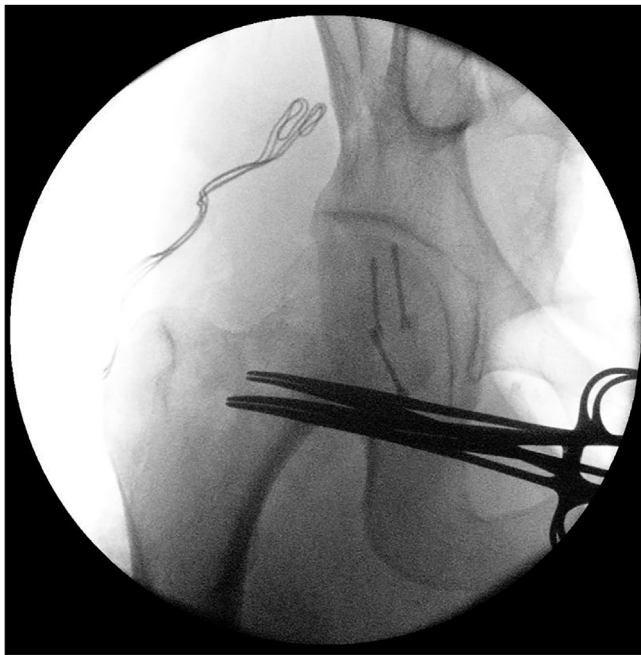


Fig. 3. A. Intraoperative anteroposterior radiograph of the hip demonstrating femoral head fixation. B. Intraoperative anteroposterior radiograph of the hip demonstrating femoral neck fixation.

femoral head and no evidence of arthritis or HO (Fig. 5A, and B). The Harris hip score was 92, indicating an excellent outcome [12].

3. Discussion

The best management strategy for femoral head fracture-dislocation remains controversial largely due to the rarity of this type of injury, the small number of cases reported in the literature, and the uncertainty of the prognosis [4–6,13]. The high energy imparted at the femoral head, damage to the vascular system supplying the femoral head, and prolonged hip dislocation are significant factors that lead to AVN. Therefore, urgent CR is thought to be paramount to save the femoral head from a catastrophic out-

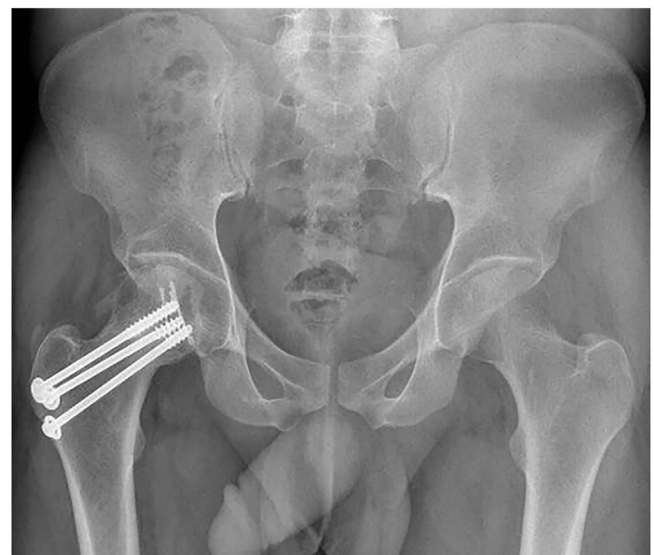
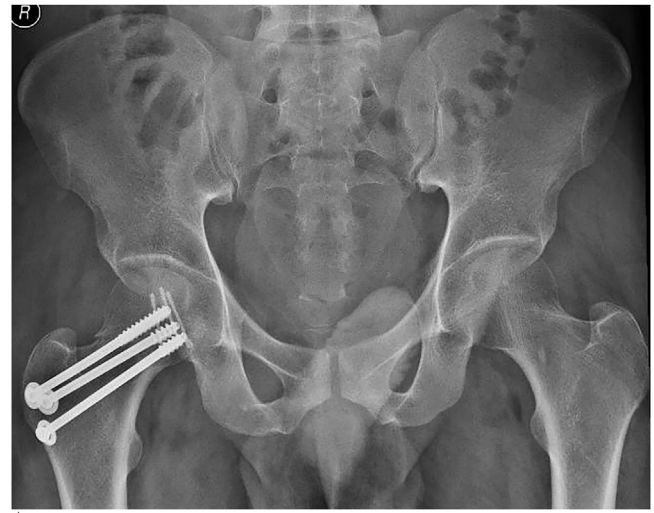
Fig. 4. A. Anteroposterior radiograph of the pelvis at 6 weeks postoperatively. B. Anteroposterior radiograph of the pelvis at 15 months postoperatively showing subchondral lucency without joint changes.

come [14]. Irreducible femoral head fracture-dislocation is a unique type of posterior hip dislocation accounting for 9% of all hip dislocations and unfortunately poses therapeutic challenges [7]. According to the literature, the irreducibility of hip dislocations is still unrecognized to a large extent, and iatrogenic femoral neck fractures is a major concern [9]. A systematic review of 301 femoral head fractures reported in 17 articles and found that only 26 (8.6%) had this injury pattern [4].

It has been reported that the presence of a slightly flexed hip in neutral or internal rotation with an element of immobility might be a sign of an irreducible hip [7]. It is true that immobility indicates “fixed” dislocation; however, the amount of internal rotation or flexion is dependent on multiple variables and cannot be a sensitive indicator of fixed dislocation. Radiologically, the presence of femoral head fracture-dislocation with subtle overlap of the head on the edge of the acetabulum should indicate to orthopedic physicians that the dislocation is irreducible which was missed by the orthopedic surgeon in the present case [7,9]. Consequently, attempting CR without thorough clinical or radiological evaluations might put the patient at undue risk of iatrogenic femoral neck fractures. CT scans might reveal perching of the femoral head fracture

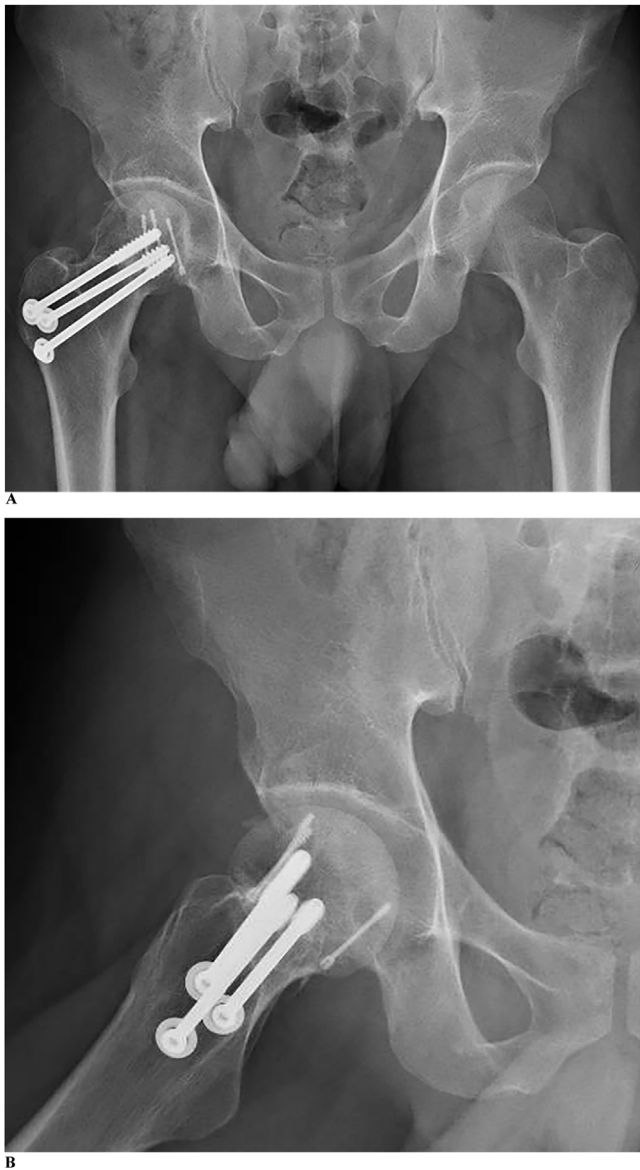


Fig. 5. A. Anteroposterior radiograph of the pelvis at 26 months postoperatively. B. Lateral radiograph of the right hip at 26 months postoperatively.

with impaction of the cancellous bone on the edge of the acetabulum [7,9]. In the presence of these clinical and radiological signs, attempts of CR must not be done in ED, and the threshold for open reduction should be very low, as a significant number of type-III Pipkin injuries are in fact iatrogenic in nature [9].

AVN of the femoral head is one of the most severe complications following femoral head or neck fractures. AVN usually occurs within two years but it can happen beyond that [15]. The overall rate of AVN is 11.8% [4]. The coexistence of femoral neck and head fractures is a devastating injury with dual insults to the proximal femur, resulting in poor outcomes [1,3,16]. Thus, we have chosen the term “terrible triad of the hip” for such a unique injury with poor outcomes. Of note, Giannoudis et al. performed a systematic review and found that 50% of Pipkin type-III injuries had either fair or poor outcomes; however, none had excellent outcomes [4]. Park et al. reported 5 cases of iatrogenic femoral neck fractures with femoral head fracture-dislocation. Eventually, all patients needed THR due to AVN [9]. Furthermore, Scolaro et al. reported 13 cases of type-III Pipkin fractures managed primarily with ORIF. All cases developed complications and required THR as a definitive proce-

dure [6]. These reports and others suggest that a Pipkin type-III fracture is a predictor of THR, regardless of patient age [6,13,16,17].

We are the first to report a case of femoral head fracture-dislocation with an iatrogenic femoral neck fracture with excellent radiologic and functional outcomes after ORIF. The patient was followed up for a total of 26 months and did not show any collapse or arthritic changes. The outcome might be attributed to multiple factors, which are the timely and emergent treatment of fracture-dislocation, limited operative dissection of the posterior capsule, and anatomic reduction of femoral head and neck fractures. Although the patient reported taking Fenugreek seeds as a traditional therapy, and these seeds have been reported to have a possible positive effect on bone in animal studies, evidence is lacking about its uses in orthopedic surgery [18].

Currently, there are no clear guidelines about the proper management of such rare conditions in the literature. The loss of the integrity of the posterior capsule might reflect injury to the femoral head blood supply, but it is not confirmatory, and it is difficult to base the treatment on this finding alone, particularly in young patients [13]. Therefore, ORIF might prove beneficial. We strongly suggest obtaining CT scans pre-reduction in questionable cases and thoroughly evaluating the injury for signs of irreducible dislocation. Although such a strategy might delay CR attempts, in the modern era, such an investigation is performed in a few minutes and can alter the treatment strategy. In cases in which irreducibility has been confirmed by imaging studies, we believe that CR must be done by an expert surgeon, in the operating theatre under general anesthesia with muscle relaxants, and one must be prepared to perform open reduction if difficulty was encountered during the CR procedure.

Declaration of Competing Interest

The authors report no declarations of interest.

Funding

The authors did not use any funding from any source.

Ethical approval

The study is exempted from ethical approval.

Consent

Written informed consent was obtained from the patient for publication of this case report and accompanying images. A copy of the written consent is available for review by the Editor-in-Chief of this journal on request.

Author contribution

Dr. Hussain Alyousif: Performed the procedure, literature review, writing - original draft.

Dr. Hasan Aleisawi: interview, literature review, case description and discussion, writing - review & editing.

Dr. Hussain Alkaf: literature review, case description and discussion, resources, writing - original draft.

Dr. Nora Albusayes: literature review, case description and discussion, resources, writing - original draft.

All authors read and approved the final manuscript.

Registration of research studies

Not applicable.

Guarantor

Dr. Hussain Alyousif.
Dr. Hasan Aleisawi.

Provenance and peer review

Not commissioned, externally peer-reviewed.

References

- [1] L.F.J.R. Roeder, J.C. Delee, Femoral head fractures associated with posterior hip dislocations, *Clin. Orthop. Relat. Res.* 147 (1980).
- [2] J.P. Stannard, H.W. Harris, D.A. Volgas, J.E. Alonso, Functional outcome of patients with femoral head fractures associated with hip dislocations, *Clin. Orthop. Relat. Res.* 377 (2000).
- [3] G. Pipkin, Treatment of grade IV fracture-dislocation of the hip: a review, *JBJS* 39 (1957).
- [4] P.V. Giannoudis, G. Kontakis, Z. Christoforakis, M. Akula, T. Tosounidis, C. Koutras, Management, complications and clinical results of femoral head fractures, *Injury* 40 (2009) 1245–1251, <http://dx.doi.org/10.1016/j.injury.2009.10.024>.
- [5] M. Koerner, J. Westberg, J. Martin, D. Templeman, Patient-reported outcomes of femoral head fractures with a minimum 10-year follow-up, *J. Orthop. Trauma* 34 (2020) 621–625, <http://dx.doi.org/10.1097/bot.0000000000001880>.
- [6] J.A. Scolaro, G. Marecek, R. Firoozabadi, J.C. Krieg, M.L. “Chip” Routh, Management and radiographic outcomes of femoral head fractures, *J. Orthop. Traumatol.* 18 (2017) 235–241, <http://dx.doi.org/10.1007/s10195-017-0445-z>.
- [7] S. Mehta, M.L.C. Routh, Irreducible fracture-dislocations of the femoral head without posterior wall acetabular fractures, *J. Orthop. Trauma* 22 (2008) 686–692, <http://dx.doi.org/10.1097/BOT.0b013e31818e2a86>.
- [8] T. Snoap, J. Freyder, J. Roberts, Management of a combined femoral head and neck fracture: a case report, *JBJS Case Connect.* 6 (2016), <http://dx.doi.org/10.2106/JBJS.CC.16.00066>.
- [9] K.H. Park, J.W. Kim, C.W. Oh, J.W. Kim, J.K. Oh, H.S. Kyung, A treatment strategy to avoid iatrogenic Pipkin type III femoral head fracture–dislocations, *Arch. Orthop. Trauma Surg.* 136 (2016) 1107–1113, <http://dx.doi.org/10.1007/s00402-016-2481-1>.
- [10] R.A. Agha, T. Franchi, C. Sohrabi, G. Mathew, A. Kerwan, A. Thoma, et al., The SCARE 2020 guideline: updating consensus surgical CASE REport (SCARE) guidelines, *Int. J. Surg.* 84 (2020) 226–230, <http://dx.doi.org/10.1016/j.ijsu.2020.10.034>.
- [11] B.R. Moed, The modified gibson posterior surgical approach to the acetabulum, *J. Orthop. Trauma* 24 (2010) 315–322, <http://dx.doi.org/10.1097/BOT.0b013e3181c4aef8>.
- [12] N.N. Mahomed, D.C. Arndt, B.J. McGrory, W.H. Harris, The Harris hip score: comparison of patient self-report with surgeon assessment, *J. Arthroplasty* 16 (2001) 575–580, <http://dx.doi.org/10.1054/arth.2001.23716>.
- [13] T. Tosounidis, J. Aderinto, P.V. Giannoudis, Pipkin Type-III fractures of the femoral head: fix it or replace it? *Injury* 48 (2017) 2375–2378, <http://dx.doi.org/10.1016/j.injury.2017.10.002>.
- [14] J.J. Yue, J.H. Wilber, J.P. Lipuma, A. Murthi, J.R. Carter, R.E. Marcus, R. Valentz, Posterior hip dislocations: a cadaveric angiographic study, *J. Orthop. Trauma* 10 (1996) 447–454, <http://dx.doi.org/10.1097/00005131-199610000-00001>.
- [15] P. Tornetta, H.R. Mostafavi, Hip dislocation: current treatment regimens, *J. Am. Acad. Orthop. Surg.* 5 (1997) 27–36, <http://dx.doi.org/10.5435/00124635-199701000-00004>.
- [16] K.E. Dreinhöfer, S.R. Schwarzkopf, N.P. Haas, H. Tscherne, Femur head dislocation fractures. Long-term outcome of conservative and surgical therapy, *Unfallchirurg* 99 (1996) 400–409.
- [17] X. Yu, Q.J. Pang, X.J. Chen, Clinical results of femoral head fracture-dislocation treated according to the Pipkin classification, *Pakistan J. Med. Sci.* 33 (2017) 650–653, <http://dx.doi.org/10.12669/pjms.333.12633>.
- [18] J. Folwarczna, M. Zych, B. Nowińska, M. Pytlik, M. Bialik, A. Jagusiak, M. Lipecka-Karcz, M. Matysiak, Effect of diosgenin, a steroidal sapogenin, on the rat skeletal system, *Acta Biochim. Pol.* 63 (2016) 287–295, <http://dx.doi.org/10.18388/abp.2015.1095>.

Not commissioned, externally peer-reviewed.

Open Access

This article is published Open Access at [sciencedirect.com](https://www.sciencedirect.com). It is distributed under the [IJSCR Supplemental terms and conditions](#), which permits unrestricted non commercial use, distribution, and reproduction in any medium, provided the original authors and source are credited.