

ONCOLOGY / RECONSTRUCTION
MINI-REVIEW

The advantages of the ventral approach to bulbar urethroplasty



Enzo Palminteri ^{a,*}, Elisa Berdondini ^a, Giovanni Battista Di Pierro ^b

^a Center for Urethral and Genitalia Reconstructive Surgery, Arezzo, Italy

^b Department of Obstetrics and Gynecology Sciences and Urologic Sciences, 'La Sapienza' University, Rome, Italy

Received 22 July 2013, Accepted 24 September 2013

Available online 31 October 2013

KEYWORDS

Bulbar urethral strictures;
Urethroplasty;
Approach;
Dorsal;
Ventral

Abstract Background: Several surgical techniques have been described for the treatment of bulbar urethral strictures, and the main goal of modern surgery is to reduce morbidity and obtain the best outcome with the fewest complications. Currently, the superiority of one surgical technique over another has not yet been clearly defined.

Methods: We analysed the historical background, advantages and disadvantages of several urethral approaches and graft placements, with the aim of focusing on the advantages of the ventral approach.

Conclusions: For short bulbar strictures (<2 cm) the traditionally advocated method is excision and end-to-end anastomosis, whilst for longer strictures, in the last decade, the patch graft urethroplasty has been used, with buccal mucosa advocated as the standard material of substitution. Our analysis showed that the approach (dorsal vs. ventral) to the bulbar urethral lumen and the location of the patch (dorsal vs. ventral) are contentious issues. Overall, surgeons tend to use techniques that are easy, quick and give excellent outcomes with few complications. The graft urethroplasty using the ventral approach fulfils these requirements.

© 2013 Production and hosting by Elsevier B.V. on behalf of Arab Association of Urology.

* Corresponding author. Address: Centre for Urethral and Genitalia Reconstructive Surgery, Piazza Guido Monaco 10, Arezzo 52100, Italy. Tel.: +39 3357012783.

E-mail address: enzo.palminteri@inwind.it (E. Palminteri).

Peer review under responsibility of Arab Association of Urology.



Production and hosting by Elsevier

Introduction

Several surgical techniques have been described for the treatment of bulbar urethral strictures, but the goal of modern surgery is to reduce morbidity and obtain the best outcome with fewest complications. Currently, the

superiority of one surgical technique over another has not yet been clearly defined [1,2].

For short bulbar strictures (< 2 cm) the traditionally advocated method is excision and end-to-end anastomosis, whilst for longer strictures, in the last decade, a patch graft urethroplasty has been used, preferably with buccal mucosa as the standard material of substitution [3].

However, over time, transecting procedures had a significant incidence of sexual complications, making the option of grafting techniques valid, even for short non-obliterative strictures [4–6].

Recently, the approach (dorsal vs. ventral) to the bulbar urethral lumen and the location of the patch (dorsal vs. ventral) have become contentious issues, with neither option being clearly better [7,8].

Thus we analysed the historical background, advantages and disadvantages of several urethral approaches and graft placements, with the aim of focusing on the advantages of the ventral approach.

Grafting by the dorsal approach

The dorsal approach allows dorsal grafting; in 1979 Devine et al. [9] popularised the use of free-skin graft techniques in anterior urethral reconstruction. In 1980, Monseur [10] first described a new type of urethroplasty that involved opening of the urethra along its dorsal surface and fixing the opened urethra over the corpora cavernosa, thus allowing the regeneration of the urethral mucosa by leaving a catheter *in situ* for a long time.

In 1996, Barbagli et al. [11] combined the technique of Devine et al. with that of Monseur, and described the first dorsal graft urethroplasty by the dorsal approach (Fig. 1).

Advantages

This technique represented a revolution in urethral surgery and has spread worldwide because it offers the advantage of the graft being splayed, fixed and supported by the corpora. Barbagli [12] stated that dorsal grafting by the dorsal urethrotomy approach offers a wider augmentation than ventral or dorsal grafting using the ventral-urethrotomy approach.

Disadvantages

Later, Barbagli et al. [13] warned that the dorsal access might damage erectile function and the bulbar arteries when the dissection from the corpora needed to be very proximal. Therefore, they recommended this approach only for selected medium or distal bulbar strictures, whilst for the repair of proximal bulbar strictures the ventral approach would seem to be more advisable [8].

Nevertheless, in time, the same authors recognised that the dorsal approach might be simpler in the distal bulbar urethra, whereas the ventral approach with ventral grafting is more effective in the proximal bulbar urethra, where the spongiosum tissue is thick.

Moreover, the dorsal urethral mobilisation was difficult in scarred urethras with marked periurethral fibrosis after previous treatments, and an extensive dorsal dissection could cause urethral ischaemia. For this reason, Kulkarni et al. [14] recently described a modified dorso-lateral approach that preserves one lateral vascular supply to the urethra, by reducing the urethral mobilisation.

In very tight strictures the dorsal approach often mandates a transecting and graft-augmented anastomotic technique, but even with this procedure the problem of vascular damage after a complete urethral transection remains. Moreover, the use of the dorsal

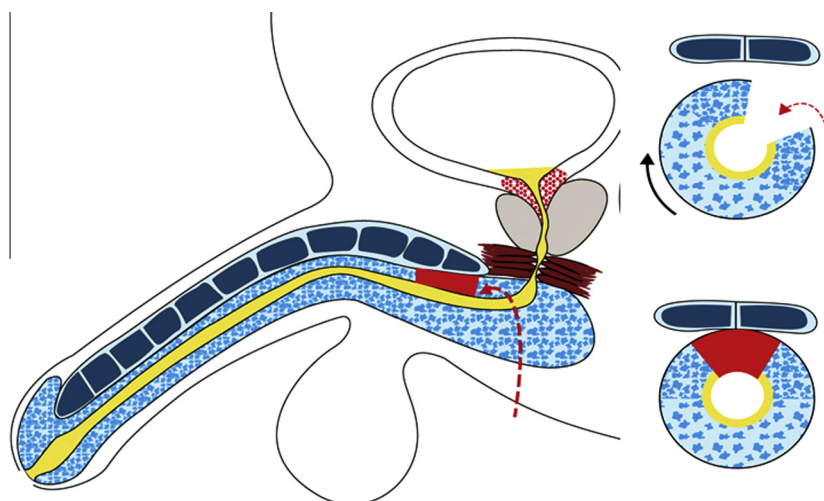


Figure 1 Dorsal graft urethroplasty by the dorsal approach.

approach requires that the surgeon has considerable surgical skill and expertise.

Grafting by the ventral approach

The ventral approach allows dorsal or ventral or dorsal plus ventral grafting. In 1999, for hypospadias surgery, Hayes and Malone [15] suggested a development of the longitudinal incision of the urethral plate described by Snodgrass, by laying an oral mucosal graft into the incised urethral plate. After merging these concepts, in 2001 Asopa et al. [16] popularised a similar technique suitable for the repair of both penile and bulbar strictures, i.e., dorsal grafting by the ventral urethrotomy approach (Fig. 2).

In 1953, Presman and Greenfield [17] introduced the ventral grafting by a ventral approach, and in 1996, this technique was revived by Morey and McAninch [18] (Fig. 3).

Combining the concept of the Asopa dorsal grafting with the Morey and McAninch ventral grafting, in 2008, Palminteri et al. [19] proposed dorsal plus ventral double grafting by the ventral approach, which allows a

sufficient enlargement even in very tight strictures (Fig. 4).

Advantages

The ventral approach is easier, quicker, less aggressive and more versatile than the dorsal approach. It is easier because it provides a direct access to the urethral lumen and a clear visualisation of the stricture, allowing the preservation of as much as possible of the urethral plate during the urethral opening. This ease of accessibility is important and evident, especially in the proximal bulbar tract.

An easy technique means that it is easy to teach and easy to learn. Indeed, the ventral approach requires no particular surgical skills and expertise, making the procedure easy even for urologists with no special training in reconstructive surgery. Furthermore, easier also means quicker, reducing the operative time.

The ventral approach is versatile because, depending on the quality of the urethral plate, it allows the surgeon to choose *in situ* the most adequate technique, i.e., one-sided dorsal grafting or one-sided ventral grafting, or

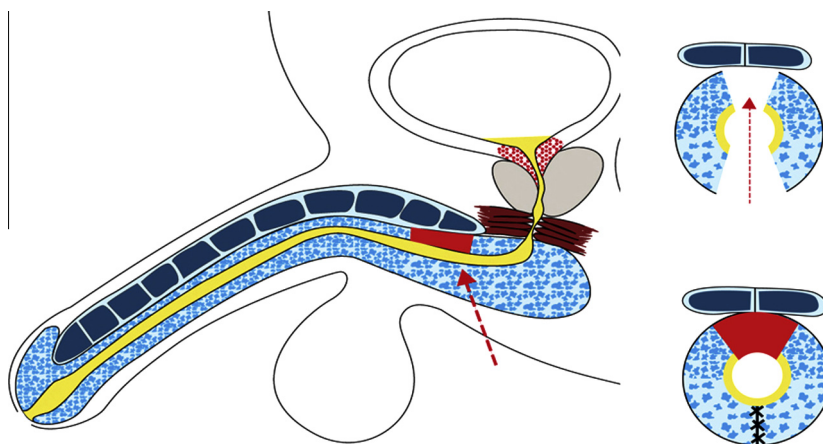


Figure 2 Dorsal grafting by the ventral urethrotomy approach.

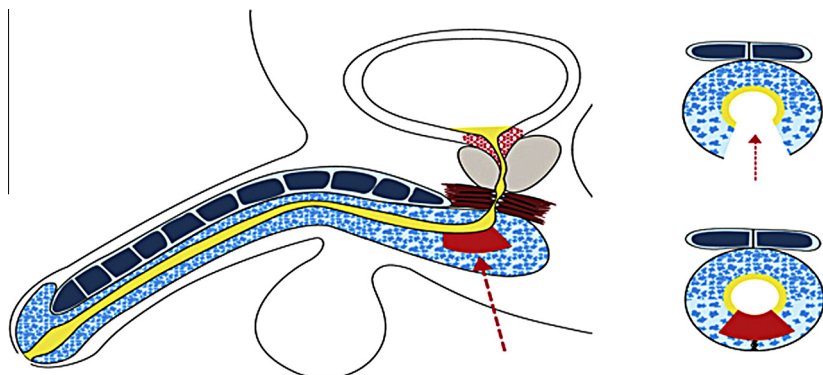


Figure 3 Ventral grafting by the ventral approach.

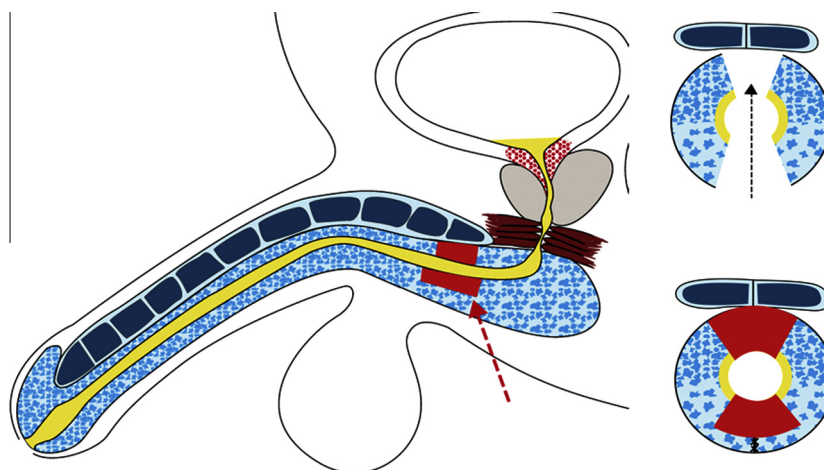


Figure 4 Double dorsal plus ventral grafting by the ventral urethrotomy approach.

two-sided double grafting, or a transecting and graft-augmented anastomosis or perineostomy.

In the case of dorsal grafting, the procedure seems easier than dorsal grafting by a dorsal access because the scarred urethra with marked spongiofibrosis is not mobilised from the corpora. There is less harm to the urethral plate, because the space for grafting is created without lifting the two urethral halves from the corpora, and thereby the blood supply is guaranteed by the saved circumflex and perforating arteries.

In the case of ventral grafting the clear view of the margins of the urethral plate allows a water-tight graft anastomosis.

If there is a very narrow urethral plate it is possible to transect and excise a portion of the urethra and make a graft-augmented anastomosis. However, in these cases the two-sided dorsal plus ventral double grafting represents a valid alternative to the aggressive anastomotic procedures, and by avoiding the transection of the spongiosum, it preserves the urethral plate [19,20]. The aim of double grafting was to maintain the integrity of the urethral vascularity and the urethral length, thus reducing the sexual complications related to the anastomotic techniques [4,5,21,22]. By avoiding the use of a single wide ventral graft, double grafting can reduce the possibility of fistula and diverticula. Furthermore, the additional second graft could correct the initial use of a single dorsal graft that was intra-operatively considered to be insufficient for adequate augmentation [23].

Finally, if necessary, the ventral approach allows the surgeon to convert a one-stage into a staged procedure during the operation, thus facilitating a perineostomy if required.

Basically, the ventral approach is less aggressive because there is a minimal dissection with no wide and circumferential mobilisation of the urethra, thus reducing, in proximal bulbar strictures, the risk of erectile dysfunction, that has been a concern when using the dorsal access.

In our daily practice we often have to deal with patients in whom the ventral approach is easier than the dorsal, e.g., obese patients, those with strictures after a failed urethroplasty or radiotherapy, with very tight strictures, and proximal bulbar strictures.

Disadvantages

Some surgeons complain that there is more bleeding and a risk of vascular damage when cutting ventrally, but there are no studies confirming these problems. Others complain of the risk of graft weakening with urethral sacculation or fistula. In reality, the abundant ventral spongiosum guarantees a satisfactory coverage and support for the graft, and reports fail to support this risk. This was probably a problem previously, when some surgeons did not cover the graft with the spongiosum. Perhaps there is a slight weakening of the augmented urethral floor and this could explain the postvoid dribbling that we find in $\approx 20\%$ of our patients. However, except for these minimal complications, it is important that no patient reported sexual complaints and all reported an improvement in sexual life [24]. However, as the spongiosum is thinner in the distal bulbar urethra it might be advisable not to use this approach in this segment.

Conclusions

Generally, surgeons tend to use techniques that are easy, quick and give excellent outcomes with few complications. The graft urethroplasty using the ventral approach fulfils these requirements.

Conflict of interest

None.

Source of funding

None.

References

- [1] Andrich DE, Mundy AR. What is the best technique for urethroplasty? *Eur Urol* 2008;**54**:1031–41.
- [2] Mangera A, Patterson JM, Chapple CR. A systematic review of graft augmentation urethroplasty techniques for the treatment of anterior urethral strictures. *Eur Urol* 2011;**59**:797–814.
- [3] Wessels H, McAninch JW. Use of free grafts in urethral stricture reconstruction. *J Urol* 1996;**155**:1912–5.
- [4] Morey AF, Kizer WS. Proximal bulbar urethroplasty via extended anastomotic approach – what are the limits? *J Urol* 2006;**175**:2145.
- [5] Al-Qudah HS, Santucci RA. Buccal mucosal onlay urethroplasty versus anastomotic urethroplasty (AU) for short urethral strictures: which is better? *J Urol* 2006;**175**(Suppl. 103):313A.
- [6] Palminteri E, Berdondini E, Shokeir AA, Iannotta L, Gentile V, Sciarra A. Two-sided bulbar urethroplasty using dorsal plus ventral oral graft. Urinary and sexual outcomes of a new technique. *J Urol* 2011;**185**:1766–71.
- [7] Patterson JM, Chapple CR. Surgical techniques in substitution urethroplasty using buccal mucosa for the treatment of anterior urethral strictures. *Eur Urol* 2008;**53**:1162–71.
- [8] Barbagli G, Sinselone S, Djinovic R, Romano G, Luzzi M. Current controversies in reconstructive surgery of the anterior urethra. A clinical overview. *Int Braz J Urol* 2012;**38**:307–16.
- [9] Devine PC, Wendelken JR, Devine CJ. Free full thickness skin graft urethroplasty: current technique. *J Urol* 1979;**121**:282–5.
- [10] Monseur J. L'élargissement de l'urètre au moyen du plan sus urétral. *J Urol (Paris)* 1980;**86**:439–49.
- [11] Barbagli G, Selli C, Tosto A, Palminteri E. Dorsal free graft urethroplasty. *J Urol* 1996;**155**:123–6.
- [12] Barbagli G. Editorial comment on: dorsal buccal mucosal graft urethroplasty for anterior urethral stricture by Asopa technique. *Eur Urol* 2009;**56**:205.
- [13] Barbagli G, Palminteri E, Guazzoni G, Montorsi F, Turini D, Lizzari M. Bulbar urethroplasty using buccal mucosa grafts placed on the ventral, dorsal or lateral surface of the urethra: are results affected by the surgical technique? *J Urol* 2005;**174**:955.
- [14] Kulkarni S, Barbagli G, Sinselone S, Luzzi M. One-sided anterior urethroplasty: a new dorsal onlay graft technique. *BJU Int* 2009;**104**:1150–5.
- [15] Hayes MC, Malone PS. The use of a dorsal buccal mucosal graft with urethral plate incision (Snodgrass) for hypospadias salvage. *BJU Int* 1999;**83**:508–9.
- [16] Asopa H, Garg M, Singhal GG, Singh L, Asopa J, Nischal A. Dorsal free graft urethroplasty for urethral stricture by ventral sagittal urethrotomy approach. *Urology* 2001;**58**:657–9.
- [17] Presman D, Greenfield DL. Reconstruction of the perineal urethra with a free full-thickness skin graft of the prepuce. *J Urol* 1953;**69**:677–80.
- [18] Morey AF, McAninch JW. When and how to use buccal mucosal grafts in adult bulbar urethroplasty. *Urology* 1996;**48**:194–8.
- [19] Palminteri E, Manzoni G, Berdondini E, Di Fiore F, Testa G, Poluzzi M, et al. Combined dorsal plus ventral double buccal mucosa graft in bulbar urethral reconstruction. *Eur Urol* 2008;**53**:81.
- [20] Abouassaly R, Angermeier KW. Augmented anastomotic urethroplasty. *J Urol* 2007;**177**:2211.
- [21] Barbagli G, De Angelis M, Romano G, Lizzari M. Long-term follow up of bulbar end-to-end anastomosis: a retrospective analysis of 153 patients in a single center experience. *J Urol* 2007;**178**:2470.
- [22] Mundy AR. Results and complications of urethroplasty and its future. *Br J Urol* 1993;**71**:322.
- [23] Palminteri E, Berdondini E, Fusco F, De Nunzio C, Giannitsas L, Larocca L, et al. Versatility of the ventral approach in bulbar urethroplasty using dorsal, ventral or dorsal plus ventral oral grafts. *Arab J Urol* 2012;**10**:118–24.
- [24] Palminteri E, Berdondini E, De Nunzio C, Bozzini G, Maruccia C, Scoffone C, et al. The impact of ventral oral graft bulbar urethroplasty on sexual life. *Urology* 2013;**81**:891–8.