



Since January 2020 Elsevier has created a COVID-19 resource centre with free information in English and Mandarin on the novel coronavirus COVID-19. The COVID-19 resource centre is hosted on Elsevier Connect, the company's public news and information website.

Elsevier hereby grants permission to make all its COVID-19-related research that is available on the COVID-19 resource centre - including this research content - immediately available in PubMed Central and other publicly funded repositories, such as the WHO COVID database with rights for unrestricted research re-use and analyses in any form or by any means with acknowledgement of the original source. These permissions are granted for free by Elsevier for as long as the COVID-19 resource centre remains active.

# Acute limb ischemia in patients with COVID-19 pneumonia

Raffaello Bellosta, MD,<sup>a</sup> Luca Luzzani, MD,<sup>a</sup> Giuseppe Natalini, MD,<sup>a,b</sup> Matteo Alberto Pegorer, MD,<sup>a</sup> Luca Attisani, MD,<sup>a</sup> Luisa Giuseppina Cossu, MD,<sup>a</sup> Camillo Ferrandina, MD,<sup>a</sup> Alessandro Fossati, MD,<sup>a</sup> Elena Conti, MD,<sup>a,b</sup> Ruth L. Bush, MD, JD, MPH,<sup>c</sup> and Gabriele Piffaretti, MD, PhD,<sup>d</sup> *Brescia and Varese, Italy; and Houston, Tex*

## ABSTRACT

**Objective:** The aim of our study was to determine the incidence, characteristics, and clinical outcomes of patients with the novel coronavirus (COVID-19) infection who had presented with and been treated for acute limb ischemia (ALI) during the 2020 coronavirus pandemic.

**Methods:** We performed a single-center, observational cohort study. The data from all patients who had tested positive for COVID-19 and had presented with ALI requiring urgent operative treatment were collected in a prospectively maintained database. For the present series, successful revascularization of the treated arterial segment was defined as the absence of early (<30 days) re-occlusion or major amputation or death within 24 hours. The primary outcomes were successful revascularization, early ( $\leq 30$  days) and late ( $\geq 30$  days) survival, postoperative ( $\leq 30$  days) complications, and limb salvage.

**Results:** We evaluated the data from 20 patients with ALI who were positive for COVID-19. For the period from January to March, the incidence rate of patients presenting with ALI in 2020 was significantly greater than that for the same months in 2019 (23 of 141 [16.3%] vs 3 of 163 [1.8%];  $P < .001$ ). Of the 20 included patients, 18 were men (90%) and two were women (10%). Their mean age was  $75 \pm 9$  years (range, 62-95 years). All 20 patients already had a diagnosis of COVID-19 pneumonia. Operative treatment was performed in 17 patients (85%). Revascularization was successful in 12 of the 17 (70.6%). Although successful revascularization was not significantly associated with the postoperative use of intravenous heparin (64.7% vs 83.3%;  $P = .622$ ), no patient who had received intravenous heparin required reintervention. Of the 20 patients, eight (40%) had died in the hospital. The patients who had died were significantly older ( $81 \pm 10$  years vs  $71 \pm 5$  years;  $P = .008$ ). The use of continuous postoperative systemic heparin infusion was significantly associated with survival (0% vs 57.1%;  $P = .042$ ).

**Conclusions:** In our preliminary experience, the incidence of ALI has significantly increased during the COVID-19 pandemic in the Italian Lombardy region. Successful revascularization was lower than expected, which we believed was due to a virus-related hypercoagulable state. The use of prolonged systemic heparin might improve surgical treatment efficacy, limb salvage, and overall survival. (*J Vasc Surg* 2020;72:1864-72.)

**Keywords:** Acute limb ischemia; COVID-19

Acute lower extremity ischemia (ALI) is a common vascular emergency.<sup>1</sup> The etiology of ALI can be multifactorial, with thrombotic occlusion generally occurring in the setting of a previously treated arterial segment or associated with atherosclerotic arterial disease.<sup>2</sup> Patients with hypercoagulable states are known to have a risk of

native arterial thrombosis, one of the most challenging of ALI scenarios to treat.<sup>3</sup> A recent analysis of a large database showed improved overall in-hospital mortality and early amputation rates. However, in the context of a hypercoagulable state, the surgical decisions and related clinical outcomes have been poorly reported.<sup>1</sup>

The novel coronavirus pneumonia (COVID-19) pandemic has affected the globe, with Italy leading many reports of the incidence and mortalities. Within a few weeks in March 2020, the number of patients with the COVID-19 skyrocketed in northern Italy, especially in the Lombardy region, which has been speculated to have resulted from the older population in that region. Recently reported studies have described the clinical characteristics and overall outcomes of patients with COVID-19 and the effects of treating these patient on the healthcare system.<sup>4</sup> Two studies have reported associated coagulopathy disorders. These reports have highlighted the presence of a coexisting hypercoagulable state in patients with COVID-19, which might be

From the Divisions of Vascular Surgery<sup>a</sup> and Anesthesia and Intensive Care,<sup>b</sup> Department of Cardiovascular Surgery, Fondazione Poliambulanza, Brescia; the Division of Vascular Surgery, Medicine and Surgery, University of Insubria School of Medicine and ASST Sottelaghi, Varese<sup>c</sup>; and the University of Houston, College of Medicine, Houston.<sup>d</sup>

Author conflict of interest: none.

Correspondence: Raffaello Bellosta, MD, Division of Vascular Surgery, Department of Cardiovascular Surgery, Fondazione Poliambulanza, Via L. Bissolati 51, Brescia 25124, Italy (e-mail: [raffaello.bellosta@poliambulanza.it](mailto:raffaello.bellosta@poliambulanza.it)).

The editors and reviewers of this article have no relevant financial relationships to disclose per the JVS policy that requires reviewers to decline review of any manuscript for which they may have a conflict of interest.

0741-5214

Copyright © 2020 by the Society for Vascular Surgery. Published by Elsevier Inc.

<https://doi.org/10.1016/j.jvs.2020.04.483>

associated with higher mortality.<sup>5,6</sup> A sudden and significant increase of COVID-19–infected patients who were presenting with ALI has been noted at our institutions with the viral spread. The aim of the present study was to determine the incidence, characteristics, and clinical outcomes of patients presenting with and treated for ALI during the COVID-19 pandemic at an Italian tertiary care hospital.

## METHODS

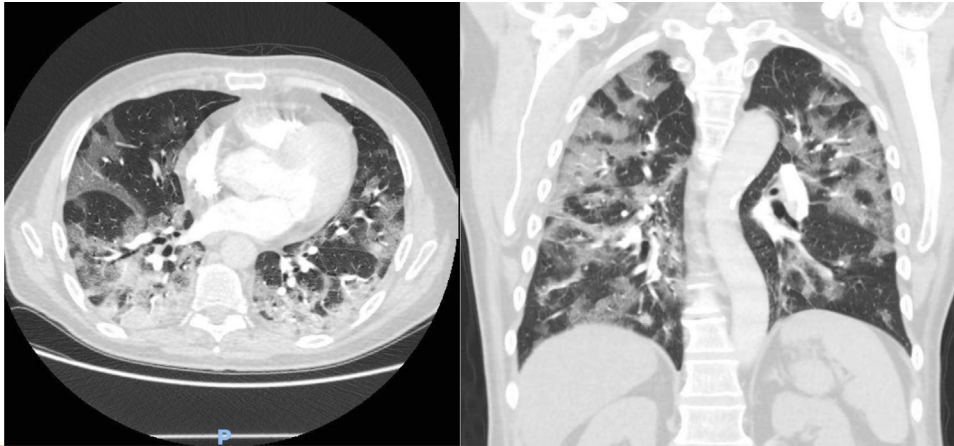
We performed a single-center, observational cohort study. Because of the clinical emergency setting caused by the current pandemic, the local institutional review board approved the present prospective study (protocol no. PO-CVA-08), and all included patients had provided written informed consent. The data from all patients who had tested positive for COVID-19 and had presented with ALI requiring urgent operative intervention were collected in a prospectively maintained database. Data entry was managed by the physicians involved in direct patient care. For our study, the data from all the patients who had presented with and been treated for ALI were identified and analyzed. From an epidemiological viewpoint, we also compared the data with data from the same period in 2019. The recorded variables included demographic data, comorbidities, laboratory blood test results, including coagulation panels, medical and surgical history, operative details, and postoperative events during hospitalization and the immediate postoperative period.

**Preoperative evaluation.** According to our standardized program, all patients with a clinical suspicion for aortoiliac and/or infrainguinal ALI and/or upper limb ischemia underwent routine preoperative screening blood tests, including creatine phosphokinase and D-dimer, and chest radiographs and electrocardiography. Preoperative computed tomography was performed to identify COVID-19-related pneumonia (Fig 1). These studies were performed in the emergency room to avoid cross-contamination and unnecessary risk of viral spread. Patients with suspected aortoiliac occlusion underwent computed tomography angiography to assess the extent of disease and vessel size (Fig 2, A and B). Those patients who had presented with infrainguinal and/or upper limb occlusive disease underwent echocardiographic color Doppler evaluation of both the arterial and the venous systems. Also, during the course of hospitalization, all patients were screened for the identification of eventual cardiac emboli sources using transthoracic echocardiography. The operative risk profile was determined using a multidisciplinary evaluation, which included the physical examination and laboratory blood test results.

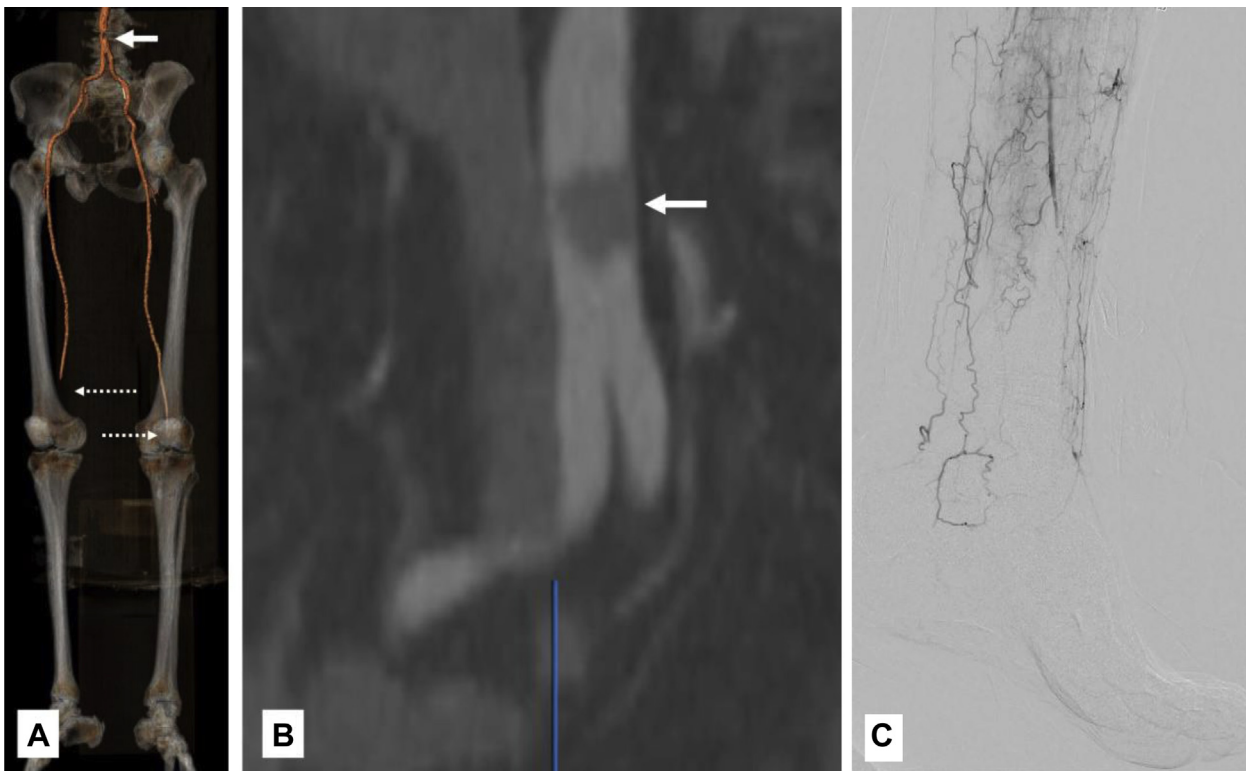
## ARTICLE HIGHLIGHTS

- **Type of Research:** Single-center, observational cohort study
- **Key Findings:** The novel coronavirus (COVID-19) might increase the incidence of acute limb ischemia (ALI) in patients who test positive for the virus. Surgical revascularization was associated with a high technical failure rate in our cohort, which might have resulted from an inherent virus-related underlying hypercoagulability state. No significant demographic differences between those with and without successful revascularization were present in our cohort; however, age was significantly older for the patients who died.
- **Take Home Message:** COVID-19 infection might increase the incidence of ALI and be associated with poorer surgical results owing to the associated acquired hypercoagulability. Prolonged systemic heparin might be warranted for both limb salvage and improved survival.

**Operative techniques.** Open surgical intervention was performed in the operating room with the patient under locoregional or local anesthesia and intravenous sedation, using 80 U/kg of intravenous heparin at arterial clamping and routine antibiotic prophylaxis. All patients received oxygen support. At the time of the present analysis, no patient had required preemptive intubation because of COVID-19-related pneumonia. In the patients with aortoiliac or femoropopliteal occlusion, a standard groin incision was used to expose the femoral bifurcation. We selectively used a below-the-knee incision to expose the popliteal artery in patients with isolated popliteal-tibial occlusion. Upper limb ischemia was treated through direct open brachial artery exposure. Thromboembolectomy was performed using standard embolectomy catheters (Le Maitre, Burlington, Mass), sized according to the location of the occlusion. In all cases, completion angiography was performed through the surgical access (Fig 2, C). Tibial arteries and/or forearm vessels were approached selectively in cases of distal occlusion. Fasciotomy was not routinely performed. In those with distal occlusion, especially those with the typical aspect of a desert foot, our protocol has been augmented with intra-arterial locoregional thrombolysis using alteplase (Actilyse; Boehringer Ingelheim Italia SpA, Milan, Italy) at 20 mg/20 minutes. The postoperative antithrombotic regimen has been standardized, with the most recent patients receiving an anticoagulation regimen consisting of continuous intravenous heparin infusion. In the case of a less than 80% basal level of antithrombin III, 500 U of antithrombin III was infused for 10 minutes before starting the continuous intravenous heparin to reach an activated partial thromboplastin



**Fig 1.** Preoperative computed tomography scan of a 66-year-old man with COVID-19-related pneumonia and acute limb ischemia. Transverse and coronal thin-section scans show extensive ground-glass opacities of both lungs.



**Fig 2.** Preoperative computed tomography angiography with volume rendering 3-dimensional reconstruction (**A**) showing the presence of intraluminal thrombus (**B**) at the infrarenal aorta (*white arrow*), total occlusion of the popliteal segment (*white dotted arrows*), and the absence of tibial vessels, bilaterally. Final completion angiogram showing the morphological aspect of "desert foot" after large amount of thrombus removal for femoral-popliteal-tibial occlusion that required selective thrombectomy of all tibial vessels bilaterally.

time of 2.5 seconds. The thrombi retrieved from each patient were sent for histologic evaluation (Fig 2). Post-operative surveillance was performed with physical examinations every hour and full blood panel tests every 8 hours. Transfusions of packed red blood cells were given only if the hemoglobin level had decreased to less

than 8 g/dL. An infectious disease specialist evaluated each patient regularly during the entire hospitalization course to optimize the type, dosage, and duration of antibiotic and antiretroviral therapy. At discharge, all patients were given enoxaparin sodium injections (Clexane; Sanofi SpA, Milan, Italy) for home use at a

therapeutic dosage. Follow-up and surveillance imaging will include clinical visits with determination of the ankle-brachial index and duplex ultrasound examination at 1, 6, and 12 months after treatment and then annually. Any change in the examination findings or ankle-brachial index or suspicion of a loss of patency will be confirmed using duplex ultrasonography and computed tomography angiography.

**Definition and primary outcomes.** The clinical status was defined using the Rutherford classification system.<sup>6</sup> The medical comorbidity grade and operative outcomes were defined in accordance with the recommended reporting standards and best practice documents from the Society for Vascular Surgery (SVS) and European Society for Vascular Surgery.<sup>7,8</sup> Complications were recorded as perioperative (<30 days) or late (>1 month) and classified as graft-related or procedure-related. The complications were described as mild (spontaneous resolution or with nominal intervention, did not prolong the hospital stay, and/or did not cause permanent disability), moderate (required significant intervention, prolonged hospitalization for >24 hours, resulted in a minor amputation, or was associated with a minor disability that did not interfere with normal daily activities), or severe (necessitated a major surgical, medical, and/or endovascular intervention or resulted in prolonged convalescence, major amputation, permanent disability, or death). Major amputations were classified as transfemoral or transtibial. Minor amputations were any toe or forefoot amputation and were not considered in the analysis of freedom from amputation. Successful revascularization of the treated segment was defined as the absence of early (<30 days) reocclusion or persistent forefoot ischemia or major amputation or death within 24 hours. The primary outcomes were successful revascularization, early (<30 days) and late survival, postoperative (<30 days) complications, and limb salvage at the last clinical evaluation available at least 7 days after revascularization.

**Statistical analysis.** The clinical data were prospectively recorded and tabulated in a Microsoft Excel database (Microsoft Corp, Redmond, Wash).<sup>9</sup> Statistical analysis was performed using SPSS, release 25.0, for Windows (IBM Corp, Armonk, NY). Continuous variables were tested for normality using the Shapiro-Wilk test. Variables that were normally distributed are presented as the mean  $\pm$  standard deviation and range. Non-normally distributed variables are presented as the median and interquartile range. Categorical variables are presented as frequencies and percentages. Categorical variables were analyzed using a  $\chi^2$  test or Fisher's exact test, as necessary. An independent samples Student *t* test was used for continuous variables. A Wilcoxon signed-rank test was used to evaluate the difference in blood test

results before and after revascularization. All reported *P* values are two-sided, and *P* < .05 was considered to indicate statistical significance.<sup>9</sup>

## RESULTS

**Study cohort.** We evaluated the data from 20 patients with ALI who had COVID-19-related pneumonia. During the same period, 3 patients were treated for ALI who had tested negative for COVID-19. For historical context, during 2019, only 27 of 630 arterial interventions (4.3%) were performed for ALI. Also, during the calendar period of January to March, the incidence rate of patients presenting with ALI in 2020 was significantly higher (23 of 141 [16.3%] vs 3 of 163 [1.8%] in the same months in 2019; *P* < .001). The present study cohort included 11 patients who had presented to our emergency department and nine who had been transferred from other hospitals. Of the 20 patients, 18 were men (90%) and two were women (10%). Their mean age was  $75 \pm 9$  years (range, 62-95 years). The demographic data, comorbidities, and risk factors, are reported in [Table I](#). In brief, all 20 patients had already presented with COVID-19-related pneumonia as documented by the preoperative computed tomography scan. All patients with a medical history positive for atrial fibrillation (*n* = 5; 25%) were taking oral anticoagulation at admission. Of those patients with previous peripheral vascular intervention (*n* = 4; 20%), an occluded graft was not determined as the only or leading reason for the occlusion causing ALI. The mean arterial oxygen pressure was  $66 \pm 21$  mm Hg (range, 31-110 mm Hg). The median interval to transfer from an outside hospital was 120 minutes (interquartile range, 67-168.7 minutes). The ALI stage at admission was Rutherford stage IIa in 2 patients (10%), IIb stage in 15 patients (75%), and stage III in 3 patients (15%). The mean preoperative SVS score was  $6 \pm 4$  (range, 1-15).

**Treatment details.** Three patients (15%) did not undergo revascularization. These patients had had severe COVID-19-related pneumonia, and intervention was not performed owing to their moribund condition (mean oxygen pressure, 47 mm Hg; mean SVS score, 8.3; and Rutherford stage III [2 patients]). Operative treatment was performed in 17 patients (85%). Local anesthesia with sedation was used for 15 patients (88.2%) and locoregional anesthesia for two patients (11.8%). Thromboembolectomy was performed for infrainguinal occlusion in 11 patients (64.7%), bilateral aortoiliac occlusion in 3 patients (17.6%), and upper limb occlusion in 1 patient (5.9%). Below-the-knee femoropopliteal bypass was performed in two patients (11.8%). Selective tibial vessel thrombectomy was performed in five patients (29.4%) and additional intraoperative thrombolysis in four patients (23.5%). Adjunctive procedures included placement of aortoiliac kissing stents in 2 patients because of nondetachable residual clots, femoral endarterectomy in

**Table I.** Demographic data, comorbidities, and risk factors for entire cohort (N = 20)

Variable	Value
Demographic	
Gender	
Male	18
Female	2
Age, years	75 ± 8
Age group, years	
60-69	5 (25)
70-79	8 (40)
≥80	6 (30)
Comorbidities	
Hypertension	11 (55)
Atrial fibrillation	5 (25)
CKD (eGFR <30 mL/min) <sup>a</sup>	4 (20)
Previous vascular surgery	4 (20)
FP stent/stent graft	2
AbF bypass	1
FP btk bypass	1
Obesity (BMI >30 kg/m <sup>2</sup> )	4 (20)
Diabetes	3 (15)
COPD (Glass stage ≥3) <sup>b</sup>	2 (10)
Coronary artery disease	2 (10)
Risk factors	
SVS score <sup>c</sup>	6 ± 4
Ischemia time, minutes	
Median	120
IQR	67-168.7
Hospital distance, km	48 ± 25
Preoperative blood parameters	
Hemoglobin, g/dL	13.8 ± 7.6
Leukocytes, 10 <sup>3</sup> /mm <sup>3</sup>	14 ± 2
D-dimer, ng/mL	
Median	2200
IQR	158-301
Platelets, 10 <sup>3</sup> /μL	239 ± 82
CPK, U/L	6479 ± 2143

Data presented as number (%), mean ± standard deviation, or median and IQR.

AbF, Aortobifemoral; BMI, body mass index; btk, below-the-knee; CKD, chronic kidney disease; COPD, chronic obstructive pulmonary disease; CPK, creatine phosphokinase; eGFR, estimated glomerular filtration rate; FP, femoropopliteal; IQR, interquartile range; SVS, Society for Vascular Surgery.

<sup>a</sup>Ann Intern Med 2009;150:604-12.

<sup>b</sup>Available at: <http://www.goldcopd.org>.

<sup>c</sup>J Vasc Surg 2015;61:2S-41S.

1 patient, and below-the-knee popliteal percutaneous transluminal angioplasty in 1 patient. At completion angiography, no critical chronic atherosclerotic obstructive lesion was observed and no anastomotic defects were observed in the surgical or endovascular graft

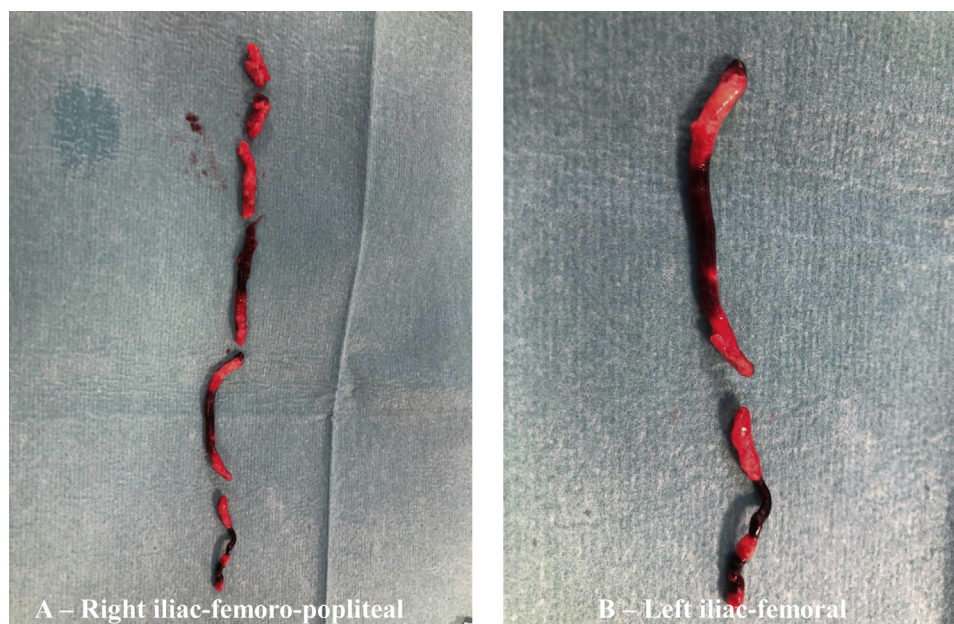already implanted. Postoperatively, all patients received systemic anticoagulation with a weight-adjusted therapeutic regimen of low-molecular-weight heparin (n = 11) or intravenous heparin infusion (n = 6). No bleeding complications were observed. All the patients had macroscopic evidence of black- and gray-striped thrombus (Fig 3). All thrombi were sent for histologic examination.

**Mortality.** Of the 20 patients, eight (40%) had died in-hospital; the cause of death is reported in Table II. The patients who had died were significantly older (81 ± 10 years vs 71 ± 5 years;  $P = .008$ ), with the mortality rate for those aged 80 years or older significantly greater than that for those younger than 80 years old (83% vs 21.4%;  $P = .018$ ). On univariate analysis, no comorbidity or risk factors was associated with mortality. The preoperative SVS score (7.7 ± 4.9 vs 4.6 ± 3;  $P = .091$ ) and preoperative creatine phosphokinase value (12,056 vs 3437;  $P = .083$ ) showed a tendency to be associated with mortality; however, the differences were not statistically significant. In contrast, on univariate analysis, the use of intravenous heparin was significantly associated with survival (0% vs 57.1%;  $P = .042$ ).

**Revascularization.** Revascularization was successful in 12 of the 17 patients (70.6%) treated. During hospitalization, 2 of 15 patients (13%) had undergone reintervention because of a recurrent thrombotic occlusion of the treated arterial segment on postoperative days 1 and 2. No ipsilateral deep venous thrombosis was detected in patients with desert foot or in those who had developed recurrent thrombotic occlusion. Overall, limb salvage was obtained for 14 of 15 patients (93.3%). A major amputation was needed in one patient, an 81-year-old man who had been transferred to our institution 450 minutes after symptom onset and for whom the attempted revascularization had been unsuccessful. Univariate analysis showed no significant differences in comorbidities or the SVS risk profile between those with and without successful revascularization ( $P = .739$ ). The presence of COVID-19-related pneumonia was not significantly associated with successful revascularization (45.4% vs 66.7%;  $P = .620$ ). In contrast, the preoperative oxygen pressure was significantly lower in those without successful revascularization (46 ± 8 mm Hg vs 76 ± 17 mm Hg;  $P = .004$ ). Although successful revascularization was not significantly associated with the postoperative use of intravenous heparin (64.7% vs 83.3%;  $P = .622$ ), no patient who had received intravenous heparin required reintervention.

## DISCUSSION

The main findings from this preliminary phase of COVID-19 health emergency are twofold. First, the number of patients in our population presenting with ALI has significantly increased compared with the same



**Fig 3.** Thrombus (**A** and **B**) specimen after aortoiliac-femoropopliteal thrombectomy and bilateral selective tibial artery thrombectomy.

**Table II.** Cause of mortality for entire cohort (N = 20)

Pt. No.	Gender	Age, years	COVID-19-related pneumonia	Anatomic location	Complication	Interval to death (days from admission)	Cause of death
Treated							
5	M	81	Yes	Aortoiliac and infrainguinal	No	0	MOF
6	M	87	Yes	Upper limb	Reocclusion, lower limb ischemia	8	ARDS
9	M	69	Yes	Infrainguinal	Reintervention	4	ARDS
10	M	89	Yes	Infrainguinal	No	2	ARF
14	M	76	Yes	Infrainguinal	No	1	MOF
Untreated							
						NA	
12	F	65	Yes	Infrainguinal		3	AMI
13	F	94	Yes	Infrainguinal		1	ARDS
16	M	84	Yes	Infrainguinal		1	ARDS

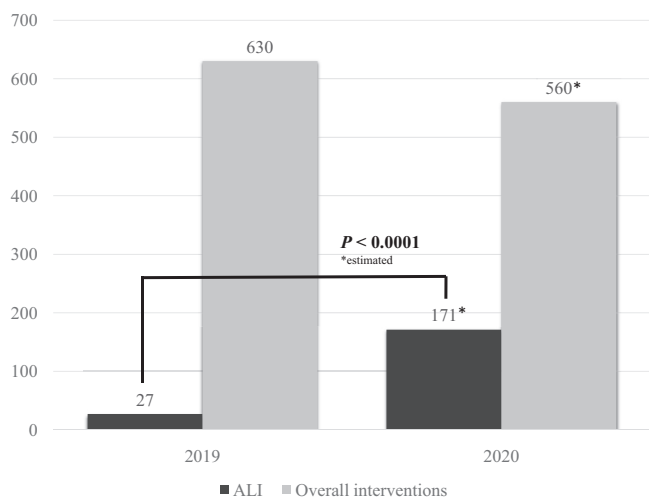
AMI, Acute myocardial infarction; ARDS, acute respiratory distress syndrome; ARF, acute renal failure; F, female; M, male; MOF, multiple organ failure; NA, not applicable; Pt. No., patient number.

period in 2019. Second, the high rate of clinical and technical failure was consistent with the presence of a hypercoagulable state triggered by COVID-19 infection.

The relationship between COVID-19 infection and hypercoagulability has been recently addressed in preliminary observations. The study by Tang et al<sup>5</sup> showed that abnormal coagulation results, characterized by a markedly elevated D-dimer level and fibrin degradation products, are common in patients who have died of COVID-19-related pneumonia. Han et al<sup>6</sup> showed that coagulation function is significantly deranged compared with

healthy uninfected people and that monitoring coagulation parameters could enable early identification of severe cases. None of the previous studies has reported observations of hypercoagulable status in patients with COVID-19 undergoing surgery.

We believe, from our direct experience, that patients who test positive for COVID-19 could experience a hypercoagulable state that could increase the incidence and extension of native arterial occlusion. Previous (pre-COVID-19) studies have reported that the overall incidence of ALI has declined significantly in the past



**Fig 4.** Estimated projection of patients with acute limb ischemia (ALI) in 2020 compared with those treated in 2019 at the same center.

decade and that the presence of a hypercoagulable state is an uncommon etiology among the broad population presenting with ALI.<sup>2,10</sup> However, in our early experience, we have evaluated a significantly greater number of patients with from ALI compared with the same period in 2019 before COVID-19. If the pandemic continues as predicted, this emergency will extend until the end of the calendar year. Undoubtedly, this will translate into the evaluation and surgical intervention of ~171 cases. This would be greater than 30% of the projected total interventions or a fivefold increase if compared with all of 2019 (Fig 4). Additionally, although a hypercoagulable state has been preferentially associated with venous thromboembolism, our patients with COVID-19 had both arterial and venous vascular system involvement.<sup>2</sup> Multiple patients had a diagnosis of extensive deep venous thrombosis, in addition to ALI, and massive pulmonary embolism has been reported to be frequently found during autopsy in these patients (Chen, unpublished data, 2020). Third, we are expecting to perform better analyses of the thrombus specimens. However, macroscopically, they appear quite different from specimens before COVID-19, with a typical gelatinous consistency. Finally, although young age and female gender have been found to be more frequently associated with known hypercoagulable disorders, in our series, this hypercoagulability state was observed in both younger and older patients, with a male predominance. These latter two findings suggest that the hypercoagulability in our patients is not related to well-known blood disorders but, rather, that native arterial thrombosis might be triggered by COVID-19 infection. This is only a preliminary, although totally new, observation. Viral-related ALI has been described anecdotally in reported studies but was not associated with venous thromboembolism or hypercoagulability.<sup>11</sup>

The choice of surgical intervention is influenced by both the clinical status of the patient and the etiology of the ALI.<sup>3</sup> Although relatively uncommon, ALI secondary to native arterial thrombosis is an ominous form. Information about the outcomes for this group of patients has been scarce. O'Connell and Quiñones-Baldrich<sup>2</sup> reported that patients with thrombotic, rather than embolic, occlusion had worse outcomes overall. In addition, Torrealba et al<sup>10</sup> reported significantly worse outcome for patients with diagnosed hypercoagulable disorders. Successful revascularization was disappointingly low in patients with COVID-19 when compared with previously reported series.<sup>12</sup> The high failure rate in our experience might have resulted from the two typical aspects observed in these patients. First, at completion angiography, we frequently found a situation of "desert foot" and a typical absence of the forefoot microcirculation, despite the removal of the thrombus with selective thrombectomy of the below-the-knee and ankle arteries. Second, this aspect might have led to sudden early recurrent thrombosis of the treated segment. The observation that a suspect marked hypercoagulability might be a contributory cause of technical failure might indirectly find support because a similar rate of success was obtained in those transferred from another hospital and the mean ischemia time was not significantly associated with technical failure. Both the inability to obtain effective distal revascularization and the recurrent episodes of thrombosis of the treated segments prompted us to change our treatment protocol by including a more aggressive regimen with thrombolysis and continuous infusion of heparin.

At present, no data are available on patients with COVID-19 presenting with ALI nor have the outcomes of those treated surgically been reported. Therefore, no standardized treatment protocol has been established. Considering the clinical and angiographic characteristics and the high failure rate for these patients, we decided to be much more aggressive and soon increased our successful clinical and technical results. Although thrombolysis has been reported to not be the best choice for most patients with severe ischemia, it was included as adjunctive intraoperative procedure to improve the distal microcirculation, which might have had a potential role in stealing outflow vessels of an otherwise successful femoropopliteal-tibial vessel declotting.<sup>2,3,6,7</sup> In contrast, heparin prevents propagation of the thrombus both proximally and distally and maintains patency of the collateral vessels. Thus, we decided to use continuous intravenous infusion of heparin starting immediately after the intervention, with the aim of preventing early recurrent thrombosis, especially in the distal microcirculation.

The overall use of heparin in these patients was also suggested by the management document from the World Health Organization.<sup>13</sup> Although this protocol implementation was used for the last 5 patients, and the conclusions



might not be generalizable, we did not observe any new thrombotic complications. In addition, none of these 5 patients died. The potential beneficial effect of heparin in our COVID-19 surgical patients might find some support in experimental data. First, plenty of data have shown that heparin is the most effective method for the prevention of thromboembolism.<sup>14</sup> Second, it is well-known that heparin has suppressive activity against the development of a cytokines storm, which is a typical pathogenetic process of COVID-19 infection that eventually results in acute lung injury and death.<sup>15,16</sup> Finally, it has already been shown that heparin has competitive binding activity to the coronavirus. This final aspect might result in a significant reduction of the pathogen's activity, which would bind to the heparin, instead of attacking the cells of the organism by inhibiting cell penetration.<sup>17-20</sup>

**Study limitations.** The present preliminary observational study had some major limitations. The first was the small number of patients included. Second, the period of inclusion and observation were short. Third, we lacked robust data on the coagulation parameters to evaluate the eventual persistent status of hypercoagulability. Finally, the significantly higher number of patients treated for ALI might reflect the increased number of patients we have been treating since the start of this infective emergency and the suggested surgical priorities indicated by governmental disposition.

## CONCLUSIONS

In our preliminary experience of COVID-19 in the Lombardy region, the number of interventions for ALI has significantly increased. This greater incidence and the high failure rate due to unsuccessful revascularization seems to support the presence of a marked hypercoagulable state in these infected patients, a process that could be triggered by the viral infection. These observations, as well as the findings from experimental models, have led us to strengthen our treatment protocol by mainly focusing on the use of continuous intravenous heparin. In our experience, the addition of heparin seemed to increase the treatment effectiveness and, most importantly, was associated with better survival.

## AUTHOR CONTRIBUTIONS

Conception and design: RB, LL, MP, AF

Analysis and interpretation: RB, LL, GN, AF, RB, GP

Data collection: RB, LL, GN, MP, LA, LC, CF, AF, EC, GP

Writing the article: RB, LL, RB, GP

Critical revision of the article: RB, LL, GN, MP, LA, LC, CF, AF, EC, RB, GP

Final approval of the article: RB, LL, GN, MP, LA, LC, CF, AF, EC, RB, GP

Statistical analysis: RB, LL, LA, RB, GP

Obtained funding: Not applicable

Overall responsibility: RB

## REFERENCES

1. Baril DT, Ghosh K, Rosen AB. Trends in the incidence, treatment, and outcomes of acute lower extremity ischemia in the United States Medicare population. *J Vasc Surg* 2014;60:669-77.
2. O'Connell JB, Quiñones-Baldrich WJ. Proper evaluation and management of acute embolic versus thrombotic limb ischemia. *Semin Vasc Surg* 2009;22:10-6.
3. Deitcher SR, Carman TL, Sheikh MA, Gomes M. Hypercoagulable syndromes: evaluation and management strategies for acute limb ischemia. *Semin Vasc Surg* 2001;14:74-85.
4. Yang X, Yu Y, Xu J, Shu H, Xia J, Liu H, et al. Clinical course and outcomes of critically ill patients with SARS-CoV-2 pneumonia in Wuhan, China: a single-centered, retrospective, observational study. *Lancet Respir Med* 2020;8:e18.
5. Tang N, Li D, Wang X, Sun Z. Abnormal coagulation parameters are associated with poor prognosis in patients with novel coronavirus pneumonia. *J Thromb Haemost* 2020;18:844-7.
6. Han H, Yang L, Liu R, Liu F, Wu KL, Li J, et al. Prominent changes in blood coagulation of patients with SARS-CoV-2 infection [published online ahead of print March 16, 2020]. *Clin Chem Lab Med* doi: 10.1515/cclm-2020-0188.
7. Aboyans V, Ricco JB, Bartelink MEL, Björck M, Brodmann M, Cohnert T, et al. 2017 ESC guidelines on the diagnosis and treatment of peripheral arterial diseases, in collaboration with the European Society for Vascular Surgery (ESVS). *Eur J Vasc Endovasc Surg* 2018;55:305-68.
8. Society for Vascular Surgery Lower Extremity Guidelines Writing Group, Conte MS, Pomposelli FB, Clair DG, Geraghty PJ, McKinsey JF, et al. Society for Vascular Surgery practice guidelines for atherosclerotic occlusive disease of the lower extremities: management of asymptomatic disease and claudication. *J Vasc Surg* 2015;61:2S-41S.
9. Hickey GL, Dunning J, Seifert B, Sodeck C, Carr MJ, Burger HU, et al; EJCTS and ICVTS Editorial Committees. Statistical and data reporting guidelines for the European Journal of Cardio-Thoracic Surgery and the Interactive Cardiovascular and Thoracic Surgery. *Eur J Cardiothorac Surg* 2015;48:180-93.
10. Torrealba JI, Osman M, Kelso R. Hypercoagulability predicts worse outcomes in young patients undergoing lower extremity revascularization. *J Vasc Surg* 2019;70:175-80.
11. Lam R, Lin PH, Alankar S, Yao Q, Bush RL, Chen C, et al. Acute limb ischemia secondary to myositis-induced compartment syndrome in a patient with human immunodeficiency virus infection. *J Vasc Surg* 2003;37:1103-5.
12. Piffaretti G, Angrisano A, Franchin M, Ferrario M, Rivolta N, Bacuzzi A, et al. Risk factors analysis of thromboembolism for acute thromboembolic lower extremity ischemia in native arteries. *J Cardiovasc Surg* 2018;59:810-6.
13. Clinical management of severe acute respiratory infection (SARI) when COVID-19 disease is suspected. WHO reference no. WHO/2019-nCoV/Clinical/2020.4. Available at: [https://www.who.int/publications-detail/clinical-management-of-severe-acute-respiratory-infection-when-novel-coronavirus-\(ncov\)-infection-is-suspected](https://www.who.int/publications-detail/clinical-management-of-severe-acute-respiratory-infection-when-novel-coronavirus-(ncov)-infection-is-suspected). Accessed March 25, 2020.
14. Kearon C, Akl EA, Ornelas J, Blaivas A, Jimenez D, Bounameaux H, et al. Antithrombotic therapy for VTE disease: CHEST Guideline and Expert Panel Report. *Chest* 2016;149:315-52.
15. Li X, Liu Y, Wang L, Li Z, Ma X. Unfractionated heparin attenuates LPS-induced IL-8 secretion via PI3K/Akt/NF-κB signaling pathway in human endothelial cells. *Immunobiology* 2015;220:399-405.
16. Shastri MD, Stewart N, Horne J, Peterson GM, Gueven N, Sohal SS, et al. In-vitro suppression of IL-6 and IL-8 release from human pulmonary epithelial cells by non-

- anticoagulant fraction of enoxaparin. *PLoS One* 2015;10:e0126763.
17. Naskalska A, Dabrowska A, Szczepanski A, Milewska A, Jasik KP, Pyrc K. Membrane protein of human coronavirus NL63 is responsible for interaction with the adhesion receptor. *J Virol* 2019;93:e00355.
  18. Szczepanski A, Owczarek K, Bzowska M, Gula K, Drebot I, Ochman M, et al. Canine respiratory coronavirus, bovine coronavirus, and human coronavirus OC43: receptors and attachment factors. *Viruses* 2019;5:11.
  19. de Haan CA, Li Z, te Lintelo E, Bosch BJ, Haijema BJ, Rottier PJ. Murine coronavirus with an extended host range uses heparan sulfate as an entry receptor. *J Virol* 2005;79:14451-6.
  20. Vicenzi E, Canducci F, Pinna D, Mancini N, Carletti S, Lazzarin A, et al. Coronaviridae and SARS-associated coronavirus strain HSRI. *Emerg Infect Dis* 2004;10:413-8.
- Submitted Apr 8, 2020; accepted Apr 21, 2020.

Access to *Journal of Vascular Surgery Online* is reserved for print subscribers!

Full-text access to *Journal of Vascular Surgery Online* is available for all print subscribers. To activate your individual online subscription, please visit *Journal of Vascular Surgery Online*, point your browser to <http://www.jvascsurg.org>, follow the prompts to **activate your online access**, and follow the instructions. To activate your account, you will need your subscriber account number, which you can find on your mailing label (*note*: the number of digits in your subscriber account number varies from 6 to 10). See the example below in which the subscriber account number has been circled:

Sample mailing label

This is your subscription  
account number

*****3-DIGIT 001
SJ P1
FEB00 J024 C: 1 (1234567-89) U 05/00 Q: 1
J. H. DOE, MD
531 MAIN ST
CENTER CITY, NY 10001-001

Personal subscriptions to *Journal of Vascular Surgery Online* are for individual use only and may not be transferred. Use of *Journal of Vascular Surgery Online* is subject to agreement to the terms and conditions as indicated online.