

Combined Arthroscopic and Endoscopic Synovectomy for Diffuse Pigmented Villonodular Synovitis (PVNS) of the Ankle



Tun Hing Lui, M.B.B.S. (H.K.), F.R.C.S. (Edin.), F.H.K.A.M., F.H.K.C.O.S., and Yuen Ting Leung, M.B.B.S. (H.K.)

Abstract: The current treatment of choice for diffuse-type pigmented villonodular synovitis (PVNS) is surgical excision. Complete synovectomy is necessary because of the local aggressiveness of the disease, with a significant recurrence rate and a minor chance of malignant transformation. The recurrence rate is even greater in those cases with extra-articular extension. Arthroscopic and endoscopic synovectomy have the advantage of avoidance of extensive soft-tissue dissection, which is associated with open synovectomy. The purpose of this Technical Note is to describe the details of combined arthroscopic and endoscopic synovectomy as treatment for diffuse PVNS of the ankle. By a combination of different arthroscopic and endoscopic approaches of the ankle region, a complete synovectomy of both intra-articular and extra-articular components of diffuse-type PVNS is feasible.

Pigmented villonodular synovitis (PVNS) develops in response to a chromosomal aberration that results in overexpression of macrophage colony-stimulating factor-1, and this suggests a neoplastic rather than a reactive origin.¹ The most common location for this lesion is the knee (75%), followed by the hip (15%), the ankle (7%), and the foot (2%); rarely, it localizes in the upper limb.² Most cases of extra-articular diffuse-type PVNS are believed to represent extra-articular extensions of primary intra-articular disease, although there are reports of primary extra-articular diffuse-type PVNS.^{3,4} Even after detailed clinical assessment and imaging studies, the diagnosis of PVNS requires histologic proof.^{2,5,6}

The current treatment of choice for diffuse-type PVNS is surgical excision.^{3,7} Complete synovectomy is necessary because of the local aggressiveness of the disease with a significant recurrence rate (25%-50%) and a minor chance of malignant transformation.^{1,3,5,7} The rate of recurrence is even greater in those cases with extra-articular extension.⁸ Arthroscopic and endoscopic synovectomy has advantage of avoidance of extensive soft-tissue dissection, which is associated with open synovectomy.⁹

To reduce the risk of recurrence after surgical synovectomy, adjuvant treatment modalities, including external beam radiotherapy, radiation synovectomy, and systemic targeted therapies using tyrosine-kinase inhibitors or colony-stimulating factor-1 receptor inhibitors, have been proposed.^{1-3,5,10-12} However, these adjunct therapies have potential risks, including radiation-induced sarcoma. The use of adjunct radiation on a benign process such as PVNS, especially in adolescents and young adults, remains a questionable treatment strategy.^{2,10,13} These adjuvant treatments may be indicated in refractory, recurrent, aggressive, or unresectable lesions, and in patients in whom surgery would produce significant functional impairment.^{2,3,5,7,14,15} Because of the potential risks of these adjuvant treatments, we aim at complete surgical synovectomy, preferably with endoscopic and arthroscopic approaches for treatment of diffuse-type PVNS.

From the Department of Orthopaedics and Traumatology, North District Hospital, Sheung Shui, NT, Hong Kong SAR, China.

The authors report that they have no conflicts of interest in the authorship and publication of this article. Full ICMJE author disclosure forms are available for this article online, as [supplementary material](#).

Received July 3, 2022; accepted August 2, 2022.

Address correspondence to Dr TH Lui, Tun Hing Lui, M.B.B.S. (H.K.), F.R.C.S. (Edin.), F.H.K.A.M., F.H.K.C.O.S., Department of Orthopaedics and Traumatology, North District Hospital, 9 Po Kin Rd., Sheung Shui, NT, Hong Kong SAR, China. E-mail: luithderek@yahoo.co.uk

© 2022 THE AUTHORS. Published by Elsevier Inc. on behalf of the Arthroscopy Association of North America. This is an open access article under the CC BY-NC-ND license (<http://creativecommons.org/licenses/by-nc-nd/4.0/>).

2212-6287/22898

<https://doi.org/10.1016/j.eats.2022.08.001>

Table 1. Indications and Contraindications of Combined Arthroscopic and Endoscopic Synovectomy for Diffuse Pigmented Villonodular Synovitis (PVNS) of the Ankle

Indications	Contraindications
It is indicated for diffuse-type PVNS of the ankle with intra-articular and extra-articular involvement.	<ul style="list-style-type: none"> • It is contraindicated if the disease is extended to the midfoot or forefoot regions. • If the tarsal tunnel is involved, open exploration of the tarsal tunnel should be performed. • If the subtalar joint or the posterior tibial, flexor digitorum longus or peroneal tendons are involved, subtalar arthroscopy or the corresponding tendoscopy should be incorporated into this approach.

The purpose of this Technical Note is to describe the details of combined arthroscopic and endoscopic synovectomy as treatment for diffuse PVNS of the ankle. By combination of different arthroscopic and endoscopic approaches of the ankle region, a complete synovectomy of both intra-articular and extra-articular components of diffuse-type PVNS is feasible. It is indicated for diffuse-type PVNS of the ankle with intra-articular and extra-articular involvement. It is contraindicated if the disease is extended to the midfoot or forefoot regions. If the tarsal tunnel is involved, open exploration of the tarsal tunnel should be performed. If the subtalar joint or the posterior tibial, flexor digitorum longus, or peroneal tendons are involved, subtalar arthroscopy or the corresponding tendoscopy should be incorporated into this approach (Table 1).¹⁶

Surgical Technique (With Video Illustration)

Preoperative Assessment and Patient Positioning

To prevent disease recurrence, accurate evaluation of lesion location and careful operative planning are mandatory.¹⁷ Preoperative magnetic resonance imaging (MRI) of the foot and ankle is essential to suggest the diagnosis of PVNS and delineate the extent of the disease and plan the operation.¹⁸

The patient is in a supine position for the anterior ankle arthroscopy and endoscopy and then placed in a prone position for the posterior ankle arthroscopy and endoscopy. A 2.7-mm, 30° arthroscope (Henke Sass Wolf GmbH, Tuttlingen, Germany) is used for the anterior ankle arthroscopy and endoscopy and a 4.0-mm, 30° arthroscope (DYONICS; Smith & Nephew, Andover, MA) is used for the posterior ankle arthroscopy and endoscopy. A thigh tourniquet is applied to provide a bloodless operative field. Fluid inflow is driven by gravity and no arthro-pump is used.

Portal Placement

Anterior ankle arthroscopy and endoscopy is performed with the anteromedial and anterolateral portals at the ankle joint line. The anteromedial portal is just medial to the tibialis anterior tendon and the

anterolateral portal is just lateral to the peroneus tertius tendon (Fig 1).

Posterior ankle arthroscopy and endoscopy is performed via the posteromedial and posterolateral portals. The posteromedial portal is at the intersection point between the medial border of the Achilles tendon and the line joining the undersurface of the first metatarsal and sustentaculum tali. The posterolateral portal is at the lateral side of the Achilles tendon, just above the posterosuperior calcaneal tubercle (Fig 2).

Anterior Ankle Recess Synovectomy

The anteromedial and anterolateral portals are interchangeable as the viewing and working portals. The inflamed synovium is biopsied and is resected with an arthroscopic shaver (DYONICS, Smith & Nephew). Inflamed synovium of the anterior ankle capsule, anterior distal tibia, and talar neck should be resected. Any bone erosions should be debrided to remove all the synoviums (Fig 3).

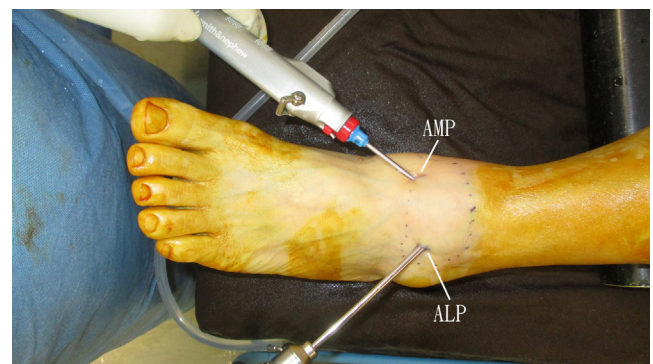


Fig 1. Combined arthroscopic and endoscopic synovectomy for diffuse pigmented villonodular synovitis of the left ankle. The patient is in the supine position for the anterior ankle arthroscopy and endoscopy and then placed in a prone position for the posterior ankle arthroscopy and endoscopy. Anterior ankle arthroscopy and endoscopy is performed with the anteromedial and anterolateral portals at the ankle joint line. The anteromedial portal is just medial to the tibialis anterior tendon and the anterolateral portal is just lateral to the peroneus tertius tendon. (ALP, anterolateral portal; AMP, anteromedial portal.)

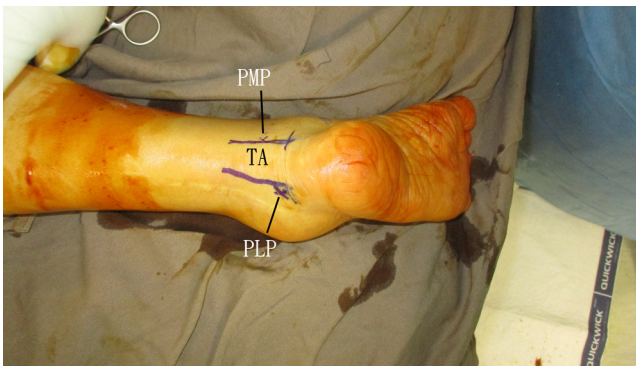
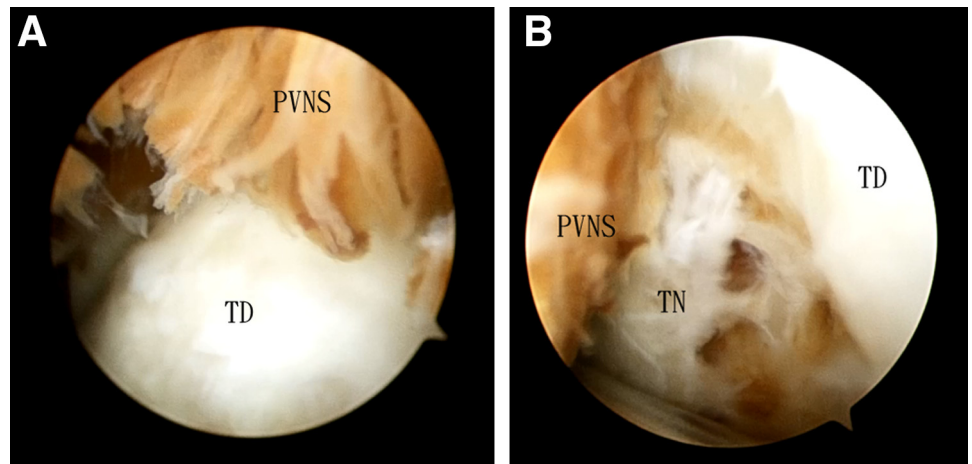


Fig 2. Combined arthroscopic and endoscopic synovectomy for diffuse pigmented villonodular synovitis of the left ankle. The patient is in the supine position for the anterior ankle arthroscopy and endoscopy and then placed in a prone position for the posterior ankle arthroscopy and endoscopy. Posterior ankle arthroscopy and endoscopy is performed via the posteromedial and posterolateral portals. The posteromedial portal is at the intersection point between the medial border of the Achilles tendon and the line joining the undersurface of the first metatarsal and sustentaculum tali. The posterolateral portal is at the lateral side of the Achilles tendon, just above the posteriosuperior calcaneal tubercle. (PLP, posterolateral portal; PMP, posteromedial portal; TA, tendo Achilles.)

Anterolateral Ankle Recess Synovectomy

The anteromedial portal is the viewing portal and the anterolateral portal is the working portal. The inflamed synovium of the anterolateral ankle recess is resected. The capsular reflection at the anterolateral edge of the lateral malleolus should be checked and synovectomy is performed if synovitis is present (Fig 4). If extra-articular PVNS is present at the anterolateral ankle, capsulotomy is performed above the anterior talofibular ligament and synovectomy of the extra-articular PVNS is performed.

Fig 3. Combined arthroscopic and endoscopic synovectomy for diffuse PVNS of the left ankle. The patient is in the supine position for the anterior ankle arthroscopy and endoscopy and then placed in a prone position for the posterior ankle arthroscopy and endoscopy. (A) The anteromedial portal is the viewing portal. The inflamed synovium of the anterior ankle recess is observed. (B) The anteromedial portal is the viewing portal. The bony erosions at the talar neck are observed. (PVNS, pigmented villonodular synovitis; TD, talar dome; TN, talar neck.)



Anteromedial Ankle Recess Synovectomy

The anterolateral portal is the viewing portal and the anteromedial portal is the working portal. The PVNS of the anteromedial ankle is resected with the shaver. The inflamed synovium at the surface of the deep deltoid ligament should be debrided. If extra-articular PVNS is present at the anteromedial ankle, capsulotomy of the anteromedial ankle capsule is performed and synovectomy of the extra-articular PVNS is performed (Fig 5).

Anterior Ankle Extra-Articular Synovectomy

The anteromedial and anterolateral portals are interchangeable as the viewing and working portals. The anterior ankle capsule is stripped from distal tibia by means of the arthroscopic shaver to expose the anterior ankle extra-articular PVNS and synovectomy is performed (Fig 6). During this step, the shaver blade should face toward the cortical bone of the distal tibia to avoid injury to the neurovascular bundle, tendons, and muscles of the anterior compartment of the leg and ankle. The ankle can be kept in neutral or dorsiflexed position to relax the anterior compartment structures and increase the endoscopic working space. After complete synovectomy of the anterior ankle, arthroscopy of the ankle joint proper is performed and chondral lesion, if any, is debrided.

Flexor Hallucis Longus Synovectomy

The patient is turned to the prone position. The posterolateral portal is the viewing portal and the posteromedial portal is the working portal. The flexor hallucis longus (FHL) tendon is traced up to the FHL muscle. The PVNS around the FHL tendon and muscle is resected with an arthroscopic shaver (DYONICS, Smith & Nephew) (Fig 7). The suction should be kept in a minimum and the shaver blade should face away the tendon and muscle to avoid injury to them. The tendon

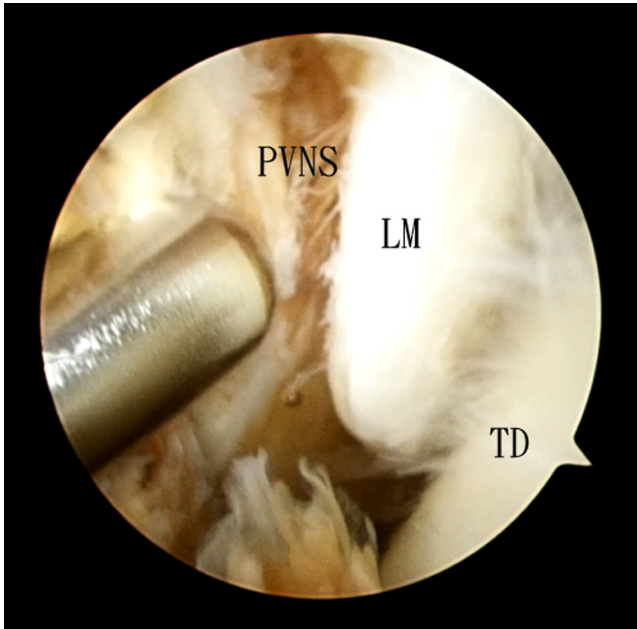


Fig 4. Combined arthroscopic and endoscopic synovectomy for diffuse PVNS of the left ankle. The patient is in the supine position for the anterior ankle arthroscopy and endoscopy and then placed in a prone position for the posterior ankle arthroscopy and endoscopy. The anteromedial portal is the viewing portal and the anterolateral portal is the working portal. The inflamed synovium of the anterolateral ankle recess is resected. The capsular reflection at the anterolateral edge of the lateral malleolus should be checked and synovectomy is performed if synovitis is present. (LM, lateral malleolus; PVNS, pigmented villonodular synovitis; TD, talar dome.)

is traced distally to the fibro-osseous hiatus at the posterior talus. If there is evidence of extension of PVNS along the FHL tendon to underneath the sustentaculum tali (zone 2), zone 2 FHL tendoscopy is performed to ensure complete synovectomy of the tendon.⁹

Posterior Ankle Recess Synovectomy

The posterolateral portal is the viewing portal and the posteromedial portal is the working portal. Posterior ankle capsulotomy is performed with the shaver at the lateral side of the FHL tendon with the shaver facing away the tendon. The capsulotomy is extended medially with the FHL tendon retracted by the shaver. After capsulotomy, the PVNS of the posterior ankle recess is resected with the shaver lateral to the FHL tendon. The most medial part of the posterior ankle recess is debrided with the shaver medial to the FHL tendon. The step should be performed under clear endoscopic visualization and the ankle is plantarflexed to relax the tibial neurovascular bundle (Fig 8).

Posterolateral Ankle Recess Synovectomy

The posteromedial portal is the viewing portal and the posterolateral portal is the working portal. PVNS of the posterolateral ankle is resected. The calcaneofibular ligament is then exposed and the inflamed synovium around the ligament is carefully resected with preservation of the ligament (Fig 9). If the preoperative MRI suggests the peroneal tendons are involved, the peroneal tendon sheath can be incised open for synovectomy of the peroneal tendons.

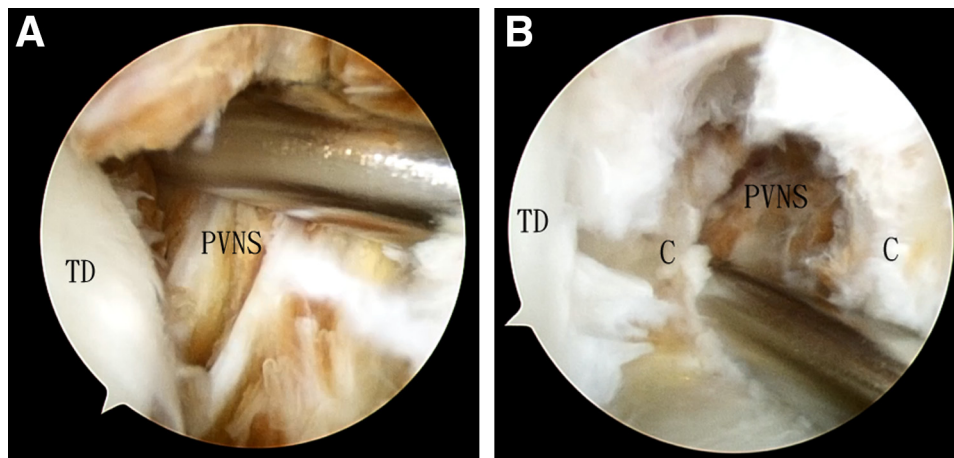


Fig 5. Combined arthroscopic and endoscopic synovectomy for diffuse PVNS of the left ankle. The patient is in the supine position for the anterior ankle arthroscopy and endoscopy and then placed in a prone position for the posterior ankle arthroscopy and endoscopy. (A) The anterolateral portal is the viewing portal and the anteromedial portal is the working portal. The inflamed synovium of the anteromedial ankle is resected with the shaver. The inflamed synovium at the surface of the deep deltoid ligament should be debrided. (B) The anterolateral portal is the viewing portal and the anteromedial portal is the working portal. The extra-articular inflamed synovium is resected via the anteromedial ankle capsulotomy site. (C, anteromedial ankle capsule; PVNS, pigmented villonodular synovitis; TD, talar dome.)

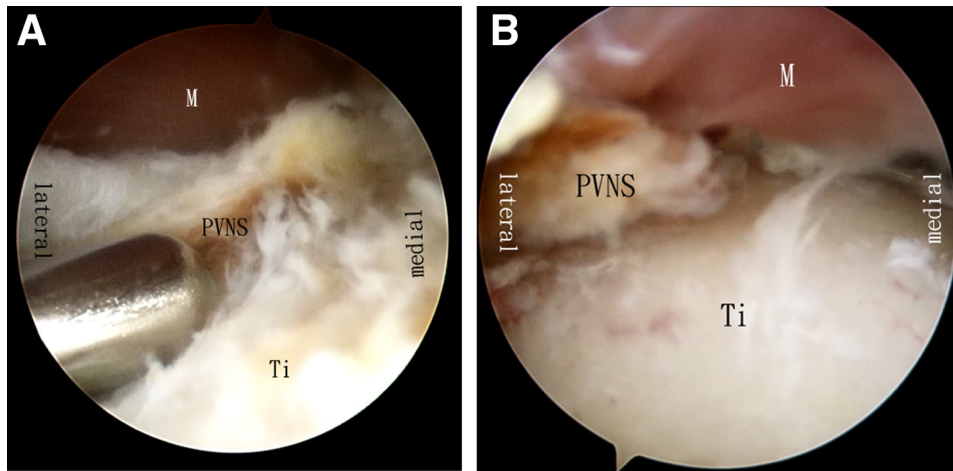


Fig 6. Combined arthroscopic and endoscopic synovectomy for diffuse PVNS of the left ankle. The patient is in the supine position for the anterior ankle arthroscopy and endoscopy and then placed in a prone position for the posterior ankle arthroscopy and endoscopy. The anteromedial and anterolateral portals are interchangeable as the viewing and working portals. The anterior ankle capsule is stripped from distal tibia by means of the arthroscopic shaver in order to expose the anterior ankle extra-articular PVNS and synovectomy is performed. (A) Extra-articular synovectomy of anterior ankle with the anteromedial portal as the viewing portal and the anterolateral portal as the working portal. (B) Extra-articular synovectomy of anterior ankle with the anterolateral portal as the viewing portal and the anteromedial portal as the working portal. (M, muscles of the anterior leg compartment; PVNS, pigmented villonodular synovitis; Ti, tibia.)

Distal Tibiofibular Syndesmosis Synovectomy

The posteromedial portal is the viewing portal and the posterolateral portal is the working portal. The PVNS above the posterior inferior tibiofibular ligament is resected with preservation of the ligament (Fig 10).

Posteromedial Ankle Recess, Flexor Digitorum Longus Synovectomy

The posteromedial portal is the viewing portal and the posterolateral portal is the working portal. Synovectomy of the posteromedial ankle recess is performed to

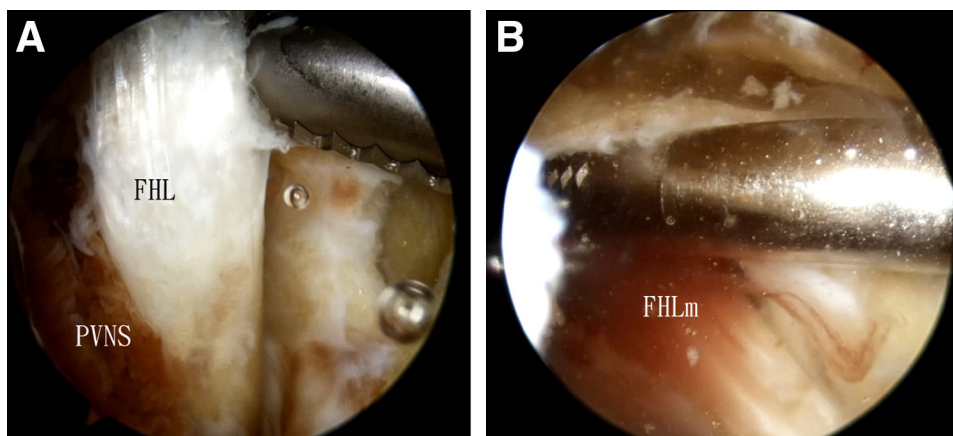


Fig 7. Combined arthroscopic and endoscopic synovectomy for diffuse PVNS of the left ankle. The patient is in the supine position for the anterior ankle arthroscopy and endoscopy and then placed in a prone position for the posterior ankle arthroscopy and endoscopy. (A) The posterolateral portal is the viewing portal and the posteromedial portal is the working portal. The inflamed synovium around the flexor hallucis longus tendon is resected. (B) The posterolateral portal is the viewing portal and the posteromedial portal is the working portal. The inflamed synovium around the flexor hallucis longus muscle is resected. (FHL, flexor hallucis longus; FHLm, flexor hallucis longus muscle; PVNS, pigmented villonodular synovitis.)

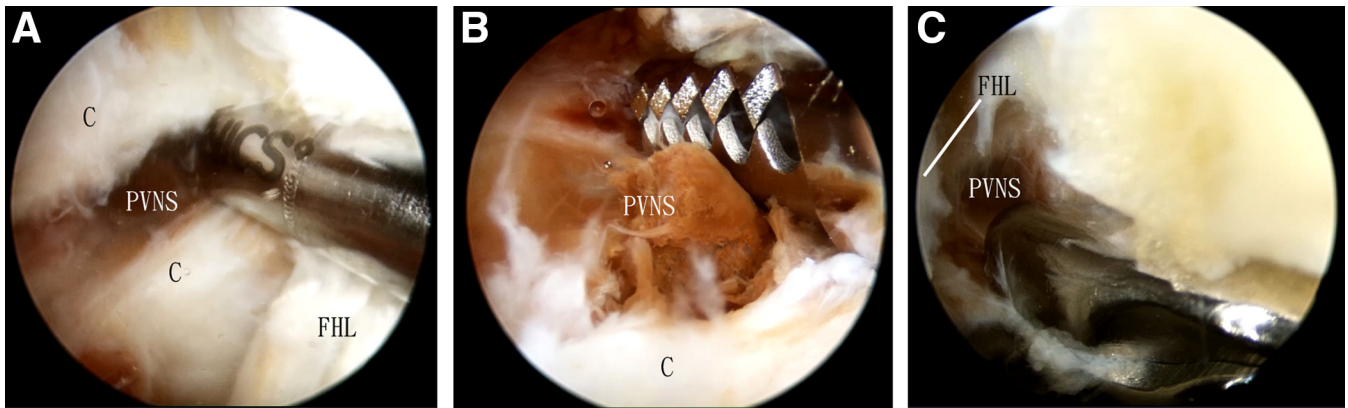


Fig 8. Combined arthroscopic and endoscopic synovectomy for diffuse PVNS of the left ankle. The patient is in supine position for the anterior ankle arthroscopy and endoscopy and then put in prone position for the posterior ankle arthroscopy and endoscopy. (A) The posterolateral portal is the viewing portal and the posteromedial portal is the working portal. Posterior ankle capsulotomy is performed with the shaver at the lateral side of the FHL tendon with the shaver facing away from the tendon. The capsulotomy is extended medially with the FHL tendon retracted by the shaver. (B) The posterolateral portal is the viewing portal and the posteromedial portal is the working portal. After capsulotomy, the PVNS of the posterior ankle recess is resected with the shaver lateral to the FHL tendon. (C) The posterolateral portal is the viewing portal and the posteromedial portal is the working portal. The most medial part of the posterior ankle recess is debried with the shaver medial to the FHL tendon. (C, posterior ankle capsule; FHL, flexor hallucis longus; PVNS, pigmented villonodular synovitis.)

expose the posteromedial part of the talar body. This step is performed medial to the FHL tendon and the ankle must not be dorsiflexed so that the tibial

neurovascular bundle is not tense up and impinged by the stem of the arthroscopic shaver. If indicated, the flexor digitorum longus tendon sheath is opened and

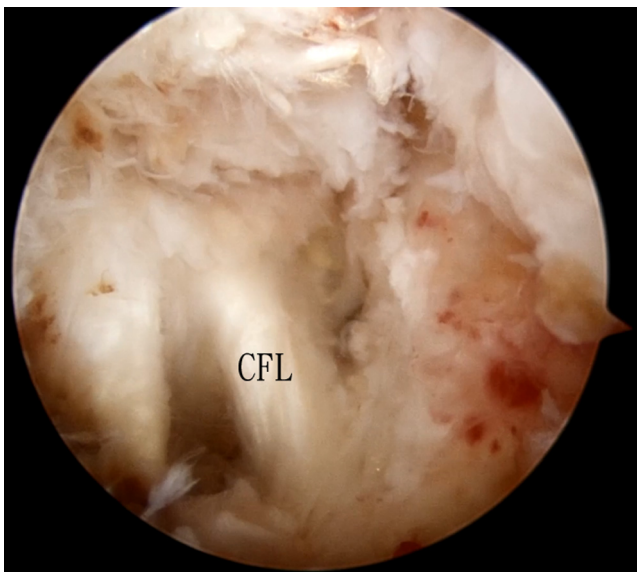


Fig 9. Combined arthroscopic and endoscopic synovectomy for diffuse PVNS of the left ankle. The patient is in supine position for the anterior ankle arthroscopy and endoscopy and then put in prone position for the posterior ankle arthroscopy and endoscopy. The posteromedial portal is the viewing portal and the posterolateral portal is the working portal. Inflamed synovium of the posterolateral ankle is resected. The calcaneofibular ligament is then exposed and the inflamed synovium around the ligament is carefully resected with preservation of the ligament. (CFL, calcaneofibular ligament; PVNS, pigmented villonodular synovitis.)

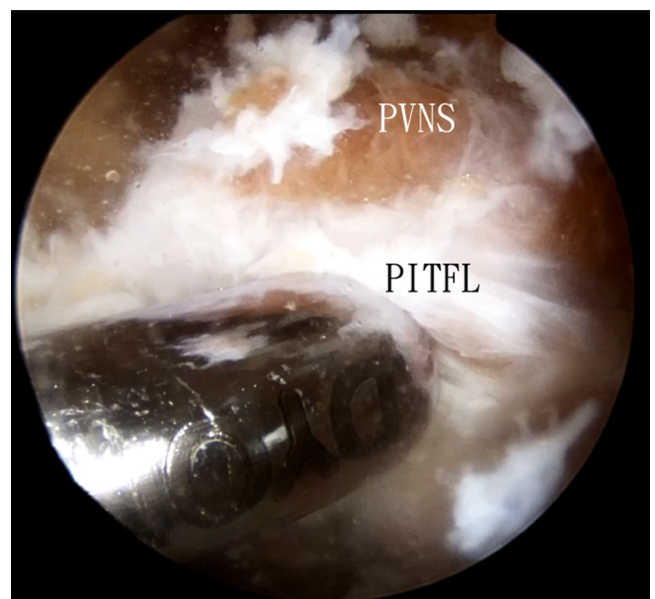


Fig 10. Combined arthroscopic and endoscopic synovectomy for diffuse PVNS of the left ankle. The patient is in the supine position for the anterior ankle arthroscopy and endoscopy and then placed in a prone position for the posterior ankle arthroscopy and endoscopy. The posteromedial portal is the viewing portal and the posterolateral portal is the working portal. The inflamed synovium above the posterior inferior tibiofibular ligament is resected with preservation of the ligament. (PITFL, posterior inferior tibiofibular ligament; PVNS, pigmented villonodular synovitis.)

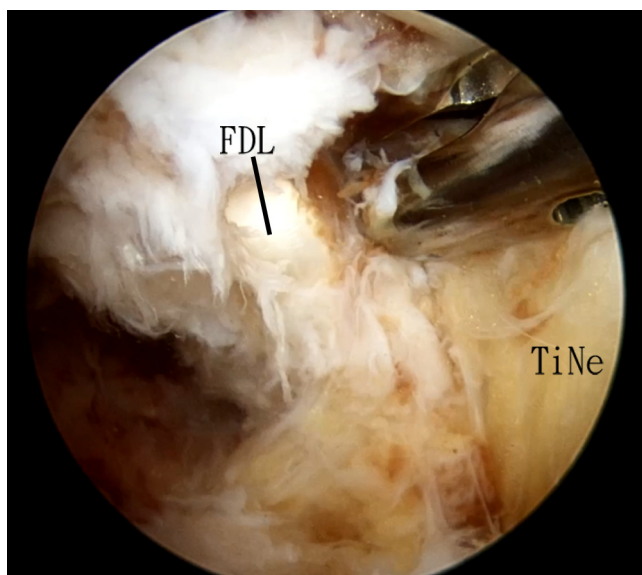


Fig 11. Combined arthroscopic and endoscopic synovectomy for diffuse pigmented villonodular synovitis of the left ankle. The patient is in the supine position for the anterior ankle arthroscopy and endoscopy and then placed in a prone position for the posterior ankle arthroscopy and endoscopy. The posteromedial portal is the viewing portal and the posterolateral portal is the working portal. The FDL tendon sheath is opened and synovectomy of the tendon is performed. (FDL, flexor digitorum longus; TiNe, tibial nerve.)

synovectomy of the tendon is performed (Fig 11). Again, the ankle is plantarflexed to relax the tibial neurovascular bundle. The step should be performed under clear endoscopic visualization.

Tibial Nerve Synovectomy

The posteromedial portal is the viewing portal and the posterolateral portal is the working portal. PVNS around the tibial nerve is carefully removed by an arthroscopic punch (Arthrex, Naples, FL) (Fig 12). This step should be performed under clear arthroscopic visualization and arthroscopic shaver should not be used.

Tibial Nerve Endoscopy (Optional)

If there is suspicion of extension of PVNS along the tibial nerve to the tarsal tunnel, tibial nerve endoscopy can be performed. The posterolateral portal is the viewing portal. A 4-mm Wissinger rod (DYONICS, Smith & Nephew) is inserted through the posteromedial portal, along the tibial nerve into the tarsal tunnel. The arthroscopic cannula is inserted along the rod via the posteromedial portal. The rod is then removed and the arthroscope is inserted into the cannula. The posteromedial portal is the viewing portal and tarsal tunnel is then examined. If PVNS extends into the tarsal tunnel, open tarsal tunnel exploration and synovectomy are performed (Fig 13, Video 1).

Discussion

The goal of treatment of diffuse-type PVNS is complete synovectomy of both the intra-articular and extra-articular components of the disease. Careful study of the preoperative MRI is essential for planning of the surgical approaches.

To minimize the risk of seeding diseased tissue to the surrounding soft tissues, the electromechanical arthropump should not be used.⁹ To address the extra-articular PVNS of the anterior ankle, stripping of the anterior ankle capsule from the distal tibia to gain access to the extra-articular space is preferred to anterior ankle capsulotomy, because the shaver blade is facing toward the tibia and not the capsule and the risk of injury to the tendons and neurovascular bundle of the anterior ankle is minimized.

For posterior ankle endoscopy, the posteromedial portal is placed a bit more proximal than the posterolateral portal. This may reduce the risk of impingement injury to the posterior tibial neurovascular bundle.¹⁹ Moreover, this can promote the use of zone 2 FHL (underneath the sustentaculum tali) tendoscopy, if indicated.¹⁹⁻²⁴ For synovectomy of the posteromedial ankle, it should be performed under direct endoscopic visualization. The shaver blade should face laterally and the suction should be kept to minimum. Moreover, the ankle should not be dorsiflexed, so that

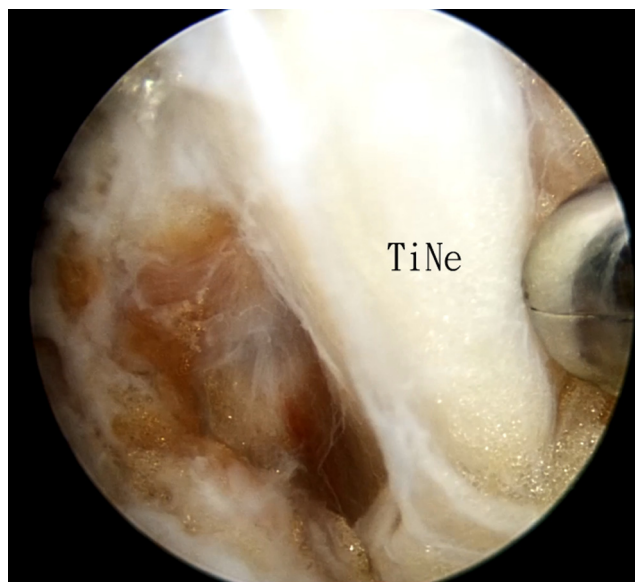


Fig 12. Combined arthroscopic and endoscopic synovectomy for diffuse pigmented villonodular synovitis of the left ankle. The patient is in the supine position for the anterior ankle arthroscopy and endoscopy and then placed in a prone position for the posterior ankle arthroscopy and endoscopy. The posteromedial portal is the viewing portal and the posterolateral portal is the working portal. Inflamed synovium around the tibial nerve is carefully removed by an arthroscopic punch. (TiNe, tibial nerve.)

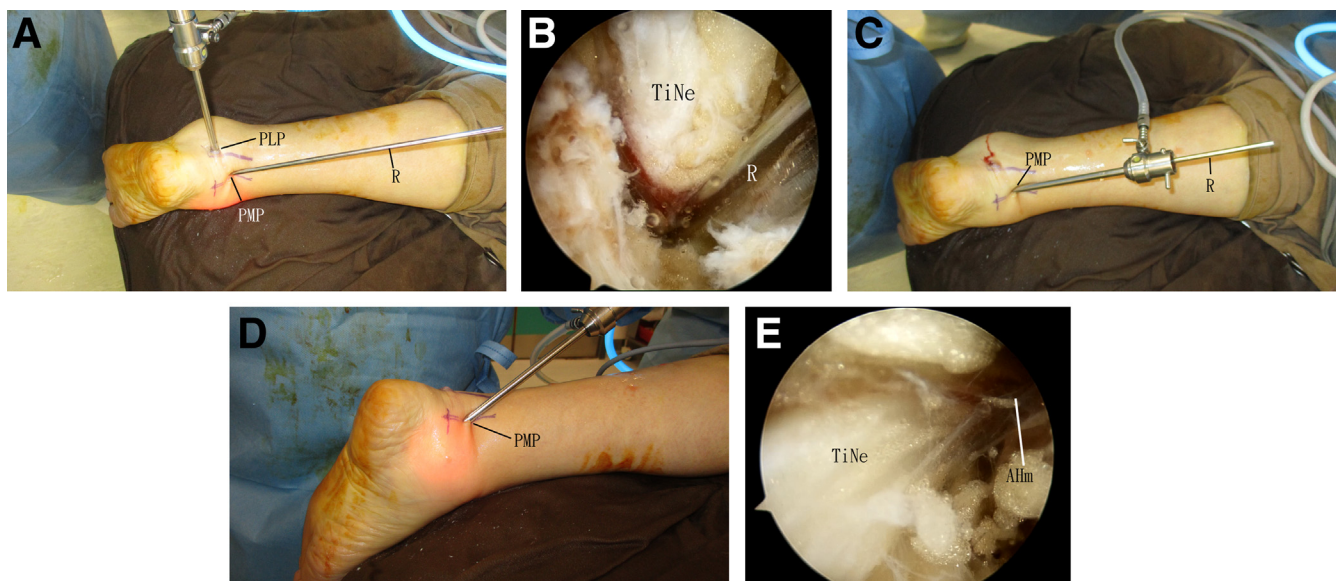


Fig 13. Combined arthroscopic and endoscopic synovectomy for diffuse pigmented villonodular synovitis (PVNS) of the left ankle. The patient is in the supine position for the anterior ankle arthroscopy and endoscopy and then placed in a prone position for the posterior ankle arthroscopy and endoscopy. If there is suspicion of extension of PVNS along the tibial nerve to the tarsal tunnel, tibial nerve endoscopy can be performed. (A) The posterolateral portal is the viewing portal. A 4-mm Wissinger rod is inserted through the posteromedial portal, along the tibial nerve into the tarsal tunnel. (B) The posterolateral portal is the viewing portal and the posteromedial portal is the working portal. A Wissinger rod is inserted along the tibial nerve. (C) The arthroscopic cannula is inserted along the rod via the posteromedial portal. (D) The rod is then removed and the arthroscope is inserted into the cannula. (E) The posteromedial portal is the viewing portal and the tarsal tunnel is then examined. (AHm, abductor hallucis muscle; PLP, posterolateral portal; PMP, posteromedial portal; TiNe, tibial nerve.)

the posterior tibial neurovascular bundle is not tensed up and brought into contact with the shaver shaft.²⁵ These precautions can minimize the risk of neurovascular injury (Table 2).

The advantages of this technique include small incisions and better cosmetic outcome, minimal soft-tissue trauma, and synovectomy under magnified arthroscopic

visualization. The potential risks of this technique include injury to the articular cartilage, the cutaneous nerve injury, tibial neurovascular bundle, dorsalis pedis artery and deep peroneal nerve, tendons and ligaments, and incomplete resection of the lesion (Table 3). This is technique technically demanding and should be reserved for the experienced foot and ankle arthroscopist.

Table 2. Pearls and Pitfalls of Combined Arthroscopic and Endoscopic Synovectomy for Diffuse Pigmented Villonodular Synovitis (PVNS) of the Ankle

Pearls	Pitfalls
<ul style="list-style-type: none"> Careful study of the preoperative MRI is essential for planning of the surgical approaches. To minimize the risk of seeding diseased tissue to the surrounding soft tissues, the electromechanical arthro-pump should not be used. To deal with the extra-articular PVNS of the anterior ankle, the anterior ankle capsule is stripped from the distal tibia to gain access to the extra-articular space. For posterior ankle endoscopy, the posteromedial portal is placed a bit more proximal than the posterolateral portal. For synovectomy of the posteromedial ankle, it should be performed under direct endoscopic visualization. The shaver blade should face laterally and the suction should be kept to minimum. Moreover, the ankle should not be dorsiflexed. 	<ul style="list-style-type: none"> Anterior ankle capsulotomy to access the extra-articular PVNS of the anterior ankle is risky to the extensor tendons, dorsalis pedis artery, and the deep peroneal nerve. During synovectomy of the posteromedial ankle, dorsiflexing the ankle to gain access to the deep part is dangerous, as the posterior tibial neurovascular bundle is tensed up and brought into contact with the shaver shaft.

MRI, magnetic resonance imaging.

Table 3. Advantages and Risks of Combined Arthroscopic and Endoscopic Synovectomy for Diffuse Pigmented Villonodular Synovitis of the Ankle

Advantages	Risks
<ul style="list-style-type: none"> • Small incisions and better cosmetic outcome • Minimal soft-tissue trauma • Synovectomy under magnified arthroscopic visualization. 	<ul style="list-style-type: none"> • Injury to the articular cartilage • Injury to the cutaneous nerve injury • Injury to the tibial neurovascular bundle • Injury to the dorsalis pedis artery and deep peroneal nerve • Injury to the tendons and ligaments • Incomplete resection of the lesion

References

1. Temple HT. Pigmented villonodular synovitis therapy with MSCF-1 inhibitors. *Curr Opin Oncol* 2012;24:404-408.
2. Stephan SR, Shallop B, Lackman R, Kim TW, Mulcahey MK. Pigmented villonodular synovitis: A comprehensive review and proposed treatment algorithm. *JBJS Rev* 2016;4:e3.
3. Savvidou OD, Mavrogenis AF, Sakellariou VI, Chloros GD, Sarlikiotis T, Papagelopoulos PJ. Extra-articular diffuse giant cell tumor of the tendon sheath: A report of 2 cases. *Arch Bone Joint Surg* 2016;4:273-276.
4. Rana R, Behera S, Jeetendra C. Pigmented villonodular synovitis of flexor hallucis longus, flexor digitorum longus, tibialis posterior: A rare case report. *Cureus* 2022;14:e24595.
5. van der Heijden L, Gibbons CL, Dijkstra PD, et al. The management of diffuse-type giant cell tumour (pigmented villonodular synovitis) and giant cell tumour of tendon sheath (nodular tenosynovitis). *J Bone Joint Surg Br* 2012;94:882-888.
6. Kaneko K, Nakahara D, Tobe M, et al. Pigmented villonodular synovitis of the ankle in an adolescent. *Int Orthop (SICOT)* 2000;24:234-237.
7. Gouin F, Noailles T. Localized and diffuse forms of tenosynovial giant cell tumor (formerly giant cell tumor of the tendon sheath and pigmented villonodular synovitis). *Orthop Traumatol Surg Res* 2017;103:S91-S97.
8. Guo Q, Shi W, Jiao C, Xie X, Jiang D, Hu Y. Results and recurrence of pigmented villonodular synovitis of the ankle: Does diffuse PVNS with extra-articular extension tend to recur more often? *Knee Surg Sports Traumatol Arthrosc* 2018;26:3118-3123.
9. Lui TH. Pigmented villonodular synovitis of the flexor hallucis longus tendon treated by means of tendoscopy and endoscopic synovectomy. *J Foot Ankle Surg* 2021;60:856-860.
10. Gross CE, Frank RM, Hsu AR, Diaz A, Gitelis S. External beam radiation therapy for orthopaedic pathology. *J Am Acad Orthop Surg* 2015;23:243-252.
11. Ćwikła JB, Żbikowski P, Kwiatkowska B, Buscombe JR, Sudoł-Szopińska I. Radiosynovectomy in rheumatic diseases. *J Ultrason* 2014;14:241-251.
12. Iakovou I, Symeonidis P, Kotrotsios D, Giannoula E, Sachpekidis C. Radiosynoviorthesis after surgery in the treatment of patients with ankle pigmented villonodular synovitis: A case series. *J Clin Med* 2020;9.
13. McKeown SR, Hatfield P, Prestwich RJ, Shaffer RE, Taylor RE. Radiotherapy for benign disease; assessing the risk of radiation-induced cancer following exposure to intermediate dose radiation. *Br J Radiol* 2015;88:20150405.
14. Ravi V, Wang WL, Lewis VO. Treatment of tenosynovial giant cell tumor and pigmented villonodular synovitis. *Curr Opin Oncol* 2011;23:361-366.
15. Brahma M, Vinceneux A, Cassier PA. Current systemic treatment options for tenosynovial giant cell tumor/pigmented villonodular synovitis: Targeting the CSF1/CSF1R Axis. *Curr Treat Options Oncol* 2016;17:10.
16. Lui TH. Flexor digitorum longus tendoscopy. *J Foot Ankle Surg* 2012;51:690-692.
17. Muramatsu K, Iwanaga R, Tominaga Y, Hashimoto T, Taguchi T. Diffuse pigmented villonodular synovitis around the ankle. *J Am Podiatr Med Assoc* 2018;108:140-144.
18. Zhao WQ, Zhao B, Li WS, Assan I. Subtalar joint pigmented villonodular synovitis misdiagnosed at the first visit: A case report. *World J Clin Cases* 2021;9:1379-1385.
19. Lui TH, Chan LK. Posterior ankle and hindfoot endoscopy: A cadaveric study. *Foot Ankle Surg* 2016;22:186-190.
20. Lui TH. Flexor hallucis longus tendoscopy: A technical note. *Knee Surg Sports Traumatol Arthrosc* 2009;17:107-110.
21. Lui TH. Arthroscopic synovectomy for Zone 2 flexor hallucis longus tenosynovitis. *Arthrosc Tech* 2015;4:e403-e405.
22. Lui TH, Chow FY. "Intersection syndrome" of the foot: Treated by endoscopic release of master knot of Henry. *Knee Surg Sports Traumatol Arthrosc* 2011;19:850-852.
23. Lui TH, Chan KB, Chan LK. Zone 2 flexor hallucis longus tendoscopy: A cadaveric study. *Foot Ankle Int* 2009;30:447-451.
24. Lui TH, Chan KB, Chan LK. Cadaveric study of zone 2 flexor hallucis longus tendon sheath. *Arthroscopy* 2010;26:808-812.
25. Lui TH. Lateral plantar nerve neuropraxia after FHL tendoscopy: Case report and anatomic evaluation. *Foot Ankle Int* 2010;31:828-831.