

Case Report

Usefulness of neuroimaging and immunohistochemical study for accurate diagnosis of chordoid glioma of the third ventricle: A case report and review of the literature

Tomoki Shinohara, Akihiro Inoue, Shohei Kohno, Yasuo Ueda¹, Satoshi Suehiro, Shirabe Matsumoto, Masahiro Nishikawa, Saya Ozaki, Seiji Shigekawa, Hideaki Watanabe, Riko Kitazawa¹, Takeharu Kunieda

Department of Neurosurgery, Ehime University School of Medicine, ¹Division of Diagnostic Pathology, Ehime University Hospital, 454 Shitsukawa, Toon, Ehime 791-0295, Japan

E-mail: Tomoki Shinohara - freude1993@gmail.com; *Akihiro Inoue - iakihiro3@gmail.com; Shohei Kohno - kouno@m.ehime-u.ac.jp; Yasuo Ueda - ueda.yasuo.is@ehime-u.ac.jp; Satoshi Suehiro - satoshi.suehiro@gmail.com; Shirabe Matsumoto - shirabem@m.ehime-u.ac.jp; Masahiro Nishikawa - ma.nishikawa1985@gmail.com; Saya Ozaki - saya.ozaki38@gmail.com; Seiji Shigekawa - shigekaw@m.ehime-u.ac.jp; Hideaki Watanabe - whideaki@m.ehime-u.ac.jp; Riko Kitazawa - riko@m.ehime-u.ac.jp; Takeharu Kunieda - kuny@m.ehime-u.ac.jp

*Corresponding author

Received: 31 August 18 Accepted: 01 October 18 Published: 02 November 18

Abstract

Background: Chordoid glioma of the third ventricle is a rare neuroepithelial tumor characterized by a unique histomorphology within the third ventricular region, but with radiological and histopathological features mimicking benign lesions such as meningioma. We report a case of chordoid glioma of the third ventricle and suggest a useful indicator for accurate diagnosis.

Case Description: A previously healthy 46-year-old woman was admitted to our hospital with mild headache. Neuroimaging revealed a large tumor measuring approximately 18 mm in the suprasellar region, and perifocal edema in the optic tract and internal capsule on magnetic resonance imaging. Laboratory findings revealed no pituitary dysfunction including diabetes insipidus. Gross total resection of the tumor was performed by the interhemispheric translamina terminalis approach. Histological findings revealed nests of regular epithelioid cells with large nuclei and abundant eosinophilic cytoplasm within myxoid stroma. Immunohistochemical studies demonstrated diffuse cytoplasmic expression of glial fibrillary acidic protein (GFAP) and CD34, and strong nuclear staining for thyroid transcription factor 1 (TTF-1). We, therefore, histologically classified the tumor as chordoid glioma of the third ventricle. Headache improved immediately postoperatively, and follow-up neuroimaging after 12 months showed no signs of recurrence.

Conclusions: Chordoid glioma of the third ventricle is a very rare tumor that is difficult to diagnose on routine neuroimaging. Accurate diagnosis requires detailed

Access this article online

Website:

www.surgicalneurologyint.com

DOI:

10.4103/sni.sni_306_18

Quick Response Code:



This is an open access journal, and articles are distributed under the terms of the Creative Commons Attribution-NonCommercial-ShareAlike 4.0 License, which allows others to remix, tweak, and build upon the work non-commercially, as long as appropriate credit is given and the new creations are licensed under the identical terms.

For reprints contact: reprints@medknow.com

How to cite this article: Shinohara T, Inoue A, Kohno S, Ueda Y, Suehiro S, Matsumoto S, et al. Usefulness of neuroimaging and immunohistochemical study for accurate diagnosis of chordoid glioma of the third ventricle: A case report and review of the literature. *Surg Neurol Int* 2018;9:226.
<http://surgicalneurologyint.com/Usefulness-of-neuroimaging-and-immunohistochemical-study-for-accurate-diagnosis-of-chordoid-glioma-of-the-third-ventricle-A-case-report-and-review-of-the-literature/>

analysis of neuroimaging and immunohistochemical studies using CD34 and TTF-1 staining.

Key Words: CD34, chordoid glioma of the third ventricle, interhemispheric trans-lamina terminalis approach, perifocal edema in optic tract, thyroid transcription factor 1

INTRODUCTION

Chordoid glioma of the third ventricle is a rare, slow-growing, noninvasive glial tumor in the third ventricle with uncertain histogenesis and chordoid appearance, first described as a clinicopathologic entity by Brat and colleagues in 1998.^[3] This tumor was initially considered a variant of meningioma, but was subsequently accepted as a distinct glioma and classified as grade II according to the 2016 World Health Organization (WHO) classification of brain tumors.^[2,3,9,12-14,19,20] Due to its rarity, the definitive features of the clinical course, treatment strategy, and prognosis have not been elucidated.^[3,8,13] Therefore, it is necessary for recognizing the characteristic features of this tumor, including neuroimaging, pathological findings, and risks of surgical procedures. Here, we report a case of chordoid glioma of the third ventricle, and suggest both useful indicators for accurate diagnosis using findings from neuroimaging and pathological examinations, and pitfalls for the treatment strategy.

CASE DESCRIPTION

A previously healthy 46-year-old woman presented to our department with a 6-month history of mild headache. Intracranial computed tomography (CT) revealed an iso-dense mass without calcification in the anterior area of the third ventricle. Magnetic resonance imaging (MRI) demonstrated that the tumor (diameter, 14 × 18 × 18 mm) was predominantly isointense on T1-weighted imaging (T1WI) and T2-weighted imaging (T2WI), and homogeneously enhanced to a high degree with gadolinium (Gd) [Figure 1]. The optic chiasma was displaced downwards, and the anterior wall of the third ventricle was deviated. Perilesional edema reaching up to the mesencephalon bilaterally and the internal capsule associated with compression by the tumor mass were clearly observable on fluid-attenuated inversion recovery (FLAIR) MRI [Figure 2]. No pituitary insufficiency was evident from laboratory examinations. Preoperative differential diagnoses included intraventricular meningioma, craniopharyngioma, ependymoma, and chordoid glioma of the third ventricle. To confirm the histological diagnosis, the tumor was resected microsurgically under an interhemispheric trans-lamina terminalis approach to the third ventricle.

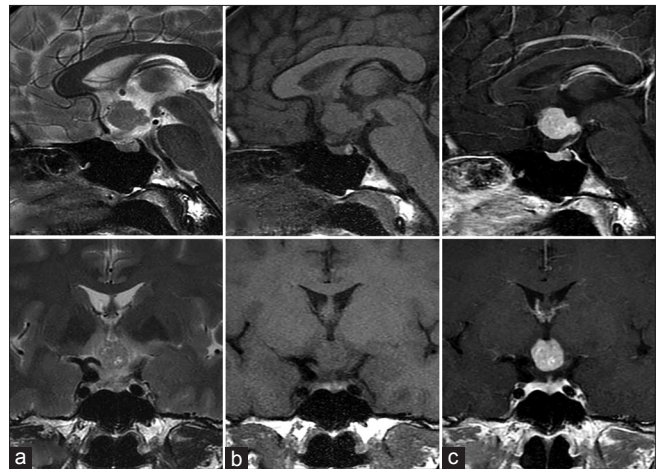


Figure 1: Preoperative T2-weighted (a), T1-weighted (b), and gadolinium-enhanced T1-weighted (c) magnetic resonance imaging (MRI) shows a tumor mass in the suprasellar region. The tumor shows a high level of homogeneous enhancement with gadolinium

Intraoperative examination demonstrated that the tumor was firm, rubbery, and nonsuckable, and appeared to be originating from the lamina terminalis with a clear margin between normal structures including the hypothalamus. We achieved gross total resection of the tumor to reduce compression of the optic nerve. Histopathological examination with hematoxylin and eosin (HE) staining of the tumor showed a neoplastic tissue comprising eosinophilic epithelioid cells with large nucleoli arranged in small sheets, within mucinous stroma. Sparse lymphocytic infiltrate was present, and no mitosis was detected [Figure 3]. Immunohistochemical studies were performed using antibodies for glial fibrillary acidic protein (GFAP) (rabbit polyclonal antibody; DAKO; ready to use), CD34 (mouse monoclonal antibody; clone 9BEnd10; DAKO; ready to use), thyroid transcription factor (TTF)-1 (mouse monoclonal antibody; clone 8G7G3/1; DAKO; ready to use), and Ki-67 (mouse monoclonal antibody; clone MIB-1; DAKO; ready to use). Most tumor cells showed immunoreactivity for GFAP and CD34 [Figure 4a and b]. In addition, almost all tumor cells appeared strongly positive for TTF-1 [Figure 4c]. The Ki-67 (MIB-1) proliferation-related labeling index was low, at 2.0% [Figure 4d]. With regard to the genetic profile, these tumor cells were immunonegative for R132H-mutated isocitrate dehydrogenase-1. Taking all these results into account, the final diagnosis was

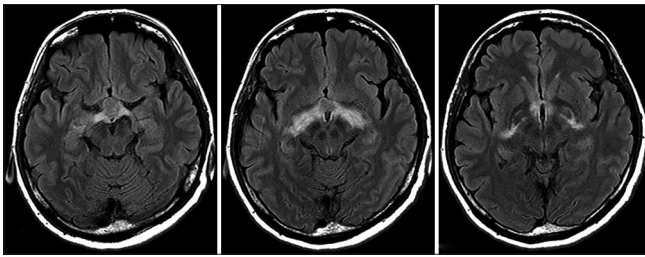


Figure 2: Preoperative axial fluid-attenuated inversion recovery (FLAIR) on MRI shows perifocal vasogenic edema reaching up to the mesencephalon bilaterally and to the internal capsule

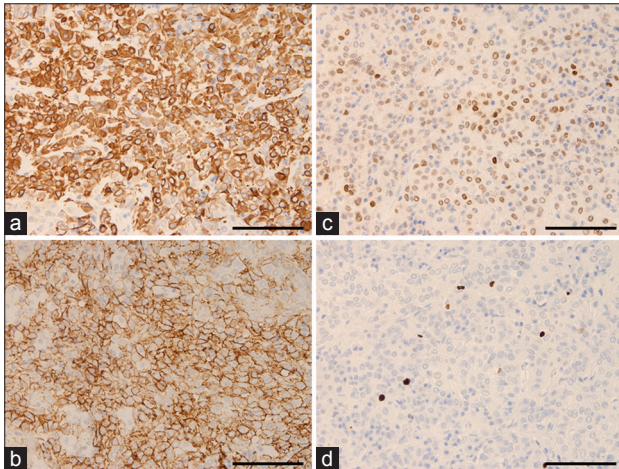


Figure 4: Photomicrographs revealing immune-histopathology of the tumor. Most tumor cells are strongly immunoreactive for GFAP (a), CD34 (b) and TTF-1 (c). This tumor shows slightly positive staining for Ki-67 (MIB-1) (MIB-1 labeling index: 2.0%) (d). Magnification, a-d) $\times 400$. Scale bar, a-d) 100 μm

chordoid glioma of the third ventricle in accordance with the 2016 WHO Classification of Tumors of the central nervous system (CNS).^[13] The postoperative course was uneventful and her headache improved immediately. MRI at 1 year after the initial treatment did not show any residual tumor [Figure 5].

DISCUSSION

Chordoid glioma of the third ventricle is a rare tumor with both glial and chordoid features. This tumor is currently recognized as a distinct glioma with grade II malignancy.^[2,3,9,12-14,19,20] In previous reports, chordoid glioma has been described as tending to occur in middle-aged and older adults (25–75 years).^[8,15] The clinical symptoms of this tumor are variable, according to tumor size and location.^[3,4,9,12,18,19] However, the epidemiology has not been clarified because of the low incidence of this tumor.

In terms of imaging characteristics, preoperative identification of this tumor with radiological examinations may be difficult. In general, MRI depicts chordoid glioma as isointense on T1WI, and iso- or

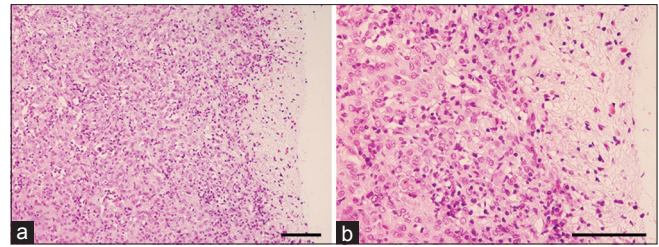


Figure 3: Histopathology of the resected tumor demonstrates solid neoplasms comprising clusters and cords of epithelioid tumor cells within variably mucinous stroma that typically contains a lymphoplasmacytic infiltrate (a and b). Nuclei are round to oval in appearance without evidence of cellular atypia or mitotic figures. Magnification, a) $\times 200$, b) $\times 400$. Scale bar, a) 250 μm , b) 100 μm

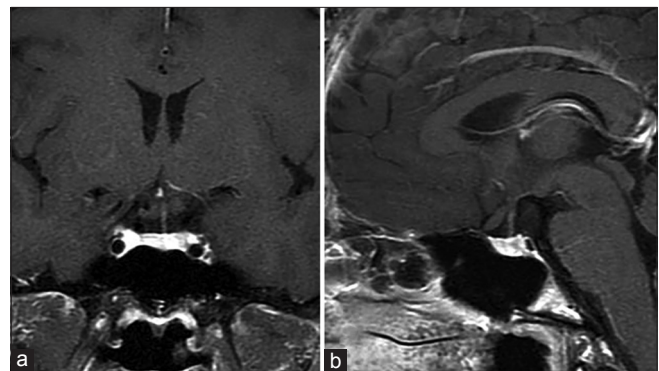


Figure 5: Postoperative (a) sagittal and (b) coronal images of gadolinium-enhanced MRI at 12 months after surgical resection show no residual tumor in the suprasellar region

slightly hyperintense on T2WI. Strong enhancement has been seen after administration of Gd.^[3,8,19] In addition, another report described this tumor mass as generally showing a symmetrical distribution and causing vasogenic edema in compressed adjacent CNS structures, including the optic tracts, basal ganglia, and internal capsules.^[6,13] This perifocal edema in the optic tracts or basal ganglia on MRI (FLAIR) is extremely interesting and seems to be the key finding for accurate preoperative diagnosis of chordoid glioma. Therefore, we consider such recognition before surgery leads to safe, effective treatment of chordoid glioma.

In the 2016 revision of the WHO classification of CNS tumors,^[13] the definition of chordoid glioma of the third ventricle is as follows: “A slow-growing, non-invasive glial tumor located in the third ventricle.” Microscopically, chordoid glioma mainly consists of solid neoplasms composed of clusters and cords of epithelioid tumor cells within a variably mucinous stroma that typically contains a lymphoplasmacytic infiltrate. The nuclei are moderately sized, ovoid and relatively uniform, and mitotic figures are rare.^[13] With regard to immunohistochemical characteristics, these tumor cells showed diffuse reactivity for GFAP. In addition, chordoid glioma was found to strongly express CD34, a transmembrane glycoprotein expressed on hematopoietic stem cells,

vascular endothelia, and mesenchymal cells.^[17] Usually, CD34 is negative in chordomas, meningiomas, and common forms of glioma such as diffuse astrocytomas, ependymomas, and oligodendrogliomas. On the other hand, CD34 is consistently positive in chordoid glioma, neurofibroma, solitary fibrous tumor, and meningeal hemangiopericytoma.^[7] Moreover, chordoid gliomas were found to strongly express the nuclear transcription factor TTF-1, which is strongly expressed in the neurons and ependymal and subependymal cells of the third ventricle, as well as in hypothalamic astrocytes.^[7,10] Huo *et al.* reported that staining for both TTF-1 and CD34 is specifically expressed in chordoid glioma of the third ventricle, providing a useful marker for distinguishing such tumors from other suprasellar tumors and third ventricular tumor.^[7] In our case, the tumor comprised clusters and cords of epithelioid cells that typically contained lymphoplasmacytic infiltration on morphological analysis. This structure was immunopositive for GFAP, and almost all tumor cells appeared strongly positive for CD34 and TTF-1. These findings are consistent with chordoid glioma in consideration of morphological studies and immunohistochemical analyses performed in accordance with the 2016 WHO classification. We, therefore, consider CD34 and TTF-1 as the most useful markers for accurate diagnosis of chordoid glioma of the third ventricle.

In terms of treatment, the best treatment strategy for this pathology remains controversial due to its rarity.^[1,7,13] In general, surgical resection is the most important part of the treatment. The choice of surgical approach may be mainly due to the presence of objective variables such as ventricular extension, tumor laterality, as well as the surgeon's confidence. In previous reports comparing all conventional approaches, a surgical route using the translamina terminalis corridor was associated with significantly decreased morbidity and mortality rates.^[1,11] However, surgical en bloc resection can be technically challenging considering the deep location of the tumor and its proximity to vital neurovascular structures and the hypothalamus. Surgeons have, therefore, attempted to balance maximal cytoreduction with complication avoidance. In addition, there are also reports of several other adjuvant therapy such as conventional radiotherapy, stereotactic radiosurgery, and intratumoral radiotherapy; however, no chemotherapy treatment is reported.^[2] In the previous report, radiotherapy is often used as an adjuvant therapy in patients who undergo subtotal resection.^[11] The knowledge of these promising tools for a combined treatment approach to these lesions could modify the surgical strategy.^[11] On the other hand, recently, several reports identified that there was a recurrent D463H missense mutation in PRKCA in chordoid glioma of the third ventricle, which localizes in the kinase domain of the encoded protein kinase C alpha (PKC α). In addition,

expression of mutant PRKCA in immortalized human astrocytes led to increased phospho-extracellular signal regulated kinase (ERK) and anchorage-independent growth that could be blocked by methyl ethyl ketone (MEK) inhibition. Therefore, the clarification of this genetic alteration has the potential to change the treatment paradigm for this uncommon tumor.^[5,16] In this case, we are convinced that taking into account the possibility of chordoid glioma before surgery resulted in safe, total removal without being surprised during surgery, in addition to excellent tumor control without neurological complications. Recognition of the detailed characteristics of chordoid glioma of the third ventricle is very important. Accumulation of further experience with this pathology and results from longer patient follow-up are required.

CONCLUSION

We suggest that chordoid glioma of the third ventricle should be included as a differential diagnosis for third ventricular tumors in patients with homogeneously enhancing lesions on MRI. In addition, this entity is difficult to diagnose using routine pathological analysis. Careful identification of signs from preoperative MRI and detailed evaluation of findings from morphological and immunohistochemical studies including CD34 and TTF-1 staining are important for accurate diagnosis and selection of appropriate treatment for chordoid glioma.

Declaration of patient consent

We certify that we have obtained all appropriate patient consent forms. In the form, the patient has consented to her images and other clinical information to be reported in the journal. The patient understands that her names and initials will not be published and due efforts will be made to conceal her identity, but anonymity cannot be guaranteed.

Financial support and sponsorship

Nil.

Conflicts of interest

There are no conflicts of interest.

REFERENCES

1. Ampie L, Choy W, Lamano JB, Kesavabhotla K, Mao Q, Parsa AT, *et al.* Prognostic factors for recurrence and complications in the surgical management of primary chordoid gliomas: A systematic review of literature. *Clin Neurol Neurosurg* 2015;138:129-36.
2. Bongetta D, Riso A, Morbini P, Butti G, Gaetani P. Chordoid glioma: A rare radiologically, histologically, and clinically mystifying lesion. *World J Surg Oncol* 2015;13:188.
3. Brat DJ, Scheithauer BW, Staugaitis SM, Cortez SC, Brecher K, Burger PC. Third ventricular chordoid glioma: A distinct clinicopathologic entity. *J Neuropathol Exp Neurol* 1998;57:283-90.
4. Desouza RM, Bodi I, Thomas N, Marsh H, Crocker M. Chordoid glioma: Ten years of a low-grade tumor with high morbidity. *Skull Base* 2010;20:125-38.

5. Goode B, Mondal G, Hyun M, Ruiz DG, Lin YH, Van Ziffle J, et al. A recurrent kinase domain mutation in PRKCA defines chordoid glioma of the third ventricle. *Nat Commun* 2018;9:810.
6. Hewer E, Beck J, Kellner-Weldon F, Vajtai I. Suprasellar chordoid neoplasm with expression of thyroid transcription factor 1: evidence that chordoid glioma of the third ventricle and pituitaryoma may form part of a spectrum of lineage-related tumors of the basal forebrain. *Hum Pathol* 2015;46:1045-9.
7. Huo CW, Rathi V, Scarlett A, Galanos J, Wang YY. The trans-laminar terminalis approach reduces mortalities associated with chordoid glioma resections: A case report and a review of 20 years of literature. *J Clin Neurosci* 2018;47:43-55.
8. Jung TY, Jung S. Third ventricular chordoid glioma with unusual aggressive behavior: Case report. *Neurol Med Chir (Tokyo)* 2006;46:605-8.
9. Ki SY, Kim SK, Heo TW, Baek BH, Kim HS, Yoon W. Chordoid glioma with intraventricular dissemination: A case report with perfusion MR imaging features. *Neuroimaging Head Neck* 2015;17:142-6.
10. Lee BJ, Cho GJ, Norgren RB Jr, Junier MP, Hill DF, Tapia V, et al. TTF-1, a homeodomain gene required for diencephalic morphogenesis, is postnatally expressed in the neuroendocrine brain in a developmentally regulated and cell-specific fashion. *Mol Cell Neurosci* 2001;17:107-26.
11. Liu W, Cheng JX, Yi XC, Zhen HN, Fei Z, Li Q, et al. Chordoid glioma: A case report and literature review. *Neurologist* 2011;17:52-6.
12. Louis DN, Ohgaki H, Wiestler OD, Cavenee WK, Burger PC, Jouvet A, et al. The 2007 WHO classification of tumours of the central nervous system. *Acta Neuropathol* 2007;114:97-109.
13. Louis DN, Perry A, Reifenberger G, von Deimling A, Figarella-Branger D, Cavenee WK, et al. The 2016 World Health Organization Classification of Tumors of the Central Nervous System: A summary. *Acta Neuropathol* 2016;131:803-20.
14. Pasquier B, Peoch M, Morrison AL, Gay E, Pasquier D, Grand S, et al. Chordoid glioma of the third ventricle: A report of two new cases, with further evidence supporting an ependymal differentiation, and review of the literature. *Am J Surg Pathol* 2002;26:1330-42.
15. Raizer JJ, Shetty T, Gutin PH, Obbens E, Holodny AI, Antonescu GR, et al. Chordoid glioma: report of a case with unusual histologic features, ultrastructural study and reviews of the literature. *J Neurooncol* 2003;63:39-47.
16. Rosenberg S, Simeonova I, Bielle F, Verreault M, Bance B, Le Roux I, et al. A recurrent point mutation in PRKCA is a hallmark of chordoid gliomas. *Nat Commun* 2018;9:2371.
17. Steen R, Egeland T. CD34 molecule epitope distribution on cells of haematopoietic origin. *Leuk Lymphoma* 1998;30:23-30.
18. Tanboon J, Aurboonyawat T, Chawalparit O. A 29-year-old man with progressive short term memory loss. *Brain Pathol* 2014;24:103-6.
19. Wanschitz J, Schmidbauer M, Maier H, Rossler K, Vorkapic P, Budka H. Suprasellar meningioma with expression of glial fibrillary acidic protein: A peculiar variant. *Acta Neuropathol* 1995;90:539-44.
20. Zeinalizadeh M, Sadrehosseini SM, Tayebi Meybodi K, Sharifabadi AH. Expanded endoscopic transnasal approach to the chordoid glioma of the third ventricle: The first case ever reported. *J Korean Neurosurg Soc* 2016;59:643-6.