

Contents lists available at [ScienceDirect](https://www.sciencedirect.com)

International Journal of Surgery Case Reports

journal homepage: www.casereports.com

Burkitt's lymphoma in pregnant woman: Difficult management of a rare case

Gaspare Cucinella^a, Claudio Rossi^a, Roberto Granà^a, Vincenzo Luca Lentini^b, Gloria Calagna^{a,*}, Vito Chiantera^c^a Obstetrics and Gynecology, "Villa Sofia Cervello" Hospital, University of Palermo, Palermo, Italy^b Anatomic Pathology, "Villa Sofia Cervello" Hospital, University of Palermo, Palermo, Italy^c Department of Gynecologic Oncology, ARNAS Civico Di Cristina Benfratelli, University of Palermo, Italy

ARTICLE INFO

Article history:

Received 27 June 2020

Received in revised form 17 October 2020

Accepted 17 October 2020

Available online 21 October 2020

Keywords:

Burkitt's lymphoma

Pregnancy

Intestinal involvement

Non-Hodgkin lymphoma

ABSTRACT

INTRODUCTION: Burkitt's lymphoma (BL), an aggressive subtype of non-Hodgkin lymphoma (NHL), is extremely rare during pregnancy. In the case of bowel localization, diagnosis can be very difficult. Moreover, signs and symptoms of the primary small intestine lymphoma are nonspecific, mostly attributable to the "mass effect" of the tumor. The most frequent symptom is abdominal cramp-like pain, associated with nausea and vomiting.

PRESENTATION OF CASE: We report a rare case of a 37-year-old pregnant woman, at the 33rd week of gestation, with an abdominal-pelvic mass of uncertain nature. Surgical strategy consisted of a *two-step* procedure, which involved a cesarean section and typing of the mass: extemporaneous examination hypothesized intestinal lymphoma. The definitive histological examination confirmed the diagnosis of rare case of BL in pregnancy.

DISCUSSION: The clinical case reported, representing a rare occurrence of BL in pregnancy, was associated with difficult interpretation and complex management. Lymphoma of the small intestine is often overlooked in the early stages of the disease, due to the fact that symptoms are non-specific and consequently underestimated. In our case, based on gestational age, it was possible to perform a multidisciplinary approach, a cesarean section with surgical intestinal exploration, achieving at the same time delivery of the child and a definitive diagnosis of BL with intestinal involvement.

CONCLUSION: The involvement of multiple professionals is undoubtedly the best way to deal with the above referred to situation, with the main point being to keep in mind the possibility of this type of occurrence.

© 2020 Published by Elsevier Ltd on behalf of IJS Publishing Group Ltd. This is an open access article under the CC BY-NC-ND license (<http://creativecommons.org/licenses/by-nc-nd/4.0/>).

1. Introduction

In recent years, the occurrence and diagnosis of cancer during pregnancy is increasing, reflecting the rate of incidence of cases found in women of reproductive age, above all breast and thyroid cancer [1]. Among haematological malignancy diagnosed in pregnancy, Hodgkin lymphoma represents the most common [2]. On the contrary, Burkitt's lymphoma (BL), an aggressive subtype of non-Hodgkin lymphoma (NHL), is extremely rare during pregnancy; it is characterized by the evidence of c-myc gene translocation on chromosome 8 and frequently presents at extranodal sites [3].

Diagnosis can be very difficult and may be delayed in pregnancy, above all regarding localization, with the risk of affecting the staging of cancer and, therefore, prognosis [4].

We report a case of advanced BL in a 37-year-old pregnant woman at the 33rd week of amenorrhea with abdominal pain and vomiting, subjected to *two-step* surgery with a multidisciplinary approach.

2. Case report

A 37-year-old pregnant caucasian woman (3rd pregnancy at sixth month of gestation), at the 33rd week of amenorrhea, arrived in the general emergency room of "Villa Sofia Cervello" Hospital of Palermo, complaining of abdominal pain and vomiting. She reported abdominal pain and distension with bowel disorders (diarrhea alternating with constipation) for about 3 weeks, taking antibiotic for 4 days. From the anamnesis, two previous pregnancies had had a regular course without pathology worthy of note and with spontaneous deliveries. Her past medical and family histories were unremarkable. She had no history of hepatitis, sexually transmitted diseases or other significant illnesses, tobacco or

* Corresponding author at: Obstetrics and Gynecology, "Villa Sofia Cervello" Hospital, University of Palermo, via Trabucco 180, 90100, Palermo, Italy.
E-mail address: gloria.calagna83@gmail.com (G. Calagna).

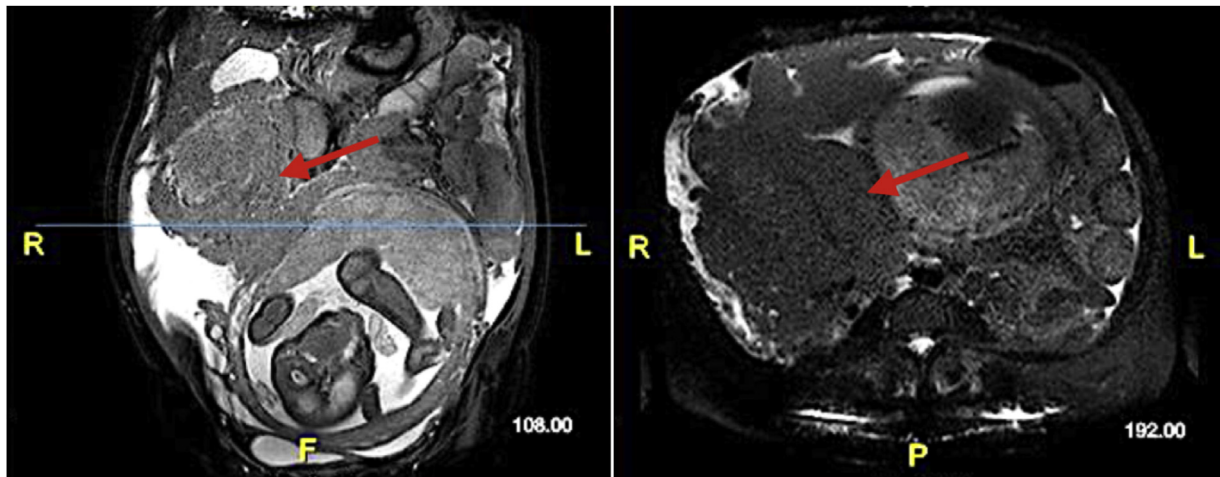


Fig. 1. Abdominal MRI (coronal and axial) sections. Note the displacement on the left of the uterus due to the “mass effect” of the tumor.

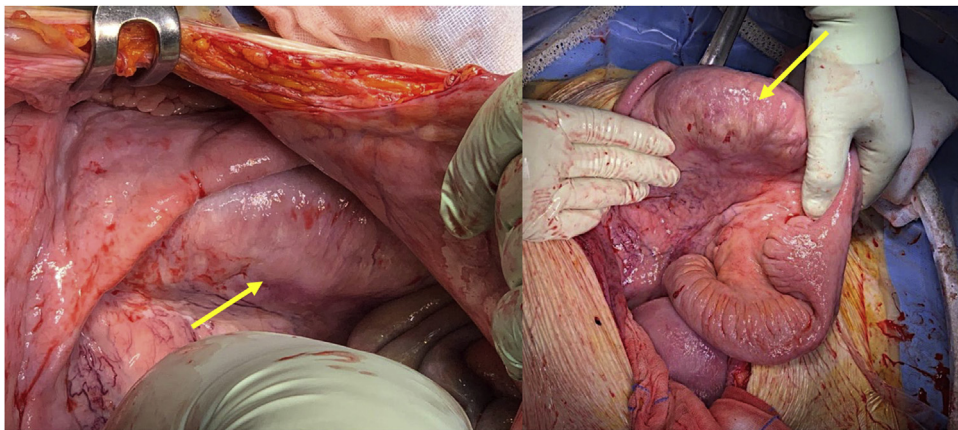


Fig. 2. Intra-operative finding. Neoplastic intestinal mass with intestinal subverted structure (arrow).

drug use, and neurologic examination was negative. At admission, vital signs were normal, with normal GCS - Glasgow Coma Scale (15/15); moderate dehydration and a diffusely painful abdomen were highlighted. All obstetric parameters were normal: no anomalies emerged from the obstetric visit, with adequate cervicometry. Pregnancy appeared to be in regular evolution: active fetal movements and fetal heartbeats were present, placenta was regular and normoinert, amniotic fluid was normal. The case was reported in line with the SCARE 2018 criteria [5].

An abnormal abdominal effusion and overdistension of the intestinal loops with reduced peristalsis was noted and, during an objective exam, a mobile abdominal mass in the right-side seat was noted (approximately 8–10 cm). An abdominal ultrasound highlighted diffused ascites, with involvement of peri-hepatic and peri-splenic areas as well as the pelvis; liver had normal echogenicity, with no focal lesions. In the right pelvic area, in the context of an abundant quantity of fluid effusion, there were some overstretched loops with reduced peristalsis, uneven echogenicity and indistinct margins. Laboratory workup showed relevant changes in the liver profile (aspartate aminotransferase 236 IU/l; alanine aminotransferase 160 IU/l; alkaline phosphatase 337 U/l; LDH 1171 IU/l), initial anaemia (10.6 g/dl) and minimal reduction of haematocrit (32.5%), white blood cell count of 12,300/mcL (with a lymphocytes reduction); coagulation tests showed an increase in fibrinogen (948 mg%). Serological tests for human immunovirus,

hepatitis B, and hepatitis C were negative. Therefore, a diagnosis of “suspected intestinal obstruction” was made and magnetic resonance imaging (MRI) was recommended. MRI revealed, on the left side and in the abdominal centre, the presence of jejunal loops moderately overstretched by liquid with thickened wall of some sections of the small intestine; on the right, the jejunal loops appeared collapsed in a conglomerate appearance, without cleavage planes: here there was thickening of the posterior peritoneum and irregular thickening of the omental apron, delimiting the intestinal mass (Fig. 1).

Differential diagnosis between inflammatory bowel disease and tumor mass (solid and/or hematological) was necessary, and, after gastroenterological, anesthesiological and surgical counseling, surgery was performed. A two-step surgical procedure was decided: first, the “obstetric phase”, with a cesarean section, and second, the “surgical phase”, focalized on the management of the intestinal mass.

The abdomen was opened with a navel-pubic incision. Approximately 5 L of ascitic fluid were obtained and a sample was sent for cytological examination. A premature baby was delivered with Apgar scores 6/8 at the first and fifth minute.

After closing the uterine breach, the surgical team continued the operating session, highlighting a large neoplastic mass starting from the root of the mesentery that infiltrated the corresponding small loop (Fig. 2). Part of the mesocolon appeared infiltrated by the

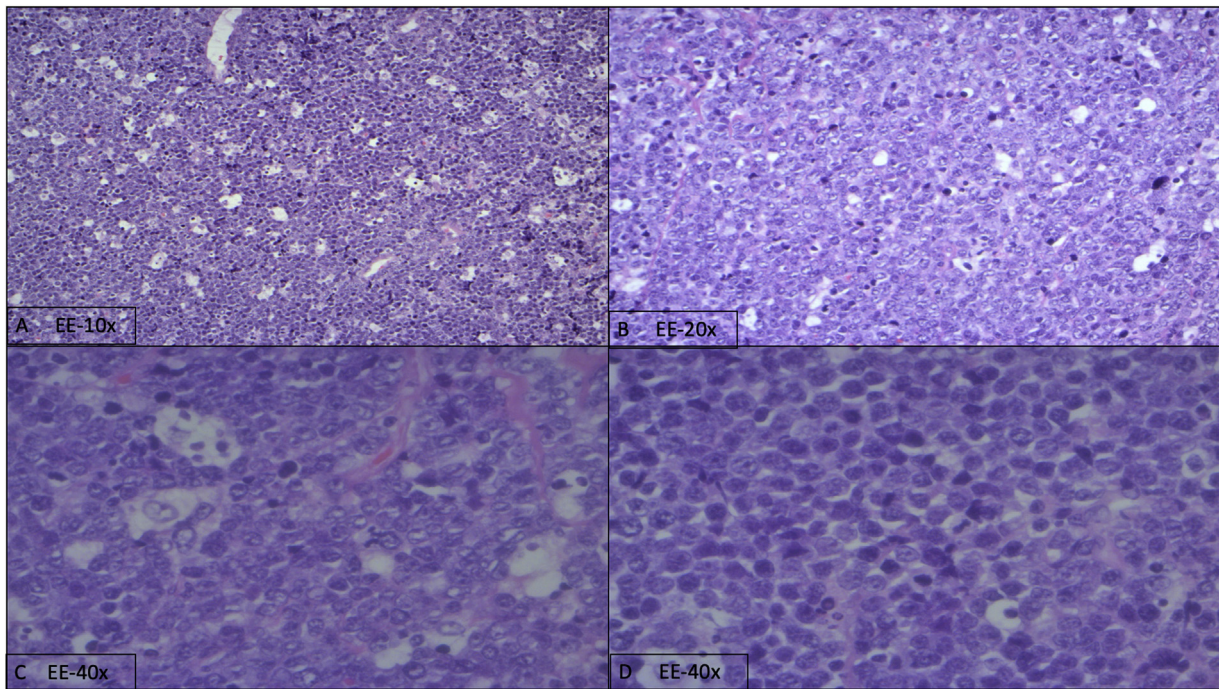


Fig. 3. (A-D). Neoplastic lymphoid population with diffused pattern of infiltration and «starry sky» aspect (A); in B, neoplastic population made by large, atypical lymphocytes. Note cellular atypia with nucleoli and mitosis (C-D).

mass. The mass was not removable, thus biopsic sampling of nodule of the parietal peritoneum, colonic epiploic fringe and part of the large epiploon were performed for extemporaneous examination which posed the hypothesis of intestinal lymphoma.

Immuno-histochemical studies showed positivity for cellular myc oncogene (cMYC) and no B-cell CLL/lymphoma 6 (Bcl6) and B-cell lymphoma 2 (bcl2) translocations were found: diagnosis of *sporadic variant BL (not endemic, not immunodeficiency asso-*

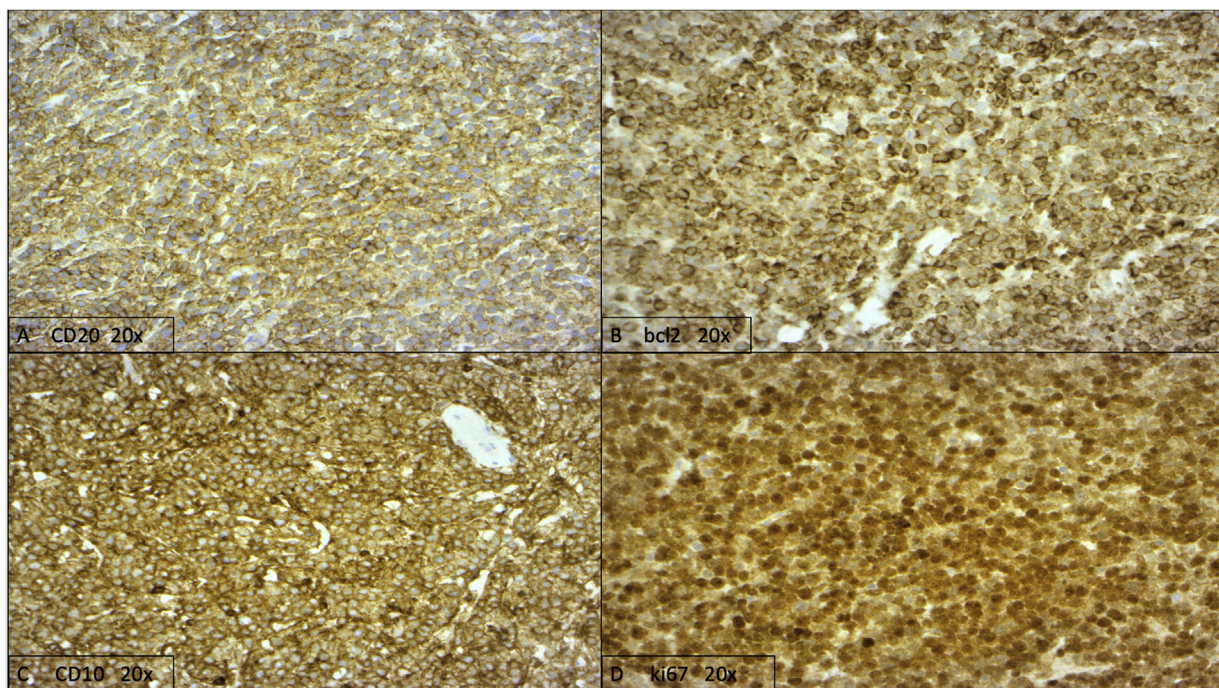


Fig. 4. (A-D). Immunophenotype of neoplastic population. CD20 Positivity (A), Bcl2 atypical paranuclear positivity (B), CD10 positivity (C) and high proliferative index (ki67): 100% of neoplastic cells (D).

ciated) was confirmed (Figs. 3 and 4). Successive MRI showed leptomeningeal lesions and our patient was therefore diagnosed as having stage IV BL based on Ann Arbor staging criteria [6]. She was started on R-Magrath (R–CODOX-M + R-IVAC) protocol at our Onco-hematological Unit and is currently in follow-up, waiting for a marrow transplant. The baby had no health issues and was discharged home with instructions to follow up for routine laboratory studies.

3. Discussion

This reported clinical case is a rare occurrence of BL in pregnancy, associated with a difficult interpretation and complex management. It was related to a rare intestinal localization of the principal lesion, representing the second case described in international literature on the topic [7]. Lymphoma of the small intestine is often overlooked in early stages of the disease, due to the fact that the symptoms are non-specific and consequently underestimated and, in this sense, diagnosis was frequently performed in an emergency situation [8]; moreover, the “young” age of onset has the problem of differential diagnosis with epidemiologically more frequent benign diseases.

BL is a neoplasm of mature B lymphocytes, which is endemic in African equatorial countries [9]. It can be divided into three main clinical types: endemic, sporadic and immunodeficiency-associated variants [10]. The sporadic type of BL (also known as non-African) is the most common variant found in “not endemic” area, such as Europe and is rarely associated with the Epstein-Barr virus [11]. To date, classification is based on the Lugano revision of the Ann Arbor/Cotswolds system which defines four stages of disease (I-IV), based on the number of locations affected by lymphoma [12]. Considering that NHLs are typically aggressive subtypes, they are often diagnosed at a more advanced stage.

Pregnancy status is a condition that generally complicates the diagnosis of many pathologies, above all cancer: it can be explained because several symptoms may be common in pregnancy and the greatest attention is given to the obstetric condition and to the fetus, also limiting diagnostic investigations. When diagnosis is performed, the general objectives for the treatment of pregnant mothers with BL should be the simultaneous optimization of maternal survival and the minimization of treatment-related fetal toxicity and prematurity. This is maximized by close collaboration with high-risk maternal-fetal medicine and also with the aim of continuing long-term pregnancy. In our case, based on gestational age, it was possible to perform a multidisciplinary approach, a cesarean section with surgical intestinal exploration, achieving at the same time delivery of the child and definitive diagnosis of BL with intestinal involvement.

4. Conclusion

The difficult management of this rare case of BL in pregnancy with intestinal involvement highlights the importance of careful anamnestic and instrumental evaluation, as well as a multidisciplinary assessment. Lack of data in international literature on the topic demonstrates that this condition is still poorly understood and consequently no definitive guidelines exist. The involvement of multiple professionals is undoubtedly the best way to deal with the above referred to situation, with the main point being to keep in mind the possibility of this type of occurrence.

Funding

In this study, sponsors had no such involvement.

Ethical approval

No specific ethical approval was necessary.

Consent

Written informed consent was obtained from the patient for publication of this case report and accompanying images. A copy of the written consent is available for review by the Editor-in-Chief of this journal on request.

Author contribution

Cucinella G: study design
Calagna G: study concept, writing the paper
Chiofalo B, Granà R: writing paper, data interpretation
Rossi C, Lentini VL: data analysis
Guiglia RA, Lo Bue V: data collection
Chiantera V: data interpretation

Registration of research studies

N/A.

Guarantor

Cucinella Gaspare, Calagna Gloria.

Provenance and peer review

Not commissioned, externally peer-reviewed.

Transparency document

The [Transparency document](#) associated with this article can be found in the online version.

Declaration of Competing Interest

The authors report no declarations of interest.

Acknowledgement

This article is part of a supplement entitled Case reports from Italian young surgeons, published with support from the Department of Surgical, Oncological and Oral Sciences – University of Palermo.

References

- [1] J. de Haan, M. Verheecke, K. Van Calsteren, et al., Oncological management and obstetric and neonatal outcomes for women diagnosed with cancer during pregnancy: a 20-year international cohort study of 1170 patients, *Lancet Oncol.* 19 (2018) 337–346.
- [2] C. Maggen, D. Dierickx, P. Lugtenburg, et al., Obstetric and maternal outcomes in patients diagnosed with Hodgkin lymphoma during pregnancy: a multicentre, retrospective, cohort study, *Lancet Haematol.* 6 (2019) 551–561.
- [3] G. Brady, G.J. MacArthur, P.J. Farrell, Epstein-Barr virus and Burkitt's lymphoma, *J. Clin. Pathol.* 60 (2007) 1397–1402.
- [4] K. Hodby, P.A. Fields, Management of lymphoma in pregnancy, *Obstet. Med.* 2 (2009) 46–51.
- [5] R.A. Agha, M.R. Borrelli, R. Farwana, K. Koshy, A. Fowler, D.P. Orgill, For the SCARE Group, The SCARE 2018 statement: updating consensus Surgical Case Report (SCARE) guidelines, *Int. J. Surg.* (60) (2018) 132–136.
- [6] P.P. Carbone, H.S. Kaplan, K. Musshoff, et al., Report of the committee on Hodgkin's disease staging classification, *Cancer Res.* 31 (1971) 1860–1861.
- [7] M. El-Hajjaoui, S. Khan, J.V. Davis, A unique case of colorectal lymphoma in a 39-week intrauterine pregnant female, *Int. J. Colorectal Dis.* 30 (2015) 271–273.

- [8] D. Howell, R. Hart, A. Smith, et al., Disease-related factors affecting timely lymphoma diagnosis: a qualitative study exploring patient experiences, *Br. J. Gen. Pract.* 69 (2019) 134–145.
- [9] D. Burkitt, A sarcoma involving the jaws in African children, *Br. J. Surgery* 46 (1958) 218–223.
- [10] E. Molyneux, R. Rochford, B. Griffin, et al., Burkitt's lymphoma, *Lancet* 379 (2012) 1234–1244.
- [11] G. Brady, G.J. MacArthur, P.J. Farrell, Epstein-barr virus and burkitt lymphoma, *J. Clin. Pathol.* 60 (2007) 1297–1402.
- [12] B.D. Heson, R.I. Fisher, S.F. Barrington, et al., Recommendations for initial evaluation, staging, and response assessment of Hodgkin and non-Hodgkin lymphoma: *the Lugano classification*, *J. Clin. Oncol.* 32 (2014), 3059–68.

Open Access

This article is published Open Access at [sciencedirect.com](https://www.sciencedirect.com). It is distributed under the [IJSCR Supplemental terms and conditions](#), which permits unrestricted non commercial use, distribution, and reproduction in any medium, provided the original authors and source are credited.