

Contents lists available at [ScienceDirect](http://www.sciencedirect.com)

International Journal of Surgery Case Reports

journal homepage: www.casereports.com

Adult intussusception caused by myoepithelial hamartoma in the small bowel: A case report



Adeyanju Adetunji^{a,*}, Donagh Healy^a, Nessa O'Donnell^b, Stephen Davitt^c,
Tim O'Hanrahan^a

^a Department of Surgery, Sligo Regional Hospital, The Mall, Sligo, Ireland

^b Department of Histopathology, Sligo Regional Hospital, The Mall, Sligo, Ireland

^c Department of Radiology, Sligo Regional Hospital, The Mall, Sligo, Ireland

ARTICLE INFO

Article history:

Received 17 October 2014

Received in revised form 22 January 2015

Accepted 23 January 2015

Available online 28 January 2015

Keywords:

Adult intussusception
Myoepithelial hamartoma
Intestinal obstruction

ABSTRACT

INTRODUCTION: Intussusception is rare in adults and can have acute, intermittent or chronic presentations. We present an unusual case of intussusception in an adult.

PRESENTATION OF CASE: A 25 year old male presented with sudden severe abdominal pain and vomiting. He had no relevant medical history. Mechanical small bowel obstruction was confirmed on imaging and laparotomy revealed a nodular lead point in the submucosa of the ileum. He had resection of a segment of small bowel with a primary anastomosis. Histopathology of the lesion demonstrated myoepithelial hamartoma (MEH), a rare cause of intussusception.

DISCUSSION: Although intussusception is not uncommon in children, it is rare in adults. Management delays are a major cause of morbidity. This report details our management of a case of intussusception caused by MEH in an otherwise healthy adult.

CONCLUSION: Intussusception caused by MEH is a rare but serious cause of mechanical bowel obstruction. We propose that surgeons should consider this diagnosis in atypical cases of bowel obstruction and expedite laparotomy when it is suspected.

Crown Copyright © 2015 Published by Elsevier Ltd. on behalf of Surgical Associates Ltd. This is an open access article under the CC BY-NC-ND license (<http://creativecommons.org/licenses/by-nc-nd/4.0/>).

1. Introduction

Intussusception is a relatively common cause of acute abdomen in the paediatric age group, but it is rare in adults [1,2]. It is a disorder in which part of the bowel slides into adjacent bowel. This then leads to bowel obstruction and its sequelae. In children, it causes sudden severe progressive abdominal pain with nausea and vomiting. In later stages, red currant jelly stools are sometimes seen. In adults, pain is often intermittent, and it can be associated with a variety of other symptoms [3]. In stable children, non-operative reduction with hydrostatic or pneumatic enemas under ultrasound or fluoroscopic guidance is an appropriate initial approach. However, in adults, surgical treatment is the norm, and it is common to find a well defined lesion serving as the lead point [4,5].

Ultrasound is the method of choice for diagnosis [6]. Although it is operator dependent, it can reliably confirm or exclude the diagnosis without the use of radiation. Plain abdominal radiography is less sensitive and less specific [7], and therefore, should be avoided if intussusception is suspected. Computed tomography (CT)

scanning can also reliably achieve the diagnosis [3], although its use is limited in children due to concerns regarding radiation and the need for sedatives.

2. Presentation of case

A 24 year old man presented with sudden onset of severe colicky central abdominal pain. There was associated anorexia and nausea and the patient vomited about ten times. At presentation, his symptoms were of 12 h duration. His complaints were progressively worsening. He was an otherwise healthy adult and had no previous surgery. On examination, he had a distended abdomen with mild generalised tenderness. There were no signs of peritonitis, and there were no detectable masses or hernias.

White cell count was elevated while other blood investigations were within normal limits. Plain abdominal X-ray and CT scan (Fig. 1) showed mechanical small bowel obstruction.

He was managed initially with intravenous fluids and opiate analgesia. He had placement of a nasogastric tube and a urinary catheter. Over the following hours, his pain worsened although his vital signs remained stable, and he did not develop peritonitis. He underwent an emergency laparotomy at 12 h following hospital admission. We did not persist with conservative management as

Abbreviations: MEH, myoepithelial hamartoma.

* Corresponding author. Tel.: +353 863901307.

E-mail address: tunjiadeyanju@gmail.com (A. Adetunji).

<http://dx.doi.org/10.1016/j.ijscr.2015.01.043>

2210-2612/Crown Copyright © 2015 Published by Elsevier Ltd. on behalf of Surgical Associates Ltd. This is an open access article under the CC BY-NC-ND license (<http://creativecommons.org/licenses/by-nc-nd/4.0/>).

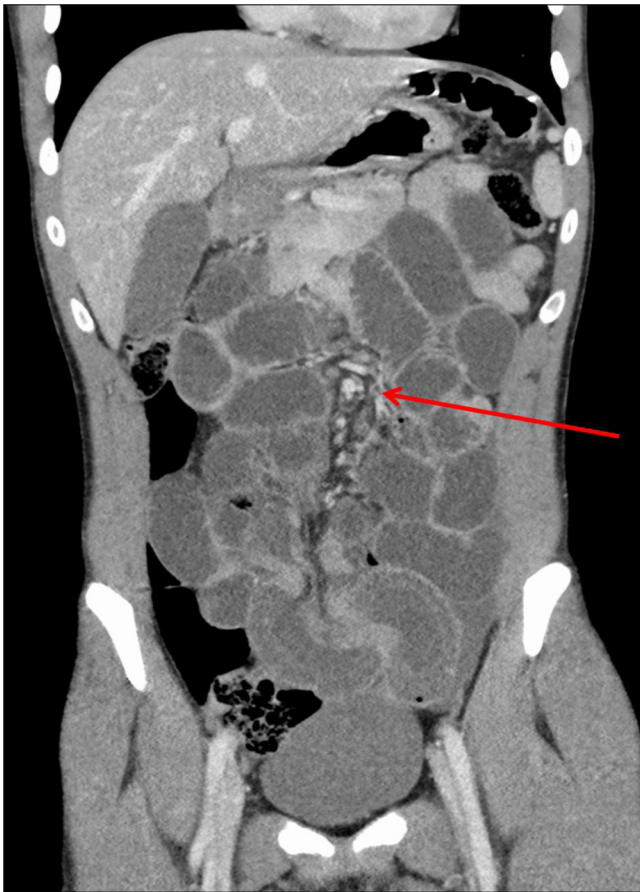


Fig. 1. Contrast enhanced computed tomography scanning image demonstrating mechanical small bowel obstruction with a transition zone (arrow).

there was obvious mechanical obstruction with worsening symptoms and with no obvious cause.

Laparotomy confirmed ileo–ileal intussusception about 2–3 feet from the ileocaecal valve (Fig. 2). Once it was reduced, a segment of gangrenous bowel was found. The lead point of the intussusception was a submucosal nodule measuring approximately 1.2 cm (Fig. 3).

The patient underwent a small bowel resection and primary anastomosis and made a full recovery.

The histology of the submucosal nodule showed ductular structures some of which were cystically dilated and lined by pancreatic duct type epithelium (Fig. 4) and surrounded by whorling smooth muscle fibres (Fig. 5) consistent with the diagnosis of myoepithelial hamartoma causing the intussusception.

3. Discussion

Intussusception is not uncommon in children, but it is rare in adult [4]. Intussusception occurs when a proximal segment of bowel becomes telescoped in to the bowel distal to it [4]. There is a lead point, termed the intussusceptum, which gives rise to the intussusception, and it is at that point that the pathology initiating the process is usually found [5].

Diagnosis of adult intussusceptions is less frequently made pre-operatively and mechanical intestinal obstruction will usually be the reason for surgical intervention. Most cases of intussusception in adult have a demonstrable cause unlike what occurs in the paediatric population [4,5]. Lymphoid hyperplasia, Meckel's diverticulum, polyps, lymphoma, lipoma, Peutz–Jegher polyps, primary adenocarcinoma and myoepithelial hamartoma are listed as some of the causes of intussusception [2,4]. Myoepithelial

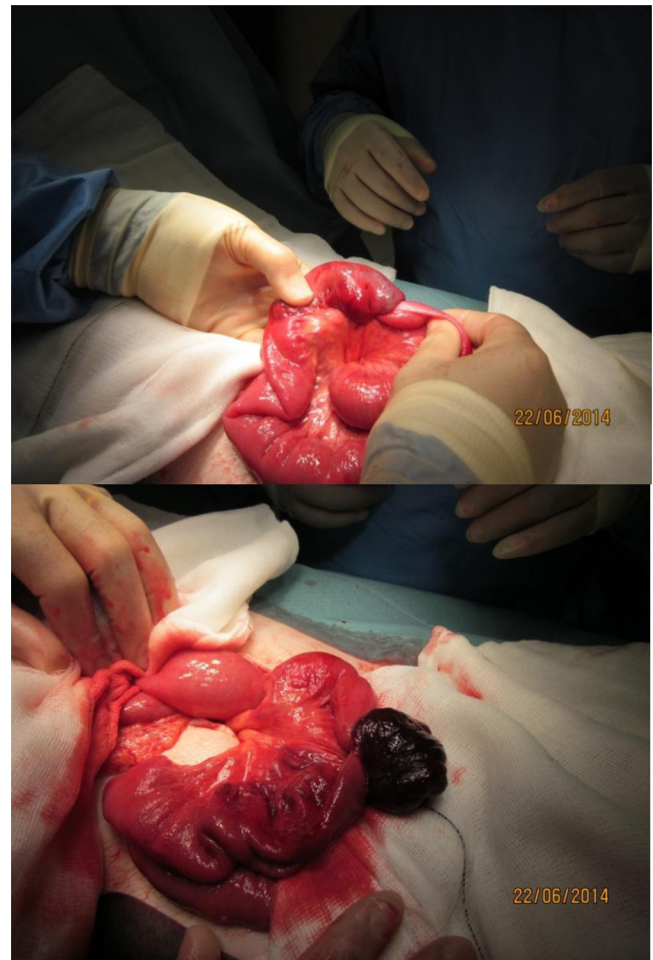


Fig. 2. Intussusception as initially found at laparotomy and after reduction showing gangrenous bowel.

hamartoma (MEH) as found in this patient is a rare cause [2] of intussusception.

Myoepithelial hamartoma has been called by various names in the literature. In addition to myoepithelial hamartoma, names such as adenomyoma, ectopic pancreas, and foregut choristoma (coined from the fact that all tissues are from the embryologic foregut) have been used [2,4]. The following are the pathologic features that

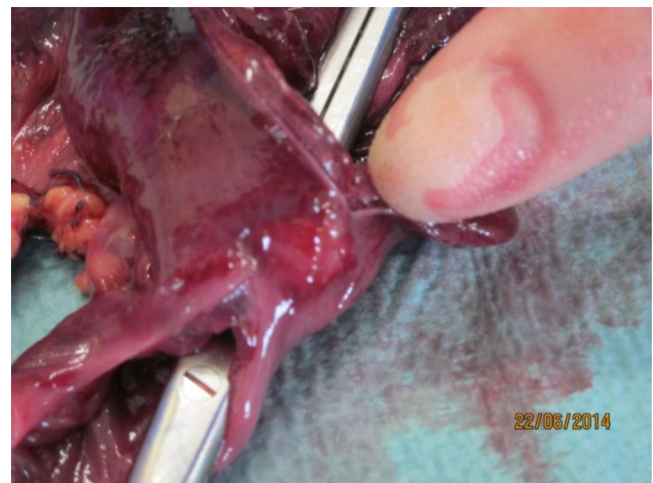

Fig. 3. Submucosal nodule.

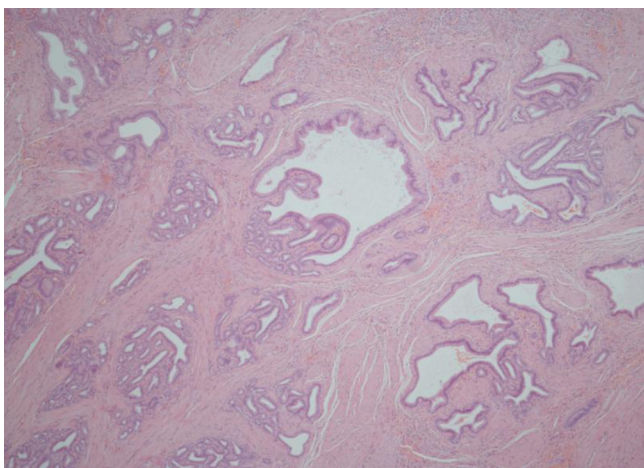


Fig. 4. Histology of submucosal nodule showing pancreatic type tissue.

define MEH: a mass is present in the submucosa and has glandular elements differentiated from embryonic epithelial buds with smooth muscle bundles surrounding the glandular elements [2,5]. MEH is a developmental abnormality. The term ‘ectopic pancreatic tissue’ is used when typical pancreatic acinar tissue is present; when smooth muscle and ductal structures predominate, it is called MEH [4].

The clinical presentations are non-specific – patients often develop mechanical obstruction and report symptoms as abdominal pain, vomiting and nausea such as in this case report [1,4]. Subacute and chronic presentations of intussusception caused by MEH have been reported in adults [2,5] – this was not the case in our patient who presented for the first time acutely. The laboratory investigations are also not specific. Our patient had leucocytosis which has also been reported in other patients with intussusception from MEH [5].

In terms of imaging, plain abdominal X-rays can show mechanical bowel obstruction as in this patient [5]. CT scan is the most useful imaging option and its diagnostic accuracy ranges from 58% to 100% [5]. Although the CT scan done in this patient showed mechanical obstruction, it did not demonstrate intussusception radiologically. Ultrasound scan is also used in diagnosis where the classical ‘target’ or ‘doughnut signs’ on the transverse view and ‘pseudo-kidney’ on the longitudinal view are the features seen.

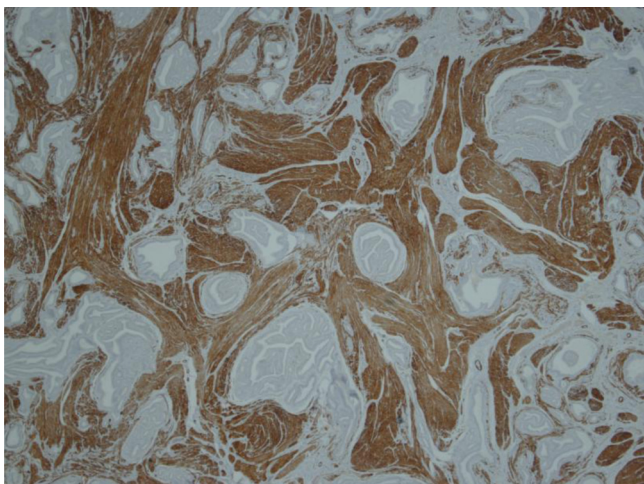


Fig. 5. Histology of submucosal nodule with actin stain demonstrating whirling muscle.

We think that the most critical aspect of our management of this case was our prompt decision to perform an exploratory laparotomy. This was preceded by CT confirmation of mechanical obstruction. Although the preoperative working diagnosis was unclear, we felt that aggressive management would be the better option. If abdominal ultrasound scanning had been performed, we may have diagnosed intussusception without radiation exposure. However, his presentation was not typical for intussusception, especially considering his age.

We propose that surgeons should have a high index of suspicion for intussusception, especially in mechanical obstruction without an obvious cause. In such cases, early laparotomy may be recommended. Intussusception is rare in the adult population. MEH is a rare cause in all populations [2,4,5].

4. Conclusion

In conclusion we report intussusception in an adult, a rare clinical finding with an even rarer aetiology.

Conflict of interest

The authors declare that no conflicts of interest exist.

Funding

No funding was received.

Ethical approval

There was no requirement for ethical approval.

Consent

Written informed consent was obtained from the patient for publication of this case report and accompanying images. A copy of the written consent is available for review by the Editor-in-Chief of this journal on request.

Author contribution

Adeyanju Adetunji – study concept, design, data collection, interpretation, literature review, writing.
 Donagh Healy – literature review, writing.
 Nessa O'Donnell – data collection, writing.
 Stephen Davitt – data collection, writing.
 Tim O'Hanrahan – data collection, writing.

Guarantor

Tim O'Hanrahan.

Key learning points

- Intussusception is not uncommon in children but it is rare in adults.
- Children tend to present acutely whereas adults may have acute, intermittent or chronic presentations.
- Pathology at a “lead point” leads to telescoping of small bowel into adjacent small bowel.
- Myoepithelial Hamartoma (MEH) is a rare cause of intussusception.
- MEH is a developmental abnormality that develops from the primitive foregut, containing submucosal elements of pancreatic ductal and acinar tissue with smooth muscle.

Acknowledgement

None.

References

- [1] R.A. Lindor, M.F. Bellolio, A.T. Sadosty, F. Earnest, D. Cabrera, Adult intussusception: presentation, management, and outcomes of 148 patients, *J. Emerg. Med.* 43 (1) (2012) 1–6.
- [2] R. Ikegami, Y. Watanabe, T. Tainaka, Myoepithelial hamartoma causing small-bowel intussusception: a case report and literature review, *Pediatr. Surg. Int.* 22 (4) (2006) 387–389.
- [3] G. Gayer, R. Zissin, S. Apter, M. Papa, M. Hertz, Pictorial review: adult intussusception – a CT diagnosis, *Br. J. Radiol.* 75 (890) (2002) 185–190.
- [4] P. Jagmohan, R. Anand, M. Narula, V. Singhal, R. Solanki, Myoepithelial hamartoma of the distal ileum – a rare cause of adult intussusception, *Indian J. Radiol. Imaging* 16 (2) (2006) 185.
- [5] C.M. Nuño-Guzmán, J. Arróniz-Jáuregui, I. Espejo, J. Solís-Ugalde, J.I. Gómez-Ontiveros, A. Vargas-Gerónimo, J. Valle-González, Adult intussusception secondary to an ileum hamartoma, *World J. Gastrointest. Oncol.* 3 (6) (2011) 103.
- [6] H.S. Ko, J.P. Schenk, J. Troger, W.K. Rohrschneider, Current radiological management of intussusception in children, *Eur. Radiol.* 17 (9) (2007) 2411–2421.
- [7] J. Morrison, N. Lucas, J. Gravel, The role of abdominal radiography in the diagnosis of intussusception when interpreted by pediatric emergency physicians, *J. Pediatr.* 155 (4) (2009) 556–559.

Open Access

This article is published Open Access at scimedirect.com. It is distributed under the [IJSCR Supplemental terms and conditions](#), which permits unrestricted non commercial use, distribution, and reproduction in any medium, provided the original authors and source are credited.