

Rebar Repair of Radial Meniscus Tears: A Reinforced Suture Technique



Patrick A. Massey, M.D., Kaylan McClary, M.D., Nicole Sanders, B.S., Mitchell Myers, M.D., Richard S. Barton, M.D., and Giovanni Solitro, Ph.D.

Abstract: The purpose of this paper is to describe the rebar repair as a technique for repair of radial meniscus tears and compare the rebar technique with current techniques used for meniscus repairs. This technique consists of 4 sutures placed with the inside-out technique. First, the vertical mattress reinforcement sutures are placed anteriorly and posteriorly to the tear. Then, 2 parallel horizontal sutures are placed directly in juxtaposition to the vertical sutures, ensuring the needles pass on the side of the reinforcing stitch away from the tear. This technique is less technically challenging than other meniscus repair techniques that require drilling of a transtibial tunnel. Overall, the rebar technique offers a more optimal way for stabilizing the meniscus by using 2 reinforcement sutures that run with the circumferential fibers to help restore the natural hoop stress of the meniscus. Also, the placement of the vertical mattress sutures in the rebar technique offers more direct reinforcement to the horizontal mattress sutures as compared with other techniques, which reduces the risk of pull-out tears.

Surgical options for radial tears include meniscectomy, meniscal repair, and meniscal transplantation.¹ From a historical perspective, meniscal tears were treated with meniscectomies because the function of the meniscus was poorly understood. With improved understanding of knee biomechanics, the literature continues to provide evidence that describes the multiple functions of the meniscus, including load-bearing, protection against osteoarthritis, joint stability, and shock absorption.^{2,3} Of the different types of meniscus tears, radial tears are one of the most unstable tears due to their disruption of the circumferential fibers of the meniscus, which results in a loss of the dispersion of force through hoop stress.^{4,5} In addition, radial tears are located in the inner portion of the menisci, known as the white zone, which has no

vascularization and is less amenable to healing.⁵ However, Anderson et al.⁵ demonstrated the potential for healing radial meniscus tears with multiple horizontal stitches.

Several techniques for meniscal repair have been used, including inside-out, all-inside, cross suture, hashtag, cross-tag, double-horizontal mattress suture, single-loop suture, and modified Mason–Allen stitch.^{4,6-11} When comparing repairs of the meniscus, it is important to consider the factors of cost, minimizing damage to the meniscus, ease of use, healing capability, and restoration of normal biomechanics. The inside-out technique is considered the standard of care in meniscal repair because it allows for cheaper implant cost and the ability to use multiple sutures while maintaining the structural integrity of the meniscus.⁶

From the Department of Orthopaedic Surgery, Louisiana State University Health, Shreveport, Louisiana, U.S.A.

The authors report that they have no conflicts of interest in the authorship and publication of this article. Full ICMJE author disclosure forms are available for this article online, as [supplementary material](#).

Received December 31, 2019; accepted March 14, 2020.

Address correspondence to Patrick Massey, M.D., Department of Orthopaedic Surgery, Louisiana State University Health, 1501 Kings Highway, Shreveport, LA 71103. E-mail: orthomassey@gmail.com

© 2020 by the Arthroscopy Association of North America. Published by Elsevier. This is an open access article under the CC BY-NC-ND license (<http://creativecommons.org/licenses/by-nc-nd/4.0/>).

2212-6287/208

<https://doi.org/10.1016/j.eats.2020.03.013>

Surgical Technique (With Video Illustration)

The patient is placed supine on an operating table, with all bony prominences well-padded. A lateral post is placed to allow for the medial compartment to be better visualized, when needed. The knee joint is injected with 50 to 60 cc of sterile normal saline using the anterolateral approach with the knee in a flexed position. Planned anterolateral and anteromedial incisions are then marked with a marking pen in the soft spot lateral and medial to the patellar tendon below the inferior pole of the patella. These planned incision

sites are then injected with local anesthetic, typically 0.25% bupivacaine. A #11 blade is then used to make an incision through skin only for the anterolateral portal. The blunt trocar is introduced through the incision and knee capsule, into the joint, with the knee flexed. The trocar is then advanced into the suprapatellar pouch with the knee in an extended position. The trocar is then removed and the camera introduced through the cannula, along with the inflow and outflow tubing. A standard diagnostic arthroscopy is then performed, evaluating the suprapatellar pouch, patellofemoral joint, trochlear groove, lateral gutter, lateral compartment, medial gutter, medial compartment, and intercondylar notch. An anteromedial portal is then established under direct visualization from a camera in the anterolateral portal. If a radial tear of the medial or lateral meniscus is noted, typically in the mid-body portion of the meniscus, the rebar technique can be used for repair via an inside-out technique. To visualize the needle ends, a mini-open incision is made on the medial or lateral joint line for a medial or lateral meniscus tear respectively.

If a lateral meniscus radial tear is noted, a mini-open lateral approach to the knee is performed. A 4- to 5-cm curved incision is made over the lateral aspect of the flexed knee, approximately 3 cm posterior to the lateral edge of the patella. Once soft tissue flaps have been made and retracted with Weitlaner retractors, the fascia between the iliotibial band and the biceps femoris is incised. Alternatively, if more anterior access is needed, the iliotibial band can be split in line with its fibers. Care is taken to protect the common peroneal nerve, which lies on the posterior border of the biceps femoris. This tissue can be retracted and protected with an Army–Navy retractor as the needles are passed through the capsule. Dissection is then performed through the lateral patellar retinaculum. The capsule can then be visualized anterior and/or posterior to the lateral collateral ligament.

Alternatively, a medial approach to the knee can be used for tears of the medial meniscus. A 4- to 5-cm curved incision is made over the mid-line aspect of the medial knee with the knee flexed and the hip flexed, abducted, and externally rotated. Skin flaps are created and retracted, with attempt to spare the infrapatellar branch of the saphenous nerve if possible, as it courses transversely across the incision. Care is taken to protect the saphenous nerve where it emerges between the sartorius and gracilis. The fascia is incised along the anterior border of sartorius, and the tendons of the pes anserinus are then retracted posteriorly. The capsule may then be visualized anterior and/or posterior to the superficial medial collateral ligament.

This technique is performed in a standard inside-out repair fashion. The rebar repair employs the use of four 2-0 nonabsorbable suture attached to Meniscus Needles (FiberWire; Arthrex, Naples, FL). Needle

cannulas are used for passage of the needles (ZoneNavigator; Arthrex). It consists of 2 vertical sutures (reinforcing sutures) and 2 parallel horizontal sutures (Fig 1). First, the lateral meniscus is viewed from the anterolateral portal so that instruments can be introduced through the anteromedial portal (Fig 2). A meniscus rasp is used to debride any scar tissue within the meniscal tear. A vertical mattress stitch, the reinforcing stitch, is performed by placing the first needle 2 mm from the inner meniscus (central) and 5 mm posterior to the tear. The second needle is inserted 8 mm from the inner meniscus and 5 mm posterior to the tear. On the other side of the tear, this process is mirrored with the vertical mattress stitch placed 5 mm anterior from the tear (Fig 3). The parallel horizontal sutures, or repair sutures, are then passed while making sure that each needle passes on the side of the reinforcing stitch away from the tear and not piercing the previously placed stitch. The first needle set is passed 7 mm from the inner and the second parallel stitch/needle set is passed 3 mm from the inner meniscus. Each parallel suture is directly juxtaposition to a vertical suture (Fig 4). Each needle is grasped with a needle driver as it passes through the capsule (Fig 1).

The needle is cut free from the suture and placed safely in a bucket. Once the corresponding suture tail has been passed, the ends are clamped together with a hemostat, and the next suture is passed. Once the sutures have been passed, they are tied firmly and directly over the capsule to their corresponding end. Careful monitoring of the meniscus and repair is required inside the knee joint with the camera so as to ensure the sutures are not pulled through the meniscus as they are tied and cut. Once the repair has been confirmed, the deep layers of the medial and/or lateral incisions are closed with a size 0 braided absorbable suture. The deep dermal layer is then closed with

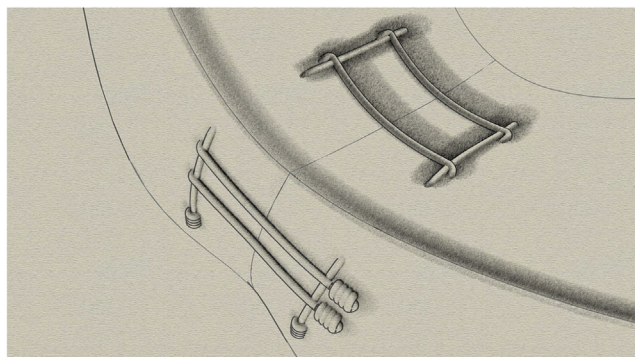


Fig 1. Illustration of a right knee lateral meniscus repair viewed from the capsular side. There is a radial tear of the mid-body. The completed rebar repair is visualized with sutures tied on the capsular side. Reproduced from Massey et al., *Journal of Experimental Orthopaedics* (<https://creativecommons.org/licenses/by/4.0/>).¹¹

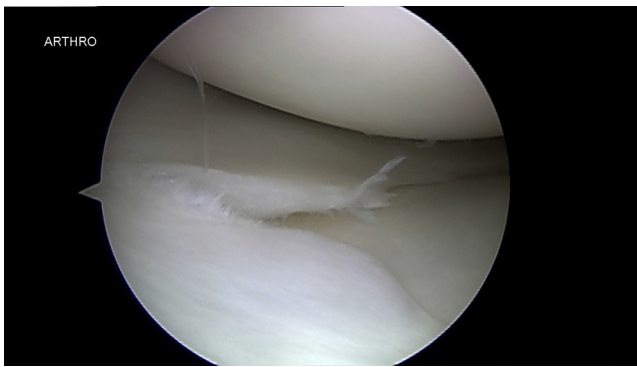


Fig 2. Right knee lateral meniscus mid-body radial meniscus tear. The arthroscope is viewing from the anterolateral portal with the knee in figure-4 supine position.

inverted simple interrupted stitches using a 3-0 braided absorbable suture. Finally, a size 3-0 monofilament absorbable suture is run in a sub-cuticular fashion. The portal incisions are then closed with a box stitch, again using the 3-0 absorbable suture. Each step can be seen in [Video 1](#). The pearls and pitfalls are listed in [Table 1](#).

Discussion

The rebar repair technique is an inside-out technique that offers a more stable suture pattern by including a reinforcing stitch on both sides of the tear that run across the circumferential fibers to help restore the natural hoop stress. These reinforcing sutures also decrease the risk of pull-out tears by reducing the tension on the tear exerted by the horizontal sutures unifying the tear.^{6,11}

For repairs of medial meniscus posterior root tears, Chung et al.¹⁰ introduced a modified Mason–Allen suture technique in which they use an inside-out suture technique and transtibial tunnel to reduce the tear and anchor the meniscus in place. This technique reduces the suture force exerted on the tear by using a horizontal loop suture as an anchor for the vertical suture used to unify the tear. The horizontal loop suture

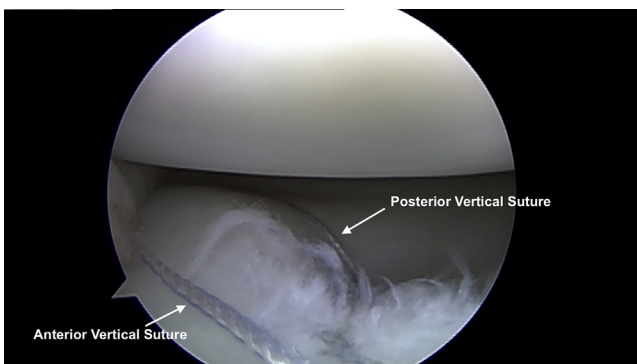


Fig 3. Right knee lateral meniscus after passage of 2 sets of meniscus needles in vertical mattress fashion. Note the tear has been partially reduced. The arthroscope is viewing from the anterolateral portal with the knee in figure-4 supine position.

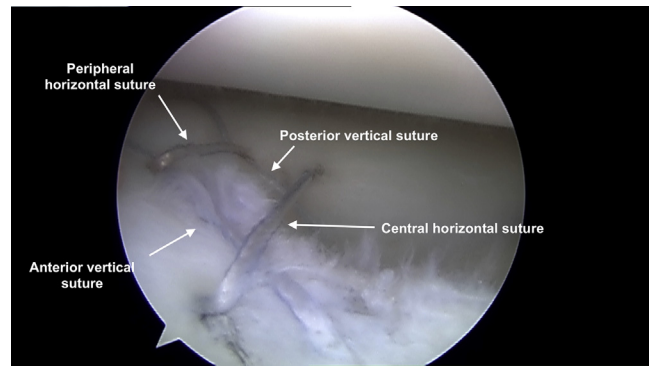


Fig 4. Right knee lateral meniscus after passage of 2 sets of meniscus needles in horizontal mattress fashion. The repair has been completed with 2 vertical sutures and then 2 parallel horizontal sutures over top of the reinforcing sutures. The arthroscope is viewing from the anterolateral portal with the knee in figure-4 supine position.

runs parallel with the radial fibers of the meniscus, which allows for a more natural distribution of force exerted on the meniscus and promotes proper healing.¹⁰ Post et al.¹² reported that the vertical suture technique was found to have a much greater load to failure than the horizontal mattress suture.

Nitri et al.⁷ describe a transtibial 2-tunnel technique to repair radial tears of the medial meniscus. The drilling of the tibial tunnels may promote healing of the tear by releasing biological factors that could aid in the healing process. However, this technique offers no reinforcement sutures, as seen in the rebar technique, and also poses the risk of decreased meniscal mobility by anchoring the meniscus into a tibial tunnel.⁷ As compared with the transtibial repair techniques, the rebar technique may offer a less technically challenging procedure to stabilize the meniscus by including 2 sets of reinforcing sutures rather than using transtibial tunnels in the bone. Buckley et al.¹³ describe a “hybrid” horizontal and vertical mattress technique where they used horizontal reinforcing sutures and compared it with 2 tunnel transtibial technique and a combined “hybrid tunnel” technique. They showed that their “hybrid” technique, which used reinforcing vertical sutures similar to the rebar repair, has comparable gapping and load to failure as their transtibial techniques.

Branch et al.¹⁴ evaluated an all-inside Mason–Allen reinforced stitch with vertical and horizontal mattress sutures. In their study, the Mason–Allen stitch had greater load to failure than the 2 inside-out parallel sutures. Nakata et al.¹⁵ also described a reinforced stitch that uses 3 horizontal sutures that had excellent clinical outcomes. Another reinforced technique has been evaluated biomechanically by Stender et al.⁸ for repairs of radial tears of the lateral meniscus. The authors showed their reinforced repair to be superior to the cross-suture technique in displacement after cyclic loading (2.42 ± 1.13 mm and 4.78 ± 1.65 mm,

Table 1. Pearls and Pitfalls

Pearls	Pitfalls
A meniscus rasp should be used to adequately free up any scar tissue.	When small longitudinal tears are also present, be sure to not place the horizontal needle too close to or inside of the tear.
Adequate dissection on the capsular side (medial or lateral) is paramount, and direct visualization of the capsule is needed for safe passage of meniscus needles.	When passing needles, hold canula firmly so that the assistant does not pull the canula into the meniscus and damage it.
Use vertical mattress sutures to reduce radial tear by passing the needle through the meniscus then translate the canula with the needle tip in the meniscus, toward the tear.	Needles may pierce previously passed sutures. If this occurs, identify the tangle on the capsular side and cut the connection of the suture limb and the loop that it passed through then pull all suture limbs tight.
Use the needle canula to move the vertical suture limb toward the tear (out of the way) and place the horizontal limb in line with the vertical limb.	Use caution to not angle the needle cannula downward too much or the needle will pierce the tibial plateau.
Use a marker to mark the horizontal limbs. Tie the vertical limbs first, then tie the marked horizontal limbs.	Meniscus needles are extremely sharp. When pulling the needles out from the capsular side, a needle driver should be kept attached close to the sharp end until it is dropped into a bucket for safety.

respectively). They report that displacement after loading is the most important concept when comparing meniscal repair techniques due to the fact that it best mimics the normal forces that act on an intact meniscus. Finally, a recent study showed the rebar repair has a greater load to failure than 2 parallel sutures and 2 crossing sutures for radial meniscus tear.¹¹ The rebar repair also has been shown to have a lower rate of meniscus cut-out than the 2 parallel suture repair or 2 crossing sutures.

There are several potential advantages and disadvantages to the rebar repair. Like all medial and lateral meniscus repairs, there are minimal risks to iatrogenic damage to neurovascular structures. From the lateral approach, caution should be used to avoid the common peroneal nerve and its branches. From the medial approach, caution should be maintained to avoid the infrapatellar branch of the saphenous nerve and saphenous vein. Another potential concern is the potential effect of the nonabsorbable suture on cartilage of the femur. Finally, the meniscus needles are long and the potential exists for a needle stick of operating room surgeons and staff. There are also several advantages to this technique. Minimal instrumentation is required, as this technique only requires standard meniscus repair needles and cannulated guides. This technique is a variation of standard inside-out technique. Surgeons who already perform basic inside-out meniscus repair should be able to easily perform this newer technique. Due to the fact that this is an inside-out technique, the needles are able to be precisely placed around the meniscus tear. Finally, the rebar repair has been shown to have a greater load to failure than standard techniques.¹¹

In conclusion, the rebar repair is an inside-out radial meniscus repair technique that may offer benefits in comparison to other reported techniques. For surgeons capable of inside-out technique with meniscus needles,

this technique offers the simplicity of only requiring meniscus needles and cannulas. This is another technique that surgeons can add to their armamentarium for dealing with this complex type of meniscus tear.

References

- Mordecai SC, Al-Hadithy N, Ware HE, Gupte CM. Treatment of meniscal tears: An evidence based approach. *World J Orthop* 2014;5:233-241.
- Fox AJ, Bedi A, Rodeo SA. The basic science of human knee menisci: Structure, composition, and function. *Sports Health* 2012;4:340-351.
- Cavanaugh JT, Killian SE. Rehabilitation following meniscal repair. *Curr Rev Musculoskelet Med* 2012;5:46-58.
- Heckmann TP, Barber-Westin SD, Noyes FR. Meniscal repair and transplantation: Indications, techniques, rehabilitation, and clinical outcome. *J Orthop Sports Phys Ther* 2006;36:795-814.
- Anderson L, Watts M, Shapter O, et al. Repair of radial tears and posterior horn detachments of the lateral meniscus: Minimum 2-year follow-up. *Arthroscopy* 2010;26:1625-1632.
- Chahla J, Serra Cruz R, Cram TR, Dean CS, LaPrade RF. Inside-out meniscal repair: Medial and lateral approach. *Arthrosc Tech* 2016;5:e163-168.
- Nitri M, Chahla J, Civitarese D, et al. Medial meniscus radial tear: A transtibial 2-tunnel technique. *Arthrosc Tech* 2016;5:e889-e895.
- Stender ZC, Cracchiolo AM, Walsh MP, Patterson DP, Wilusz MJ, Lemos SE. Radial tears of the lateral meniscus—two novel repair techniques: A biomechanical study. *Orthop J Sports Med* 2018;6:2325967118768086.
- Matsubara H, Okazaki K, Izawa T, et al. New suture method for radial tears of the meniscus: Biomechanical analysis of cross-suture and double horizontal suture techniques using cyclic load testing. *Am J Sports Med* 2012;40:414-418.
- Chung KS, Ha JK, Ra HJ, Kim JG. Arthroscopic medial meniscus posterior root fixation using a modified Mason—Allen stitch. *Arthrosc Tech* 2016;5:e63-e66.

11. Massey P, McClary K, Parker D, Barton RS, Solitro G. The rebar repair for radial meniscus tears: A biomechanical comparison of a reinforced suture repair versus parallel and cross-stitch techniques. *J Exp Orthop* 2019;6:38.
12. Post WR, Akers SR, Kish V. Load to failure of common meniscal repair techniques: Effects of suture technique and suture material. *Arthroscopy* 1997;13:731-736.
13. Buckley PS, Kemler BR, Robbins CM, et al. Biomechanical comparison of 3 novel repair techniques for radial tears of the medial meniscus: The 2-tunnel transtibial technique, a "hybrid" horizontal and vertical mattress suture configuration, and a combined "hybrid tunnel" technique. *Am J Sports Med* 2019;47:651-658.
14. Branch EA, Milchtein C, Aspey BS, Liu W, Saliman JD, Anz AW. Biomechanical comparison of arthroscopic repair constructs for radial tears of the meniscus. *Am J Sports Med* 2015;43:2270-2276.
15. Nakata K, Shino K, Kanamoto T, et al. New technique of arthroscopic meniscus repair in radial tears. *Sports Injuries* 2012:305-311.