

A rare etiology behind isolated lateral rectus palsy: Scrub typhus

Ahmad Ozair¹, Vivek Kumar², D. Himanshu², Vivek Bhat³

¹Faculty of Medicine and ²Department of Medicine, King George's Medical University, Lucknow, Uttar Pradesh, ³Faculty of Medicine, St. John's Medical College, Bengaluru, Karnataka, India

ABSTRACT

Scrub typhus (ST), a zoonotic disease, is currently being recognized as a significant contributor to the changing landscape of infectious diseases in India. As one of the important causes of febrile illness, in many parts of the country, general practitioners need to include it as part of the workup for cases of fever of unknown origin. While very amenable to early treatment with a simple regime of doxycycline, delayed diagnosis can result in a spectrum of complications. We report here one such complication of a case of ST manifesting with isolated lateral rectus palsy, which, to the best of our knowledge, has been reported only thrice in the world previously. Family physicians also need to be aware of the availability in India of affordable serological testing for ST that is useful for rapid and inexpensive diagnosis, leading to timely treatment.

Keywords: Abducens, lateral rectus, meningitis, orientia tsutsugamushi, scrub typhus

Introduction

We here present a case of scrub typhus (ST) manifesting with isolated lateral rectus palsy, which, to the best of our knowledge, has been reported only thrice in the world previously.^[1-3]

ST is endemic to the geographical region described as the tsutsugamushi triangle, which extends from northern Japan and Far-Eastern Russia in the north, to northern Australia in the south, and to Pakistan and Afghanistan in the west.^[4] It is a zoonotic disease caused by *Orientia tsutsugamushi*, transmitted by larval mites of *Leptotrombidium deliense* group, which leave behind a characteristic eschar at the bite site. The eschar is however uncommonly seen in dark-skinned individuals, including the Indian population.^[5] ST is a common cause of acute febrile illness in endemic regions but often overlooked due to nonspecific

clinical presentation, lack of specific diagnostic facilities in most areas and low index of suspicion by clinicians. Most patients of ST, however, can recover without specific complications with early diagnosis and treatment.^[6] Unfortunately, as is also commonly noticed from the cases referred to our institution, delayed treatment can lead to a host of neuropsychiatric manifestations including but not limited to meningoencephalitis, cranial nerve palsies, cerebellitis, intracranial hemorrhage, acute transverse myelitis, neuroleptic malignant syndrome (NMS), Guillain-Barre syndrome (GBS), etc.^[4] In recent years, the morbidity and mortality caused by ST have been increasingly recognized across India, especially the northern regions, where this disease was uncommonly diagnosed. Recently, Jain *et al.* described 39 seropositive cases of ST from northern India, of which around half had hypoxemia, while pleural effusions and crepitations were present in over a third of cases.^[7] Narlawar *et al.* also lately described the clinico-epidemiological profile of 173 outbreak cases over a 5-month period from Central India, most cases being from rural areas, where 17.3% of patients expired despite adequate care.^[8]

Address for correspondence: Dr. Vivek Kumar,
Department of Medicine, King George's Medical University,
Lucknow - 226 003, Uttar Pradesh, India.
E-mail: iamvivekbhagat@icloud.com

Received: 20-02-2020

Revised: 14-03-2020

Accepted: 26-03-2020

Published: 31-05-2020

Access this article online

Quick Response Code:



Website:
www.jfmipc.com

DOI:
10.4103/jfmipc.jfmipc_287_20

This is an open access journal, and articles are distributed under the terms of the Creative Commons Attribution-NonCommercial-ShareAlike 4.0 License, which allows others to remix, tweak, and build upon the work non-commercially, as long as appropriate credit is given and the new creations are licensed under the identical terms.

For reprints contact: WKHLRPMedknow_reprints@wolterskluwer.com

How to cite this article: Ozair A, Kumar V, Himanshu D, Bhat V. A rare etiology behind isolated lateral rectus palsy: Scrub typhus. J Family Med Prim Care 2020;9:2538-40.

Case Report

A 27-year-old, previously healthy female presented to the apex public referral hospital of Uttar Pradesh with a 10-day history of fever, followed by altered sensorium, jaundice, and diplopia for 4 days. Physical examination discovered icterus, right-sided lateral rectus palsy and GCS of $E_4V_4M_6$, other than which all systems seemed normal, including hemodynamic status and neurological examination. However, intracranial pressure did not seem to be elevated clinically, nor was papilloedema present. Accordingly, she was admitted and started on broad-spectrum intravenous antibiotics, while being worked-up with a broad differential. Routine investigations revealed leucocytosis (TLC = 17200 cells/mm³), mild microcytic hypochromic anemia, pre-renal acute kidney injury (BUN = 52 mg/dL, serum creatinine = 0.87 mg/dL), conjugated hyperbilirubinemia (total = 8.2 mg/dL, direct = 5.3 mg/dL), deranged liver function (AST = 128 IU/L, ALT = 125 IU/L, ALP = 859 IU/L, serum albumin = 2.8 g/dL). Coagulation studies and platelet counts were within normal limits. The patient was diagnosed with multi-organ dysfunction syndrome (MODS) and workup was continued.

However, blood and urine cultures turned out to be sterile. CSF examination revealed protein = 137 mg/dL, CSF glucose = 53 mg/dL (normal as per corresponding blood glucose), leukocyte count = 10 cells/mm³ (neutrophils = 20%, lymphocytes = 80%). PCR in CSF for Herpes simplex virus was negative, while so was testing for antibodies to Japanese Encephalitis virus and GeneXpert MTB/RIF assay for tuberculosis. Tests for malaria and leptospirosis also came back negative. While headache and meningeal signs were absent, MRI of the brain indicated patchy leptomenigeal enhancement only suggestive of meningitis [Figure 1].

As part of the local protocol for workup of febrile illness, serological testing via ELISA found her positive for IgM antibodies against all three of dengue, chikungunya and ST, which introduced a diagnostic challenge for us. Our forthcoming work has demonstrated that antibody cross-reactivity is common; hence a single agent needed to be focused upon.^[9] Based on the 10-day history of fever, a viral etiology seemed unlikely. Clinical features, CSF picture, leucocytosis all supported ST; hence we went ahead with the administration of doxycycline. The rapid clinical response confirmed this diagnosis as correct. The patient was discharged after a week of admission, to further continue on oral doxycycline for a week. Currently, she is in regular follow-up for 4 months, with the lateral rectus palsy having resolved gradually over months. No residual deficits are currently present.

Discussion

A comprehensive review of the MEDLINE database and searching of reference lists suggests, to the best of our knowledge, that this is the fourth reported case in the literature of ST manifesting with isolated abducens nerve palsy, without

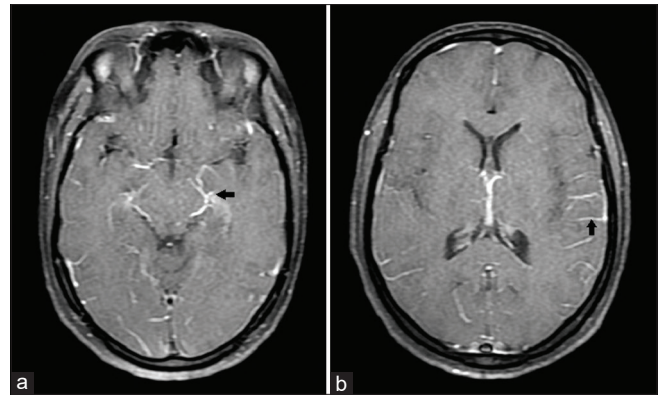


Figure 1: (a) and (b) Patchy leptomenigeal enhancement on an axial section of contrast-enhanced brain MRI, suggestive of meningitis (arrows)

intracranial hypertension.^[1-3] Bharadwaj *et al.* reported a case from India of a 23-year-old female with meningitis and characteristic eschar who, after diagnosis of ST and initiation of doxycycline, developed sudden-onset diplopia with right-sided esotropia, which resolved after completion of doxycycline therapy.^[1] Lee *et al.* described a case of a 24-year-old female in Korea who presented classically with eschar and febrile rash and again developed sudden-onset diplopia with left-sided esotropia on starting of doxycycline therapy. The eye signs here took four months to fully resolve, as in ours.^[2] Most recently, Ete *et al.* reported of a 22-year-old female from India, who presented with altered sensorium, meningitis and bilateral lateral rectus palsy, but responded well to doxycycline.^[3] Unlike these cases, our case did not have an eschar, which is often not found in ST cases in our clinical practice, a point to be noted by general practitioners. Here, Weil-Felix testing or PCR for ST for additional diagnostic confirmation could not be performed due to the patient's poor financial condition.

We recognize that since ST is endemic in many parts of Asia, literature in Chinese, Korean or Japanese languages might have further cases of such sequelae, which we were unable to account for due to logistical challenges in translation.

As frontline doctors in the field, family physicians ought to know of the growing recognition of ST in north India. Because MODS and/or death can occur with therapeutic delay, early diagnosis of ST is critical, which is facilitated by the rapid and inexpensive serological testing. General practitioners should be cognizant of the availability of serological testing in India at affordable rates since 2015. Family physicians need also to be aware of its diverse presentations and keep a high index of suspicion, with its current endemicity in large parts of India. Finally, general practitioners should recognize that meningoencephalitis with ST can mimic tubercular meningitis, and can lead to devastating complications if not timely treated.^[4,5]

Declaration of patient consent

The authors certify that they have obtained all appropriate patient consent forms. In the form, the patient (s) has/have

given his/her/their consent for his/her/their images and other clinical information to be reported in the journal. The patients understand that their names and initials will not be published and due efforts will be made to conceal their identity, but anonymity cannot be guaranteed.

Financial support and sponsorship

Nil.

Conflicts of interest

There are no conflicts of interest.

References

1. Bhardwaj B, Panda P, Revannasiddaiah S, Bhardwaj H. Abducens nerve palsy in a patient with scrub typhus: A case report. *Trop Biomed* 2013;30:706-9.
2. Lee YH, Yun YJ, Jeong SH. Isolated abducens nerve palsy in a patient with scrub typhus. *J AAPOS* 2010;14:460-1.
3. Ete T, Mishra J, Barman B, Mondal S, Sivam RKN. Scrub typhus presenting with bilateral lateral rectus palsy in a female. *J Clin Diagnostic Res* 2016;10:16-7.
4. Mahajan SK, Mahajan SK. Neuropsychiatric manifestations of scrub typhus. *J Neurosci Rural Pract* 2017;8:421-6.
5. Iqbal N, Mookkappan S, Basheer A. Scrub typhus meningoencephalitis. *J Curr Res Sci Med* 2015;1:3-5.
6. Kim DM, Kim SW, Choi SH, Yun NR. Clinical and laboratory findings associated with severe scrub typhus. *BMC Infect Dis* 2010;10:108.
7. Jain D, Nand N, Giri K, Bhutani J. Scrub typhus infection, not a benign disease: An experience from a tertiary care center in Northern India. *Med Pharm Rep* 2019;92:36-42.
8. Narlawar UW, Lilare RR, Gawande BS. Epidemiology and clinical profile of scrub typhus outbreak in a tertiary care centre of central India. *Int J Community Med Public Health* 2019;6:4867-9.
9. Ozair A, Khan DN, Prakash S, Bhagat A, Verma A, Shukla S, *et al.* Upsurge of Chikungunya in Uttar Pradesh. *Indian J Med Res* (in press).