

Ophthalmic presentations and long-term outcomes of subconjunctival and atypical orbital myocysticercosis

Manpreet Singh, Manjula Sharma, Shweta Chaurasia, Aditi Mehta Grewal, Savleen Kaur, Manpreet Kaur, Deepti Yadav, Pankaj Gupta

Purpose: To study the clinical presentation, radiological features, diagnosis, and treatment response in subconjunctival and atypical orbital myocysticercosis. **Methods:** Retrospective analysis of diagnosed subconjunctival and atypical (strabismus, diplopia, and blepharoptosis) orbital myocysticercosis was performed. A diagnostic criterion (2 of the 3) among clinical features, radiological findings, and treatment response was used in our study. A minimum of “post-treatment” follow-up of 12 months was observed. **Results:** Thirty-five patients were included with a mean age of 16 years having male predominance ($n = 22$, 62.8%). All had a unilateral presentation, with 24 (68.6%) patients having subconjunctival cysticercosis, of which 22 were located in close proximity of the rectus muscle insertion. At presentation, 10 patients had diplopia, 7 had strabismus, and 6 had face turn. Pseudo Duane’s and pseudo-Brown’s syndrome were noted in 5 and 4 patients, respectively. Radiologically, single muscle myositis without scolex was seen in 12 (34.3%) cases. All patients first received medical treatment, and surgical intervention (cyst removal) was attempted after treatment failure. Complete resolution of symptoms was noted in 22 (after medical treatment only) and in 8 (after surgery). **Conclusion:** In the majority, the subconjunctival cysticercosis is found in proximity to the rectus muscle insertion, as a part of orbital myocysticercosis. In atypical scenarios, a satisfactory response to medical treatment can be considered as diagnostic of cysticercosis.

Key words: Atypical ophthalmic cysticercosis, atypical orbital myocysticercosis, orbital myocysticercosis, subconjunctival cysticercosis

Ophthalmic cysticercosis is broadly divided into intraocular and extraocular cysticercosis; the latter is more common (up to 86%) in the Indian population.^[1-3] Among extraocular cysticercosis, the orbital myocysticercosis is the commonest subtype.^[1,2] However, the subconjunctival (3%–86%), orbital (7%–59%), and eyelid (0–14%) tissues may get involved in descending order.^[1-6] Subconjunctival cysticercosis has been mentioned as an anterior extension of the cyst from the insertions of extraocular muscles (recti and obliques).^[1,2]

The extraocular cysticercosis can have a myriad of clinical presentations depending on the cyst stage, its site, size, and relation to adjacent vital ophthalmic structures.^[1,7] Orbital myocysticercosis masquerades various ophthalmic manifestations, both clinically and radiologically. It may mimic preseptal and orbital cellulitis, idiopathic orbital inflammatory disease, optic neuritis, acquired blepharoptosis, subperiosteal abscess, double elevator palsy, or double depressor underaction, Duane’s retraction syndrome, and Brown’s syndrome.^[7-14] Hence, the initial presentations may pose a significant diagnostic dilemma to primary ophthalmologists.

The radiological features may mislead in cases having cysticercosis cyst without typical scolex.^[7,15,16] A fusiform or localized enlargement of the rectus muscle, absence of scolex, atypical location of the cyst, and severe localized inflammation are such scenarios.^[8,9,15] There is a lacuna about the atypical presentations and diagnostic criteria of orbital myocysticercosis. Moreover, subconjunctival or conjunctival cysticercosis has been mentioned as unusual cases in research articles and case reports.^[17-21] Hence, we conducted a study inferring the clinical and radiological features of suspected or diagnosed subconjunctival and atypical orbital myocysticercosis. Informed consent was obtained from all patients for the publication of their nonidentifiable clinical images in scientific journals. Our study adhered to the tenets laid by the Declaration of Helsinki.

Methods

Ours is a retrospective study of patients having subconjunctival and orbital myocysticercosis who presented to our institute

This is an open access journal, and articles are distributed under the terms of the Creative Commons Attribution-NonCommercial-ShareAlike 4.0 License, which allows others to remix, tweak, and build upon the work non-commercially, as long as appropriate credit is given and the new creations are licensed under the identical terms.

For reprints contact: WKHLRPMedknow_reprints@wolterskluwer.com

Cite this article as: Singh M, Sharma M, Chaurasia S, Grewal AM, Kaur S, Kaur M, *et al.* Ophthalmic presentations and long-term outcomes of subconjunctival and atypical orbital myocysticercosis. *Indian J Ophthalmol* 2021;69:2782-7.

Access this article online

Website:

www.ijo.in

DOI:

10.4103/ijo.IJO_568_21

Quick Response Code:



Department of Ophthalmology, Advanced Eye Centre, Post Graduate Institute of Medical Education and Research, Chandigarh, India

Correspondence to: Dr. Manpreet Singh, Department of Ophthalmology, Room No. 504, 5th Floor, Advanced Eye Centre, Post Graduate Institute of Medical Education and Research, Chandigarh, India. E-mail: drmanu83@gmail.com

Received: 11-Mar-2021

Revision: 08-Jun-2021

Accepted: 02-Jul-2021

Published: 25-Sep-2021

from January 2014 to December 2018. The ethical clearance to conduct this study was duly obtained from department on 30.11.2019. The clinic record files and telephonic conversations with patients for additional information were used to fill the study sheet. All patients were clinically suspected to be subconjunctival [Fig. 1a-d] or orbital myocysticercosis and orbital imaging was requested for its detection, confirmation, and/or monitoring of the disease.

The data included patient demographics (age, gender, laterality, and duration of presentation), clinical features (symptoms and signs), working diagnosis, imaging, treatment advised (medical only/medical + surgical), and clinical outcomes. The ophthalmic examination records included visual acuity, extraocular movements, eyelid and adnexal details, exophthalmometry (if required), and detailed ocular examination on slit-lamp biomicroscopy and indirect ophthalmoscopy. The detailed fundus examination of all patients ruled out intraocular cysticercosis before starting antihelminthic treatment to prevent vision decline. The patients having intraocular cysticercosis were excluded from our study.

The radiological features of ultrasonography (USG)/computed tomography (CT)/magnetic resonance imaging (MRI) were observed for extraocular muscle involved, location of cyst in the muscle (anterior half/posterior half), and presence of coexisting neurocysticercosis (cranial imaging) [Fig. 2a-d]. The clinical and radiological images were retrieved from the image data bank of our clinic.

In the primary management, oral albendazole (15 mg/kg/day) with oral steroids (1 mg/kg, same day) was prescribed to all patients for 4–12 weeks depending upon the speed of response. Topical fluorometholone, 0.1% suspension, was used in all to reduce the ocular surface inflammation [Figs. 1b, 3b and 4a]. A few cases required surgical excision for subconjunctival

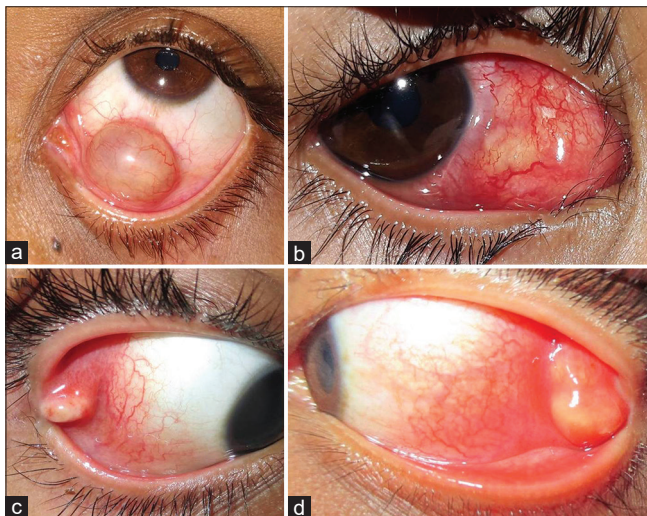


Figure 1: (a) An isolated yellowish subconjunctival cyst is noted in the left inferior fornix. The transillumination test was negative. (b) Right medial subconjunctival cyst (in medial rectus region) with overlying conjunctival congestion. Few dilated and tortuous vessels are noted. (c) A right temporal subconjunctival cyst (in lateral rectus region) with more localized conjunctival congestion. Note the features suggestive of possible spontaneous extrusion. (d) Left temporal subconjunctival cyst with localized inflammation

and anterior myocysticercosis cysts. Histopathology was duly performed for the excised tissues and cysts.

Any 2 of the 3 below-mentioned criteria were considered as diagnostic of orbital myocysticercosis. The criteria included:

1. *Clinical features (in various combinations):* orbital pain with restricted ocular motility, diplopia, blepharoptosis, proptosis, squint, localized conjunctival inflammation, and localized yellowish subconjunctival nodule.
2. *Radiological findings (CT/MRI scans)* [Fig. 2]: the presence of cyst with or without scolex inside the rectus muscle, enlarged rectus muscle (myositis), fusiform muscle belly enlargement, with or without neurocysticercosis.
3. *Desired treatment response:* complete resolution of symptoms within 6–8 weeks and/or radiological evidence of the disappearance of cyst.

Medical treatment failure was described as minimal or no resolution of symptoms after 6 weeks of continuous treatment. The total duration of therapy, indications for surgical intervention, and the time taken for complete clinical and/or radiological resolution were noted. The patients having a minimum follow-up of 12 months after completion of the treatment were included in our study.

Results

Of 39 diagnosed patients, complete records were available for 35 patients having orbital myocysticercosis. The majority of patients were males ($n = 22$, 62.8%) with a median age at presentation of 16 years (range, 1–50 years). All had unilateral orbital involvement with a slight right orbital preponderance ($n = 19$, 54.3%). The rest of the demographic details, clinical symptoms, and signs are compiled in Table 1. The diagnosis at referral were conjunctivitis ($n = 14$), strabismus ($n = 9$), preseptal cellulitis ($n = 8$), and conjunctival retention cyst ($n = 4$).

Sixteen (45.7%) patients underwent orbital ultrasonography in the clinic, while all ($n = 35$) underwent orbital and cranial imaging. The latter was requested for detecting any neurocysticercosis lesion (active or inactive). The details of orbital imaging are mentioned in Table 1. Radiologically, the size of the cyst ranged from 4 mm to 18 mm in the longest dimension.

On presentation, 24 (68.6%) patients had reddish-yellow subconjunctival nodule representing the anterior part or complete lesion [Fig. 1a-d]. Of these, 22 (91.7%) nodular lesions were located near the insertion of a rectus muscle. Coexisting neurocysticercosis was seen in 2 (5.71%) patients. One patient had an isolated subconjunctival nodulo-cystic lesion at the limbus without muscle involvement [Fig. 1a]. None of our patients had disseminated cysticercosis. The diagnosis of cysticercosis was based on clinical features ($n = 26$, 74.3%), radiological findings ($n = 18$, 51.4%), and treatment response ($n = 9$, 25.7%). The combination of 2 of the 3 criteria was considered as diagnostic of conjunctival or atypical orbital myocysticercosis.

All 35 patients were primarily managed with medical treatment (albendazole + oral steroids), and of those, 22 resolved completely without any sequelae [Fig. 3]. Five (14.2%) had residual extraocular muscle movement restriction in extreme gaze without clinically disturbing diplopia. Four (11.4%) patients having subconjunctival cysts showed spontaneous

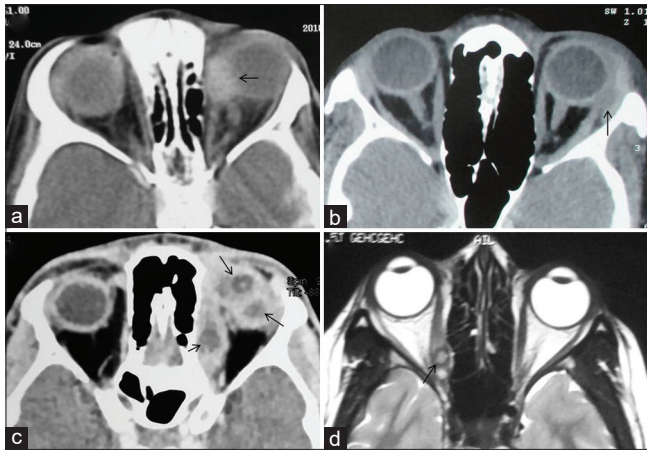


Figure 2: (a) Left medial rectus shows isolated muscle belly enlargement (black arrow) in anterior 1/3rd of belly and insertion. (b) A small speck of hyperdensity seen inside the anterior lateral rectus muscle cyst. (c) A superior section shows a rare event of 3 cysts in superior oblique muscle (3 black arrows), two cysts showing hyperdense foci inside suggestive of a scolex. (d) A posterior 1/3rd muscle belly cyst of right medial rectus muscle with mild compression over the optic nerve

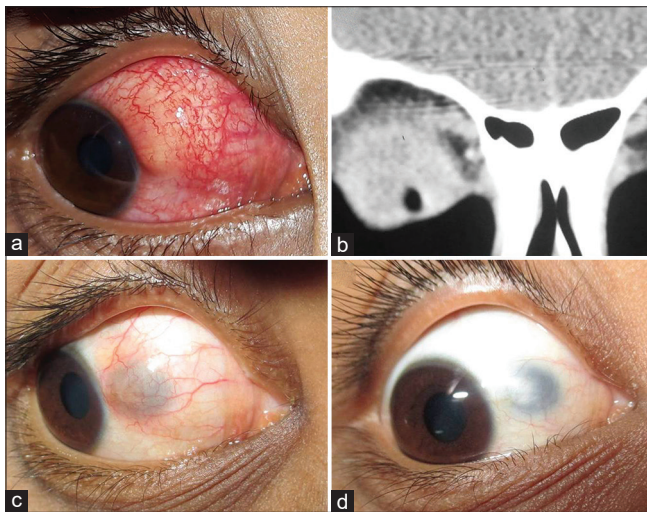


Figure 4: (a) Right anterior subconjunctival cyst with inflammation in the medial rectus region. (b) CT scan shows hyperdense scolex with surrounding hypodense fluid. (c) 1 month after completion of medical treatment, the resolution of cyst is noted with mild scleral thinning and resolving conjunctival congestion. (d) Six months after completion of treatment, minimal congestion and a well-defined region of scleral thinning (medial rectus insertion) can be noted

extrusion after starting the medical treatment. Visual acuity recovered in all patients irrespective of the treatment modality. Other treatment details are tabulated in Table 2.

Total 13 patients required surgical intervention, of which 5 had anterior subconjunctival lesions. Histopathology established the diagnosis of cysticercosis in 7 cases (53.8%), while in the rest, it was reported as an inflammatory cyst. Postoperatively, the majority ($n = 8$) showed satisfactory clinical outcomes, while five showed partial recovery with a residual deficit in extraocular motility. However, the residual diplopia was noted in extreme gazes and did not affect daily life activities. Of these, 2 patients showed clinical recurrence, which

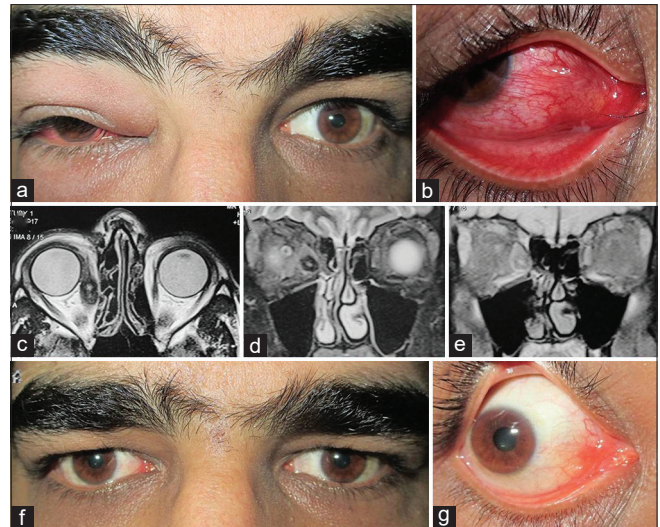


Figure 3: (a) A 17-year-old male with right painful blepharoptosis, eyelid edema, and conjunctival congestion. Mild adduction restriction is noted. (b) A localized yellowish subconjunctival cyst in medial rectus region with surrounding acute conjunctival inflammation. (c-e) (MRI axial and coronal sections) A left medial rectus cystic lesion is noted in the middle 1/3rd of belly, showing hyperintense focus surrounded by hypointense fluid. Similar features are seen in coronal sections without (d) and with contrast (e). (f) Complete resolution of blepharoptosis, eyelid edema, and conjunctival congestion (g)

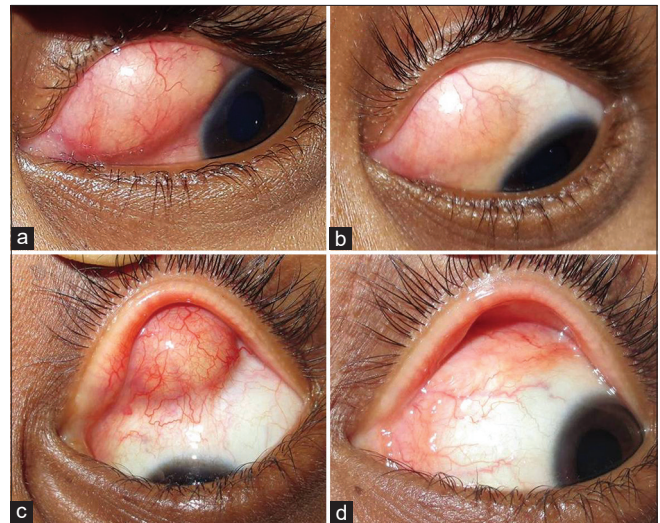


Figure 5: (a) Left superonasal large anterior subconjunctival cyst. (b) After 6 weeks of medical treatment, near-total resolution of the cyst is noted. (c) Another patient with left superior subconjunctival cyst with localized inflammation and impeding spontaneous extrusion. (d) Post-surgical, complete resolution of the symptoms and the mild conjunctival scar is noted. This patient did not respond to medical treatment for 6 weeks

got resolved after a second course of albendazole and steroids of 4 weeks. After the medical resolution of the cysticercosis cyst, one patient had a residual scleral thinning at the same site, near the medial rectus insertion [Fig. 4]. One patient had a near-total resolution of the subconjunctival cyst and had a minimal yellowish inactive portion of the cyst, which remain the same at 12 months post-treatment follow-up [Fig. 5a and b].

Table 1: Clinical and radiological features of patients having subconjunctival and atypical orbital myocysticercosis

1. Locality of patients	Urban=7 (20%)	Semi-urban=20 (57.1%)	Rural=8 (22.9%)
2. Socio-economic status	High=5 (14.3%)	Middle=19 (54.3%)	Low=11 (31.4%)
3. Mean duration of symptoms	5.5 days		
a. Symptoms		b. Signs	
Conjunctival congestion	28 (80%)	Restricted extraocular movements	26 (74.3%)
Orbital pain	18 (51.4%)	Subconjunctival cyst	24 (68.6%)
Diplopia	10 (28.6%)	Orbital sulcus fullness	14 (40%)
Proptosis	10 (28.6%)	Pseudo Duane's retraction	5 (14.3%)
Strabismus	7 (20%)	Pseudo Brown's syndrome	4 (11.4%)
Face turn	6 (17.1%)	Blepharoptosis	4 (11.4%)
Best corrected visual acuity	<6/60=3 patients; >6/60=32 patients		
c. Orbital imaging features			
Extraocular muscle involved		Atypical features	
Medial rectus	12 (34.3%)	Single muscle myositis without scolex	12 (34.3%)
SR-LPS complex	9 (25.7%)	Diffuse single muscle myositis	6 (17.1%)
Superior oblique	7 (20%)	Pseudo-abscess	5 (14.3%)
Lateral rectus	5 (14.3%)	Multiple loculations	3
Inferior rectus	1 (2.85%)	Fusiform belly enlargement	2
Location of cyst in muscle belly			
Anterior 1/3rd	20		
Central 1/3rd	9		
Posterior 1/3rd	5		

Table 2: Treatment summary of the patients

Total patients received medical treatment	35
Total patients underwent surgery	13
Mean duration of medical treatment	8.5 weeks
Indications for surgery	Treatment failure Subconjunctival anterior cyst
Mean time taken for complete resolution	14.5 weeks

At a mean follow-up of 14.5 months, 30 patients showed complete clinical response without residual sequelae in terms of visual acuity, proptosis, and extraocular movements. Two patients showed partial clinical recovery (residual strabismus) and 3 showed no response to the medical + surgical treatment.

Discussion

Cysticercosis usually affects more vascularized tissues like the brain, the muscles of the head and neck, tongue, and heart.^[22] The glucose or glycogen content of these tissues and the rate of blood flow are directly responsible for this preponderance. Orbital cysticercosis can have variable presentations, which may become a diagnostic challenge for primary ophthalmologists. Moreover, the anterior cysts present inside the rectus muscle bellies or near their insertion points have inconsistent presentations depending upon the acute or chronic stage. Hence, our study aimed to describe these atypical clinical and radiological features of orbital myocysticercosis.

As described in previous reports, the diagnosis of cysticercosis at referral is noted in around 7% of cases.^[1] In orbital and adnexal cysticercosis, extraocular myocysticercosis

has been reported as the most common variety.^[2] Typical findings of cysticercosis cyst constitute inflammatory and mass effect features.^[2,23] The masquerading clinical presentations of atypical orbital myocysticercosis in our study were blepharoptosis, yellowish subconjunctival nodule with inflammation, strabismus, diplopia, face turn, and pseudo-Duane's and pseudo-Brown's syndrome [Table 1]. The incidence of cysticercosis has been found to be more common in the younger population and our results (mean age: 16 years) also supported the same.^[1,2,22,16]

In atypical clinical presentation of orbital and adnexal cysticercosis, radiological investigations like USG, CT scan, or MRI of orbits may provide the diagnostic clues (like highly reflective or hyperdense scolex). The cystic or mass-like lesions without scolex inside an extraocular muscle with surrounding inflammation may point toward myocysticercosis. In few occasions, there might be more than one cystic or mass-like lesion inside or arising from the recti muscles. Honavar and Sekhar^[16] have reported that around 50% of the cysts may show scolex on USG. Hence, fusiform enlargement of rectus muscle alone has been considered to be likely of cysticercosis by Sekhar and Lemke.^[24] In our study, the scolex was not seen in 20 cases on orbital imaging. We experienced features like single muscle myositis (localized *n* = 12, and diffuse *n* = 6) and fusiform enlargement of muscle belly in 2 patients.

Escobar has described the pathology of neurocysticercosis as the vesicular stage, colloid phase of vesicular form, granular nodular stage, and nodular calcified stage.^[25] Honavar and Sekhar^[16] have described the stages of the cyst as viable, degenerative, and inactive on the basis of ultrasonography. However, the intracystic hyperreflective foci can be viable scolex or calcified inactive cysts.^[16,22] These radiological

masquerades should be backed by the clinical presentation and a response to the medical treatment for establishing a diagnosis of ophthalmic cysticercosis.

The differential for an ill-defined, multi-loculated, cystic lesion with thick peripheral enhancement with or without surrounding inflammatory change is a tuberculoma. Both tuberculosis and cysticercosis are endemic in India as well as other developing nations.^[1-8,22,23] Classically, total and differential leukocyte counts, Mantoux test, chest X-ray, and sputum examination for acid-fast bacilli help in establishing the diagnosis of tuberculosis and help in starting appropriate treatment. For cysticercosis, blood investigations like peripheral eosinophilia, ELISA for anticysticercal antibodies, and stool examination for cysts can be helpful but are inconclusive, if negative.

Various authors have recommended considering the overall clinical presentation with available radiological features for making a diagnosis of orbital myocysticercosis and starting the treatment.^[2,16,22] We have suggested the use of treatment response as the additional diagnostic criteria in perplexing situations where the clinical and radiological evidence is not sufficient for establishing the diagnosis of orbital myocysticercosis.

Subconjunctival cysticercosis is an interesting clinical entity due to its masquerading clinical features like acute conjunctivitis in the early inflammatory phase.^[17-21] We have hypothesized subconjunctival cysticercosis to be a part of anterior myocysticercosis and have documented few cases. All had a close association between the rectus muscles of the complimentary orbital quadrant. In our study, 4 (11.4%) patients had spontaneous extrusion of the subconjunctival cysticercosis cyst. However, the role of medical treatment in spontaneous extrusion is not established, with anecdotal pieces of evidence in its favor.

The extraocular muscle myocysticercosis may masquerade any acquired motility disorder like paralytic or restrictive pathology and have presentations similar to double elevator palsy, Brown's syndrome, Duane's retraction syndrome, and sometimes total ophthalmoplegia.^[11-14,22] However, a detailed strabismus evaluation with the clinico-radiological evidence of inflammatory pathology may provide clarity to the situation. The superior oblique muscle has been shown to have twin cysticercosis lesions, often probably due to its long course and closer proximity to the neuro-vascular bundle present at the orbital apex.^[21]

The management of orbital myocysticercosis is medical in >95% of cases and a few need surgical intervention for the removal of nonresponding cysts.^[1-8,22,23] In either of the management strategies, residual restriction of extraocular movements in extreme gaze can be seen as the sequelae of orbital myocysticercosis. However, in the case of subconjunctival cysticercosis, the surgical management can be performed earlier at a stage when acute anterior inflammation has subsided. It may reduce the overall duration of the medical treatment and provide faster and effective relief from the symptoms. The chance of extraocular muscle movement restriction after the surgical treatment is also negligible in the case of subconjunctival cysticercosis. Rath *et al.*^[1] reported residual deficits in 21% of their patients

at the final follow-up, while in our series, we experienced a residual deficit in 14.2% cases. Rath *et al.* believed that early diagnosis and treatment might limit the fibrosis and restriction of ocular movements.^[1]

Salim *et al.*^[26] showed 9.83% cases to have orbital cysticercosis without the involvement of an extraocular muscle. They showed complete radiological resolution in 45% and partial resolution in 47.5% of cases. The equal importance of clinical, radiological, microbiological, and histopathological evidence has been suggested by Hamal *et al.*^[27] for the diagnosis of cysticercosis. In treatment, the steroids have been shown to increase the plasma levels of albendazole, hence, supplementing the therapeutic response of the antihelminthic drug leading to an overall improvement in the outcomes.^[28]

Conclusion

With our experience of atypical and subconjunctival cysticercosis, we suggest keeping the odds of having a diagnosis of cysticercosis high in the younger population, especially in an endemic region like ours. Subconjunctival cysticercosis is a part of anterior myocysticercosis, which needs to be dealt with medical treatment followed by surgical intervention (if needed). A patient having diplopia with restrictive strabismus and inflammation may need orbital imaging as a part of the investigative protocol. Overall, in suspected orbital myocysticercosis patients, a satisfactory clinical response to the medical management may be considered as a diagnostic sign.

Acknowledgments

Prof. Jagat Ram, Director, Post Graduate Institute of Medical Education and Research, Chandigarh, India for his encouragement and support.

Financial support and sponsorship

Nil.

Conflicts of interest

There are no conflicts of interest.

References

- Rath S, Honavar SG, Naik M, Anand R, Agarwal B, Krishnaiah S, *et al.* Orbital cysticercosis: Clinical manifestations, diagnosis, management, and outcome. *Ophthalmology* 2010;117:600-5.
- Pushker N, Bajaj MS, Betharia SM. Orbital and adnexal cysticercosis. *Clin Exp Ophthalmol* 2002;30:322-33.
- Madigubba S, Vishwanath K, Reddy G, Vemuganti GK. Changing trends in ocular cysticercosis over two decades: An analysis of 118 surgically excised cysts. *Indian J Med Microbiol* 2007;25:214-9.
- David S, Mathai E. Ocular cysticercosis-a review of 25 cases. *J Assoc Physicians India* 2000;48:704-7.
- Chowdhary A, Bansal R, Singh K, Singh V. Ocular cysticercosis-a profile. *Trop Doct* 2003;33:185-8.
- Mohan K, Saroha V, Sharma A, Pandav S, Singh U. Extraocular muscle cysticercosis: Clinical presentations and outcome of treatment. *J Pediatr Ophthalmol Strabismus* 2005;42:28-33.
- Singh U, Gupta P, Bansal R. Unusual presentation of orbital cysticercosis in subperiosteal space. *J Pediatr Ophthalmol Strabismus* 2008;45:379-80.
- Malhotra R, Garg P, Mishra R, Khanduri S. Orbital cysticercosis: Masquerading as orbital inflammatory disorder. *Trop Doct* 2011;41:119-20.

9. Angotti-Neto H, Gonçalves AC, Moura FC, Monteiro ML. Extraocular muscle cysticercosis mimicking idiopathic orbital inflammation: Case report. *Arq Bras Oftalmol* 2007;70:537-9.
10. Bajaj MS, Pushker N. Optic nerve cysticercosis. *Clin Exp Ophthalmol* 2002;30:140-3.
11. Basu S, Muthusami S, Kumar A. Ocular cysticercosis: An unusual cause of ptosis. *Singapore Med J* 2009;50:e309-11.
12. Labh RK, Sharma AK. Ptosis: A rare presentation of ocular cysticercosis. *Nepal J Ophthalmol* 2013;5:133-5.
13. Pandey PK, Chaudhuri Z, Bhatia A. Extraocular muscle cysticercosis presenting as Brown syndrome. *Am J Ophthalmol* 2001;131:526-7.
14. Pandey PK, Bhatia A, Garg D, Singh R. Canine tooth syndrome due to superior oblique myocysticercosis. *J Pediatr Ophthalmol Strabismus* 2006;43:185-7.
15. Pahwa S, Sharma S, Das CJ, Dhamija E, Agrawal S. Intraorbital cystic lesions: An imaging spectrum. *Curr Probl Diagn Radiol* 2015;44:437-48.
16. Honavar SG, Sekhar CG. Ultrasonological characteristics of extraocular cysticercosis. *Orbit* 1998;17:271-84.
17. Obedulla H, Pujari A, Gupta Y, Basheer S. Spontaneous extrusion of subconjunctival cysticercosis cyst. *BMJ Case Rep* 2017;2017:bcr2017221470.
18. Bhatia K, Sengupta S, Sharma S. Spontaneous extrusion of subconjunctival cysticercosis cyst. *JAMA Ophthalmol* 2016;134:e155025.
19. Joshi R. Subconjunctival cysticercosis. *J Indian Med Assoc* 2009;107:177.
20. Kumar A, Pushker N, Bajaj MS, Sen S, Agrawal A. Unifocal, subconjunctival twin cysticercosis cysts. *J Pediatr Ophthalmol Strabismus* 2007;44:55-6.
21. Bhattacharjee K, Singh M, Das D, Bhattacharjee H. Subconjunctival and orbital (Twin) cysticercosis in a child. *J Ophthalmic Vis Res* 2019;14:387-9.
22. Murthy R, Samant M. Extraocular muscle cysticercosis: Clinical features and management outcome. *Strabismus* 2008;16:97-106.
23. Rao VB, Sahare P, Varada V. Acquired brown syndrome secondary to superior oblique muscle cysticercosis. *J AAPOS* 2003;7:23-34.
24. Sekhar GC, Lemke BN. Orbital cysticercosis. *Ophthalmology* 1997;104:1599-604.
25. Escobar A. The pathology of neurocysticercosis. In: Palacios E, Rodriguez-Carbajal J, Taveras JM, editors. *Cysticercosis of the Central Nervous System*. Springfield, IL: Thomas; 1983. p. 27-54.
26. Salim S, Alam MS, Backiavathy V, Raichura ND, Mukherjee B. Orbital cysticercosis: Clinical features and management outcomes. *Orbit* 2020;1-7. doi: 10.1080/01676830.2020.1833942. Online ahead of print.
27. Hamal D, Kafle S, Arjyal P, Poudyal P, Lamichhane B, Limbu B. Orbital myocysticercosis different presentation and management in Eastern Nepal. *Nepal J Ophthalmol* 2020;12:125-32.
28. Jung H, Hurtado M, Medina MT, Sanchez M, Sotelo J. Dexamethasone increases plasma levels of albendazole. *J Neurol* 1990;237:279-80.