



Published in final edited form as:

Mod Pathol. 2012 May ; 25(5): 699–708. doi:10.1038/modpathol.2011.208.

Clinical Assessment of PTEN Loss in Endometrial Carcinoma: Immunohistochemistry Out-Performs Gene Sequencing

Bojana Djordjevic^{1,2}, Bryan T. Hennessy^{3,4}, Jie Li⁵, Bedia A. Barkoh⁶, Rajyalakshmi Luthra⁶, Gordon B. Mills⁵, and Russell R. Broaddus¹

¹Department of Pathology, University of Texas M.D. Anderson Cancer Center, Houston, Texas, United States

³Department of Gynecologic Medical Oncology, University of Texas M.D. Anderson Cancer Center, Houston, Texas, United States

⁵Department of Systems Biology, University of Texas M.D. Anderson Cancer Center, Houston, Texas, United States

⁶Department of Hematology, University of Texas M.D. Anderson Cancer Center, Houston, Texas, United States

Abstract

PTEN is a tumor suppressor that negatively regulates the PI3K-AKT signaling pathway, which is implicated in the pathogenesis of endometrial carcinoma. Sanger sequencing has been considered to be the gold standard for detection of *PTEN* sequence abnormalities. However, this approach fails to address the epigenetic mechanisms that contribute to functional *PTEN* loss. Using a study cohort of 154 endometrioid and non-endometrioid endometrial carcinomas, we performed full-length *PTEN* sequencing and *PTEN* immunohistochemistry on each tumor. *PTEN* sequence abnormalities were detected in a significantly lower proportion of cases (43%) than *PTEN* protein loss (64%, $p=0.0004$). Endometrioid tumors had a significantly higher proportion of *PTEN* sequence abnormalities and *PTEN* protein loss than non-endometrioid tumors. Within the latter group, *PTEN* sequence abnormalities and *PTEN* protein loss were most frequent in undifferentiated carcinomas, followed by mixed carcinomas; they were least frequent in carcinosarcomas. Overall, at least one *PTEN* sequence abnormality was detected in each exon, and the greatest number of sequence abnormalities was detected in exon 8. Pure endometrioid tumors had a significantly higher frequency of sequence abnormalities in exon 7 than did the non-endometrioid tumors ($p=0.0199$). Importantly, no mutational hotspots were identified. While *PTEN* protein loss by immunohistochemistry was identified in 89% of cases with a *PTEN* sequence abnormality, *PTEN* protein loss was detected by immunohistochemistry in 44% of cases

Users may view, print, copy, download and text and data-mine the content in such documents, for the purposes of academic research, subject always to the full Conditions of use: http://www.nature.com/authors/editorial_policies/license.html#terms

Corresponding Author: Russell R. Broaddus, MD, PhD Department of Pathology, Unit 85 University of Texas M. D. Anderson Cancer Center 1515 Holcombe Blvd Houston, TX 77030 Phone: 713-745-2794 rbroaddus@mdanderson.org.

²Current address: Department of Pathology and Laboratory Medicine, University of Ottawa, The Ottawa Hospital, Ottawa, Ontario, Canada

⁴Current Address: Department of Medical Oncology, Beaumont Hospital and Royal College of Surgeons in Ireland, Dublin, Ireland

Conflict of Interest: The authors report no conflict of interest.

classified as *PTEN* wildtype by sequencing. For the first time, we demonstrate that *PTEN* immunohistochemistry is able to identify the majority of cases with functional *PTEN* loss. However, *PTEN* immunohistochemistry also detects additional cases with *PTEN* protein loss that would otherwise be undetected by gene sequencing. Therefore, for clinical purposes, immunohistochemistry appears to be a preferable technique for identifying endometrial tumors with loss of *PTEN* function.

Introduction

The (phosphatase and tensin homolog) *PTEN* gene is located at chromosome 10q23.31. The *PTEN* protein plays a crucial role in the control of the PI3K -AKT pathway through dephosphorylation of PIP3 at the cell membrane. Absence of functional *PTEN* protein leads to unopposed action of PI3K with resultant uncontrolled PIP3 production. One major effector of the PI3K -AKT pathway is mTOR, which stimulates protein synthesis, initiates entry into G1 phase of the cell cycle and interacts with proteins that regulate apoptosis (1). Loss of *PTEN* function has been implicated in the pathogenesis of a number of different tumors, particularly endometrial cancer. Functional *PTEN* loss can result from somatic mutations, abnormalities in *PTEN* transcriptional and post-transcriptional regulation, microRNAs, regulation of microRNAs by a *PTEN* pseudogene, or regulation of *PTEN* protein stability and degradation mechanisms (2). Somatic *PTEN* mutations have been detected in 34–55% of endometrial cancers (3, 4), particularly in the endometrioid histotype.

Accurate identification of functional *PTEN* loss is an integral part of a comprehensive evaluation of tumors with potential abnormalities in the PI3K -AKT pathway, particularly as targeted therapeutics against the pathway are entering trials and the clinic. Studies have shown that different types of PIK3CA (the catalytic subunit of PI3K) isoform derangements are required in combination with *PTEN* abnormalities to achieve upregulation of the PI3K -AKT pathway (5, 6). Even in tumors in which this pathway may not be the primary driver of cell proliferation, the PI3K -AKT pathway has been shown to be activated in a compensatory fashion in the setting of treatment with anti-receptor tyrosine kinase agents (2), prompting the need for therapies that target more than one signal transduction pathway. Currently, numerous clinical trials with PI3K, AKT and mTOR inhibitors are underway (<http://www.ClinicalTrials.gov>), several specifically involving endometrial cancer (7).

Previously reported *PTEN* gene sequence abnormalities are highly variable in type (frameshifts, point mutations) and can occur throughout all 9 exons (3, 4, 8). Therefore, to date, Sanger sequencing has been considered to be the gold standard for detection of *PTEN* mutations and subsequent loss of *PTEN* protein function. From a clinical perspective, the problems with this sequencing approach include high cost, labor-intensiveness, and failure to identify *PTEN* protein loss via epigenetic mechanisms. Alternative methods, such as immunohistochemistry, may be the preferred method of assessing functional *PTEN* loss in patient tumors. However, until recently, *PTEN* immunohistochemistry has been considered somewhat unreliable. In a tissue microarray study of four different antibodies (9), only results using antibody 6H2.1 have been shown to have a statistically significant correlation with pAKT (activated form of AKT). Stemming from historical difficulties in *PTEN*

antibody performance, there has been no uniform scoring system for PTEN immunohistochemistry. Furthermore, direct head-to-head comparisons of PTEN immunohistochemistry and *PTEN* sequence analysis to date have been very limited. In one study of endometrial tumors, PTEN immunohistochemistry and *PTEN* sequence analysis were carried out, but each technique was applied to a different set of tumors (10). Another study of histologically normal endometrium has shown that normal endometrial glands with loss of PTEN protein expression by immunohistochemistry do have *PTEN* mutations (11).

The objective of our study was to perform a direct comparison of PTEN immunohistochemistry and *PTEN* gene sequencing on a large group of endometrial carcinomas to determine which method is clinically preferable for identifying PTEN loss. This first necessitated that we establish a PTEN immunohistochemistry scoring system that can be applied clinically. The large cohort of both endometrioid and non-endometrioid endometrial carcinomas used has been carefully characterized as to tumor grade and histotype. Given that PTEN loss can occur through a variety of mechanisms in addition to mutations, we hypothesized that immunohistochemistry would outperform the sequencing analysis as a clinically applicable method to detect PTEN loss in endometrial carcinomas.

Materials and Methods

Case Selection

One hundred fifty-four consecutive cases of endometrial carcinoma with available fresh frozen tissue and formalin fixed, paraffin embedded tissue were retrieved from the tumor bank of the University of Texas M.D. Anderson Cancer Center Department of Pathology under the auspices of an institutional review board-approved protocol. By histotype, the study cohort was composed of 100 pure endometrioid carcinomas (6 FIGO grade 1, 78 FIGO grade 2, and 16 FIGO grade 3) and 54 non-endometrioid carcinomas consisting of 13 carcinosarcomas, 10 undifferentiated carcinomas, 4 clear cell carcinomas, 1 serous carcinoma, and 26 mixed carcinomas. Mixed carcinomas were designated as tumors with an endometrioid component and any amount of at least one other non-endometrioid histotype, including clear cell carcinoma, serous carcinoma, undifferentiated carcinoma, carcinoma with sarcomatoid features or carcinoma with neuroendocrine features. Among the 26 mixed endometrial carcinomas, 19 had a minor component of serous carcinoma. There is limited experience regarding the nature of mixed endometrial carcinomas composed of endometrioid and non-endometrioid components. The most studied combination has been that of endometrioid and serous histotypes. While the majority of studies have shown that the behavior of these tumors is similar to that of pure serous carcinoma, the cut-offs for the relative amount of serous carcinoma in a mixed tumor have been quite varied, ranging from 50% (12), 25% (13, 14) to <10% (15, 16). Similarly, a few studies have shown that clear cell carcinoma in combination with endometrioid carcinoma confers a poor outcome (16, 17).

Sequencing Analysis

Genomic DNA was isolated from fresh frozen tumors using standard methods. Bidirectional sequencing of PTEN exons 1–8 was performed at the Human Genome Sequencing Center at

Baylor College of Medicine using intron-based, exon-specific primers. PCR reactions were performed in 8 μ l containing 10 ng of genomic DNA, 0.4 μ M oligonucleotide primers, and 0.7 \times Qiagen[®] PCR HotStar Taq Master Mix containing buffer and polymerase. Cycling parameters were 95 $^{\circ}$ – 15 minutes, then 95 $^{\circ}$ – 45 seconds, 60 $^{\circ}$ – 45 seconds, and 72 $^{\circ}$ – 45 seconds for 40 cycles followed by a final extension at 72 $^{\circ}$ for 7 minutes. After thermocycling, 5 μ l of a 1:15 dilution of Exo-SAP was added to each well and reactions incubated at 37 $^{\circ}$ C for 15 minutes prior to inactivation at 80 $^{\circ}$ for 15 minutes. Reactions were diluted by 0.6 \times and 2 μ l were combined with 5 μ l of 1/64th Applied Biosystems[®] (AB) BigDye[™] sequencing reaction mix and cycled as above for 25 cycles. Reactions were precipitated with ethanol, re-suspended in 0.1 mM EDTA and loaded on AB 3730XL sequencing instruments using the Rapid36 run module and 3xx base-caller. SNPs were identified using SNP Detector software. Identified mutations were verified by bidirectional re-sequencing of the original DNA sample. Sequencing of exon 9 for all tumors was performed at the University of Texas M.D. Anderson Cancer Center Molecular Diagnostics Laboratory. Two μ l of DNA were used to amplify exon 9 of *PTEN* using M13-tagged published primers. Reaction mixtures of 50 μ L contained 1 mM dNTPs, 2.5 mM MgCl₂, 0.2 uM primers, 1.5 U Ampli-Taq Gold 360 Polymerase (Applied Biosystems) were amplified with the following PCR conditions: an initial 10-minute activation at 95 $^{\circ}$ C followed by 40 cycles of 30 seconds at 95 $^{\circ}$ C; 30 seconds at 50 $^{\circ}$ C; 30 seconds at 72 $^{\circ}$ C, and a final extension of 10 minutes at 72 $^{\circ}$ C. PCR products were purified (Agencourt Ampure, Beckman Coulter) prior to being loaded on an ethidium bromide-stained agarose gel. Fluorescent-based automated cycle sequencing was performed by the dye-terminator method using a multi-capillary sequencer (ABI 3130 Genetic Analyzer; PE Applied Biosystems) according to manufacturer's protocol (BigDye Terminator v1.1 Ready Reaction Cycle Sequencing Kit; PE Applied Biosystems). Briefly, reaction tubes (total volume 20 μ L) containing 100 ng of the purified PCR product, 3.2 pmol of either the sense or antisense M13 primer and 6 μ L of the sequencing mixture were placed in a DNA thermal cycler and cycled for 25 cycles at 96 $^{\circ}$ C for 10 seconds, 58 $^{\circ}$ C for 5 seconds, 60 $^{\circ}$ C for 4 minutes, and final hold at 4 $^{\circ}$ C. Sequencing reactions were purified using the Qiagen DyeEx[™] purification kit (Qiagen) as per manufacturer's protocol. The resulting data were analyzed by Seqscape software (PE Applied Biosystems).

Immunohistochemistry

Immunohistochemistry was performed on 4 μ m sections of formalin fixed, paraffin embedded tumors. Following deparaffinization and rehydration of the tissues sections, antigen retrieval was performed at 100 $^{\circ}$ C for 20 minutes with Tris-EDTA buffer, pH 6.0 (*PTEN*) or using microwave treatment in 10 mM citrate buffer, pH 6 (pS6). Endogenous peroxidase was blocked with 3% peroxide for 5 minutes. Primary *PTEN* antibody (Dako, clone 6H2.1) was applied at 1:100 dilution. Primary phospho-S6 Ribosomal Protein (Ser235/236) antibody (Cell Signaling) was applied at 1:50 dilution. Primary antibody detection was carried out using a polymer system (Bond Polymer Refine Detection, Leica). Staining development was achieved by incubation with DAB and DAB Enhancer (Leica for *PTEN*; Dako for pS6). The *PTEN* antibody was validated using nude mouse xenografts of a breast carcinoma cell line with a known *PTEN* mutation and xenografts of a breast cancer cell line with wild type *PTEN*.

PTEN immunohistochemistry was scored by two different pathologists (BD and RB) as positive, negative and heterogeneous. In all cases, stromal cells and blood vessels had intensely positive expression for PTEN and thus served as integral internal positive controls. Tumors considered positive showed diffuse positive cytoplasmic and nuclear staining in the majority (>90%) of cells (Figure 1A). Positive staining in tumor cells was comparable to that detected in normal stromal cells. Tumors with no or only rare cells staining (<1%) were considered negative for PTEN (Figure 1B). For all negative cases, the presence of positive staining stromal cells confirmed that the immunohistochemistry reaction was working. Tumors with distinctive positive and negative staining foci were designated as having a heterogeneous staining pattern (Figure 1C). pS6 immunohistochemistry was scored as a percentage of tumor cells with positive cytoplasmic expression.

Statistical Analysis

Statistical analyses were performed using SPSS 17.0 (Chicago, IL). Statistical comparisons were carried out using the Fisher's exact test. A p-value of <0.05 was considered statistically significant.

Results

An overview of *PTEN* sequencing and PTEN immunohistochemistry results is summarized in Table 1. More detailed sequencing (Tables 2 and 3) and immunohistochemistry (Tables 4, 5 and 6) data are provided in subsequent tables. As shown in Table 1, more endometrial carcinomas had loss of PTEN protein detected by immunohistochemistry (64%) than had a *PTEN* sequence abnormality (43%; $p=0.0004$). Endometrioid tumors had a significantly higher proportion of *PTEN* sequence abnormalities (51%) and PTEN protein loss by immunohistochemistry (75%) than non-endometrioid tumors (28% for sequencing, $p=0.0064$; 43% for immunohistochemistry, $p=0.0001$). Grade of endometrioid tumor did not significantly correlate with the likelihood of a *PTEN* sequence abnormality or PTEN protein loss being detected. Undifferentiated endometrial carcinomas have been previously shown to have a prognosis significantly worse than that of grade 3 endometrioid endometrial carcinoma (18). However, based on *PTEN* sequencing and PTEN immunohistochemistry, the undifferentiated tumors are more comparable to the endometrioid tumors (Table 1). The undifferentiated tumors had a significantly higher proportion of cases with PTEN sequence abnormality (60%) compared to the remainder of the cases in the non-endometrioid group (20%, $p=0.0199$). Also, undifferentiated tumors had a significantly higher proportion of cases with PTEN protein loss (80%) compared to the remainder of the cases in the non-endometrioid group (20%, $p=0.0125$). Carcinosarcomas are known to have an aggressive clinical course, similar to that of uterine serous carcinoma. The carcinosarcomas had a notably lower proportion of cases with *PTEN* sequence abnormality (8%) than the remainder of the cases in the non-endometrioid group (34%, $p=0.0830$) and a significantly lower proportion of cases with PTEN protein loss (15%) compared to the remainder of the cases in the non-endometrioid group (51%, $p=0.0277$) (Table 1). Of the 13 carcinosarcoma cases, a PTEN mutation was detected in only one case. This case was scored as heterogeneous by immunohistochemistry. Mixed endometrioid-non-endometrioid tumors had a lower proportion of *PTEN* sequence abnormalities (31%) than pure endometrioid tumors (51%, $p=$

0.0794) and also a significantly lower proportion of PTEN protein loss (42%) than pure endometrioid tumors (75%, $p=0.0037$).

PTEN sequencing revealed a wide variety of different sequence abnormalities detected (Table 2). Endometrioid tumors had a comparatively higher proportion of missense mutations ($p=0.0088$) and frameshift deletions ($p=0.0606$) than the non-endometrioid tumors. The non-endometrioid tumors did not have any significant association with any particular *PTEN* sequence abnormality. Endometrioid tumors and non-endometrioid tumors had a comparable average number of *PTEN* sequence abnormalities per case (1.4 and 1.3, respectively). From a total of 89 *PTEN* sequence abnormalities, only 6 (6.7%) were homozygous, while the remainder was hemizygous.

Table 3 summarizes the *PTEN* sequence abnormalities by exon for the endometrioid and nonendometrioid carcinomas. Overall, at least one *PTEN* sequence abnormality was detected in each exon, and the greatest number of sequence abnormalities was detected in exon 8. Endometrioid tumors had a significantly higher frequency of sequence abnormalities in exon 7 than did the non-endometrioid tumors ($p=0.0199$). The presence of sequence aberrations across all exons highlights the impracticality of focused sequencing efforts on just one or a few exons to evaluate tumors clinically.

Table 4 summarizes the results of 3-tiered PTEN immunohistochemistry scoring in the endometrioid and non-endometrioid carcinomas. More PTEN positive cases were observed in the non-endometrioid group. The percentages of endometrioid and non-endometrioid tumors with the heterogeneous pattern were comparable (18% and 17%, respectively). A significantly greater percentage of cases with immunohistochemical PTEN loss (negative and heterogeneous scored cases combined) was detected in endometrioid carcinomas (75%) compared to the non-endometrioid carcinomas (43%; $p=0.0001$).

We observed two general patterns of heterogeneous PTEN expression; a geographic pattern containing large and well demarcated positive and negative areas (Figure 2, A and B), and a focal pattern, where the majority of the tumor is PTEN negative, with focal, less well-demarcated areas of positive staining (Figure 2, C and D). The nature of the PTEN immunohistochemistry heterogeneous cases is uncertain. A trivial explanation for this group is that it represents uneven immunohistochemical staining in tumor sections that may not have undergone optimal histological processing. There are several arguments against this explanation, however. One, in these heterogeneous cases, we uniformly observed very strong, positive PTEN immunohistochemical expression in adjacent stromal cells and blood vessels. Second, collaborators at Memorial Sloan-Kettering Cancer Center have observed an identical staining pattern when using the same PTEN antibody (19). Finally, activation of the PI3K-AKT pathway, such as occurs with PTEN protein loss, results in elevated levels of pS6 (20). Accordingly, the PTEN negative tumors had significantly higher pS6 scores compared to the PTEN positive tumors ($p=0.037$) (Figure 3). Endometrial carcinomas with a heterogeneous PTEN immunohistochemistry staining pattern have an intermediate level of pS6 compared to PTEN positive and negative tumors (Figure 3). pS6 immunohistochemistry scores in relation to PTEN immunohistochemistry and *PTEN* sequence abnormalities are presented in Table 5. The mean pS6 immunohistochemistry score was comparable between

the groups which had no *PTEN* sequence abnormalities (mean = 46.7%) compared to the group in which *PTEN* sequence abnormalities were detected (mean = 36.0%). Note that in both the *PTEN* mutant and *PTEN* wild-type groups, mean pS6 is highest in the tumors with negative PTEN immunohistochemistry.

Table 6 provides a direct comparison of immunohistochemistry and sequencing. In 89% of the cases with a detected *PTEN* sequence abnormality, PTEN protein loss was identified by immunohistochemistry (22% heterogeneous and 67% negative). However, the absence of a *PTEN* sequence abnormality was corroborated by positive expression of PTEN by immunohistochemistry in only 56% of cases. In other words, in 44% of the tumors in which no *PTEN* sequence abnormality was detected, immunohistochemistry identified partial (14% heterogeneous scored cases) or complete (30% negative scored cases) PTEN protein loss. Thus, when compared head-to-head, immunohistochemistry identifies more endometrial carcinomas with PTEN loss, and this correlates with pathway activation, at least as indicated by pS6 staining.

Discussion

Endometrial cancer is the most prevalent malignancy of the gynecologic tract in the developed world. While patients with early stage disease and tumors of endometrioid histotype tend to have a good prognosis, patients with non-endometrioid tumors or recurrent endometrioid tumors do not respond well to conventional chemotherapy and have poor outcomes. The PI3K-AKT pathway is frequently activated in endometrial carcinoma, often in part due to functional PTEN loss. Therefore, accurate identification of this aberration is an important component of patient triage and selection in order to achieve optimal therapeutic benefit from targeted agents. Given the limited life expectancy of endometrial cancer patients being considered for targeted therapies, the laboratory tools used to gauge potential eligibility of targeted therapy must therefore be not only accurate, but inexpensive and accessible, as well as simple, reproducible, and able to be performed in a narrow time window.

Other key components of the PI3K-AKT pathway, such as AKT (21) or PI3K (22, 23), are altered primarily by mutation, resulting in pathway activation. In contrast, loss of PTEN may be due to gene mutations, gene methylation (24, 25), and a variety of other causes including abnormalities in *PTEN* post-transcriptional regulation, actions of micro RNAs, as well as due to aberrant mechanisms of PTEN protein stability and degradation (2). While immunohistochemistry would seem to be the best method to assess functional PTEN loss in endometrial tumors, it has historically been considered as having somewhat poor reproducibility (26–33). This has, in large part, been due to inconsistent performance of one PTEN antibody compared to another, as well as the variation of scoring systems between studies. However, we have recently shown that the 3-tiered PTEN immunohistochemical scoring system summarized in this study is highly reproducible (19) and that PTEN immunohistochemistry scores are concordant with reverse phase protein lysate array results in 93% of cases (23). In the current study, 64% of all endometrial carcinomas had PTEN protein loss demonstrated by immunohistochemistry. In comparison, *AKT* mutations have been identified in only 2%–4% of endometrial carcinomas (21, 34), and *PIK3CA* mutations

in 24–52% of endometrioid endometrial tumors (22, 35, 36) and 15%–33% non-endometrioid endometrial tumors (22, 37). Therefore, adding PTEN immunohistochemistry to the clinical evaluation of these tumors would allow for the identification of more endometrial cancer patients with activation of the PI3K-AKT pathway; importantly, these are patients who might be potentially responsive to treatment with PI3K pathway inhibitors. The importance of such accurate patient identification is underscored by the fact that it has recently been demonstrated that patients with advanced cancers with *PIK3CA* mutations have better response to pharmacological inhibitors of PI3K/AKT/mTOR(38).

There is presently no standardized system for PTEN immunohistochemistry interpretation. Some investigators have used the histologic score (H-score) (9), a complex semi-quantitative scoring method. We developed a scoring system that reflected the intrinsic nature of the staining patterns we were observing empirically with this antibody. Upon a thorough review of the literature, we found that one group (29, 30, 33) used a similar positive-negative-heterogeneous scoring system, although with a different PTEN antibody. Whereas the positive and negative PTEN immunohistochemistry categories are self-explanatory, the biological nature of the PTEN heterogeneous tumors is currently not known. There is no mouse model or cell line model that recapitulates this heterogeneous expression pattern. Whether this pattern is representative of subclones within the tumor or of differential post transcriptional regulation is not known. However, PTEN protein loss even in a portion of the tumor may mean that a patient could potentially derive some benefit from PI3K-AKT pathway inhibitors. Interestingly, in our study, the PTEN heterogeneous group had higher expression of pS6 than did the PTEN positive group (Figure 3). Future correlation with molecular analyses and clinical outcomes may help to clarify the significance of these results. It is also important to note that, while this simple scoring system seems appropriate for endometrial carcinoma, it may not be applicable to other tumors from other organ systems. Molecular regulation mechanisms of PTEN protein expression in other tissue types may be different from that in the endometrium, potentially resulting in different immunohistochemical staining patterns. Finally, our study highlights the importance of the use of whole tissue sections, rather than tissue microarrays, in evaluation of PTEN immunohistochemical expression. Cores in tissue microarrays may contain insufficient internal positive control stroma, and tissue microarray cores may be too small to capture both the positive and negative portions of the tumor, particularly in the case of geographic pattern of heterogeneous PTEN immunohistochemical expression (Figure 2, A and B).

While many studies in the past have examined either *PTEN* sequence abnormalities (3, 4, 8, 39) or PTEN expression by immunohistochemistry (26, 27, 29–33, 40), our study is the first to date to provide detailed information on the correlation of PTEN immunohistochemistry with *PTEN* sequence abnormalities and tumor histotype. In terms of correlation of the PTEN immunohistochemistry and *PTEN* sequence analysis results, both testing modalities detected significantly more frequent PTEN loss in endometrioid tumors relative to the non-endometrioid tumors (Table 1). However, for both the endometrioid and non-endometrioid groups, immunohistochemistry detected a substantially greater proportion of cases with PTEN loss than did the sequencing analysis. Overall, of the tumors in which *PTEN* sequence

abnormality was not detected, 44% had partial (heterogeneous score) or complete (negative score) PTEN loss by immunohistochemistry (Table 6). The prevalence of sequence abnormalities in our study (43%) is comparable to that of 34–55% in the published literature (3, 4). By histotype, we found that *PTEN* mutations occurred more frequently in endometrioid-type endometrial carcinomas (51%) compared to non-endometrioid carcinomas (28%). Similarly, Tashiro et al.(41) found *PTEN* mutations in 50% of the endometrioid subtype and no *PTEN* mutations in the serous subtype. Risinger et al. (42) identified *PTEN* mutations in 37% of endometrioid carcinomas and in only 5% of serous/clear cell endometrial carcinomas. Sun et al. (43) detected *PTEN* mutations in 26% of the endometrioid subtype and no *PTEN* mutations in the serous subtype. Finally, Rudd et al. (22) identified *PTEN* mutations in as many as 79% endometrioid carcinomas and 11% of non-endometrioid (serous and clear cell) carcinomas.

The PTEN status of non-endometrioid endometrial tumors such as undifferentiated carcinoma, carcinosarcoma, and mixed endometrial carcinomas has not been previously reported. It is interesting to note that mixed carcinomas (all of which had an endometrioid component) as a group contained a lower proportion of *PTEN* sequence abnormalities and PTEN protein loss relative to the pure-endometrioid group, but a higher proportion of the same relative to the remainder of cases in the non-endometrioid group. Undifferentiated carcinomas showed an even more dramatic rate of *PTEN* sequence abnormalities and PTEN protein loss compared to the other members of the non-endometrioid group. Therefore, while non-endometrioid tumors are generally thought of as having infrequent PTEN abnormalities, our results suggest that mixed endometrial carcinomas and undifferentiated endometrial carcinomas in particular should not be excluded from clinical testing for PTEN loss.

Of further interest is the fact that the vast majority (94%) of detected *PTEN* sequence abnormalities in our study were hemizygous and yet resulted in either partial or complete PTEN protein loss by immunohistochemistry. Similar observations have been made in other studies of endometrial cancer, as well as in hematologic malignancies (44) and breast cancer (45). A possible explanation for this is that sequence abnormalities alone do not account for all cases of PTEN protein loss in tumors. Rather, epigenetic mechanisms, such as promoter methylation, micro RNAs or increased protein degradation in the hemizygous state may also regulate PTEN expression. *PTEN* promoter methylation has been observed in approximately 19% of endometrial cancers (46). In addition, recent studies in non-small cell lung cancer (47) and hepatocellular carcinoma (48) have found that miRNA -21 post-transcriptionally down-regulates the expression of PTEN.

In summary, for the first time, we demonstrate a detailed correlation between *PTEN* sequencing abnormalities and PTEN immunohistochemistry. PTEN immunohistochemistry is able to identify the majority of cases with genetic PTEN loss *and* also detects additional cases with functional PTEN loss otherwise undetected by mutational analysis. In particular, mixed carcinomas and undifferentiated carcinomas have relatively frequent loss of PTEN. In addition, compared to *PTEN* full-length sequencing, PTEN immunohistochemistry is quicker, less costly and labor intensive and requires routinely obtained formalin-fixed, paraffin-embedded tissues. Finally, we propose a simple scoring system for PTEN

immunohistochemistry, which may act as a primer for correlating PTEN levels of expression in endometrial tumors with patient response to PI3K/AKT/mTOR inhibitors.

Acknowledgements

NIH 2P50 CA098258-06 SPORE in Uterine Cancer (RRB) and Stand Up to Cancer/American Association for Cancer Research Dream Team Translational Cancer Research Grant, Grant No. SU2C-AACR- DT0209 (RRB, BTH, and GBM), and M.D. Anderson Cancer Center Support Grant (CCSG) CA016672 from National Institutes of Health. This original research was presented in part at the 99th United States and Canadian Academy of Pathology Annual Meeting, March 20–26, 2010, Washington, DC. The authors also thank Michelle Hildebrandt, Ph.D., Department of Epidemiology, M.D. Anderson Cancer Center, for her helpful discussion regarding this manuscript and to Su-Su Xie, M.D., for technical assistance. Drs. Broaddus and Hennessy contributed equally to this work as senior authors.

References

1. Le Tourneau C, Faivre S, Serova M, Raymond E. mTORC1 inhibitors: is temsirolimus in renal cancer telling us how they really work? *Br J Cancer*. 2008; 99:1197–1203. [PubMed: 18797463]
2. Zhang S, Yu D. PI(3)king apart PTEN's role in cancer. *Clin Cancer Res*. 2010; 16:4325–4330. [PubMed: 20622047]
3. Risinger JI, Hayes AK, Berchuck A, Barrett JC. PTEN/MMAC1 mutations in endometrial cancers. *Cancer Res*. 1997; 57:4736–4738. [PubMed: 9354433]
4. Kong D, Suzuki A, Zou TT, et al. PTEN1 is frequently mutated in primary endometrial carcinomas. *Nat Genet*. 1997; 17:143–144. [PubMed: 9326929]
5. Wee S, Wiederschain D, Maira SM, et al. PTEN-deficient cancers depend on PIK3CB. *Proc Natl Acad Sci U S A*. 2008; 105:13057–13062. [PubMed: 18755892]
6. Torbett NE, Luna-Moran A, Knight ZA, et al. A chemical screen in diverse breast cancer cell lines reveals genetic enhancers and suppressors of sensitivity to PI3K isoform-selective inhibition. *Biochem J*. 2008; 415:97–110. [PubMed: 18498248]
7. Slomovitz BM, Lu KH, Johnston T, et al. A phase 2 study of the oral mammalian target of rapamycin inhibitor, everolimus, in patients with recurrent endometrial carcinoma. *Cancer*. 2010; 116:5415–5419. [PubMed: 20681032]
8. Bussaglia E, del Rio E, Matias-Guiu X, Prat J. PTEN mutations in endometrial carcinomas: a molecular and clinicopathologic analysis of 38 cases. *Hum Pathol*. 2000; 31:312–317. [PubMed: 10746673]
9. Pallares J, Bussaglia E, Martinez-Guitarte JL, et al. Immunohistochemical analysis of PTEN in endometrial carcinoma: a tissue microarray study with a comparison of four commercial antibodies in correlation with molecular abnormalities. *Mod Pathol*. 2005; 18:719–727. [PubMed: 15578076]
10. Mutter GL, Lin MC, Fitzgerald JT, et al. Altered PTEN expression as a diagnostic marker for the earliest endometrial precancers. *J Natl Cancer Inst*. 2000; 92:924–930. [PubMed: 10841828]
11. Mutter GL, Ince TA, Baak JP, et al. Molecular identification of latent precancers in histologically normal endometrium. *Cancer Res*. 2001; 61:4311–4314. [PubMed: 11389050]
12. Williams KE, Waters ED, Woolas RP, Hammond IG, McCartney AJ. Mixed serous-endometrioid carcinoma of the uterus: pathologic and cytopathologic analysis of a high-risk endometrial carcinoma. *Int J Gynecol Cancer*. 1994; 4:7–18. [PubMed: 11578379]
13. Sherman ME, Bitterman P, Rosenshein NB, Delgado G, Kurman RJ. Uterine serous carcinoma. A morphologically diverse neoplasm with unifying clinicopathologic features. *Am J Surg Pathol*. 1992; 16:600–610. [PubMed: 1599038]
14. Carcangiu ML, Chambers JT. Uterine papillary serous carcinoma: a study on 108 cases with emphasis on the prognostic significance of associated endometrioid carcinoma, absence of invasion, and concomitant ovarian carcinoma. *Gynecol Oncol*. 1992; 47:298–305. [PubMed: 1473741]
15. Lim P, Al Kushi A, Gilks B, Wong F, Aquino-Parsons C. Early stage uterine papillary serous carcinoma of the endometrium: effect of adjuvant whole abdominal radiotherapy and pathologic parameters on outcome. *Cancer*. 2001; 91:752–757. [PubMed: 11241243]

16. Quddus MR, Sung CJ, Zhang C, Lawrence WD. Minor serous and clear cell components adversely affect prognosis in “mixed-type” endometrial carcinomas: a clinicopathologic study of 36 stage-I cases. *Reprod Sci.* 2010; 17:673–678. [PubMed: 20393071]
17. Carcangiu ML, Chambers JT. Early pathologic stage clear cell carcinoma and uterine papillary serous carcinoma of the endometrium: comparison of clinicopathologic features and survival. *Int J Gynecol Pathol.* 1995; 14:30–38. [PubMed: 7883423]
18. Altrabulsi B, Malpica A, Deavers MT, et al. Undifferentiated carcinoma of the endometrium. *Am J Surg Pathol.* 2005; 29:1316–1321. [PubMed: 16160474]
19. Garg K, Broaddus RR, Soslow RA, et al. Pathologic Scoring of PTEN Immunohistochemistry in Endometrial Carcinoma is Highly Reproducible. *Int J Gynecol Pathol.* 2011 In Press.
20. McCampbell AS, Harris HA, Crabtree JS, et al. Loss of inhibitory insulin receptor substrate-1 phosphorylation is an early event in mammalian target of rapamycin-dependent endometrial hyperplasia and carcinoma. *Cancer Prev Res (Phila).* 2010; 3:290–300. [PubMed: 20179297]
21. Shoji K, Oda K, Nakagawa S, et al. The oncogenic mutation in the pleckstrin homology domain of AKT1 in endometrial carcinomas. *Br J Cancer.* 2009; 101:145–148. [PubMed: 19491896]
22. Rudd ML, Price JC, Fogoros S, et al. A unique spectrum of somatic PIK3CA (p110alpha) mutations within primary endometrial carcinomas. *Clin Cancer Res.* 2011; 17:1331–1340. [PubMed: 21266528]
23. Cheung LW, Hennessy BT, Li J, et al. High Frequency of PIK3R1 and PIK3R2 Mutations in Endometrial Cancer Elucidates a Novel Mechanism for Regulation of PTEN Protein Stability. *Cancer Discov.* 2011; 1:170–185. [PubMed: 21984976]
24. Salvesen HB, MacDonald N, Ryan A, et al. PTEN methylation is associated with advanced stage and microsatellite instability in endometrial carcinoma. *Int J Cancer.* 2001; 91:22–26. [PubMed: 11149415]
25. Goel A, Arnold CN, Niedzwiecki D, et al. Frequent inactivation of PTEN by promoter hypermethylation in microsatellite instability-high sporadic colorectal cancers. *Cancer Res.* 2004; 64:3014–3021. [PubMed: 15126336]
26. An HJ, Lee YH, Cho NH, et al. Alteration of PTEN expression in endometrial carcinoma is associated with down-regulation of cyclin-dependent kinase inhibitor, p27. *Histopathology.* 2002; 41:437–445. [PubMed: 12405911]
27. Sarmadi S, Izadi-Mood N, Sotoudeh K, Tavangar SM. Altered PTEN expression; a diagnostic marker for differentiating normal, hyperplastic and neoplastic endometrium. *Diagn Pathol.* 2009; 4:41. [PubMed: 19930726]
28. Gao Q, Ye F, Xia X, et al. Correlation between PTEN expression and PI3K/Akt signal pathway in endometrial carcinoma. *J Huazhong Univ Sci Technolog Med Sci.* 2009; 29:59–63. [PubMed: 19224164]
29. Uegaki K, Kanamori Y, Kigawa J, et al. PTEN-positive and phosphorylated-Akt-negative expression is a predictor of survival for patients with advanced endometrial carcinoma. *Oncol Rep.* 2005; 14:389–392. [PubMed: 16012720]
30. Kanamori Y, Kigawa J, Itamochi H, et al. PTEN expression is associated with prognosis for patients with advanced endometrial carcinoma undergoing postoperative chemotherapy. *Int J Cancer.* 2002; 100:686–689. [PubMed: 12209607]
31. Kapucuoglu N, Aktepe F, Kaya H, et al. Immunohistochemical expression of PTEN in normal, hyperplastic and malignant endometrium and its correlation with hormone receptors, bcl-2, bax, and apoptotic index. *Pathol Res Pract.* 2007; 203:153–162. [PubMed: 17317031]
32. Salvesen HB, Stefansson I, Kretzschmar EI, et al. Significance of PTEN alterations in endometrial carcinoma: a population-based study of mutations, promoter methylation and PTEN protein expression. *Int J Oncol.* 2004; 25:1615–1623. [PubMed: 15547698]
33. Terakawa N, Kanamori Y, Yoshida S. Loss of PTEN expression followed by Akt phosphorylation is a poor prognostic factor for patients with endometrial cancer. *Endocr Relat Cancer.* 2003; 10:203–208. [PubMed: 12790783]
34. Cohen Y, Shalmon B, Korach J, et al. AKT1 pleckstrin homology domain E17K activating mutation in endometrial carcinoma. *Gynecol Oncol.* 2010; 116:88–91. [PubMed: 19853286]

35. Velasco A, Bussaglia E, Pallares J, et al. PIK3CA gene mutations in endometrial carcinoma: correlation with PTEN and K-RAS alterations. *Hum Pathol.* 2006; 37:1465–1472. [PubMed: 16949921]
36. Hayes MP, Wang H, Espinal-Witter R, et al. PIK3CA and PTEN mutations in uterine endometrioid carcinoma and complex atypical hyperplasia. *Clin Cancer Res.* 2006; 12:5932–5935. [PubMed: 17062663]
37. Hayes MP, Douglas W, Ellenson LH. Molecular alterations of EGFR and PIK3CA in uterine serous carcinoma. *Gynecol Oncol.* 2009; 113:370–373. [PubMed: 19272638]
38. Janku F, Tsimberidou AM, Garrido-Laguna I, et al. PIK3CA mutations in patients with advanced cancers treated with PI3K/AKT/mTOR axis inhibitors. *Mol Cancer Ther.* 2011; 10:558–565. [PubMed: 21216929]
39. Minaguchi T, Yoshikawa H, Oda K, et al. PTEN mutation located only outside exons 5, 6, and 7 is an independent predictor of favorable survival in endometrial carcinomas. *Clin Cancer Res.* 2001; 7:2636–2642. [PubMed: 11555573]
40. Alkushi A, Kobel M, Kalloger SE, Gilks CB. High-grade endometrial carcinoma: serous and grade 3 endometrioid carcinomas have different immunophenotypes and outcomes. *Int J Gynecol Pathol.* 2010; 29:343–350. [PubMed: 20567148]
41. Tashiro H, Blazes MS, Wu R, et al. Mutations in PTEN are frequent in endometrial carcinoma but rare in other common gynecological malignancies. *Cancer Res.* 1997; 57:3935–3940. [PubMed: 9307275]
42. Risinger JI, Hayes K, Maxwell GL, et al. PTEN mutation in endometrial cancers is associated with favorable clinical and pathologic characteristics. *Clin Cancer Res.* 1998; 4:3005–3010. [PubMed: 9865913]
43. Sun H, Enomoto T, Fujita M, et al. Mutational analysis of the PTEN gene in endometrial carcinoma and hyperplasia. *Am J Clin Pathol.* 2001; 115:32–38. [PubMed: 11190805]
44. Dahia PL, Aguiar RC, Alberta J, et al. PTEN is inversely correlated with the cell survival factor Akt/PKB and is inactivated via multiple mechanisms in haematological malignancies. *Hum Mol Genet.* 1999; 8:185–193. [PubMed: 9931326]
45. Perren A, Weng LP, Boag AH, et al. Immunohistochemical evidence of loss of PTEN expression in primary ductal adenocarcinomas of the breast. *Am J Pathol.* 1999; 155:1253–1260. [PubMed: 10514407]
46. Salvesen HB, MacDonald N, Ryan A, et al. Methylation of hMLH1 in a population-based series of endometrial carcinomas. *Clin Cancer Res.* 2000; 6:3607–3613. [PubMed: 10999752]
47. Zhang JG, Wang JJ, Zhao F, et al. MicroRNA-21 (miR-21) represses tumor suppressor PTEN and promotes growth and invasion in non-small cell lung cancer (NSCLC). *Clin Chim Acta.* 411:846–852. [PubMed: 20223231]
48. Meng F, Henson R, Wehbe-Janek H, et al. MicroRNA-21 regulates expression of the PTEN tumor suppressor gene in human hepatocellular cancer. *Gastroenterology.* 2007; 133:647–658. [PubMed: 17681183]

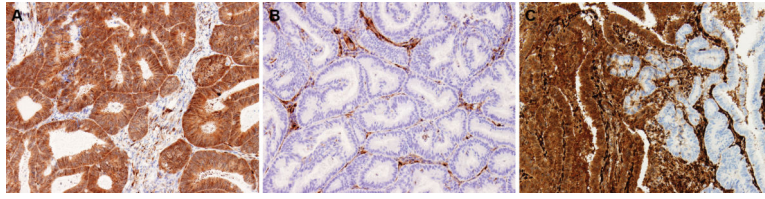


Figure 1.

(a) Positive immunohistochemistry for PTEN. Diffuse cytoplasmic staining is present in the majority (>90%) of tumor cells. (b) Negative immunohistochemistry for PTEN. No or only scattered tumor cells (<1%) have cytoplasmic staining. Note stromal cells serve as positive internal control. (c) Heterogeneous immunohistochemistry score for PTEN. Heterogeneous tumors have distinct positive and negative foci. All photomicrographs 20 \times .

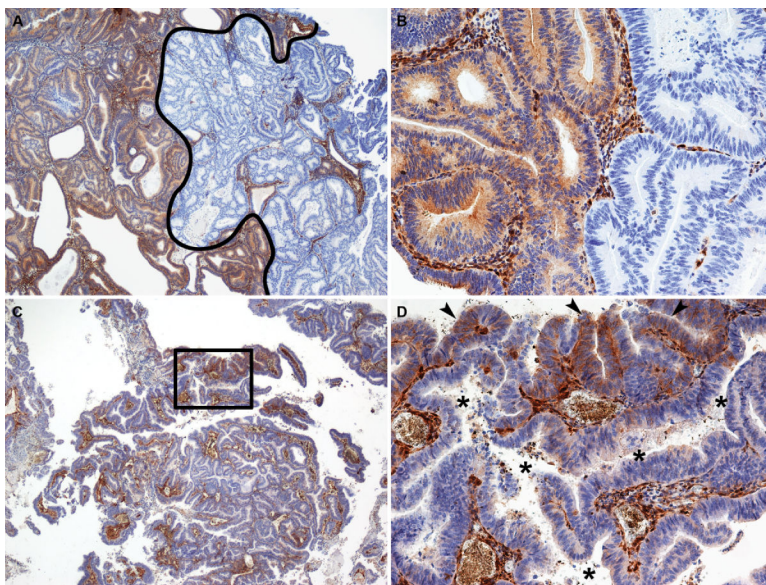


Figure 2. Representative photomicrographs of different patterns of PTEN heterogeneous immunohistochemistry. (A and B) Geographic pattern of PTEN heterogeneous immunohistochemical expression. In A, the portion of the tumor to the right of the black line represents a large area that is negative for PTEN immunohistochemistry, while the area to the left is positive for PTEN immunohistochemistry. A higher magnification of the positive-negative interface is shown in B. For the geographic pattern, the interface between the positive and negative areas is typically sharp and abrupt. (C and D) Focal pattern of PTEN heterogeneous immunohistochemical expression. In this case, the vast majority of the tumor is PTEN negative. D represents a higher magnification view of the area outlined by the rectangle in C. In D, it is clear that small foci of the tumor are immunohistochemically positive for PTEN (arrowheads), while a large, irregular malignant gland immediately adjacent is PTEN negative (asterisks in gland lumen). Note that in this pattern, the interface between PTEN positive and negative areas is more subtle. Note also that the intervening tumor stroma has uniformly strong PTEN staining throughout the tumor. A and C, 4 \times ; B and D, 20 \times .

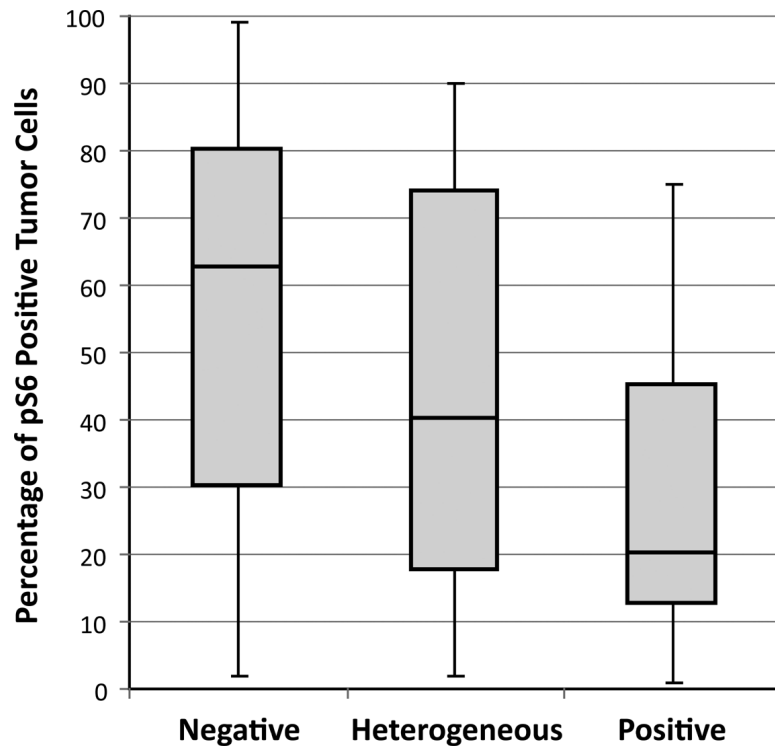


Figure 3. Percentage of immunopositive tumor cells for phosphorylated S6 in PTEN negative, heterogeneous, and positive groups. Rectangular bars represent the 25th, 50th (median), and 75th percentiles, while the whiskers represent the range. There was a significant ($p=0.037$) difference in the percentage of pS6 positive tumor cells between the PTEN negative and positive tumors.

Table 1

An overview of the relationship of *PTEN* sequencing results and *PTEN* status by immunohistochemistry according to histological tumor type and grade.

Tumor Histotype and Grade (n)	<i>PTEN</i> Sequence Abnormality Detected n(%)	<i>PTEN</i> Protein Loss by Immunohistochemistry n(%)¹
All cases (154)	66 (43%)	98 (64%)
Endometrioid (100)	51 (51%)	75 (75%)
Grade 1 (6)	2 (33%)	4 (67%)
Grade 2 (78)	38 (49%)	62 (79%)
Grade 3 (16)	11 (69%)	9 (56%)
Non-endometrioid (54)	15 (28%)	23 (43%)
Mixed (26)	8 (31%)	11 (42%)
Undifferentiated (10)	6 (60%)	8 (80%)
Carcinosarcoma (13)	1 (8%)	2 (15%)
Clear Cell (4)	0 (0%)	2 (50%)
Serous (1)	0 (0%)	0 (0%)

¹Immunohistochemical loss of *PTEN* protein included tumors scored as negative and heterogeneous.

Table 2

Detailed *PTEN* sequencing results according to tumor histological type.

Type of Sequence Abnormality	ENDOMETRIOID			NON-ENDOMETRIOID		
	¹ Number of sequence abnormalities	Sequence abnormality as a % of all cases (n=100)	Sequence abnormality as a % of the total number of sequence abnormalities detected (n=70)	² Number of sequence abnormalities	Sequence abnormality as a % of all non-endometrioid cases (n=54)	Sequence abnormality as a % of the total number of sequence abnormalities detected (n=19)
Insertions and deletions	32	32.0%	45.7%	10	18.5%	52.6%
4 amino acid deletion	1	1.0%	1.4%	0	0.0%	0.0%
1 amino acid deletion	1	1.0%	1.4%	0	0.0%	0.0%
Exon boundary, insertion	0	0.0%	0.0%	1	1.9%	5.3%
Exon boundary, deletions	1	1.0%	1.4%	0	0.0%	0.0%
Frameshift, insertion	9	9.0%	12.9%	5	9.3%	26.3%
³ Frameshift, deletion **	20	20.0%	28.6%	4	7.4%	21.1%
Point Mutations	38	38.0%	54.3%	9	16.7%	47.4%
³ Missense mutation *	25	25.0%	35.7%	4	7.4%	21.1%
Nonsense mutation	10	10.0%	14.3%	4	7.4%	21.1%
Splice region point mutation	2	2.0%	2.9%	1	1.9%	5.3%
Splice site point mutation	1	1.0%	1.4%	0	0.0%	0.0%
All sequence abnormalities	70	70.0%	100.0%	19	35.2%	100.0%

¹ 51 endometrioid tumors in the study had a total of 70 sequence abnormalities for an average of 1.4 sequence abnormalities per case.

² 15 non-endometrioid cases in the study had a total of 19 sequence abnormalities for an average of 1.3 sequence abnormalities per case.

³ Endometrioid tumors had a significantly higher frequency of

* missense mutations (p=0.0088) than the non-endometrioid tumors and showed a trend toward a higher frequency of

** frameshift deletions (p=0.0606).

Table 3

Summary of *P TEN* exon sequence abnormalities (insertions, deletions, and point mutations) and endometrial carcinoma type.

	ENDOMETRIOID				NON-ENDOMETRIOID				
	All Sequence Abnormalities Detected n(%) [/]	Insertions and deletions	Point Mutations	All Sequence Abnormalities Detected n(%) [/]	Insertions and deletions	Point Mutations	All Sequence Abnormalities Detected n(%) [/]	Insertions and deletions	Point Mutations
Exon 1	9 (12.9%)	5	4	5 (26.3%)	2	3			
Exon 2	2 (2.9%)	0	2	0 (0%)	0	0			
Exon 3	2 (2.9%)	0	2	0 (0%)	0	0			
Exon 4	1 (1.4%)	0	1	1 (5.3%)	1	0			
Exon 5	12 (17.1%)	4	8	4 (21.1%)	1	3			
Exon 6	10 (14.3%)	5	5	0 (0%)	0	0			
Exon 7	14 (20.0%)	10	4	1 (5.3%)	1	0			
Exon 8	16 (22.9%)	7	9	5 (26.3%)	3	2			
Exon 9	0 (0%)	0	0	1 (5.3%)	1	0			
Exon 3 boundary	1 (1.4%)	1	0	0 (0%)	0	0			
Exon 8 boundary	0 (0%)	0	0	1 (5.3%)	1	0			
Splice region 6/7	2 (2.9%)	0	2	1 (5.3%)	0	1			
Splice region 7/8	1 (1.4%)	0	1	0 (0%)	0	0			
All	70	32	38	19	10	9			

[/] Exon 7 sequence abnormalities were significantly more common in endometrioid carcinomas compared to the non-endometrioid group (p=0.0199).

Table 4

Relationship between PTEN immunohistochemistry and tumor histology.

Immunohistochemistry Score	Endometrioid n (%)	Non-Endometrioid n (%)
Positive	25 (25%)	31 (57%)
Loss	75 (75%)	23 (43%)
Heterogeneous	18 (18%)	9 (17%)
Negative	57 (57%)	14 (26%)
All Cases	100	54

Author Manuscript

Author Manuscript

Author Manuscript

Author Manuscript

Table 5

Mean percentage of tumor cells positive for pS6 in relation to PTEN immunohistochemistry (IHC) and sequencing results

	PTEN IHC Positive	PTEN IHC Heterogeneous	PTEN IHC Negative	All cases
<i>PTEN</i> Sequence Abnormality Detected	15%	18.5%	45.8%	36.0%
<i>PTEN</i> Sequence Abnormality Not Detected	31.5%	46.2%	55.0%	46.7%
All cases	30.4%	34.3%	51.3%	42.9%

Author Manuscript

Author Manuscript

Author Manuscript

Author Manuscript

Table 6Relationship between PTEN immunohistochemistry and *PTEN* sequencing.

Immunohistochemistry Score	Sequence Abnormality Detected n (%)	Sequence Abnormality Not Detected n (%)
Positive	7 (11%)	49 (56%)
Loss	59 (89%)	39 (44%)
Heterogeneous	15 (22%)	12 (14%)
Negative	44 (67%)	27 (30%)
All Cases	66	88

Author Manuscript

Author Manuscript

Author Manuscript

Author Manuscript