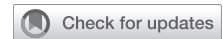

Simplifying the autograft and homograft: The inverted-graft mattress technique



Stephen M. Spindel, MD,^a Antonio Polanco, MD,^b Jasmine Su, BS,^c Reginald E. Du, MD,^a and Autumn P. Stevenson, MD,^a New Orleans, La; Baltimore, Md; and Amherst, Mass

From the ^aSection of Cardiothoracic Surgery, Department of Surgery, Ochsner Medical Center, New Orleans, La; ^bDivision of Cardiac Surgery, The Johns Hopkins University, Baltimore, Md; and ^cThe University of Massachusetts, Amherst, Mass.

Received for publication Aug 9, 2023; revisions received Sept 19, 2023; accepted for publication Sept 20, 2023; available ahead of print Oct 4, 2023.

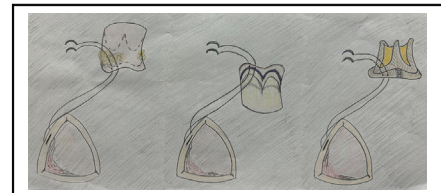
Address for reprints: Stephen M. Spindel, MD, Section of Cardiothoracic Surgery, Ochsner Medical Center, 1514 Jefferson Highway, New Orleans, LA 70121 (E-mail: stephenspindel123@gmail.com).

JTCVS Techniques 2023;22:187-8

2666-2507

Copyright © 2023 The Author(s). Published by Elsevier Inc. on behalf of The American Association for Thoracic Surgery. This is an open access article under the CC BY-NC-ND license (<http://creativecommons.org/licenses/by-nc-nd/4.0/>).

<https://doi.org/10.1016/j.xjtc.2023.09.025>



The inverted-graft mattress technique for simplifying autograft and homograft surgery.

CENTRAL MESSAGE

The inverted-graft mattress technique demonstrated in this video simplifies the graft–LVOT anastomosis segment of pulmonary autograft and aortic homograft root replacements.

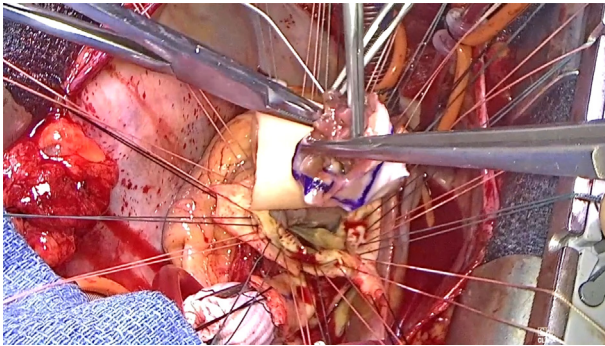
▶ Video clip is available online.

Evidence suggests pulmonary autograft and aortic homograft have good long-term survival, excellent hemodynamics, and may offer improved outcomes compared with biological and mechanical prostheses.¹⁻³ However, pulmonary autograft and aortic homograft represent <0.1% of aortic valve replacements (AVRs), with most of these performed at high-volume centers.¹ Its limited use can be attributed to the technical complexity, potentially increased operative risk, and lack of surgeon experience.¹ During the left ventricular outflow tract (LVOT)

anastomosis, the pliant pulmonary autograft and aortic homograft, hereon referred to as the “graft,” obstruct visualization of suture placement. We demonstrate an adoptable framework, the inverted-graft mattress technique, that transforms the challenging LVOT anastomosis into one familiar with most cardiac surgeons. Institutional review board approval was not required. Informed written consent was obtained to include patient information in the included video.

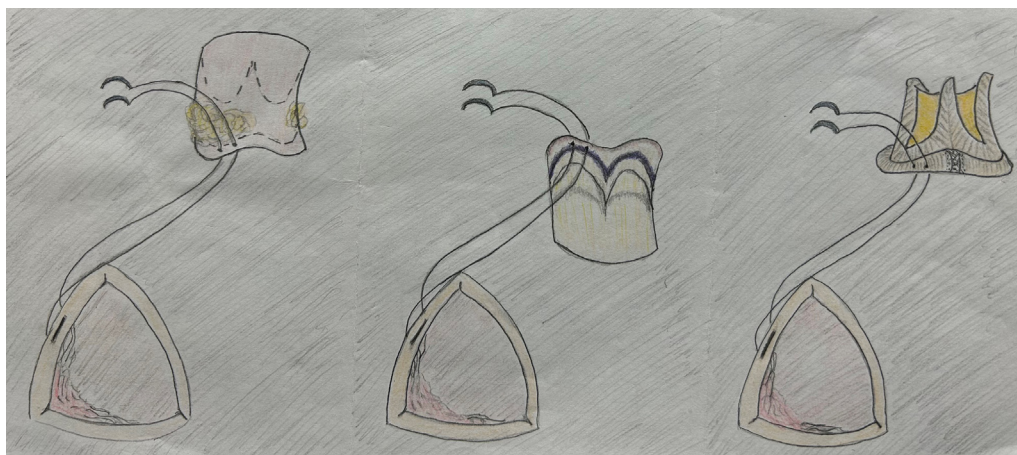

FIGURE 1. Envisioning the LVOT anastomosis with the autograft or homograft as a standard bioprosthetic aortic valve replacement.



VIDEO 1. Intraoperative video illustrating the inverted-graft mattress technique to simplify a pulmonary autograft or aortic homograft root replacement. Video available at: [https://www.jtcvs.org/article/S2666-2507\(23\)00372-3/fulltext](https://www.jtcvs.org/article/S2666-2507(23)00372-3/fulltext).

We envision the graft–LVOT anastomosis as a standard AVR with a biological or mechanical prosthesis (Figure 1). Video 1 illustrates the steps providing excellent exposure of the graft annulus, regarding it as a sewing cuff akin to a prosthetic valve. First, invert the graft, bringing the leaflets and annulus to the outside. Mark the annulus, creating a “safe zone” for suture placement. The result is a configuration comparable to the sewing cuff of a prosthetic valve.

Suture placement mirrors a standard AVR with first placing the LVOT sutures, then placing these into the sewing cuff. The framework for the “sewing cuff” is created by the 3 commissural sutures being placed first through the graft for suspension. The remaining LVOT sutures are now passed through the graft “sewing cuff.” The graft is parachuted and the sutures tied. Considerations include

alternating colored polyethylene sutures in the LVOT for improved organization and marking the left coronary ostium in the aortic homograft for assistance with graft orientation. Importantly, note the pulmonary autograft does not sit within the LVOT, and its annulus lacks basal support. Therefore, one should strongly consider using an external ring annuloplasty (prosthetic graft or felt) in the autograft to prevent annular dilatation.

This standardized AVR framework simplifies the graft–LVOT anastomosis. We believe this technique offers improved organization and enhances surgical precision, making pulmonary autograft and aortic homograft root replacement a more accessible option for all cardiac surgeons.

Conflict of Interest Statement

The authors reported no conflicts of interest.

The *Journal* policy requires editors and reviewers to disclose conflicts of interest and to decline handling or reviewing manuscripts for which they may have a conflict of interest. The editors and reviewers of this article have no conflicts of interest.

References

1. Mazine A, El-Hamamsy I, Verma S, Peterson MD, Bonow RO, Yacoub MH, et al. Ross procedure in adults for cardiologists and cardiac surgeons: JACC State-of-the-Art Review. *J Am Coll Cardiol*. 2018;72:2761-77. <https://doi.org/10.1016/j.jacc.2018.08.2200>
2. El-Hamamsy I, Toyoda N, Itagaki S, Stelzer P, Varghese R, Williams EE, et al. Propensity-matched comparison of the ross procedure and prosthetic aortic valve replacement in adults. *J Am Coll Cardiol*. 2022;79:805-15. <https://doi.org/10.1016/j.jacc.2021.11.057>
3. Yazdchi F, Harloff M, Hirji S, Percy E, McGurk S, Cherkasky O, et al. Long-term outcomes of aortic valve replacement with aortic homograft: 27 years experience. *Ann Thorac Surg*. 2021;112:1929-38. <https://doi.org/10.1016/j.athoracsur.2020.12.030>