

# Lower endoscopic ultrasound in preoperative evaluation of rectosigmoid endometriosis



## Authors

Theodore W. James<sup>1</sup>, Y. Claire Fan<sup>2</sup>, Lauren D. Schiff<sup>3</sup>, Lisa M. Gangarosa<sup>1</sup>

## Institutions

- 1 Division of Gastroenterology and Hepatology, University of North Carolina, Chapel Hill, North Carolina, United States
- 2 Department of Medicine, University of North Carolina, Chapel Hill, North Carolina, United States
- 3 Department of Obstetrics and Gynecology, University of North Carolina, Chapel Hill, North Carolina, United States

submitted 18.1.2019

accepted after revision 1.4.2019

## Bibliography

DOI <https://doi.org/10.1055/a-0901-7259> |

Endoscopy International Open 2019; 07: E837–E840

© Georg Thieme Verlag KG Stuttgart · New York

eISSN 2196-9736

## Corresponding author

Theodore W. James, MD, Division of Gastroenterology and Hepatology, University of North Carolina, Chapel Hill, 130 Mason Farm Road, CB 7080, Chapel Hill, NC 27599  
 Fax: +1-919-966-7047  
 ted@unc.edu

## ABSTRACT

**Background and study aims** Endometriosis affects a significant proportion of reproductive-aged women and involves the bowel in up to one-third of patients with the con-

dition. Lower endoscopic ultrasound (LEUS) in assessment of endometriosis of the rectosigmoid colon was first described 20 years ago in European populations. The current study aimed to describe the diagnostic characteristics of this imaging modality at a tertiary US referral center in a large cohort and its impact on surgical planning.

**Patients and methods** This was a retrospective cohort study of adult women evaluated for rectosigmoid endometriosis by LEUS at an American tertiary referral center between January 2003 through June 2017. The reference standard for rectosigmoid endometriosis was surgical evaluation regardless of whether tissue was obtained for histologic evaluation. Two separate analyses were run; one comparing EUS to laparoscopic findings and another comparing EUS to histologic findings.

**Results** LEUS demonstrated a positive predictive value (PPV) of 93.8% (CI:68.1,99.1) and negative predictive value (NPV) of 96.4% (CI:87.8,99.0) in the diagnosis of rectosigmoid endometriosis. Test sensitivity was 88.2% (CI:63.6,98.5) and specificity was 98.2% (CI:90.1,99.9). Overall diagnostic accuracy of the test was 95.8% (CI:88.1,99.1).

**Conclusions** In this large cohort of women at an American tertiary referral center undergoing evaluation for rectosigmoid endometriosis, LEUS demonstrated high PPV and NPV as well as excellent diagnostic accuracy. In addition, the LEUS findings provided important information to the referring gynecologic surgeon. This minimally-invasive imaging modality should be utilized in preoperative evaluation of women undergoing surgery for suspected or known endometriosis.

## Introduction

Endometriosis affects 5% to 15% of reproductive-aged women; [1] within this population, bowel endometriosis affects between 3.8% and 37% of women [2]. Endometrial implants involving the bowel occur most commonly in the sigmoid colon and rectum, followed by the ileum, appendix and cecum [3]. Symptoms associated with rectosigmoid endometriosis may include dyschezia, constipation, diarrhea, abdominal bloating and cyclical rectal bleeding [4]. These symptoms may mimic or

overlap with symptoms of irritable bowel syndrome, making diagnosis of rectosigmoid endometriosis challenging [5]

Lower endoscopic ultrasound (LEUS) has been employed in preoperative evaluation of patients with suspected endometriosis of the rectosigmoid colon since the late 1990s [6, 7]. Preoperative diagnosis of rectosigmoid endometriosis may assist with operative planning and lead to involvement of a bowel surgeon in addition to the primary gynecologic surgeon. Previous studies have reported positive and negative predictive values for LEUS in diagnosis of rectosigmoid endometriosis as high as

86.8% and 97.7%, respectively [8–10], but have not described how this affected preoperative planning. In addition, no large American series has been reported.

The current study aimed to describe endosonographic, surgical, and histologic findings in patients referred for evaluation of rectosigmoid endometriosis via LEUS and to report the diagnostic sensitivity, specificity, positive predictive values (PPV) and negative predictive values (NPV) as well as to assess the impact of findings of LEUS on surgical planning at a tertiary American referral center.

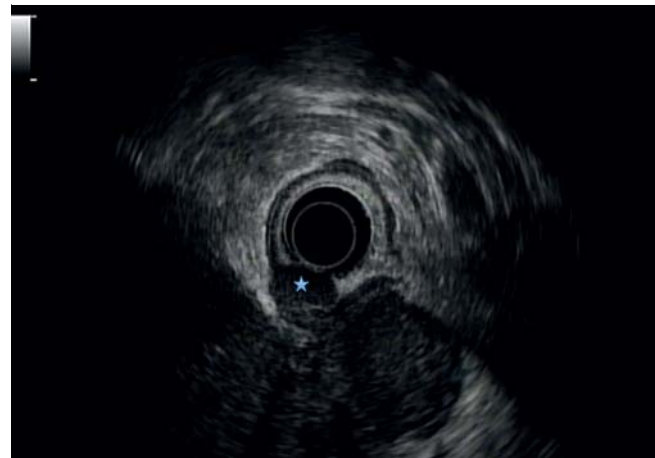
## Patients and methods

All adult women (age  $\geq 18$  years) evaluated for rectosigmoid endometriosis by LEUS at our tertiary referral center between January 2003 through June 2017 were identified. The study design was evaluated and exempted by the local Institutional Review Board. In all instances, the patients were referred by their gynecologist. All procedures were performed by or under the supervision of one of two experienced attending endosonographers utilizing Olympus Radial Array (GF-UE160-AL5) endosonoscopes. Gastroenterology trainees were involved in some of the cases. All procedures were performed under moderate or deep sedation following a standard polyethylene glycol 3350-based oral preparation. Clinical and procedural data were collected, including patient-reported symptoms, physical exam findings, prior imaging and endoscopic data, LEUS findings, surgical and histologic findings as well as surgical interventions, when available. An endometrial implant into the rectosigmoid was diagnosed on LEUS by a hypoechoic or heterogeneous intramural lesion, usually irregularly shaped and within the bowel wall (► Fig. 1) [11]. Fine-needle aspiration (FNA) at the time of LEUS was not performed in this population. Adverse events (AE) were graded according to the American Society for Gastrointestinal Endoscopy lexicon [12].

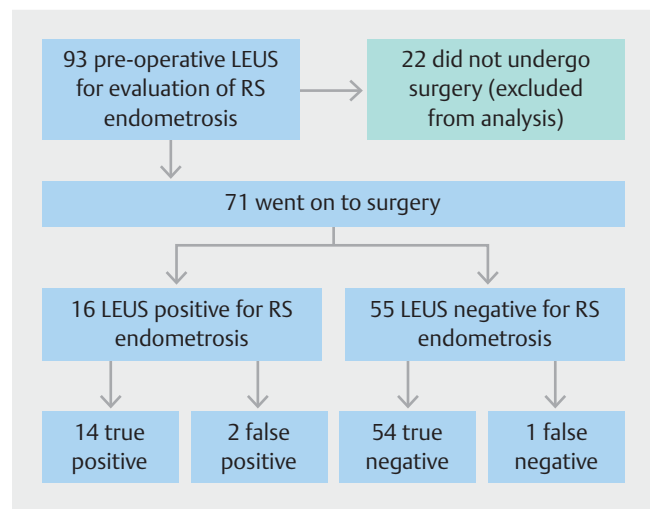
Statistical analyses were performed using Stata version 15.1 (StataCorp, Texas, United States). All continuous variables are expressed as mean  $\pm$  standard deviation, and skewed variables are expressed as median and interquartile range. Categorical variables are expressed as proportions (%). A  $P$  value  $<0.05$  was considered statistically significant. Two separate analyses were run; one comparing LEUS to laparoscopic findings and another comparing LEUS to histologic findings. The reference standard for rectosigmoid endometriosis was laparoscopic evaluation regardless of whether tissue was obtained for histologic evaluation.

## Results

Ninety-three patients underwent LEUS for evaluation of rectosigmoid endometriosis during the study period and of them, 71 went on to have operative evaluation and were analyzed (► Fig. 2). Mean age in this cohort was 34.0 years (SD  $\pm$  6.3); 57 patients (80.3%) had a prior diagnosis of endometriosis and 53 patients (74.6%) had previously undergone surgery for endometriosis. Sixty-three patients (88.7%) had lower gastrointestinal symptoms, with the most common being dyschezia.



► Fig. 1 Lower endoscopic ultrasound demonstrating deep pelvic endometriosis involving the rectum. Note the characteristic hypoechoic appearance of the mass contiguous with muscularis propria (see star).



► Fig. 2 Schema of analysis and results. LEUS, lower endoscopic ultrasound; RS, rectosigmoid.

Prior imaging studies were available in our medical records system for 34 patients (47.9%), with transvaginal ultrasound as the dominant modality (23 patients). Eight patients (11.3%) had prior lower endoscopic examination without use of ultrasound; only one patient had findings concerning for endometriosis due to external compression of the colon. One severe AE (perforation) occurred during the study period in a patient with a history of partial colectomy and colonic stricture, which was managed surgically with a favorable clinical outcome; there were no other AEs. Patient demographic data are presented in ► Table 1.

Of the 71 patients analyzed, ectopic endometrial tissue was found on laparoscopic evaluation in 51 (71.8%) with rectosigmoid endometriosis diagnosed intraoperatively in 15 of these patients. Sixty-three patients (88.7%) had intraoperative histologic specimens collected, with 17 patients undergoing biopsy

► **Table 1** Patient demographic data.

Patients evaluated for RS Endometriosis by LEUS (n = 71)	
Mean age, y (SD)	34 (± 6.3)
Prior diagnosis of endometriosis, n (%)	57 (80.3%)
History of surgery for endometriosis, n (%)	53 (74.6%)
Presence of gastrointestinal symptoms, n (%)	63 (88.7%)
Prior imaging to evaluate for endometriosis, n (%)	34 (47.9%)
CT, n	6
Transvaginal ultrasound, n	23
MRI, n	3
Other, n	2
Prior lower endoscopy, other than LEUS, n (%)	8 (11.3%)

RS, rectosigmoid; CT, computed tomography; MR, magnetic resonance imaging; LEUS, lower endoscopic ultrasound.

of suspected rectosigmoid endometrial implants; histology confirmed a diagnosis of rectosigmoid endometriosis in 14 of these 17 patients (82.4%). Sixteen patients (22.5%) had evidence of rectosigmoid endometriosis on preoperative LEUS and diagnosis was laparoscopically confirmed in 14 of 16. In the two false-positive cases, a dedicated bowel surgeon was present during the case and pronounced a lack of involvement in the rectosigmoid colon. On LEUS, endometrial tissue was diagnosed in the rectum (13 patients) and rectosigmoid junction (3 patients), with depth of invasion of muscularis propria (13 patients), submucosa (1 patient) and serosa (2 patients).

Fourteen patients had a resection of the involved bowel, with a dedicated colorectal surgeon (10 cases) or gynecologic oncologist (4 cases) involved in all cases. In 13 of 14 cases of bowel resection, the preoperative LEUS had been positive. Preoperative LEUS was negative in 55 patients with 54 patients confirmed negative at the time of surgery. In the case of the false-negative LEUS, a bowel surgeon was consulted intraoperatively once rectosigmoid involvement was discovered.

The overall diagnostic accuracy of LEUS compared to operative findings was 95.8% (CI: 88.1, 99.1), which was comparable to the concordance between LEUS and histologic findings at 95.0%. When compared to intraoperative laparoscopic visual evaluation, LEUS demonstrated a PPV of 87.5% (CI: 64.1, 96.5) and a NPV of 98.2% (CI: 89.0, 99.7). Sensitivity was 93.3% (CI: 68.1, 99.8) and specificity was 96.4% (CI: 87.7, 99.6). Test characteristics are presented in ► **Table 2**. Intraoperative visual assessment for rectosigmoid endometriosis correlated closely with histologic confirmation of the diagnosis with an overall accuracy of 98.3% (CI: 91.1, 99.9), and NPV and sensitivity were 100% in our cohort. Lower gastrointestinal symptoms had an accuracy of 26.8% when compared to laparoscopic diagnosis of rectosigmoid endometriosis.

► **Table 2** Comparison of LEUS and operative findings.

	Laparoscopy positive	Laparoscopy negative	Total
LEUS Positive	14	2	16
LEUS Negative	1	54	55
Total	15	56	71

Positive predictive value: 87.5% (CI: 64.1, 96.5), negative predictive value: 98.2% (CI: 89.0, 99.7), sensitivity: 93.3% (CI: 68.1, 99.8), specificity: 96.4% (CI: 87.7, 99.6).  
LEUS: Lower endoscopic ultrasound.

## Discussion

Endometriosis that involves the rectosigmoid colon can be challenging to manage and, in many cases, requires operative intervention to control the symptoms and improve patients' quality of life. Preoperative diagnosis is of paramount importance to inform surgical planning and coordination of care, including the decision to involve an experienced bowel surgeon. Imaging modalities used to investigate presence of rectosigmoid endometriosis include LEUS, transvaginal ultrasound, contrast-enhanced computed tomography, and pelvic magnetic resonance imaging (MRI).

Pelvic MRI is in use at many centers in preoperative assessment of endometriosis, however, our experience with LEUS in diagnosis of rectosigmoid endometriosis demonstrates that it outperforms MRI. In the current study of a large American cohort, LEUS was found to have a high accuracy and a NPV of 98.2% compared to MRI which has a PPV of 84% to 91.2% and a NPV of 64.1% to 84% [13–16]. In addition, the Centers for Medicaid and Medicare Services Physician Fee Schedule lists the professional charge for an MRI of the pelvis with and without contrast as \$434.52 in February of 2018 [17]. This is in contrast to \$179.64 for LEUS within this database during the same period. As the practice of medicine in the United States begins to focus on value-based care, LEUS should be considered as an imaging modality for conditions involving the rectum and sigmoid colon such as endometriosis.

In our cohort, lower gastrointestinal symptoms correlated poorly with presence of histologically confirmed rectosigmoid endometriosis. This may be due to the non-specific nature of these symptoms and the high prevalence of irritable bowel syndrome in the general public, with particularly increased prevalence among women with endometriosis [18]. Because of the non-specific nature of lower gastrointestinal symptoms, they cannot be relied upon without additional imaging to assess for endometriosis involving the rectosigmoid colon.

Rectosigmoid resection carries notable risks distinct from gynecologic surgery and necessitates additional preoperative discussion and planning, with consideration of involving an experienced bowel surgeon. As rectosigmoid endometriosis is seen in stage IV disease, it is common to find additional extensive abdominopelvic endometriosis, which requires substantial operating block times for both the gynecologic and colorectal

components of the surgery. For this reason, high confidence about presence or absence of rectosigmoid endometriosis is essential to efficient surgeon and operating room management.

Limitations to the current study include a single-center experience with two endosonographers included. Further, only patients that went on to have laparoscopic evaluation were included in the analysis. This is a well-known source of selection bias in clinical research as patients who undergo surgery often have more advanced and, therefore, symptomatic disease [19]. This has been shown to overestimate the positive predictive value of preoperative diagnostic tests [20]. While this is a limitation, patients undergoing LEUS for evaluation of rectosigmoid endometriosis may have a high pre-test probability, making exclusion of non-operative patients acceptable. In our cohort, the majority (76.3%) went on to surgical evaluation.

## Conclusion

In conclusion, LEUS is a reliable, minimally invasive imaging modality for evaluation of rectosigmoid endometriosis with high PPV and NPV. It offers an excellent diagnostic profile, a favorable side-effect profile, and is cost-effective. In patients where there is concern for rectosigmoid endometriosis, preoperative assessment by LEUS should be considered to assist in operative planning. This planning may include ensuring appropriate equipment and staff are present as well as the decision to involve a colorectal or appropriately trained bowel surgeon if a bowel resection is anticipated.

## Acknowledgement

Dr. James receives research and training support through a grant from the NIH (T32DK007634).

## Competing interests

None

## References

- [1] Chapron C, Fauconnier A, Dubuisson JB et al. Deep infiltrating endometriosis: Relation between severity of dysmenorrhoea and extent of disease. *Hum Reprod* 2003; 18: 760–766
- [2] Parasar P, Ozcan P, Terry KL. Endometriosis: epidemiology, diagnosis and clinical management. *Curr Obstet Gynecol Rep* 2017; 6: 34–41
- [3] Remorgida V, Ferrero S, Fulcheri E et al. Bowel endometriosis: Presentation, diagnosis, and treatment. *Obstet Gynecol Surv* 2007; 62: 461–470
- [4] Seracchioli R, Mabrouk M, Guerrini M et al. Dyschezia and posterior deep infiltrating endometriosis: analysis of 360 cases. *J Minim Invasive Gynecol* 2008; 15: 695–699
- [5] Ferrero S, Camerini G, Ragni N et al. Endometriosis and irritable bowel syndrome: Co-morbidity or misdiagnosis? *BJOG An Int J Obstet Gynaecol* 2009; 116: 129
- [6] Schröder J, Löhnert M, Doniec JM et al. Endoluminal ultrasound diagnosis and operative management of rectal endometriosis. *Dis Colon Rectum* 1997; 40: 614–617
- [7] Chapron C, Dumontier I, Dousset B et al. Results and role of rectal endoscopic ultrasonography for patients with deep pelvic endometriosis. *Hum Reprod* 1998; 13: 2266–2270
- [8] Roseau G, Dumontier I, Palazzo L et al. Rectosigmoid endometriosis: Endoscopic ultrasound features and clinical implications. *Endoscopy* 2000; 32: 525–530
- [9] Rossi L, Palazzo L, Yazbeck C et al. Can rectal endoscopic sonography be used to predict infiltration depth in patients with deep infiltrating endometriosis of the rectum? *Ultrasound Obstet Gynecol* 2014; 43: 322–327
- [10] Gauche CC, Koskas M, Martin B et al. Preoperative imaging of deeply infiltrating endometriosis in: Transvaginal sonography, rectal endoscopic sonography and magnetic resonance imaging. *Gynecol Obstet Fertil* 2012; 40: 634–641
- [11] Koga K, Osuga Y, Yano T et al. Characteristic images of deeply infiltrating rectosigmoid endometriosis on transvaginal and transrectal ultrasonography. *Hum Reprod* 2003; 18: 1328–1333
- [12] Cotton PB, Eisen GM, Aabakken L et al. A lexicon for endoscopic adverse events: report of an ASGE workshop. *Gastrointest Endosc* 2010; 71: 446–454
- [13] Bazot M, Lafont C, Rouzier R et al. Diagnostic accuracy of physical examination, transvaginal sonography, rectal endoscopic sonography, and magnetic resonance imaging to diagnose deep infiltrating endometriosis. *Fertil Steril* 2009; 92: 1825–1833
- [14] Chapron C, Vieira M, Chopin N et al. Accuracy of rectal endoscopic ultrasonography and magnetic resonance imaging in the diagnosis of rectal involvement for patients presenting with deeply infiltrating endometriosis. *Ultrasound Obstet Gynecol* 2004; 24: 175–179
- [15] Alborzi S, Rasekhi A, Shomali Z et al. Diagnostic accuracy of magnetic resonance imaging, transvaginal, and transrectal ultrasonography in deep infiltrating endometriosis. *Medicine* 2018; 97
- [16] Scardapane A, Lorusso F, Bettocchi S et al. Deep pelvic endometriosis: accuracy of pelvic MRI completed by MR colonography. *La Radiol Med* 2013; 118: 323–338
- [17] Centers for Medicare & Medicaid Services. Physician Fee Schedule. 2018: Available at <https://www.cms.gov/apps/physician-fee-schedule/>
- [18] Ballard K, Lane H, Hudelist G et al. Can specific pain symptoms help in the diagnosis of endometriosis? A cohort study of women with chronic pelvic pain *Fertil Steril* 2010; 94: 20–27
- [19] Melton LJ. Selection bias in the referral of patients and the natural history of surgical conditions. *Mayo Clin Proc* 1985; 60: 880–885
- [20] Hegedus EJ, Moody J. Clinimetrics corner: the many faces of selection bias. *J Man Manip Ther* 2010; 18: 69–73