

Synergistic effects of Combined Therapy: nonfocused ultrasound plus Aussie current for noninvasive body contouring

Vivianne Carvalho Canela¹
Cynthia Nicoletti Crivelaro¹
Luciane Zacchi Ferla¹
Gisele Marques Pelozo¹
Juliana Azevedo²
Richard Eloin Liebano³
Caroline Nogueira^{4,5}
Renata Michelini Guidi^{4,5}
Clóvis Grecco⁴
Estela Sant'Ana⁴

¹Ibramed Center for Education and Advanced Training (CEFAL), Amparo, SP, Brazil; ²CDE Medical Imaging Department, Brazilian College of Radiology (CBR), Amparo, SP, Brazil; ³Department of Physiotherapy, Federal University of São Carlos (UFSCar), São Carlos, SP, Brazil; ⁴Research, Development and Innovation Department, Ibramed Research Group (IRG), IBRAMED, Amparo, SP, Brazil; ⁵Biomedical Engineering Department, Faculty of Electrical Engineering and Computing, University of Campinas (UNICAMP), Campinas, SP, Brazil

Correspondence: Estela Sant'Ana
Research, Development and Innovation
Department IBRAMED, Av Dr Carlos
Burgos, 2800 – Jd. Itália CEP, Amparo,
Sao Paulo 13901-080, Brazil
Tel +55 193 817 9633
Fax +55 193 817 9634
Email profa_estelasantana@yahoo.com.br

Background and objectives: Nowadays, there are several noninvasive technologies being used for improving of body contouring. The objectives of this pilot study were to verify the effectiveness of the Heccus[®] device, emphasizing the synergism between nonfocused ultrasound plus Aussie current in the improvement of body contour, and to determine if the association of this therapy with whole-body vibration exercises can have additional positive effects in the results of the treatments.

Subjects and methods: Twenty healthy women aged 20–40 years participated in the study. Ten patients received Combined Therapy treatment (G1) and the other 10 participants received Combined Therapy with additional vibratory platform treatment (G2). Anthropometric and standardized photography analysis, ultrasonography, cutometry and self-administered questionnaires of tolerance and satisfaction levels with the treatment were used.

Results: Compared with baseline values, reduction of fat thickness was observed by ultrasonography in the posterior thigh area in the G1 group ($P<0.05$) and in the buttocks ($P<0.05$) and the posterior thigh areas ($P<0.05$) in the G2. All the treated areas in both groups showed reduction in cellulite degree in the buttocks, G1 ($P<0.05$) and G2 ($P<0.05$), and in posterior thigh areas, G1 ($P<0.05$) and G2 ($P<0.05$). Optimal improvement of skin firmness (G1, $P<0.0001$; G2, $P=0.0034$) in the treated areas was observed in both groups.

Conclusion: We conclude that the synergistic effects of the Combined Therapy (nonfocused ultrasound plus Aussie current) might be a good option with noninvasive body contouring treatment for improving the aspect of the cellulite, skin firmness and localized fat. If used in association with the whole-body vibratory platform, the results can be better, especially in the treatment of localized fat. Further studies with larger sample size should be performed to confirm these results.

Keywords: cellulite, therapeutic ultrasound, skin tightening, localized fat, flaccid skin, therapeutic current

Introduction

Cellulite, localized fat deposits and skin flaccidity are common complaints in esthetic medicine clinics. Cellulite is the noninflammatory pathology of the subcutaneous tissue affecting over 80% of postpubertal females, and it is frequently localized on the thigh and buttock regions characterized by the “orange peel” appearance. It is frequently associated with localized fat deposits and flaccid skin, influenced by female sex hormones, and the localized fat in these areas is metabolically more stable and resistant to lipolysis.^{1–3}

Nowadays, there are several noninvasive and minimally invasive technologies to improve the appearance of skin and subcutaneous fat, such as radiofrequency,

cryolipolysis, manual massage, carboxytherapy and high-intensity focused ultrasound, among others.⁴⁻⁷

Nonfocused ultrasound and electrical stimulation are therapeutic modalities commonly used in physiotherapy practice and, when used simultaneously, they are called Combined Therapy. The combination of electrical stimulation and ultrasound can be more effective than each of them used separately.⁸⁻¹⁰ The main justification for Combined Therapy is that the beneficial effects of the two modalities can be achieved at the same time, and studies suggest that there may be an amplifying effect of one therapy over the other.^{10,11} A second justification is the efficiency in terms of time spent by the therapist and the patient.^{10,11} Therapeutic ultrasound is characterized by mechanical vibrations of high frequency – above 20 kHz – and it can be a potent modality to promote biological effects.^{12,13}

In therapeutic applications, the ultrasonic energy is characterized by intensity (W/cm^2) and frequency in kilohertz (kHz) or megahertz (MHz).^{12,14} Medium-frequency alternating currents, defined as currents in the frequency range from 1 to 10 kHz, are used extensively in rehabilitation.^{15,16} Among them, the Aussie current has been considered more comfortable and effective.¹⁷ This current is characterized by an alternating medium frequency wave modulated in low frequency, and it can be indicated for various purposes, including muscle strengthening, pain control, circulation promotion and edema control.^{18,19} Usually, esthetic treatments can be positively associated with physical activity. There is some evidence that the use of the long-term whole-body vibration platform technique can have positive effects on the muscular performance of the leg among untrained people and elderly women.²⁰

We hypothesize that the Combined Therapy, nonfocused ultrasound plus Aussie current, may improve body contouring simultaneously treating cellulite, skin flaccidity and localized fat. The objectives of this study were to verify the effectiveness of the Heccus[®] device, emphasizing the effects of Combined Therapy, and to determine if the association of this therapy with whole-body vibration exercises can have additional positive effects in the results of the treatments.

Subjects and methods

Subjects

This study included 20 healthy women aged between 20 and 40 years and with the cellulite diagnosis of grade ≥ 2 according to Nürnberger and Müller's classification.²¹ Subjects were recruited through word of mouth. The investigator examined the subjects and marked the treatment area which included the

gluteous area and posterior thighs. All the participants underwent anthropometric measurements, circumference measurements, skin firmness measurement and measurements of the thickness of the fat layer. All measurement readings were taken by a trained physiotherapist blind to the group interventions. Each subject was evaluated by the same physiotherapist at each visit. The assessments were carried out in the Center for Education and Advanced Training (CEFAI) clinic before and 15 days after the last session of treatment. Patient inclusion criteria were the presence of clinically appreciable skin laxity, localized subcutaneous fat and cellulite in the buttocks and posterior thighs area, and also, a body mass index (BMI) ≥ 30 kg/m^2 . Volunteers were excluded if they had undergone some kind of treatment in the gluteal region and thighs for up to 6 months before the start of this study; if they were pregnant or had been pregnant recently (< 6 months); if they had cardiovascular problems, metabolic disorders, respiratory disorders, immunosuppression, kidney and/or liver failure and skin lesions in the treatment area; or if they had diabetes mellitus. This study was approved by the Research Ethics Committee: União das Instituições de Serviço, Ensino e Pesquisa – UNISEPE (CAAE: 01386312.0.0000.5490), and all subjects signed an informed consent document. The treatment was performed in the Clinical Laboratory of the Ibramed Center for Education and Advanced Training (CEFAI) (Amparo, Sao Paulo, Brazil). This is a nonrandomized clinical trial and was performed in two cities from São Paulo state, Brazil. Participants from city 1 (Itapira) were allocated to G1 ($n=10$) and received Combined Therapy. Participants from city 2 (Jacutinga) were allocated to G2 ($n=10$) and received Combined Therapy with additional vibratory platform treatment. All volunteers were given directions about the treatment steps and procedures to be performed.

Treatment protocol

Both groups (G1 and G2) were treated with Heccus (Ibramed Indústria Brasileira de Equipamentos Médicos EIRELI, Amparo, Sao Paulo, Brazil), a device that uses a combination of electrical stimulation (Aussie current, high-voltage pulsed current or polarized current) and ultrasound (1 or 3 MHz), with the intensity ranging between 0.1 and 3.0 W/cm^2 . The protocol used was continuous ultrasound (3 MHz; 2 W/cm^2) plus Aussie current (4 kHz; modulated in 10 Hz; with an intensity of 40–60 mA, enough to produce a strong, but comfortable paresthesia). The device was previously calibrated by the manufacturer, and the treatment time was calculated as described by Watson⁹ and ranged from 30 to 60 min per session, which was variable according to the area

size, allowing at least 1 min of treatment time for each area of 1 cm². In other words, the area to be treated was divided by the effective radiation area, and the result was considered as the treatment time. The treatment was applied on the buttocks and the posterior thigh areas bilaterally. Ultrasound gel (RMC, Amparo, Sao Paulo, Brazil) was first applied and the transducer was used over the target area with a constant pressure. The session of the G2 was associated with 10 min of the vibratory platform Kikos p204I® (WKS Fitness e Serviços Técnicos LTDA – ME, Sao Paulo, Brazil). The volunteers stood on the platform, with upright spine and semi-flexed knees. The frequency used was 10 Hz and the treatment time was divided in two periods of 5 min with 2 min of interval between each activity. All the volunteers received 10 sessions of treatment, twice a week for 5 weeks. Prior to the start of the treatment, a clinical evaluation was performed, which was considered as baseline and was later compared to evaluations collected 15 days after the last treatment session.

Anthropometric measurements

In assessing the weight and height, the volunteers wore only underwear and did not wear shoes. A classical mechanical stadiometer (model 110 CH; Welmy, Santa Bárbara D'Oeste, Brazil) was used. The BMI was evaluated by applying the formula $BMI = \text{weight in kilograms} / \text{square of the height in meters (kg/m}^2\text{)}$.²² The circumference of treated areas was evaluated using a flexible tape measure. The buttocks were measured considering the upper point of the curve of the hip. Each measurement point was recorded at baseline to ensure that subsequent measurements were obtained at the same location.

Ultrasound analysis

All the volunteers participating in the study underwent diagnostic ultrasound that was performed at baseline and 15 days after the proposed treatment using a linear transducer (frequency 6–18 MHz; MyLab™ 25 Gold; Esaote, Genova, Italy), and VPan software (Esaote) was used for the construction of panoramic images. All panoramic images were taken in the standing position. The probe was slipped at a slow and regular speed in the distal/proximal direction, with coupling gel, along the areas without compressing the tissue. Panoramic images were analyzed quantitatively by measuring the subcutaneous tissue between anatomic planes (dermis and muscular fascia and the thickness of fat at the treatment site was measured using the measurement tool on the ultrasound machine). Qualitative analysis considering the hyperechoic areas was also performed to evaluate the severity of cellulite. Bright

echoes represent highly reflective structures (white = dermis and fibrotic septa) and hypoechoic areas are represented by sparse echoes, reflection or intermediate transmission (gray = adipose tissue and skeletal muscle). Fat layer thickness was measured in three points per image from the dermis–fat interface down to the deep fat–muscle fascia interface in the posterior thighs and the buttocks areas. Measurements were made by a single trained physiotherapist. For the analysis of cellulite, an independent radiologist conducted a blind analysis of all ultrasonography images 15 days after the last session of treatment and it was compared to baseline. The criterion of comparison was the condition of the improvement of cellulite when a hyperechoic decrease was demonstrated in the areas of fibrous connective tissue septa.²³

Skin viscoelasticity measurements

A Cutometer® MPA 580 (Courage & Khazaka GmbH, Köln, Germany) was used to assess skin firmness on the areas at baseline and 15 days after the final treatment. The resistance of the skin to the negative pressure and its ability to return to its original position was evaluated. Before each set of measurements, volunteers were required to equilibrate in a closed environment with a constant temperature (20°C±2°C) and humidity (55%–65% relative humidity). A probe of 2 mm hole was used, and the parameters selected were as follows: measurement mode 1, pressure of 450 mbar, on time of 5 s and off time of 3 s and the measurements were performed in triplicate. A single investigator (a trained physiotherapist) blinded to participants' group allocation performed all measurements. Analyses of the biomechanical characteristics of the skin were performed in sequence, and the variable analyzed was parameter R0 that corresponds to the distensibility/firmness of skin.^{24,25}

Standardized photographs

Standardized digital photographs were taken with a digital camera (Canon EOS Rebel T3i; Canon USA Inc., Melville, NY, USA) at baseline and 15 days after the proposed treatment. All patients were photographed in standing position in three views. The focus of the image was in the gluteal cleft with a focal length of 1 m, and the muscles of the photographed areas were relaxed. The images were offered to independent evaluators together with the criteria for the verification of the aspect of cellulite severity. Nürnberger and Müller describe different degrees or stages of severity based on clinical presentation from 0 to 3 as follows: 0=there is no alteration of the skin surface (visible without changes); 1=the skin of the affected area is smooth while the subject

is standing or lying, but the alterations to the skin surface can be seen by pinching the skin or with muscle contraction (visible changes with skin clamping or muscle contraction); 2=the orange peel aspect of the skin or mattress appearance is evident when standing, without the use of any manipulation of the skin pinching or muscle contraction (visible without manipulation) and 3=the alterations described in grade or stage 2 are present together with raised areas and nodules (visible changes associated with nodules).^{21,23}

Questionnaires

The results were also assessed subjectively by the patients who completed a self-questionnaire that assessed the tolerability and satisfaction with the treatment during the re-evaluation. Volunteers ticked their sensory referential as to the tolerance level, considering 1- intolerable, 2- tolerable, 3- comfortable, 4- very comfortable and their satisfaction level regarding the treatment being 1- dissatisfied, 2- indifferent, 3- satisfied and 4- very satisfied.

Statistical analysis

Data were analyzed using OriginLab software by an investigator who was blind to group allocation. Kolomogorov–Smirnov test was used to determine the nature of the distribution of the data. The differences between the baseline and posttreatment measurements were analyzed using Student's *t*-test. Significance was set at $P<0.05$.

Results

In this study, all the patients (G1 and G2) received the same treatment with Combined Therapy, and only the G2 patients received additional treatment with the whole-body vibration platform for 10 min. A total of 200 sessions of treatments were made in 10 sessions by a volunteer. Baseline characteristics were comparable between the two study groups and are presented in Table 1. Anthropometric measurement values of the volunteers (n=20) were: age: G1=28±7 years, G2=29±5 years. There were no significant changes in anthropometric measures of weight of the G1 ($P=0.27$) and G2 ($P=0.50$)

Table 1 Baseline characteristics of the study participants

	G1	G2	P-value
Age (years)	28±7	29±5	0.537
Weight (kg)	67.5±8.6	69.5±8.6	0.617
BMI (kg/m ²)	25.7±2.8	26.3±1.9	0.570
Buttocks (cm)	102.3±4.0	104.9±5.1	0.236
R0 (firmness skin)	0.14±0.01	0.15±0.01	0.087

Note: All values are mean±SD.

Abbreviation: BMI, body mass index.

patients and BMI of the G1 ($P=0.27$) and G2 ($P=0.24$) patients at baseline and after the treatment in both groups. Regarding the circumference measurement (cm), G2 showed substantial decrease in the measurements on buttocks (Table 2). The quantitative analysis by diagnostic ultrasound showed reduction in the thickness of subcutaneous fat (mm) in both groups. G1 did not show significant difference in the buttocks area ($P=0.09$); on the other hand, it showed a significant reduction in the posterior thigh region ($P<0.05$) when compared with posttreatment as assessed by ultrasound. G2 showed significant reduction in the buttocks area and in the posterior thigh region ($P<0.05$) when compared with posttreatment as measured by ultrasound (Figure 1A). In the panoramic image analysis performed by diagnostic ultrasound, the reduction of adipose tissue lodged between the skin and the muscles of the treated regions was verified, as can be seen in Figure 1B and C. Qualitative analysis showed morphologic improvement with respect to the subcutaneous tissue, fibrotic septa and aspects of the dermis-related cellulite, as can also be seen in Figure 1B and C.

In Figure 2A, a cellulite degree evaluation is shown according to the generally accepted classification of cellulite, at baseline (before) and 15 days after the last session in G1 and G2, respectively. The results showed that, in all the areas treated in both groups, a statistically significant reduction of the cellulite aspect was found in the buttocks (G1 and G2, $P<0.05$) and in the posterior thighs area (G1 and G2, $P<0.05$). Standardized photographs showed improvement of body contouring and cellulite reduction in both groups (Figure 2B and C).

The results of parameter R0 showed a statistically significant (G1, $P<0.0001$ and G2, $P=0.0034$) improvement in the firmness of skin in all areas treated in both groups, when compared with baseline and 15 days posttreatment (Table 3).

The volunteers in both groups tolerated the treatment well: 40% (n=8) of the volunteers reported it tolerable, 45% (n=9) reported it comfortable and 15% (n=3) considered the treatment very comfortable. None of the volunteers (0%) considered the treatment intolerable. Regarding the satisfaction levels in both groups, comparison between the values at baseline and 15 days after the last treatment session gave the following results: 0% (none) of the volunteers was dissatisfied, 5% (n=1) were indifferent, 30% (n=6) were satisfied and 65% (n=13) were very satisfied with the treatment (Figure 3).

Discussion

The objectives of this study were to verify the effectiveness of the Heccus device, emphasizing the effects of Combined Therapy in the improvement of body contouring and to

Table 2 Clinical characteristics of the study population at baseline and posttreatment (age, weight, BMI, circumference of the buttocks)

	G1		G2	
	Baseline	Posttreatment	Baseline	Posttreatment
Age (years)	28±7		29±5	
Weight (kg)	67.5±8.6	65.8±8.6	69.5±8.6	69.5±8.6
BMI (kg/m ²)	25.7±2.8	24.9±2.8	26.3±1.9	26.3±1.9
Buttocks (cm)	102.3±4.0	101.1±5.1	104.9±5.1	103.9±4.7*

Notes: *Statistically significant difference ($P<0.05$). All values are mean±SD.

Abbreviation: BMI, body mass index.

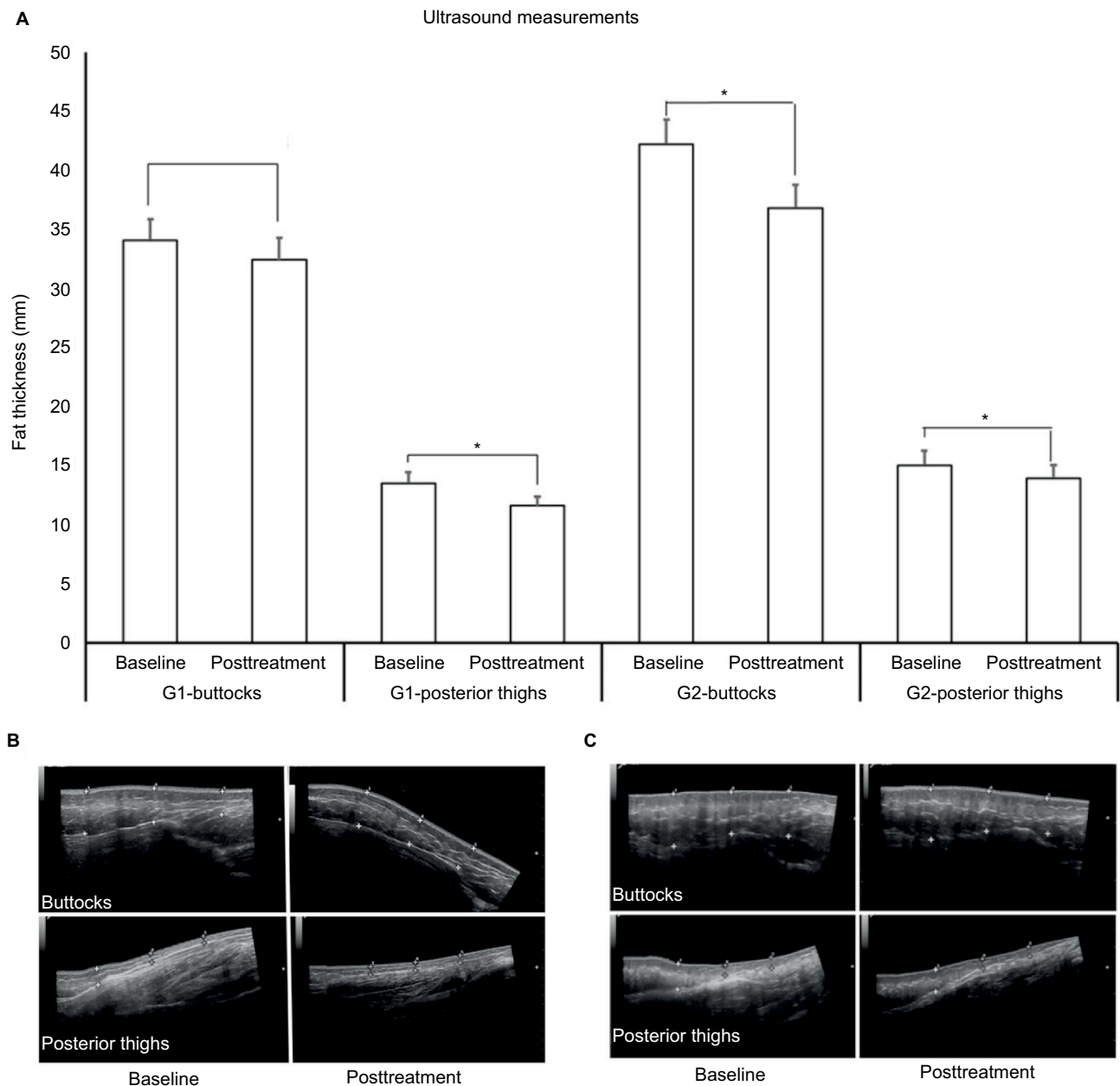


Figure 1 (A) Mean values and SDs of the fat thickness assessment by diagnostic ultrasound before treatment (baseline) and after treatment (after 15 days). *Statistically significant difference ($P<0.05$). Comparative panoramic images of the buttocks and the posterior thighs in (B) G1 and (C) G2 groups. Note the hyperechoic areas: bright echoes, highly reflective structures (white = dermis and fibrotic septa) and hypoechoic areas: sparse echoes, reflection or intermediate transmission (gray = adipose tissue and skeletal muscle). The points (+) indicate the areas compared and the decrease in thickness and density of the fibrotic septa after treatment.

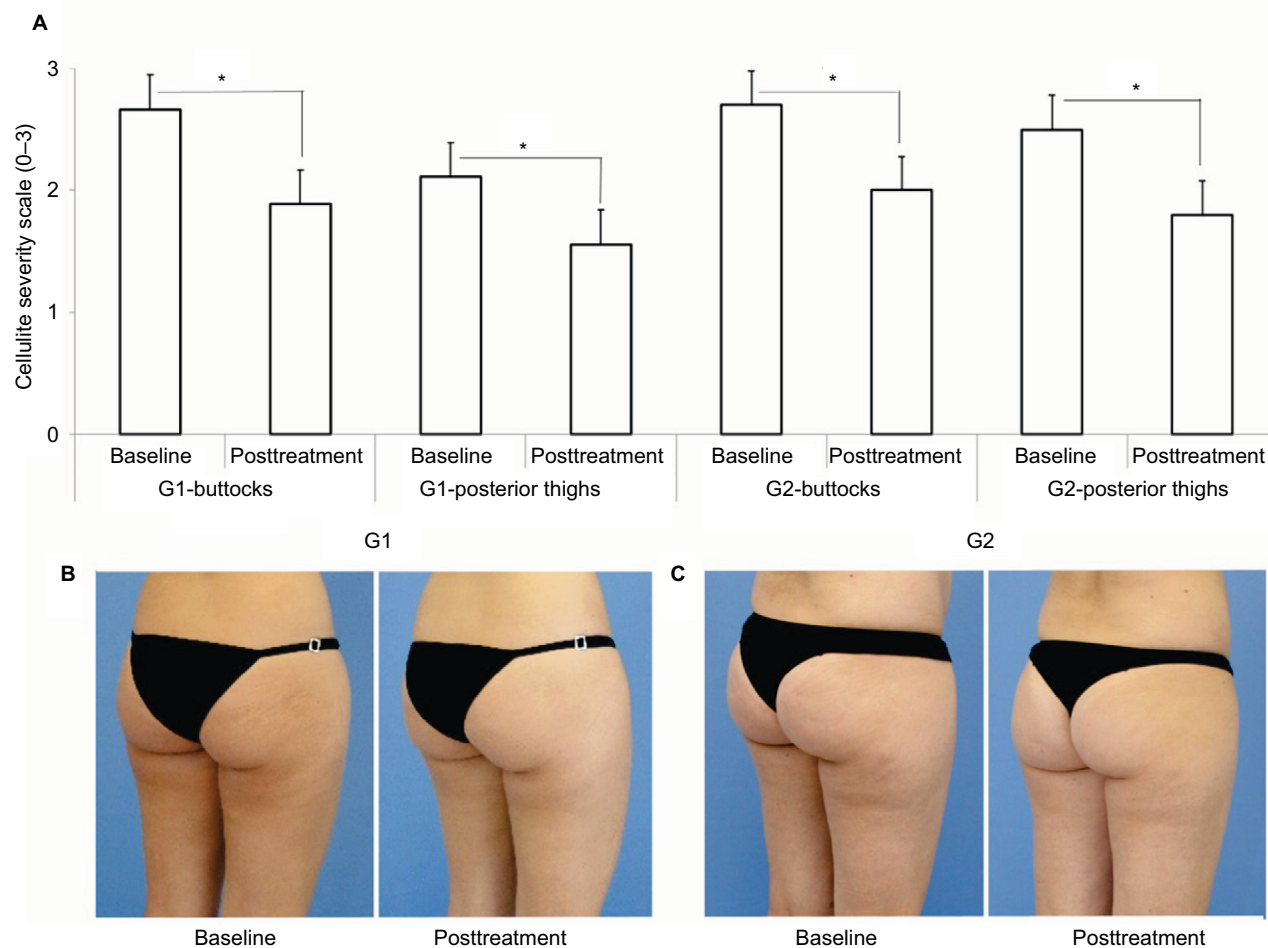


Figure 2 (A) Mean values and SDs of the cellulite degree evaluation according to the generally accepted classification of cellulite at baseline (before) and 15 days after the last session. *Statistically significant difference ($P < 0.05$). Comparative photographic representation showing clinical improvement of the buttocks and posterior thighs in **(B)** G1 and **(C)** G2 at baseline and posttreatment.

Table 3 Values of the R0 (skin firmness) in baseline and posttreatment in G1 and G2

R0	Baseline	Posttreatment
G1	0.14 ± 0.01	0.09 ± 0.01*
G2	0.15 ± 0.01	0.12 ± 0.02#

Notes: Statistically significant difference (* $P < 0.0001$, # $P = 0.0034$). All values are mean ± SD.

determine if the association of this therapy with whole-body vibration exercises can promote additional positive effects in the results of the treatments. In the esthetic treatment, both the ultrasonic energy and the therapeutic current interact with all the structures of the skin and with the subcutaneous tissue (epidermis–dermis to subcutaneous fat). In Combined Therapy Heccus, the effects induced by therapeutic ultrasound can be associated with different therapeutic currents’ effects: Aussie current, high-voltage current or polarized current.

Nowadays, there are devices that have been developed to use focused ultrasound mostly for localized fat treatments. This type of system emits focused ultrasound waves to deliver concentrated energy into a focal volume at a precise depth in the subcutaneous tissue.^{26–30} However, this type of technology treats only localized fat, whereas the Heccus system, using Combined Therapy, may have the potential to treat localized fat deposits, cellulite and skin flaccidity simultaneously.

Ultrasound can induce biological effects through heating that results from the absorption of ultrasonic energy and through nonthermal mechanisms that include ultrasonic cavitation, mechanical stress and other nonthermal processes. In cosmetic application, both thermal and nonthermal mechanisms within an ultrasonic field are used for the destruction of adipose tissue and contraction of collagen-based tissue (dermis).¹² Ultrasonic waves create compression cycles

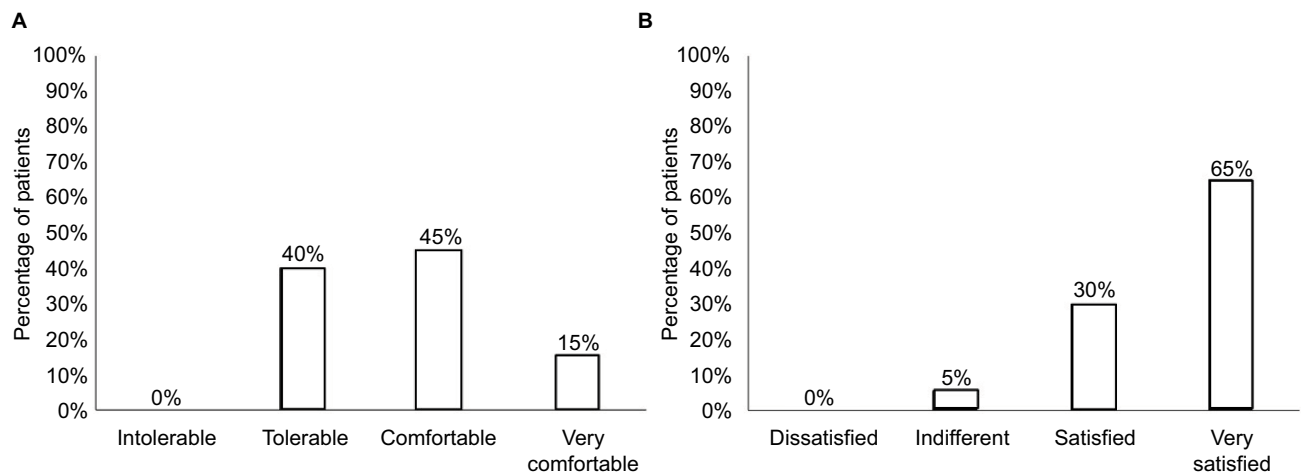


Figure 3 (A) Volunteer satisfaction with treatment: 1- dissatisfied, 2- indifferent, 3- satisfied and 4- very satisfied. **(B)** Volunteer tolerance to treatment: 1- intolerable, 2- tolerable, 3- comfortable and 4- very comfortable.

that exert positive pressure and expansion cycles that exert negative pressure. When ultrasonic waves penetrate and travel through tissue, they lose energy as they are reflected, scattered or absorbed by the tissues. Therapeutic currents can be used to improve the venous and lymphatic return of lower limbs. Their use is based on the premise that muscle contraction increases the compartment pressure and compresses the lymphatic and blood vessels, propelling the fluids contained therein as a milking action.³¹ In addition, studies have shown that therapeutic electrical currents can positively influence lymphatic smooth muscle activity.³² In this study, the ultrasound was combined with Aussie current, which is a type of medium-frequency alternating current, and the stimulation intensity was increased by the operator until the participant felt a strong, but comfortable paresthesia. In this study, the 4 kHz Aussie current was modulated at a low frequency (10 Hz). Studies suggest that the stimulation frequencies of the lymphatic smooth muscle vary from 0.5 to 40 Hz, since the lymphatic smooth muscle responds to low-frequency stimuli.^{32,33}

This study revealed that all the treatment areas in both groups showed reduction in the thickness of subcutaneous fat (mm) on diagnostic images when compared to baseline. The greatest reduction of fat thickness was observed in the posterior thigh areas of the G1 group and in the buttocks areas and the posterior thigh areas of the G2 group (Figure 1A). These results may be related to the slight weight gain of G1 during the treatment (baseline: 67.5 ± 8.6 /posttreatment: 69.5 ± 8.6), as can be seen in Table 1. The reduction in adipose tissue after the treatment in both groups may be a result of lipolysis or mechanical disruption of subcutaneous adipocytes. Experimental studies suggest that the absorption of

ultrasonic energy can lead to changes in the cellular activity and in the structure of adipocytes, and it releases lipids in the blood circulation and extracellular space immediately after the treatment.³⁴⁻³⁶

The mechanism of fat mobilization is not clear; however, there are some hypotheses as follows: fat mobilization may be based on frequency resonance, where the energy provided to the enzyme by the ultrasound wave may induce transient conformational shifts in certain enzymatic proteins, altering the activity of the enzyme (i.e., kinases or phosphatases) and the overall function of the cell; it may involve a mechanism of ultrasound irradiation-induced secretion of norepinephrine from the sympathetic nerves; it may happen by altering the permeability of the adipocytes, besides adipocytes' disruption.^{9,28,36,37} Body circumference is statistically significant only in G2. However, these data may not be as relevant since circumferential measurements may be affected by abdominal distension. Measurements of the adipose layer obtained by diagnostic ultrasound are accurate and indicate reduction of thickness in the treated areas.

Cellulite is related to collagen and elastic tissue degeneration in dermis and hypodermis associated with fat deposition. Higher echogenicity can be viewed by ultrasonography when the level of disorganization and abundance of collagen tissue is high.³⁸ In this study, qualitative analysis demonstrated morphologic improvement in the subcutaneous tissue, fibrotic septa and aspects of the dermis-related cellulite, as can be seen in Figure 1B and C. It is noteworthy that ultrasound changes are apparently less visible than clinical alterations, and that the evaluation parameters by ultrasonography are not well established; however, it was possible to observe general improvement of the cellulite, especially in the gluteal region.

In the panoramic image analysis performed by the diagnostic ultrasound, the reduction of adipose tissue lodged between the skin and the muscles of the treated regions was verified. Cavitation and heating are intensity dependent, and the 3 MHz frequency increases the tissue temperature at a faster rate than the 1 MHz frequency.^{39,40} Therapeutic ultrasound acts on the subcutaneous tissue, giving positive results in localized fat.⁴¹ Studies showed that ultrasound in low intensity can induce apoptosis by a mild hyperthermia (40°C–44°C for 10–30 min), and they suggest that hyperthermia seems to inhibit repair of membrane damage caused by sonication.⁴² In this study, 3 MHz, 2 W/cm² and continuous mode were used because these parameters can be more effective to produce thermal and nonthermal effects in subcutaneous tissue (~2 cm depth).⁴³ The evaluation of photographic records of the areas treated, following the scale proposed by Nürnberger and Müller,⁶ showed statistically significant difference in all the areas treated in both groups, in the buttocks and the posterior thigh areas of the G1 and G2 groups, as shown in Figure 2A. All volunteers showed improvement of skin appearance after treatment with Combined Therapy sessions, suggesting a decrease of the tensile forces on the skin and possible redistribution of vector forces (vertical forces) in the septum. Ultrasound vibrations have been implicated in the upregulation of some immediate-early response genes known to be mechanosensitive.⁴⁴ Perhaps this may explain the improvement of skin appearance and the apparent tissue remodeling visible through digital photographs of the treated regions, as can be seen in Figure 2B and C. In our study, two modalities were used together, ultrasound plus Aussie current, which probably promote improvement of localized fat and cellulite by edema reduction and excessive hydrophilia of the extracellular matrix.

In this study, whole-body vibration was used as a complement to the effects of Combined Therapy. The use of whole-body vibration as a complement to conventional physical training has increased over the last 20 years. This treatment is applied through a vibration platform on which the person may stand while performing activities such as a body weight squat, and is currently enjoying popularity as an alternative exercise modality for enhancing muscle activity, force and power.⁴⁵ The vibration protocol often includes 5–10 intervention sets of 30–60 s of vibration with rest intervals of 1–2 min between sets.^{45,46} The volunteers of G2, in addition to receiving treatment with Combined Therapy, received 10-minute sessions in a whole-body vibration platform (10 Hz), divided into two periods of 5 min with 2 min of interval between each activity, immediately after treatment with the device. The

volunteers were positioned in standing position with upright spine and semi-flexed knees on the whole-body vibration platform. The results suggest that the whole-body vibration platform can be used to increase the results of the treatment with Combined Therapy, especially in the localized fat treatment, but it does not seem to influence the cellulite and skin flaccidity because both groups showed similar improvement. The mechanism of reduction of the fat thickness is not clear, but studies suggest that the whole-body vibration platform seems to have positive effects in fat mobilization, such as increase in metabolism, thermogenic effect and increase in oxygen consumption (VO₂).^{46–48} The firmness of skin was also evaluated in this study through the Cutometer MPA 580 device, a noninvasive tool to measure the biomechanical properties of the skin, which has often been used to study changes in skin viscoelasticity, such as in burn scars and post-esthetic treatments such as manual lymphatic drainage, cosmetic products, shockwave therapy and in evaluating age-related changes.^{5,24,49–51} Few studies have been found showing relation between the use of therapeutic nonfocused ultrasound and the biomechanical characteristics of the skin, and studies using Combined Therapy were not found. The exact mechanism of action of the therapeutic ultrasound on skin firmness is not clear. However, an experimental study demonstrated through histologic and morphometric analysis that the absorption of higher doses of ultrasound can produce changes in the epidermis and dermis, such as increase in the thickness of epidermis and thinning of collagen fibers in dermis; this could be considered as a proliferation mechanism of the collagen fibers, leading to changes in the local younger fibers.⁵² On the other hand, a study that used continuous ultrasound (3 MHz, 1 W/cm²) for treatment of 31 volunteers and the parameter R0 showed a significant increase in skin firmness, when compared to the values before application and immediately post-application, which feature a greater distensibility.⁵³ In this study, Combined Therapy (ultrasound nonfocused plus Aussie current) was used in the treatment of buttocks, and an optimal improvement of skin firmness was observed on the treated areas in both groups, G1 and G2, which is demonstrated in Table 3. In this study, 2 W/cm² of ultrasound intensity was used; higher intensities seem to be related to the increase of collagen and significant skin tightening.

Another important point of this study was the evaluation of the levels of tolerance and satisfaction with the treatment through self-questionnaires. The procedure was considered well tolerated (0% intolerable). The percentage of satisfaction level was 95% (30% satisfied, 65% very satisfied) after

the treatment (Figure 3). One of the great advantages of this system is the safety and comfort of the therapy, since 200 treatment sessions were performed and no adverse reactions were observed. All patients resumed normal activities immediately after each session of the treatment, without downtime, pain or discomfort.

This pilot study has some limitations that must be considered when interpreting the results. The sample size is small and there is no placebo group. Therefore, caution must be applied, as the findings might not be transferable to the general population. Further studies using larger sample size and placebo group should be performed to confirm these results.

Conclusion

We conclude that the synergistic effects of the Combined Therapy (nonfocused ultrasound plus Aussie current) might be a good option with noninvasive body contouring treatment for improving the aspect of the cellulite, skin firmness and localized fat. If used in association with the whole-body vibratory platform, the results can be better, especially in the treatment of localized fat. The treatment was well tolerated and the satisfaction index was 95%. Randomized trials with more volunteers should be carried out, and a placebo group should be introduced in further studies.

Acknowledgments

This research project is supported by the Center for Education and Advanced Training CEFAP (Amparo, Sao Paulo, Brazil). The authors thank Ms Alexandra Paioli for English language and grammatical technical support.

Disclosure

Dr Sant'Ana, Dr Guidi, Dr Grecco and Dr Nogueira are researchers at IBRAMED. The other authors report no conflicts of interest in this work.

References

- Khan MH, Victor F, Rao B, Sadick NS. Treatment of cellulite: part I. pathophysiology. *J Am Acad Dermatol*. 2010;62:361–370.
- Rossi ABR, Vergnanini AL. Cellulite: a review. *J Eur Acad Dermatol Venereol*. 2000;14:251–262.
- Avram MM. Cellulite: a review of its physiology and treatment. *J Cosmet Laser Ther*. 2004;6:181–185.
- Chang P, Wiseman J, Jacoby T, Salisbury AV, Ersek RA. Noninvasive mechanical body contouring: (Endermologie) a one-year clinical outcome study update. *Aesthetic Plast Surg*. 1998;22:145–153.
- Schonvetter B, Soares JLM, Bagatin E. Longitudinal evaluation of manual lymphatic drainage for the treatment of gynoid lipodystrophy. *An Bras Dermatol*. 2014;89:712–718.
- Pianez LR, Custódio FS, Guidi RM, Freitas JN, Sant'Ana E. Effectiveness of carboxytherapy in the treatment of cellulite in healthy women: a pilot study. *Clin Cosmet Investig Dermatol*. 2016;9:183–190.
- Mulholland RS, Paul MD, Chalfoun C. Noninvasive body contouring with radiofrequency, ultrasound, cryolipolysis, and low-level laser therapy. *Clin Plast Surg*. 2011;38:503–520.
- Souza NH, Ferrari RA, Silva DF, Nunes FD, Bussadori SK, Fernandes KP. Effect of low-level laser therapy on the modulation of the mitochondrial activity of macrophages. *Brazilian J Phys Ther*. 2014;18:308–314.
- Watson T. The role of electrotherapy in contemporary physiotherapy practice. *Man Ther*. 2000;5:132–141.
- Almeida TF, Roizenblatt S, Benedito-Silva AA, Tufik S. The effect of combined therapy (ultrasound and interferential current) on pain and sleep in fibromyalgia. *Pain*. 2003;104:665–672.
- Sant'Ana EMC. Fundamentação teórica para a Terapia Combinada Heccus® – Ultrassom e Corrente Aussie no tratamento da lipodistrofia ginóide e da gordura localizada [Theoretical Background to Heccus® Combination Therapy – Ultrasound and Aussie current in the treatment of lipodystrophy gynoid and localized fat. *Rev Bras Ciência Estética* 2010;1:1–15. Portuguese.
- Miller DL, Smith NB, Bailey MR, Czarnota GJ, Hynynen K, Makin IR; Bioeffects Committee of the American Institute of Ultrasound in Medicine. Overview of therapeutic ultrasound applications and safety considerations. *J Ultrasound Med*. 2012;31:623–634.
- Robertson VJ, Baker KG. A review of therapeutic ultrasound: effectiveness studies. *Phys Ther*. 2001;81:1339–1350.
- Watson T. Electrotherapy on the web. *Therapeutic ultrasound*. 2015. Available from http://www.electrotherapy.org/assets/Downloads/Therapeutic_Ultrasound_2015.pdf.
- Venancio RC, Pelegrini S, Gomes DQ, Nakano EY, Liebano RE. Effects of carrier frequency of interferential current on pressure pain threshold and sensory comfort in humans. *Arch Phys Med Rehabil*. 2013;94:95–102.
- Ward AR, Robertson VJ, Makowski RJ. Optimal frequencies for electric stimulation using medium-frequency alternating current. *Arch Phys Med Rehabil*. 2002;83:1024–1027.
- Dantas LO, Vieira A, Siqueira AL, Salvini TF, Durigan JL. Comparison between the effects of 4 different electrical stimulation current waveforms on isometric knee extension torque and perceived discomfort in healthy women. *Muscle Nerve*. 2015;51:76–82.
- Ward AR, Lucas-Toumbourou S, McCarthy B. A comparison of the analgesic efficacy of medium-frequency alternating current and TENS. *Physiotherapy*. 2009;95:280–288.
- Dantas LO, Vieira A, Siqueira AL, Salvini TF, Durigan JL. Comparison between the effects of 4 different electrical stimulation current waveforms on isometric knee extension torque and perceived discomfort in healthy women. *Muscle Nerve*. 2015;51:76–82.
- Rehn B, Lidström J, Skoglund J, Lindström B. Effects on leg muscular performance from whole-body vibration exercise: a systematic review. *Scand J Med Sci Sport* 2007;17:2–11.
- Nürmberger F, Müller G. So-called cellulite: an invented disease. *J Dermatol Surg Oncol*. 1978;4:221–229.
- World Health Organization. *Obesity: Preventing and Managing the Global Epidemic – Report of a WHO Consultation*. 2000. Available from http://whqlibdoc.who.int/trs/WHO_TRS_894.pdf.
- Pianez LR, Custódio FS, Guidi RM, Freitas JN, Sant'Ana E. Effectiveness of carboxytherapy in the treatment of cellulite in healthy women: a pilot study. *Clin Cosmet Investig Dermatol*. 2016;9:183–190.
- Lee KC, Dretzke J, Grover L, Logan A, Moiemmen N. A systematic review of objective burn scar measurements. *Burn Trauma*. 2016;4:14.
- Addor FAS, Schalka S, Pereira VDMC, Filho JDO. Gestação e predisposição ao aparecimento de estrias: correlação com as propriedades biomecânicas da pele. *Surg Cosmet Dermatol*. 2010;2:253–256.
- Jewell ML, Solish NJ, Desilets CS. Noninvasive body sculpting technologies with an emphasis on high-intensity focused ultrasound. *Aesthetic Plast Surg*. 2011;35:901–912.
- Saedi N, Kaminer M. New waves for fat reduction: high-intensity focused ultrasound. 2013;32(1):26–30.

28. Brown SA, Greenbaum L, Shtukmaster S, Zadok Y, Ben-Ezra S, Kushkuley L. Characterization of nonthermal focused ultrasound for noninvasive selective fat cell disruption (lysis): technical and preclinical assessment. *Plast Reconstr Surg*. 2009;124:92–101.
29. Moreno-Moraga J, Valero-Altés T, Martínez Riquelme AM, Isarria-Marcosy MI, de la Torre JR. Body contouring by non-invasive transdermal focused ultrasound. *Lasers Surg Med*. 2007;39:315–323.
30. Mulholland RS. Non-surgical body contouring: introduction of a new non-invasive device for long-term localized fat reduction and cellulite improvement using controlled, suction coupled, radiofrequency heating and high voltage ultra-short electrical pulses. *J Clin Exp Dermatology*. 2012;3:157.
31. Faghri PD, Votto JJ, Hovorka CF. Venous hemodynamics of the lower extremities in response to electrical stimulation. *Arch Phys Med Rehabil*. 1998;79:842–848.
32. Cook HA, Morales M, La Rosa EM, et al. Effects of electrical stimulation on lymphatic flow and limb volume in the rat. *Phys Ther*. 1994;74:1040–1046.
33. Ohhashi T, McHale NG, Roddie IC, Thornbury KD. Electrical field stimulation as a method of stimulating nerve or smooth muscle in isolated bovine mesenteric lymphatics. *Pflugers Arch*. 1980;388:221–226.
34. Gonçalves WL, Graceli JB, Santos RL, Cicilini MA, Bissoli NS, Abreu GR, Moysés MR. Ultrasound lipoclasia on subcutaneous adipose tissue to produce acute hyperglycemia and enhance acute inflammatory response in healthy female rats. *Dermatologic Surg*. 2009;35:1741–1745.
35. Gonçalves WLS, Cirqueira JP, Abreu GR, Moysés MR. Implicações da lipoclasia dermosônica no metabolismo energético e na composição corporal de ratos wistar saudáveis. [Implications of dermosonic lipoclasia for energy metabolism and body composition of healthy Wistar rats] *Rev Bras Fisioter*. 2009;13:24–30. Portuguese.
36. Garcia O, Schafer M. The effects of nonfocused external ultrasound on tissue temperature and adipocyte morphology. *Aesthet Surg J*. 2013;33:117–127.
37. Miwa H, Kino M, Han LK, et al. Effect of ultrasound application on fat mobilization. *Pathophysiology*. 2002;9:13–19.
38. Mlosek RK, De bowska RM, Lewandowski M, Malinowska S, Nowicki A, Eris I. Imaging of the skin and subcutaneous tissue using classical and high-frequency ultrasonographies in anti-cellulite therapy. *Ski Res Technol*. 2011;17:461–468.
39. Baker KG, Robertson VJ, Duck FA. A review of therapeutic ultrasound: biophysical effects. *Phys Ther*. 2001;81:1351–1358.
40. Cambier D, D'Herde K, Witvrouw E, Beck M, Soenens S, Vanderstraeten G. Therapeutic ultrasound: temperature increase at different depths by different modes in a human cadaver. *J Rehabil Med*. 2001;33:212–215.
41. Rossi ABR, Vergnanini AL. Cellulite: a review. *J Eur Acad Dermatol Venereol*. 2000;14:251–262.
42. Feril LB Jr., Kondo T. Biological effects of low intensity ultrasound: the mechanism involved, and its implications on therapy and on biosafety of ultrasound. *J Radiat Res*. 2004;45:479–489.
43. Johns LD. Nonthermal effects of therapeutic ultrasound: the frequency resonance hypothesis. *J Athl Train*. 2002;37:293–9.
44. Huang H, Kamm RD, Lee RT. Cell mechanics and mechanotransduction: pathways, probes, and physiology. *Am J Physiol Cell Physiol*. 2004;287:C1–C11.
45. Capes IC, Universidade U, Paulista E, et al. Vibration exercise: the potential benefits. *Int J Sports Med*. 2011;32(2):75–99.
46. Kang J, Porfido T, Ismaili C, et al. Metabolic responses to whole-body vibration: effect of frequency and amplitude. *Eur J Appl Physiol*. 2016;116:1829–1839.
47. Hazell TJ, Lemon PWR. Synchronous whole-body vibration increases VO_2 during and following acute exercise. *Eur J Appl Physiol*. 2012;112:413–420.
48. Fares EJ, Charrière N, Montani JP, Schutz Y, Dulloo AG, Miles-Chan JL. Energy expenditure and substrate oxidation in response to side-alternating whole body vibration across three commonly-used vibration frequencies. *PLoS One*. 2016;11(9):e0163822.
49. Callaghan TM, Wilhelm K. A review of ageing and an examination of clinical methods in the assessment of ageing skin. Part 2: clinical perspectives and clinical methods in the evaluation of ageing skin. *Int J Cosmet Sci*. 2008;30:323–332.
50. Bielfeldt S, Buttgerit P, Brandt M, Springmann G, Wilhelm KP. Non-invasive evaluation techniques to quantify the efficacy of cosmetic anti-cellulite products. *Ski Res Technol*. 2008;14:336–346.
51. Knobloch K, Joest B, Vogt PM. Cellulite and extracorporeal Shockwave therapy (CelluShock-2009) – a randomized trial. *BMC Womens Health*. 2010;10:29.
52. De Bem DM, Maciel CD, Zuanon JA, Neto CB, Parizotto NA. Histological analysis of healthy epithelium of Wistar rats in vivo irradiated with different intensities of therapeutic ultrasound. *Revista brasileira de fisioterapia*. 2010;14:114–120. Portuguese.
53. Brancalion Catapani L, da Costa Gonçalves A, Morano Candeloro N, Rossi LA, Caldeira de Oliveira Guirro E. Influence of therapeutic ultrasound on the biomechanical characteristics of the skin. *J Ther Ultrasound*. 2016;4:1–8.

Clinical, Cosmetic and Investigational Dermatology

Publish your work in this journal

Clinical, Cosmetic and Investigational Dermatology is an international, peer-reviewed, open access, online journal that focuses on the latest clinical and experimental research in all aspects of skin disease and cosmetic interventions. This journal is included on PubMed. The manuscript management system is completely online

Submit your manuscript here: <https://www.dovepress.com/clinical-cosmetic-and-investigational-dermatology-journal>

Dovepress

and includes a very quick and fair peer-review system, which is all easy to use. Visit <http://www.dovepress.com/testimonials.php> to read real quotes from published authors