

# How Replace the Gastrostomy Tube in Children with Extremely Compromised General Conditions

Carmine Noviello, Mercedes Romano, Lorenzo Rossi, Giovanni Cobellis, Ascanio Martino

Maternal and Child Health Department, Paediatric Surgery Unit, Salesi Children Hospital, Ancona, Italy

## Abstract

The percutaneous endoscopic gastrostomy is the best technique to use in case of children requiring long-time enteral nutrition. The first replacement of the tube is easy in most of the patient, but this step can be extremely problematic in patients with compromised general conditions. The authors report their experience in some cases. Two boys with endoscopic gastrostomy had a deterioration in the general conditions, when replacing the probe, these conditions contraindicated anaesthesia for which the “cut-and-push” technique was adopted in a patient with heart malformation and a local anaesthetic in a neuropathic patient. Both the boys died a few days after this procedure. In our opinion, in children who are not using anaesthesia to reposition the gastrostomy probe, it is best to continue feeding through the nasogastric probe.

**Keywords:** Endoscopy, gastrostomy, percutaneous endoscopic gastrostomy

## INTRODUCTION

Gastrostomy feeding is the best way for enteral nutrition in children with several neurological impaired. Most of the time these patients have important cardiac problems too. Gauderer *et al.* described an endoscopic technique in 1980.<sup>[1]</sup> Actually, percutaneous endoscopic gastrostomy (PEG) is widely accepted as a safe and easy procedure for children requiring long-term enteral nutrition. For this technique, a particular tube is necessary with an internal bumper to avoid dislocation. The use of gastrostomy for long time requires the replacement of the tube because of damage so that a new anaesthesia is necessary to remove endoscopically the bumper. Often, these patients have a general condition that contraindicates anaesthesia, and then, other methods must be used to remove the bumper. The authors report their experience in these problematic cases.

## CASE REPORTS

### Case 1

A male presented with Simpson–Golabi–Behmel syndrome, congenital heart malformation (Type IV truncus arteriosus with interrupted aortic arch) and diaphragmatic hernia. After surgical correction of diaphragmatic hernia, he had a palliative surgical

treatment for congenital heart malformation (pulmonary artery banding). When he was 3 months old, a PEG was performed because of alimentary problems (enteral feeding only by nasogastric tube). Later, the patient had some cardiovascular complication (cerebral ischemic attack, inferior vena cava thrombosis and fungal sepsis), so that a definitive heart correction was considered impossible. Six months later, he had a “cut-and-push” technique to change the gastrostomy tube because it was broken, and general conditions of the patient did not allow a safe anaesthesia (American Society of Anaesthesiologists [ASA] IV). One month later, the boy had bowel occlusion [Figure 1] and a surgical operation was necessary to remove the bumper (by little enterotomy in the distal ileum where a stenosis was present). The immediate post-operative period was regular, but 5 days after the operation, he died because of acute heart failure (autopsy report).

### Case 2

A male presented with spastic tetraparesis and serious food problems. When he was 1 year old, PEG was necessary

**Address for correspondence:** Dr. Carmine Noviello,  
Paediatric Surgery Unit, Salesi Children Hospital,  
Via Corridoni, 11, 60128, Ancona, Italy.  
E-mail: carmine.noviello@libero.it

Received: 23-12-2017 Accepted: 19-02-2018 Available Online: 16-09-2020

### Access this article online

Quick Response Code:



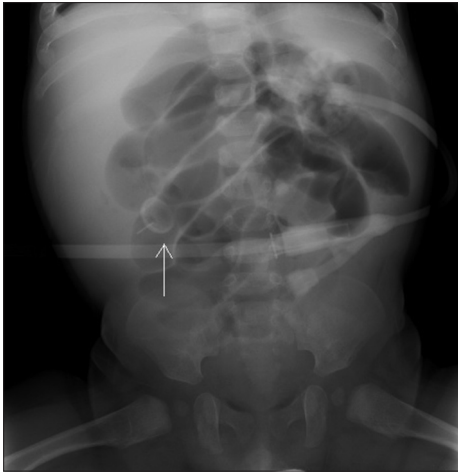
Website:  
www.afjpaedsurg.org

DOI:  
10.4103/ajps.AJPS\_100\_17

This is an open access journal, and articles are distributed under the terms of the Creative Commons Attribution-NonCommercial-ShareAlike 4.0 License, which allows others to remix, tweak, and build upon the work non-commercially, as long as appropriate credit is given and the new creations are licensed under the identical terms.

**For reprints contact:** WKHLRPMedknow\_reprints@wolterskluwer.com

**How to cite this article:** Noviello C, Romano M, Rossi L, Cobellis G, Martino A. How replace the gastrostomy tube in children with extremely compromised general conditions. Afr J Paediatr Surg 2019;16:38-9.



**Figure 1:** X-ray of the abdomen: Bumper blocked in the distal ileum (white arrow)

because of exclusively nasogastric tube feeding. Later, general conditions became worst: the patient developed a sepsis and was admitted to another centre for the treatment. During this hospitalisation, he had problem to use the gastric tube so that a new one was necessary. A nasogastric tube was positioned until general condition improved. Two months later, the boy came to our emergency room for accidentally removing of the gastrostomy tube and narrowing of the stoma. Anaesthesiologist classified an ASA III risk so that a dilatation of the stoma was performed with local anaesthesia until to insert a new tube with balloon (14 CH). General condition was stable, but 48 h later, he died because of acute heart failure (autopsy report).

## DISCUSSION

The PEG procedure for gastrostomy placement is safe, easy and universally accepted in children because of the low risk, especially in case of generally compromised conditions. Most of the tube used for this procedure has a small and soft intragastric device that keeps in place the gastrostomy. The management of this device is quite easy in children who may be undergoing anaesthesia: endoscopic removing or external traction removal.<sup>[2]</sup> Important problems arise in patients with complex cardiac malformations or in case of general conditions extremely compromised where anaesthesiological risk is high. Sometimes, the general conditions of these patients get worse so that it is more risky to handle the bumper than to place the PEG. Some authors reported a safe way to manage the

tube gastrostomy in adults: the “cut-and-push” technique<sup>[3,4]</sup> that is a cutting of the tube at skin level, pushing the bumper into the stomach and wait until the expulsion in the faeces. This technique is well reported in the adult although some complications are possible, especially in particular patients.<sup>[5,6]</sup> The “cut and push” is rarely used in children because serious complications are possible.<sup>[7]</sup> We managed in this way, with a bad result, the first case because it was a severely cardiopathic patient, declared inoperable and with sepsis. In the second one, we tried what we do in anaesthesia (external traction removal) using less invasiveness, but obviously, the technique has caused such a stress to lead the patient to death. In our opinion, similar children need a nasogastric tube for enteral nutrition until general conditions improve for a safe anaesthesia.

## Declaration of patient consent

The authors certify that they have obtained all appropriate patient consent forms. In the form the patient(s) has/have given his/her/their consent for his/her/their images and other clinical information to be reported in the journal. The patients understand that their names and initials will not be published and due efforts will be made to conceal their identity, but anonymity cannot be guaranteed.

## Financial support and sponsorship

Nil.

## Conflicts of interest

There are no conflicts of interest.

## REFERENCES

1. Gauderer MW, Ponsky JL, Izant RJ Jr. Gastrostomy without laparotomy: A percutaneous endoscopic technique. *J Pediatr Surg* 1980;15:872-5.
2. Ponsky JL. Techniques of removal and replacement. *Gastrointest Endosc Clin North Am* 1992;2:215-21.
3. Merrick S, Harnden S, Shetty S, Chopra P, Clamp P, Kapadia S, *et al.* An evaluation of the “cut and push” method of percutaneous endoscopic gastrostomy (PEG) removal. *JPEN J Parenter Enteral Nutr* 2008;32:78-80.
4. Agha A, AlSaudi D, Furnari M, Abdulhadi Ali MM, Morched Chakik R, AlSaudi I, *et al.* Feasibility of the cut-and-push method for removing large-caliber soft percutaneous endoscopic gastrostomy devices. *Nutr Clin Pract* 2013;28:490-2.
5. Harrison E, Dillon J, Leslie FC. Complications of the cut-and-push technique for percutaneous endoscopic gastrostomy tube removal. *Nutr Clin Pract* 2011;26:230-1.
6. Brown JN, Borrowdale RC. Small bowel perforation caused by a retained percutaneous endoscopic gastrostomy tube flange. *Nutr Clin Pract* 2011;26:227-9.
7. Okpechi JC, Schenkman KA. Bronchoesophageal fistula after gastrostomy tube removal by the “cut and push” method. *Gastrointest Endosc* 2003;58:134-7.