

Sudden cardiac arrest of a 16-year-old boy with left main coronary artery atresia: a case report

Nobunari Tomura ¹, Takuo Nakagami^{1*}, Shinichiro Yamaguchi¹, and Hitoshi Yaku²

¹Department of Cardiovascular Medicine, Omihachiman Community Medical Center, 1379 Tsuchidacho, Omihachiman, Shiga 523-0082, Japan; and ²Department of Cardiovascular Surgery, University Hospital, Kyoto Prefectural University of Medicine, 465 Kajicho, Kamigyo-ku, Kyoto-shi, Kyoto 602-8566, Japan

Received 12 December 2019; first decision 30 December 2019; accepted 23 April 2020; online publish-ahead-of-print 9 June 2020

Background

In many cases, the cause of exercise-induced cardiopulmonary arrest in young persons is thought to be fatal arrhythmia, and one of the causes is ischaemic heart disease. Left main coronary artery atresia (LMCAA) is an extremely rare disease in which there is a congenital defect of the left main coronary artery, causing heart failure and exercise-induced angina attacks at a young age. Thus, it is disease that should be differentiated when examining young persons with chest pain.

Case summary

A 16-year-old boy experienced sudden cardiopulmonary arrest during soccer practice, was brought to our hospital for emergency treatment after return of spontaneous circulation. Elective coronary angiography revealed findings indicating an osmium defect in the left coronary artery (LCA) and blood flow via collateral circulation from the right coronary artery. Contrast-enhanced coronary computed tomography (CT) angiography showed a defect in the LCA ostium and LMCAA was diagnosed in the patient. After coronary artery bypass grafting was performed, but the patient was discharged in an ambulatory state with a wearable cardiac defibrillator. Postoperative course has been favourable.

Discussion

Left main coronary artery atresia is an extremely rare disease in which there is a congenital defect of the left main trunk of the coronary artery and should be differentiated when encountering cases of heart failure or exercise-induced angina/arrhythmia attacks in young persons who are not at risk for atherosclerosis. Exercise electrocardiogram may show a false negative result, and therefore coronary CT is useful for diagnosis.

Keywords

Case report • Left main coronary artery atresia • Sudden cardiac arrest • Coronary computed tomography angiography

Learning points

- Left main coronary artery atresia (LMCAA) is an extremely rare anomaly and can be the cause of exercise-induced ischaemic heart attack.
- We should consider LMCAA when examining young people with ischaemic symptoms and no cardiovascular risk factors.
- Cardiac computed tomography angiography is very useful of diagnosis of LMCAA.

*Corresponding author. Tel: +810748333151, Email: takuonakagami@gmail.com

Handling Editor: Christian Fielder Camm

ESC Case Competition Winner and underwent peer review by that organization prior to being submitted to EHJ-Case Reports.

Compliance Editor: Amir Aziz

Supplementary Material: Editor: Peysh A. Patel

© The Author(s) 2020. Published by Oxford University Press on behalf of the European Society of Cardiology.

This is an Open Access article distributed under the terms of the Creative Commons Attribution Non-Commercial License (<http://creativecommons.org/licenses/by-nc/4.0/>), which permits non-commercial re-use, distribution, and reproduction in any medium, provided the original work is properly cited. For commercial re-use, please contact journals.permissions@oup.com

Introduction

Fatal arrhythmia is thought to be the cause of many cases of cardiopulmonary arrest during exercise in young persons. One of the typical causes is ischaemic heart disease, but it is rare in young persons.¹ Left main coronary artery atresia (LMCAA) is an extremely rare disease in which there is a congenital defect of left main coronary artery, causing heart failure and exercise-induced angina attacks at a young age.^{2,3} Here, we report our experience with a case of LMCAA diagnosed after resuscitation in a boy who had the symptoms of exercise-induced angina attacks since the age of 12 years, but electrocardiogram test results were negative and who experienced sudden cardiopulmonary arrest during soccer practice at age of 16 years.

Timeline

2014	Exertional chest pain with normal echocardiogram [ejection fraction (EF): 57%] and treadmill load test.
May 2018	
Hospital Day 1	Collapsed due to ventricular fibrillation during soccer practice and resuscitated with automated external defibrillator. Left ventricular (LV) function globally reduced (EF: 34%) without ST elevation. Cerebral low-temperature therapy conducted.
Day 2	Recovered consciousness completely.
Day 7	Coronary angiography and aortography (AoG) showed the absence of contrast filling to left main trunk (LMT) antegradely.
Day 9	Coronary computed tomography angiography confirmed the absence of true LMT.
Day 15	Coronary artery bypass grafting conducted.
Day 28	Coronary computed tomography angiography showed good patency of bypass grafts.
Day 32	Echocardiogram showed improvement of LV function (EF: 59%).
Day 65	Discharged without any sequelae.

Case presentation

A 16-year-old boy suddenly experienced cardiopulmonary arrest while playing soccer, received cardiopulmonary resuscitation and automated external defibrillator (AED) treatment by a bystander and was brought to our hospital after return of spontaneous circulation.

The patient had low exercise tolerance since childhood and was admitted to another hospital at age 12 due to the symptom of chest pain while playing soccer. Transthoracic echocardiographic imaging showed normal left ventricular diffuse wall motion [ejection fraction (EF) = 57%], and formation of a trabeculation with suspected non-compaction at the left ventricular apex. The results of treadmill exercise test were negative and follow-up was performed without treatment. The patient became a high school student and noticed an angina attack twice during exercise, but symptoms were quickly ameliorated by bed rest only. In May

2018, an AED was used by a schoolteacher who suddenly collapsed during soccer. After the third AED operation, return of spontaneous circulation was noted and the patient was brought to our hospital for emergency treatment. On admission, significantly reduced consciousness (Glasgow coma scale; E1V1M2) was noted, and therapeutic hypothermia under ventilator management was promptly introduced for protection of the brain.

The initial workup was 103.2 pg/mL (<18.4) for B-type natriuretic peptide and 0.09 ng/mL (0.00–0.03) for Troponin I. Atrial blood gas analysis were pH 7.233 (7.35–7.45), pCO₂ 39.0 mmHg (35–48), pO₂ 101.0 mmHg (83–108), and Lac 93.0 mg/dL (4.5–14.4). Chest X-ray revealed the presence of cardiac enlargement (CTR 58%) and pulmonary oedema. Head computed tomography (CT) indicated unclear medullary boundary on the basilar side and hypoxic encephalopathy was suspected. A 12-lead electrocardiogram indicated sinus rhythm, 2-mm ST depression in the anterolateral leads and borderline QTc (441 ms) (Figure 1B). Transthoracic echocardiographic imaging showed decreased left ventricular diffuse wall motion (EF = 34%), and formation of a trabeculation with suspected non-compaction at the left ventricular apex. As a result of AED analysis, initial waveform indicated ventricular fibrillation (Figure 1A).

When midazolam administration was discontinued on hospital Day 1 for the purpose of assessment of consciousness level, an improvement to GCS E4VtM6 was noted. Therefore, the rewarming period was shortened from 48 to 20h, the artificial respiration was ceased on hospital Day 2, and the patient was discharged from the intensive care unit on hospital Day 4.

Selective coronary angiography revealed left coronary artery (LCA) defect from the ostium and return of blood flow from the right coronary artery via collateral circulation on hospital Day 7 (Figure 2A). Right coronary artery was well developed, there were no angiectopia or stenosis, and collateral circulation was observed from a posterior descending artery branch to the periphery of the left anterior descending artery (LAD), from a posterolateral branch to the diagonal branch, and from an atrioventricular node branch to left circumflex artery (LCX). Furthermore, a solitary conus branch with a different ostium directly above the right coronary ostium allowed circulation of blood flow to LAD/LCX via Vieussens' arterial ring. The left main trunk had a blind end at the junction of both (Figure 2B). As a result of collateral circulation, there was no significant stenosis in LAD and LCX revealed by contrast-enhancement.

Coronary angiography CT showed a lack of LCA ostium and no traffic between the left pulmonary artery on hospital Day 9 (Figure 3). Therefore, LMCAA was diagnosed in the patient. Myocardial perfusion scintigraphy revealed drug-induced blood flow imbalance in the apex and posterior wall and viability of the same site on hospital Day 10. Off-pump coronary artery bypass grafting with two branches (left internal mammary artery–LAD, right internal mammary artery–D1) was performed for the purpose of revascularization on hospital Day 15. Postoperative course was favourable, and coronary angiography CT on postoperative Day 13 revealed favourable bypass graft patency (Figure 4). Transthoracic echocardiographic imaging on postoperative Day 17 showed dramatically improved left ventricular diffuse wall

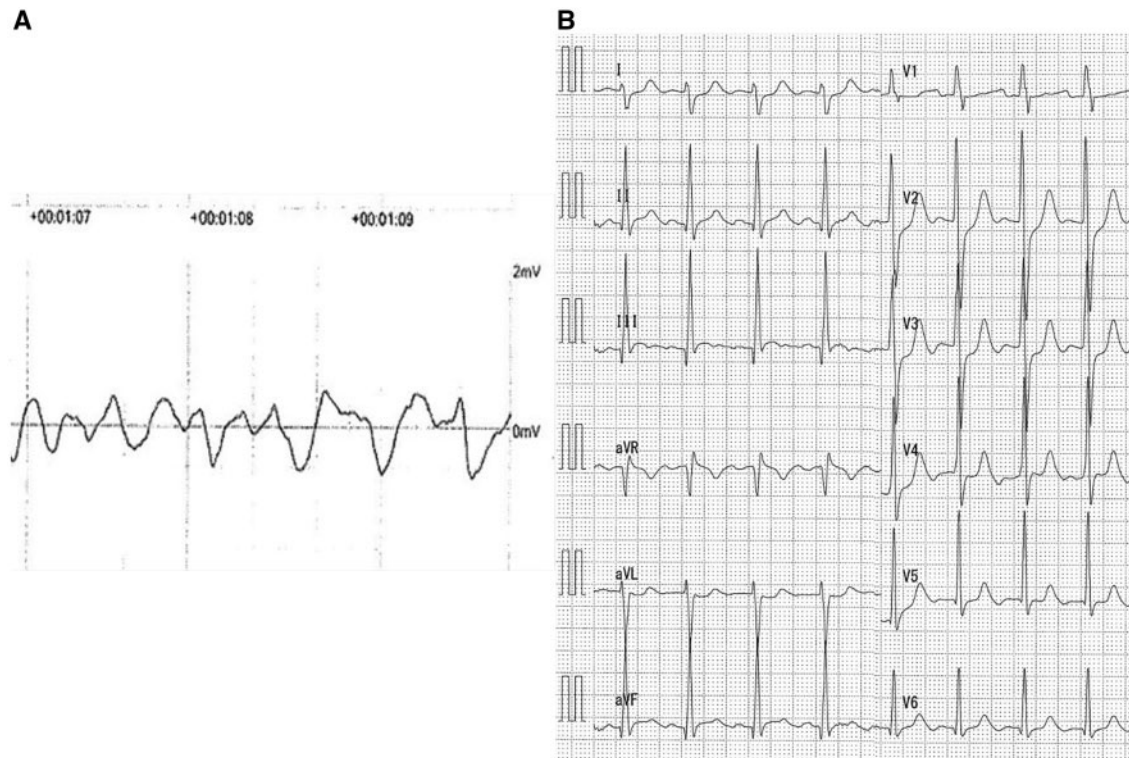


Figure 1 (A) Ventricular fibrillation waveform documented on the automated external defibrillator record. (B) Electrocardiogram on initial work up.

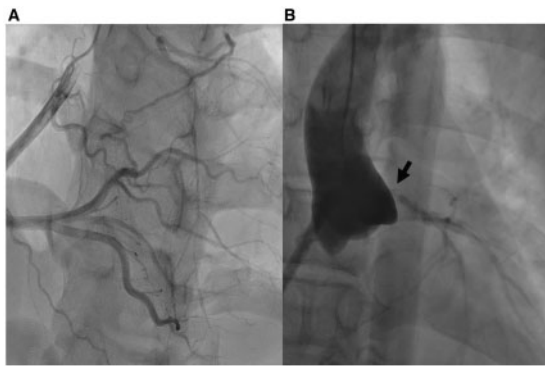


Figure 2 (A) Coronary angiography showed dominant right coronary artery, supplying to left coronary artery retrogradely. (B) AoG showed the absence of contrast filling of left main trunk (black arrow).

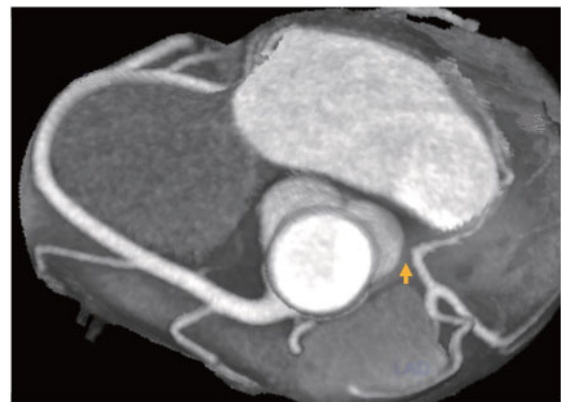


Figure 3 Coronary computed tomography angiography confirmed absence of true left main trunk (yellow arrow).

motion (EF = 59%). After cardiac rehabilitation, the patient was discharged in an ambulatory state on postoperative Day 50. A wearable cardioverter-defibrillator (WCD) was used for approximately 3 months, but no obvious chest symptoms or ventricular arrhythmia were observed, and the patient is currently showing good progress without implantable cardioverter-defibrillator (ICD) implantation.

Discussion

Left main coronary artery atresia is an extremely rare congenital coronary artery abnormality that causes ischaemic cardiomyopathy at a young age. To the best of our knowledge, only about 55 cases of LMCAA were reported in the English literature.^{2,3} During childhood, the aspects of myocardial ischaemia change during the growth

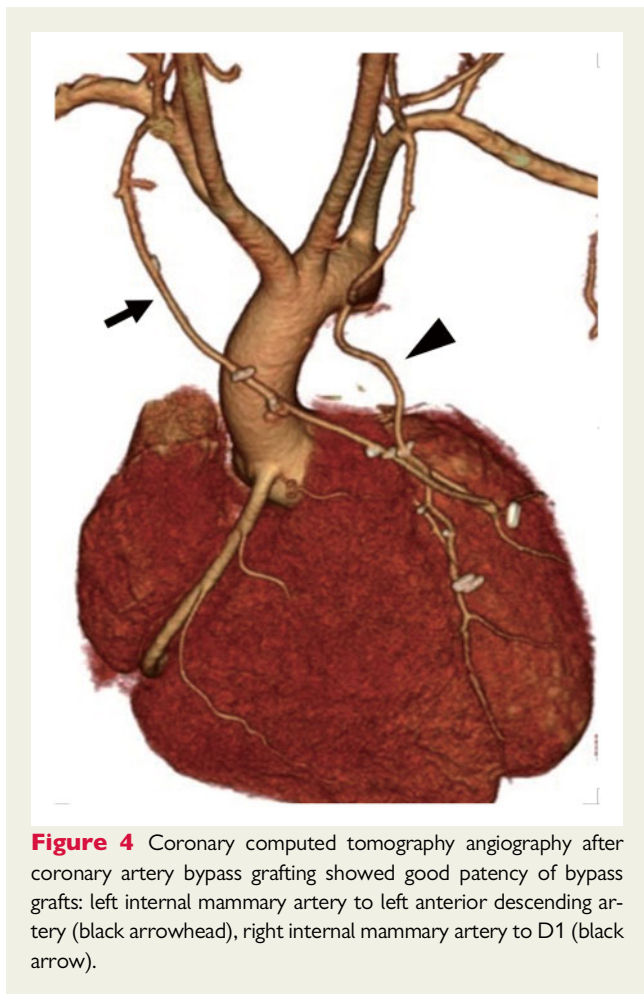


Figure 4 Coronary computed tomography angiography after coronary artery bypass grafting showed good patency of bypass grafts: left internal mammary artery to left anterior descending artery (black arrowhead), right internal mammary artery to D1 (black arrow).

process, making it difficult to diagnose, and there are many severe cases leading to heart failure symptoms, syncope, sudden death, and so on. The five causes of LMCAA are as follows: primordial defect of the coronary artery, failure of the coronary artery primordia to develop in a fixed position, fibrosis of the aorta media, occlusion due to early Foetal infection, and occlusion due to thrombus.⁴ To date, coronary angiography has been essential for the definitive diagnosis of this disease, but in recent years, the usefulness of coronary angiographic CT has been reported.⁵ Angiography has limitations in its diagnostic capabilities because of the lack of extraluminal evaluation. Differential diagnosis includes anomalous origin of right/LCA from pulmonary artery, congenital LCA stenosis, and so on, all of which can be differentiated by coronary angiography CT. In early childhood screening tests, it may be useful to evaluate coronary artery ostia by echocardiography, but there are no reports at present. Exercise caution as the exercise electrocardiogram might be false negative as in this case.

In the treatment of this disease, maintaining blood flow to the LCA and conservation of left heart function are important. Many symptomatic patients are resistant to medical treatment and may be indicated for aggressive coronary artery bypass.^{4,6} Although the long-term prognosis of coronary artery bypass grafting for this disease is

unknown, it has been reported that internal mammary artery (IMA)–LAD anastomosis in paediatric patients showed favourable results.^{7–9} However, Sato et al.¹⁰ report that only one IMA is not enough to return blood flow to the left ventricular myocardium. Because the present patient was symptomatic and was still growing, and LCX was slightly hypoplastic, two IMAs were used and anastomosed to LAD and D1, respectively.

Many causes of sudden cardiac death are due to fatal arrhythmia, and secondary prevention by ICD is highly recommended. However, it is controversial when the cause of fatal arrhythmia is clear and amelioration can be expected by revascularization. In recent years, less invasive devices such as subcutaneous ICD and WCD have become available and may be a treatment option for young persons. In the present case, continuous cardiac rehabilitation with WCD was performed, and as a result, marked improvement of cardiac function and improved exercise tolerance were noted and three months have passed without onset of exercise-induced arrhythmia or ischaemic attack. Thus, placement of an implanted device was not performed, and post-treatment course is favourable. The patient attends a hospital once in 2 months without any symptoms and follow-up coronary angiography CT performed 18 months after operation revealed favourable bypass graft patency.

Conclusion

When a young person who is not at risk for arteriosclerosis complains of chest pain when active, rare ischaemic heart disease associated with congenital coronary artery malformation, including LMCAA, should be kept in mind when making a differential diagnosis, and contrast-enhanced coronary CT angiography is useful for making a diagnosis.

Lead author biography



Nobunari Tomura graduated from Kyoto Prefectural University of Medicine in Japan. Currently, he is doing a resident at Omihachiman Community Medical Center as cardiologist.

Supplementary material

[Supplementary material](#) is available at *European Heart Journal - Case Reports* online.

Slide sets: A fully edited slide set detailing this case and suitable for local presentation is available online as [Supplementary data](#).

Consent: The authors confirm that written consent for submission and publication of this case report including images and associated text has been obtained from the patient in line with COPE guidance.

Conflict of interest: none declared.

References

1. Maron BJ, Doerer JJ, Haas TS, Tierney DM, Mueller FO. Sudden deaths in young competitive athletes: analysis of 1866 deaths in the United States, 1980. *Circulation* 2009;**119**:1085–1092.
2. Tanawuttiwat T, O'Neill BP, Schob AH, Alfonso CE. Left main coronary atresia. *J Card Surg* 2013;**28**:37–46.
3. D'Souza TF, Samuel BP, Vettukattil JJ, Haw MP. Surgical treatment of neonate with congenital left main coronary artery atresia. *Ann Thorac Surg* 2016;**101**:352–355.
4. Koh E, Nakagawa M, Hamaoka K, Sawada T, Oga K. Congenital atresia of the left coronary ostium: diagnosis and surgical treatment. *Pediatr Cardiol* 1989;**10**:159–162.
5. Sohn S, Jang G, Choi B. Congenital atresia of the left main coronary artery in an infant. *J Zhejiang Univ Sci B* 2010;**11**:539–541.
6. Vidne BA, Nili M, Aygen M, Levy MJ. Congenital atresia of the left main coronary artery ostium. *Scand J Thorac Cardiovasc Surg* 1979;**13**:37–40.
7. Fortune RL, Baron PK, Fitzgerald JW. Atresia of the left main coronary artery: repair with left internal mammary artery bypass. *J Thorac Cardiovasc Surg* 1987;**94**:150–151.
8. Leitz KH, Oster H, Keutel J. Use of the left internal thoracic artery to correct a left main coronary atresia. *Thorac Cardiovasc Surgeon* 1987;**35**:345–347.
9. Rosenkranz ER, Murphy DJ, Cosgrove DM. Surgical management of left coronary artery ostial atresia and supravalvular aortic stenosis. *Ann Thorac Surg* 1992;**54**:779–781.
10. Sato S, Majima T, Kawaguchi T. Congenital atresia of the left main coronary artery ostium—a case suffering from ventricular tachycardia. *J Jap Ass Thor Surg* 1990;**80**:1474.