



A Comprehensive Review of Pyogenic Spondylitis Management for Neurosurgeons

Masatoshi Yunoki¹

¹Department of Neurosurgery, Kagawa Rosai Hospital, Marugame, Kagawa, Japan

Address for correspondence Masatoshi Yunoki, MD, PhD, Department of Neurosurgery, Kagawa Rosai Hospital, Marugame, Kagawa 763-8502, Japan (e-mail: yunomasato@me.com).

Asian J Neurosurg 2023;18:724–733.

Abstract

Older populations have been increasing recently, resulting in an increase in cases of pyogenic spondylitis. Neurosurgeons who frequently treat the elderly are at a higher risk of encountering this condition. Therefore, this article provides a summary of the literature and our experience to help neurosurgeons effectively manage pyogenic osteomyelitis. It is important not to rule out pyogenic spondylosis when examining a patient with back pain, even in the absence of a fever. This is because the chronic type is common, easily overlooked, and early diagnosis and treatment are crucial. Empirical antibiotics should be avoided in cases where blood culture and biopsy are negative, to prevent microbial resistance and an increase in difficult-to-treat cases. Biopsies, such as computed tomography-guided percutaneous biopsy and full endoscopic debridement and drainage, should be attempted. Currently, 6 weeks of parenteral antibiotic therapy is the main treatment for pyogenic spondylitis. Surgical treatment is recommended if this method is ineffective. However, in the early stages, full endoscopic debridement and drainage and percutaneous pedicle screw fixation are optional.

Keywords

- ▶ conservative treatment
- ▶ management
- ▶ neurosurgeons
- ▶ pyogenic spondylitis
- ▶ surgical treatment

Introduction

Pyogenic spondylitis was previously a rare infectious disease; however, its incidence is increasing owing to growing elderly and immunocompromised populations.^{1,2} Despite being an unfamiliar disease for neurosurgeons, we have diagnosed and treated 12 cases over the past 6 years in our outpatient and emergency departments under the supervision of a board-certified spinal surgeon (► **Table 1**). Through our experience, we realized the need for neurosurgeons to increase their awareness of pyogenic spondylitis to improve the prognosis.² Therefore, we performed a literature review to provide comprehensive information on the current clinical and pathogenic aspects of the disease and the available treatment options. We also summarized the essen-

tial knowledge that neurosurgeons need to correctly manage pyogenic spondylitis.

Symptoms and Clinical Characteristics of Pyogenic Spondylitis

Pyogenic spondylitis can be classified into three types on basis of the symptoms as acute, subacute, and chronic. The acute type is characterized by severe symptoms, such as high fever (> 38°C), intense pain, and malaise. The subacute type is associated with moderate symptoms, namely low-grade fever (< 38°C), moderate pain, and mild malaise. In contrast, the chronic type is associated with mild symptoms, no fever, and local pain that does not affect the patient's general condition.^{3,4} The acute type represents 49% of cases, the

DOI <https://doi.org/10.1055/s-0043-1777272>.
ISSN 2248-9614.

© 2023. Asian Congress of Neurological Surgeons. All rights reserved.

This is an open access article published by Thieme under the terms of the Creative Commons Attribution-NonDerivative-NonCommercial-License, permitting copying and reproduction so long as the original work is given appropriate credit. Contents may not be used for commercial purposes, or adapted, remixed, transformed or built upon. (<https://creativecommons.org/licenses/by-nc-nd/4.0/>)

Thieme Medical and Scientific Publishers Pvt. Ltd., A-12, 2nd Floor, Sector 2, Noida-201301 UP, India

Table 1 Summary of 14 cases of pyogenic spondylitis treated over a 7-year period.

Case	Age (years)/sex	Spinal level	History	Symptom at onset	Appearance of fever (after onset)	Interval	Kulowski classification	Microbiological diagnosis	Treatment	Outcome	FW (months)
1	37/F	L4/5	-	Lumbar pain	10 days	10 days	Subacute	Blood culture (negative)	Antibacterials (CAM, 6 weeks)	good	8
2	66/M	L3/4	-	Neck pain	4 days	7 days	Acute	Blood culture (negative)	Antibacterials (CEZ, 2 weeks; IPM/CS 4 weeks)	good	24
3	67/M	L2/3	DM	Lumbar pain	4 days	4 days	Acute	Blood culture (Streptococcus agalactiae)	Antibacterials (CEZ, 6 weeks)	good	63
4	57/M	C5/6	prostatitis	Neck pain	7 days	7 days	Subacute	Blood culture (negative)	Antibacterials (CEZ 2 weeks, CAM 4 weeks)	good	61
5	64/M	L4/5	-	Fever	Onset with fever	6 days	Acute	Blood culture (MRSA)	Antibacterials (LZD, 1 week; MINO 5 weeks)	good	52
6	48/M	L1/2	-	Back pain	-	2 months	Chronic	Blood culture (negative) FEDD (Streptococcus intermedius)	Antibacterials (CEZ, 6 weeks) FEDD	good	6
7	31/M	L5/S1	-	Lumbar pain	20 days	18 days	Subacute	Blood culture (negative)	Antibacterials (CEZ 6 weeks)	good	6
8	87/F	Th12/L1	CI, HT	Fever	Onset with fever	7 days	Acute	Blood culture (MRSA)	Antibacterials (VCM, 3 weeks; DAP, 2 weeks)	dead	-
9	77/M	C5/6	CI, HT	Neck pain	2 days	3 days	Acute	Blood culture (negative)	Antibacterials (LZD, 3 weeks, MINO 3 weeks)	good	84
10	57/F	Th11/12	DM	Back pain	3 days	3 days	Acute	Blood culture (negative) Fluoroscopic drainage (Escherichia coli)	PLF Antibacterials (CTX, 2 weeks; MINO, 4 weeks)	good	50
11	60/M	L3/4	AS	Lumbar pain	20 days	20 days	Acute	Blood culture (MSSA)	Antibacterials (ABPC, 6 weeks)	good	6
12	74/F	Th5/6	DISH DM	Back pain	-	1 year	Chronic	Blood culture (negative)	PLF Antibacterials (CEZ 2 weeks, CAM 4 weeks)	good	21

Abbreviations: ABPC, ampicillin; AS, aortic stenosis; BF, bladder fistula; CAM, clarithromycin; CEZ, cefazolin sodium; CI, cerebral infarction; CTX, cefotaxime; DAP, daptomycin; DISH, diffuse idiopathic skeletal hyperostosis; DM, diabetes mellitus; F, female; FEDD, full endoscopic discectomy and drainage; FW, follow-up; HT, hypertension; LZD, linezolid; M, male; MINO, minocycline; PLF, posterolateral fusion; VCM, vancomycin. "Interval" refers to the time from symptom onset to diagnosis.

Table 2 Classifications commonly used for pyogenic spondylitis

A: Kulowski classification		
Acute type	High-grade fever, severe back or neck pain	46%
Subacute type	Low-grade fever (< 38°C), slowly-progressive mild pain over the affected area	25%
Chronic type	No fever with chronic back or neck pain	29%
B: Griffiths classification		
Stage I	Early stage	Narrowing of the disc space
Stage II	Destructive stage	Bone destruction, collapse of softened vertebra, and bone proliferation
Stage III	Osteosclerotic stage	New bone formation and osteosclerotic changes
C: Classification of MRI findings		
Stage I	Bruising and localized radiolucency in the vertebral endplate	
Stage II	Vertebral edema and/or suspected fluid collection within the vertebral body (inhomogeneously increased signal intensity on MRI with disc space narrowing) at one or two vertebral levels, with poor demarcation of the lesion	
Stage III	Irregularly-increased signal intensity area on MRI, with confinement of the lesion within the posterior longitudinal ligament (subligamentous)	
Stage IV	Obvious fluid collection within the disc in association with extensive endplate destruction and diffusely-extended high-signal-intensity lesions in the vertebral body, with transligamentously extended epidural mass lesions at multiple levels	
Stage V	Obvious disappearance of the disc, vertebral collapse with non-homogenous increased signal intensity within the collapsed vertebrae, epidural fluid collection in the mass lesions, and abnormally high signal intensity in the vertebrae, including the spinous processes and paravertebral ligaments as well as the muscles	

Abbreviation: MRI, magnetic resonance imaging.

A: Kulowski classification, B: Griffiths classification, C: Classification of MRI findings.

subacute type represents 25%, and the chronic type represents 29% (► **Table 2A**).^{3,4}

In our study, among the 12 cases of pyogenic spondylitis, 2 were identified as chronic cases. These individuals exhibited persistent low back pain lasting for several years, but were not correctly diagnosed earlier. This finding underscores the fact that chronic pyogenic spondylitis cases are not infrequent, and therefore, require careful consideration in clinical management.

More than 90% of patients with pyogenic spondylitis present with continuous back pain that is not relieved by rest, while fever is reported as the first symptom in 35 to 60% of cases.^{1,2} However, the presence of a fever can be affected by oral pain relievers.¹ It should be noted that fever may not be present in the early stages of both chronic and acute types of pyogenic spondylitis.¹

Of the 12 cases we encountered, 7 (58.3%) were classified as the acute type, 3 (25.0%) as the subacute type, and 2 (16.7%) as the chronic type in accordance with Kulowski's classification.³ Nine of the 12 acute and subacute cases developed lower back pain and posterior neck pain, with an average fever onset of 7.0 ± 7.5 days after the start of symptoms (► **Table 1**).

When a patient complains of back pain, pyogenic spondylitis should not be excluded even if there is no fever. Especially in the early stages, fat-suppressed imaging, which

is highly sensitive for pyogenic spondylitis, should be included in magnetic resonance imaging (MRI).^{5,6}

Epidemiology and Risk Factors

Pyogenic spondylitis has an incidence of approximately 2.4 cases per 100,000 people, although reported data show some variability.^{1,7,8} The incidence appears to be increasing, possibly owing to improved life expectancy among patients with chronic debilitating conditions.^{1,8} Risk factors comprise conditions such as diabetes mellitus, substance abuse, human immunodeficiency virus infection, renal failure, septicemia, and the long-term use of steroids.⁵ Approximately 95% of pyogenic spondylitis cases involve the vertebral bodies and/or intervertebral discs, while only 5% are associated with the posterior elements of the spine.⁸ The disease mainly affects adults, particularly those in their fifth decade of life, and the incidence increases with age.^{8,9} Men are more likely to develop the disease than women, with a ratio of 1.5 to 3:1.^{8,9} The most common site is the lumbar spine (45–50%), followed by the thoracic (35%), cervical (3–20%), and sacral areas.^{5,8,9} *Staphylococcus aureus* and *Streptococcus* species account for more than 50% of the microorganisms that cause pyogenic spondylitis.^{7,10} The causative bacteria of pyogenic spondylitis tend to vary depending on the underlying disease; for example,

Escherichia coli and *Proteus* tend to be present in patients with urinary tract infections.¹¹ Gram-negative bacilli are frequently isolated in intravenous drug abusers.⁸ Less toxic microorganisms, such as coagulase-negative *Staphylococcus* and *Streptococcus viridians*, can also cause pyogenic spondylitis, especially in immune-compromised patients.^{5,8} In patients with diabetes mellitus, aerobic organisms are common, and in cases of spinal trauma, these organisms can be directly inoculated.⁸ Children with sickle cell anemia may develop *Salmonella*-associated osteomyelitis.¹²

Pathophysiology

Pyogenic spondylitis is commonly caused by the hematogenous spread of bacteria.^{5,7,8} The bacteria usually enter the bloodstream through the skin, respiratory tract, genitalia, gastrointestinal tract, or oral cavity, and spread through the arteries rather than via the venous route.^{1,8} The intervertebral disc and the adjacent upper and lower vertebrae are supplied by the same segmental artery, resulting in an infection that often involves two adjacent vertebrae and an intervertebral disc.⁸

However, the pathophysiology of spinal infections differs somewhat between children and adults. In children, bacterial inoculation commonly occurs through persistent vascular channels within the disc space, and pyogenic discitis can develop after bacteremia.¹² In contrast, in adults, the disc is avascular, and bacteria invade the end-arterial arcades in the subchondral region adjacent to the disc. The infection then spreads by extending directly to the intervertebral disc through the endplate.^{8,12}

Prognosis

Pyogenic spondylitis has the potential to be life-threatening owing to the difficulty of early detection. Moreover, older patients with multiple risk factors are more susceptible to unfavorable outcomes.⁹ The reported average length of hospital stay for this condition ranges from 30 to 49 days, while the mortality rate is estimated at between 2 and 17%.¹³ Recurrence of spondylodiscitis is generally uncommon and is reported in 0 to 7% of cases.¹³ Overall, early diagnosis and initiation of appropriate management are critical in enhancing the prognosis of pyogenic spondylitis.

Diagnosis and Differential Diagnosis

Especially in the early stages, diagnosis of pyogenic spondylitis can be challenging owing to the lack of specific symptoms and signs.² The reported average duration between initial symptoms and diagnosis is between 2 and 6 months.¹³ In our 12 cases, 8 of the 10 acute and subacute cases presented with lower back pain, posterior neck pain, and fever, which diagnosed 7.0 ± 7.5 (mean \pm standard deviation) days after symptom onset.

Clinicians should combine clinical symptoms, radiological findings, blood and tissue cultures, and histopatholog-

ical findings to diagnose pyogenic spondylitis. Owing to the localized pain, it is important to consider other conditions, such as degenerative or metastatic spinal disease, disc herniation, vertebral compression fractures, ankylosing spondylitis, and reactive arthritis in the differential diagnosis.⁸

Modic type 1 changes, which manifest as anomalies characterized by reduced signal intensity on T1-weighted MRI scans, are commonly believed to be associated with segmental hypermobility and low-back pain.¹⁴ However, a previous study has proposed a bacterial etiology for Modic type 1 changes. The study found that 4.2% of patients who exhibited Modic type 1 changes were diagnosed with pyogenic spondylitis during a 2-year follow-up period.¹⁴ This underscores the importance of caution among physicians when differentiating between these two conditions.¹⁴

Laboratory Tests

C-reactive protein (CRP) and erythrocyte sedimentation rate (ESR) are commonly used laboratory tests to aid in the diagnosis of pyogenic spondylitis.^{1,5,8,9} CRP levels are known to be more sensitive and specific in detecting acute inflammation when compared with ESR, and they can promptly reflect the response to treatment.^{5,8} ESR levels are less sensitive and specific compared with CRP and may not reflect changes as quickly.^{1,5,8,15} Despite the slower fluctuation pattern of ESR, this test still provides supplementary information regarding the potential presence of infection and some insight into the response to treatment.¹⁵ It is important to note that laboratory tests should not be used in isolation to diagnose pyogenic spondylitis. These tests should be used in combination with clinical and radiological findings to arrive at a diagnosis.

Plain Radiography

Plain radiography is recommended for all individuals suspected of having pyogenic spondylitis. However, its diagnostic accuracy may be limited in the early stages, as changes may not be detectable until 2 to 8 weeks after the onset of symptoms.¹¹ These changes usually include disc space narrowing, blurring of the endplates, and a loss of height in the affected vertebral bodies.^{5,8} Soft tissue extension is less common in pyogenic spondylitis than in tuberculosis infections, but may be indicated by an abnormal psoas shadow, widening of the mediastinum, or enlargement of the retropharyngeal space.^{5,8} Radiographic stages of bone destruction have been classified into the early stage (narrowing of the disc space), destructive stage (bone destruction, collapse of softened vertebrae, and bone proliferation), and osteosclerotic stage (new bone formation and osteosclerotic changes) (– Table 2B).¹⁶

MRI

In 1985, Modic et al first reported the diagnostic potential of MRI for pyogenic spondylitis, and since then, numerous authors have confirmed these findings.¹⁷ T1-weighted images demonstrate a decrease in signal intensity of the

vertebral body, endplate, and intervertebral disc, while T2-weighted images show an increase in signal intensity of the vertebral body and/or disc.^{18,19} Fat suppression techniques, particularly short T1 inversion recovery, have the highest sensitivity for detecting increased water content in infected tissue.^{18,19} Various studies have described the typical pathological progression of pyogenic lesions in the vertebrae, resulting in a five-stage classification system based on MRI findings.²⁰ The enhancement pattern of the suspected septic lesion is particularly noteworthy (►Table 2C).^{20,21}

Although the diagnosis of pyogenic spondylitis can be challenging in the early stages using X-ray, computed tomography (CT), or MRI, Smids et al reported that MRI has a sensitivity of 82% and specificity of 83% for detecting pyogenic spondylitis after 14 days of onset, whereas the sensitivity and specificity within 14 days of onset were 50 and 86%, respectively.¹⁸ 18F-fluorodeoxyglucose positron emission tomography-CT is more effective than MRI in the early diagnosis of suppurative spondylitis, with a sensitivity of 96% and specificity of 95%.¹⁸ If a patient with low back pain has elevated CRP levels, pyogenic spondylitis should be suspected, and lumbar MRI should be performed. If the lesion is not diagnosed, a thorough examination for other conditions, such as urinary tract infection, should be performed. If no other heat source

is identified, repeat MRI should be performed.²² Pyogenic spondylitis should not be ruled out simply because the patient is afebrile or shows no abnormal lesions on MRI (►Fig. 1).

Illustrative case 1: An example of acute pyogenic spondylitis characterized by the absence of fever and abnormal MRI findings during the initial 3 weeks of onset.

The patient, a 60-year-old man, presented with severe lumbar pain; however, lumbar radiography and MRI showed no significant abnormalities except for mild disc herniation at L4/5 (►Fig. 2A and B). Conservative treatment was initiated, but the pain worsened gradually. Three weeks later, the patient visited the emergency room with a fever of 39°C, and repeat MRI revealed pyogenic spondylitis at L3/4 (►Fig. 2C). CT revealed bone erosion of the intervertebral endplate at this level, leading to a diagnosis of pyogenic spondylitis (►Fig. 2D). Blood culture confirmed the presence of methicillin-sensitive *Staphylococcus aureus*, and a 6-week course of antibiotics was administered, resulting in the resolution of the back pain, fever, and inflammation. The patient was discharged from the hospital and remained recurrence-free for 6 months. Notably, the patient did not have diabetes or any known risk factors for pyogenic spondylitis. Although he visited a cardiology department, no apparent etiology for pyogenic spondylitis was identified.

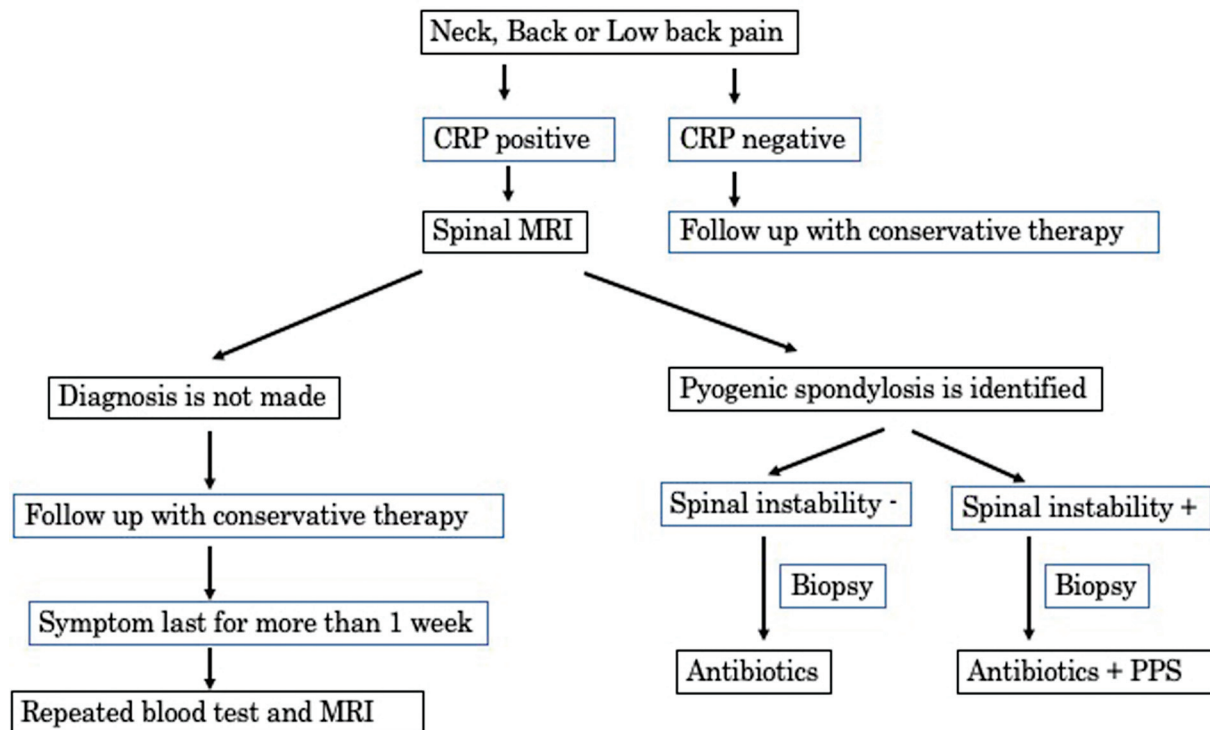


Fig. 1 Algorithmic approach for diagnosing and managing suspected cases of pyogenic spondylitis in our department. When a patient presents with cervical or lumbar back pain and elevated CRP, the presence of pyogenic spondylitis is considered. In such cases, lumbar MRI is performed. If spinal instability is evident or antibiotics are ineffective, PPS fixation is considered. Even if the initial MRI does not reveal the presence of pyogenic spondylitis, further testing, such as blood tests and spinal MRI, are recommended if the symptoms persist for 1 week. CRP, C-reactive protein; MRI, magnetic resonance imaging; PPS, percutaneous pedicle screw.

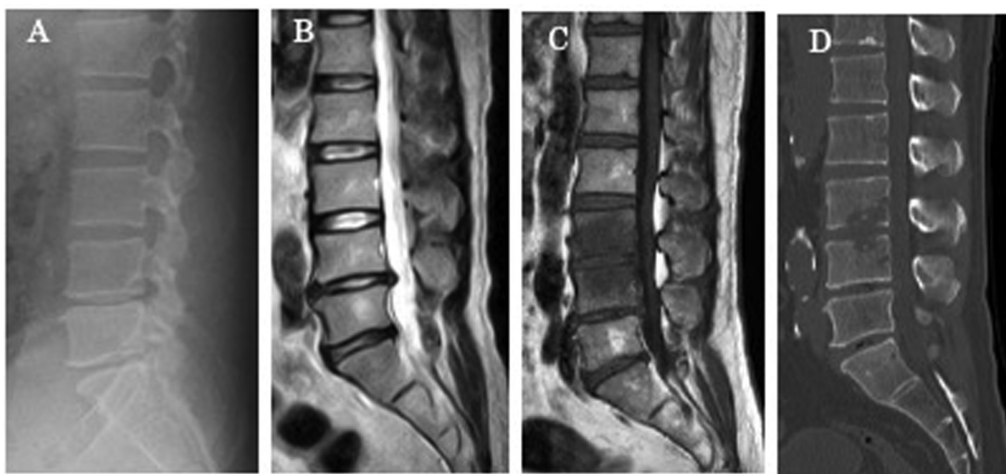


Fig. 2 Radiological findings in a case of acute type pyogenic osteomyelitis in which neither fever nor abnormal radiological findings were noted at symptom onset. (A, B) Sagittal T2-weighted magnetic resonance image (MRI) and lumbar X-ray at onset demonstrating no abnormal findings except for mild L4/5 disc herniation. (C, D) When the patient visited our emergency department because of a fever of 39°C 3 weeks after symptom onset, T1-weighted sagittal MRI (C) demonstrated low-intensity signals in the L3/4 vertebral bodies, and computed tomography revealed bone erosion of the L3/4 intervertebral endplate (D).

Blood and Tissue Cultures

The primary diagnostic approach for pyogenic spondylitis entails performing a blood culture, as it enables the possibility of growth of the causative organism within the blood culture medium.^{12,13} Positive blood cultures are often observed in acute cases, although some authors have reported blood culture-positive cases in chronic cases as well.²³ If the causative microorganism cannot be determined through blood culture, biopsy of the inflamed tissue is performed.^{7,15,23} The causative organism is identified in only 15 to 50% of cases owing to low recognition of pyogenic spondylitis among clinicians and the administration of antibiotics before diagnosis.²⁴ In our case series, the overall bacteriological identification rate was 50%, which is acceptable compared with previous reports. When blood culture and biopsy are negative and withholding antibiotics is clinically safe, biopsy is recommended. Fluoroscopic, CT-guided percutaneous biopsy and full endoscopic debridement and drainage (FEDD) are optional.²⁵

Empirical antibiotics are administered without a biopsy in negative blood culture cases, especially in less severely-affected patients, because bacterial biopsies are somewhat invasive. More than half of the causative organisms are *Staphylococci*; therefore, first-generation cephalosporin antibiotics are usually used empirically even if the organism remains undetermined.^{5,8} In our case series, in the negative blood culture cases, empirical antibiotics were administered without a biopsy. Nonetheless, unwarranted utilization of antibiotics may contribute to the occurrence of difficult-to-treat cases such as methicillin-resistant *Staphylococcus aureus* (MRSA), resulting in prolonged hospitalization, escalated expenses, and detrimental impacts on prognosis.^{5,8} Unless the patient becomes septic or critically ill, empirical antibiotic treatment

should not be initiated before the causative organism is identified.

Treatment

Conservative treatment with appropriate antibiotics and early diagnosis can lead to successful outcomes for patients with pyogenic spondylitis.² The Infectious Diseases Society of America released the 2015 Guidelines for vertebral osteomyelitis, which recommend a 6-week course of antibiotics for conservative treatment.²⁶ At our institute, the preferred approach for treating pyogenic spondylitis comprises systemic administration of antibiotics and immobilization. During the early stages of infection, patients should continue bed rest until acute pain subsides. For infections in the thoracic or lumbar spine, rigid bracing with a thoracolumbosacral orthosis is generally used.²² However, clinicians should be mindful of the potential complications associated with bed rest, particularly in elderly patients, such as pneumonia, dementia, decubitus ulceration, deep vein thrombosis, and pulmonary embolism.²⁷

Surgical Treatment

When conservative antibacterial treatment leads to worsening neurological symptoms, progression of spinal malformations, and increased instability, surgical intervention is recommended.^{12,13} However, the guidelines do not offer a detailed and practical description of surgical treatment, nor do they examine predictors of conservative treatment-resistant purulent spondylitis.²⁶ While we have not encountered such cases, urgent decompression may be necessary in the presence of acute neurological symptoms. Even with successful antibiotic treatment, vertebral body destruction, radiculopathy, progressive kyphosis, and long-term low back pain may still occur.¹²

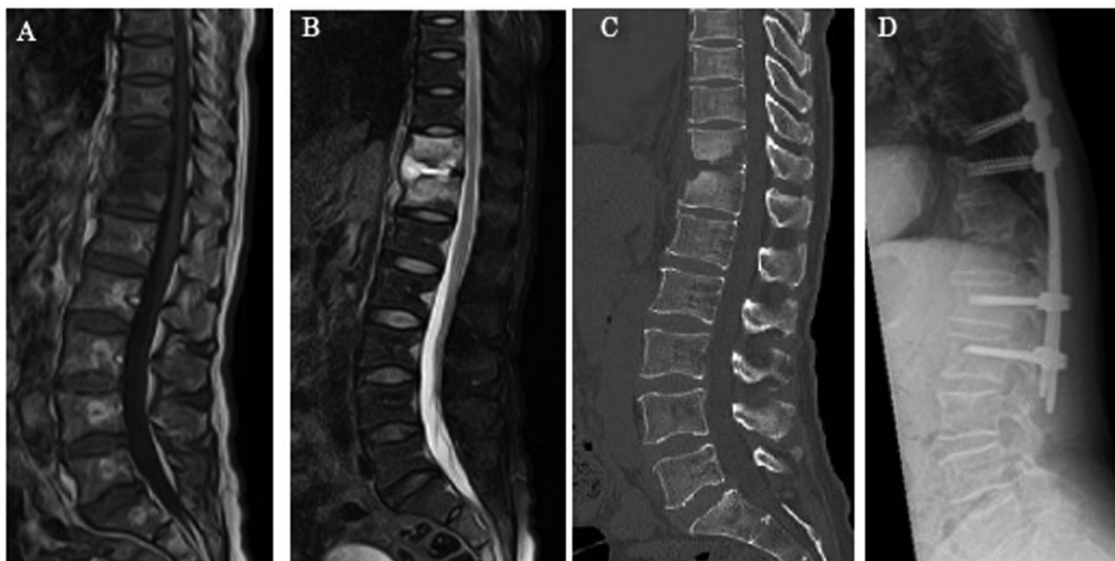


Fig. 3 Radiological findings in a case of pyogenic spondylitis in which posterior fixation was performed because spinal instability was recognized. (A) T2-weighted, fat-suppressed sagittal magnetic resonance image showing hyperintense signals at Th11/12, suggestive of pyogenic spondylitis. (B) Computed tomography demonstrating destructive change at the Th11/12 level. (C) Lateral radiograph after percutaneous posterior (D) fixation from T9 to L2.

Recent studies indicate that surgical treatment prior to conservative treatment can shorten hospital stays and improve infection control.²⁸ Traditionally, the gold standard for surgical treatment has been anterior open debridement of infected bone and soft tissue, followed by interbody fusion with or without instrumentation.^{8,13} However, this treatment carries the disadvantage of high morbidity rates due to extensive exposure during open surgery, particularly in patients with poor nutritional and general health conditions.²⁶ Early diagnosis is crucial because early posterior fusion can avoid the need for highly invasive anterior surgery. However, for cases involving large bone defects or severe spinal deformities, anterior surgery may be necessary.

Percutaneous Pedicle Screw (PPS) Fixation

Deininger et al and Fushimi et al reported an alternative surgical treatment for pyogenic spondylitis using minimally invasive surgery, namely PPS fixation without anterior debridement.^{29,30} These studies demonstrated that local stabilization is crucial for the treatment of spinal infection and can eliminate the need for additional surgical debridement and bone grafting. Additionally, PPS fixation results in less intraoperative blood loss, shorter operative time, reduced postoperative pain, and less opioid consumption compared with traditional open posterior instrumentation approaches.²² Minimally invasive surgery should be considered in cases where bone destruction or instability is severe, or when the efficacy of antibiotics is low. However, PPS requires general anesthesia, which raises concerns about the reduced range of motion of the spinal column,

spread of infection to implants, implant loosening and breakage, and the high cost of the implants.

Illustrative Case 2: A Case of Acute Suppurative Spondylitis Treated with PPS Fixation

A 57-year-old woman with a history of diabetes mellitus presented with severe low back pain that had begun 3 days earlier. She was referred to our department following lumbar spine MRI by a local physician, which revealed abnormal findings. On admission to our hospital, the patient presented with a fever of 38.5°C. MRI demonstrated hypointensity of the Th11/12 vertebrae on T1-weighted imaging and hyperintensity on fat-suppressed T2-weighted imaging (→Fig. 3A and B). CT revealed osteolysis at Th11/12 (△) (→Fig. 3C). Blood culture identified methicillin-susceptible *Staphylococcus aureus*, leading to a diagnosis of acute pyogenic spondylitis. Three days after admission, the patient underwent PPS (→Fig. 3D) and received 6 weeks of antibiotic therapy following bacterial identification. She was discharged from the hospital with resolved back pain and decreased inflammatory marker levels compared with preoperative levels.

FEDD

FEDD is a minimally invasive surgery for pyogenic spondylitis that involves lesion curettage under local anesthesia and fluoroscopy. Although good treatment results have been reported, this procedure may result in inadequate lesion curettage owing to blind treatment under fluoroscopy.²⁴

FEDD is considered reasonable for pyogenic spondylitis. Debridement by FEDD can permit the collection of

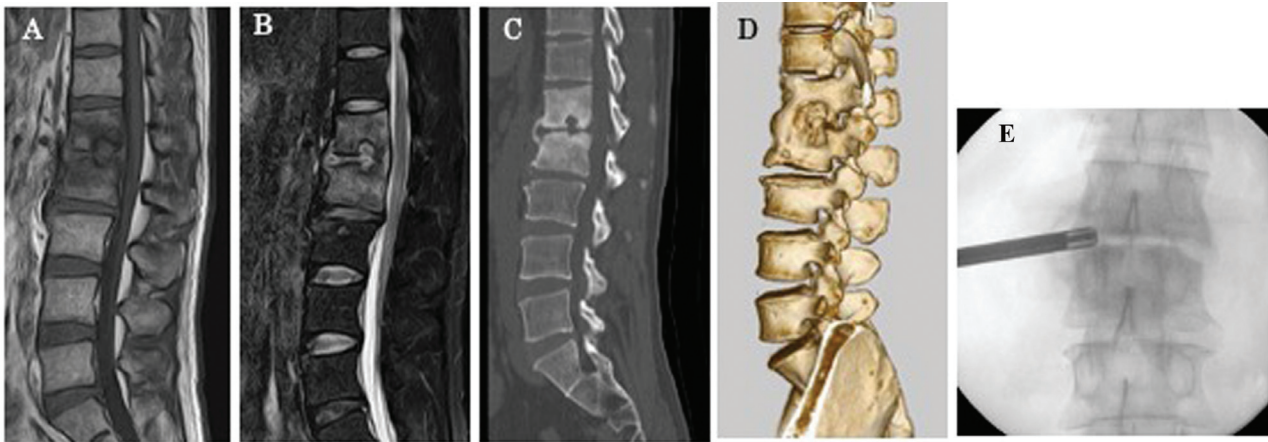


Fig. 4 (A) Radiological findings in a case of chronic pyogenic spondylitis diagnosed by full endoscopic discectomy and drainage (FEDD). T1-weighted sagittal magnetic resonance image (MRI) on admission showing hypointense signals in the L2/3 vertebral bodies and the disc space. (B) T2-weighted fat-suppressed sagittal MRI showing hyperintense signals in the L2/3 vertebral bodies and the disc space. Computed tomography (CT), sagittal (C) and three-dimensional CT images, (D) showing bone erosion of the intervertebral endplates and reactive osteosclerosis of L2 and L3. The presence of anterior vertebral fusion is clearly demonstrated, which suggests that this pathology had a chronic course. (E) Suspecting the chronic form of pyogenic spondylitis, FEDD was performed, and the causative organism was identified.

intraoperative specimens, increasing the likelihood of identifying the causative organism and demonstrating its effectiveness.³¹ There are only a limited number of reports describing the concurrent use of minimally invasive debridement and fusion techniques. However, Saito et al demonstrated the successful treatment of recalcitrant MRSA pyogenic spondylitis through the combined use of PPS fixation and FEDD.³²

Illustrative Case 3: A Case of the Chronic Type of Pyogenic Spondylitis Treated Using FEDD

The patient was a 48-year-old man who experienced mild back pain for several years, which had worsened over the past 2 months. He consulted his local doctor, and MRI

revealed an abnormal finding at L1/2, prompting a referral to our department. On admission, he had no fever but showed a mild inflammatory response on blood tests (CRP: 2.6 mg/dL and white blood cell count: 9800 / μ L). MRI showed hypointensity at L1 and L2 on T1-weighted images and hyperintensity on fat-suppressed T2-weighted images, indicating chronic pyogenic spondylitis (**Fig. 4A and B**). CT confirmed bony fusion between L1 and L2 and osteolysis of the terminal plate (**Fig. 4C and D**). Although no bacteria were detected in the blood culture, FEDD revealed the presence of *Streptococcus intermedius* (**Fig. 4D**). The patient received a 6-week course of antibiotics, resulting in the resolution of the initial signs of inflammation, and he was then discharged from the hospital.

Table 3 A concise overview of the essential information for neurosurgeons to effectively manage pyogenic spondylitis

On the basis of the symptoms, pyogenic spondylitis is classified into three types as acute, subacute, and chronic (Chronic cases in particular are not well known and are easily overlooked; however, they also require early diagnosis and appropriate treatment)
Fever is the first reported symptom in 35–60% of cases (In patients with back pain, the possibility of pyogenic spondylitis should not be ruled out because of the absence of a fever)
The sensitivity and specificity of MRI for detecting pyogenic spondylitis are 50 and 86%, respectively, within 14 days of onset, which are lower than the rates 14 days after symptom onset (Pyogenic spondylitis should not be ruled out simply because no abnormal lesions are detected on MRI)
The identification rate of the causative organism is 15–50% (Antibiotics should not be administered before the diagnosis is made. In cases in which the blood cultures are negative, biopsy should be attempted before empirical antibiotics are administered)
Surgical treatment should be performed when conservative treatment is ineffective. However, early surgery is recommended when there is instability. (Recently, FEDD and PPS fixation have been used in combination as early surgery.)

Abbreviations: FEDD, full endoscopic discectomy and drainage; MRI, magnetic resonance imaging; PPS, percutaneous pedicle screw.

In our series of cases, only two patients required surgical intervention, both of whom achieved resolution through posterior fixation. There were no instances where anterior surgery was necessary, even in cases of anterior vertebral body destruction or instability. It is crucial to further explore which cases require anterior surgery, as this is an invasive procedure. To address this issue, we performed a comprehensive literature review to consolidate current knowledge on the clinical, pathogenic, and therapeutic aspects of pyogenic spondylitis. Drawing from our review and clinical experience, we have summarized the key considerations for neurosurgeons in managing pyogenic spondylitis, in ▶ **Table 3**.

Conclusion

As the numbers of elderly and immunocompromised patients continue to increase, neurosurgeons are increasingly encountering cases of pyogenic spondylitis. This review provides a comprehensive overview of the disease on the basis of our own cases and the existing literature. To appropriately manage patients with pyogenic spondylitis, it is crucial to understand the clinical features and pathogenesis of the disease and to be knowledgeable about the available treatment options.

Conflict of Interest

The authors have no personal, financial, or institutional conflicts of interest regarding any of the drugs, materials, or devices in this article. The authors who are members of the Japan Neurosurgical Society (JNS) have registered online and completed the self-reported COI Disclosure Statement Forms through the JNS members' Website.

Acknowledgment

We thank Jane Charbonneau, DVM from Edanz (<https://jp.edanz.com/ac>) for editing a draft of this manuscript.

References

- Marchionni E, Marconi L, Ruinato D, Zamparini E, Gasbarrini A, Viale P. Spondylodiscitis: is really all well defined? *Eur Rev Med Pharmacol Sci* 2019;23(2, Suppl):201–209
- Asamoto S, Doi H, Kobayashi N, et al. Spondylodiscitis: diagnosis and treatment. *Surg Neurol* 2005;64(02):103–108, discussion 108
- Kulowski J. Pyogenic osteomyelitis of the spine, an analysis and discussion of 102 cases. *J Bone Joint Surg Br* 1936;18:343–364
- Puig Guri J. Pyogenic osteomyelitis of the spine. *J Bone Joint Surg Am* 1946;28:29–39
- Sato K, Yamada K, Yokosuka K, et al; RESEARCH GROUP FOR SPINE AND SPINAL CORD DISORDERS (HONNEKAI) Pyogenic spondylitis: clinical features, diagnosis and treatment. *Kurume Med J* 2019;65(03):83–89
- Thrush A, Enzmann D. MR imaging of infectious spondylitis. *AJNR Am J Neuroradiol* 1990;11(06):1171–1180
- Kim NJ. Microbiologic diagnosis of pyogenic spondylitis. *Infect Chemother* 2021;53(02):238–246
- Cheung WY, Luk KD. Pyogenic spondylitis. *Int Orthop* 2012;36(02):397–404
- Jaramillo-de la Torre JJ, Bohinski RJ, Kuntz C IV. Vertebral osteomyelitis. *Neurosurg Clin N Am* 2006;17(03):339–351, vii
- Yee DKH, Samartzis D, Wong YW, Luk KDK, Cheung KMC. Infective spondylitis in Southern Chinese: a descriptive and comparative study of ninety-one cases. *Spine* 2010;35(06):635–641
- Togan T, Azap OK, Durukan E, Arslan H. The prevalence, etiologic agents and risk factors for urinary tract infection among spinal cord injury patients. *Jundishapur J Microbiol* 2014;7(01):e8905
- Tsantes AG, Papadopoulos DV, Vrioni G, et al; World Association Against Infection In Orthopedics And Trauma W A I O T Study Group On Bone And Joint Infection Definitions. Spinal infections: an update. *Microorganisms* 2020;8(04):476
- Zarghooni K, Röllinghoff M, Sobottke R, Eysel P. Treatment of spondylodiscitis. *Int Orthop* 2012;36(02):405–411
- Ohtori S, Koshi T, Yamashita M, et al. Existence of pyogenic spondylitis in Modic type 1 change without other signs of infection: 2-year follow-up. *Eur Spine J* 2010;19(07):1200–1205
- Skaf GS, Domloj NT, Fehlings MG, et al. Pyogenic spondylodiscitis: an overview. *J Infect Public Health* 2010;3(01):5–16
- Griffiths HE, Jones DM. Pyogenic infection of the spine. A review of twenty-eight cases. *J Bone Joint Surg Br* 1971;53(03):383–391
- Modic MT, Feiglin DH, Piraino DW, et al. Vertebral osteomyelitis: assessment using MR. *Radiology* 1985;157(01):157–166
- Smids C, Kouijzer IJ, Vos FJ, et al. A comparison of the diagnostic value of MRI and ¹⁸F-FDG-PET/CT in suspected spondylodiscitis. *Infection* 2017;45(01):41–49
- Maamari J, Tande AJ, Diehn F, Tai DBG, Berbari EF. Diagnosis of vertebral osteomyelitis. *J Bone Jt Infect* 2022;7(01):23–32
- Uchida K, Nakajima H, Yayama T, et al. Epidural abscess associated with pyogenic spondylodiscitis of the lumbar spine; evaluation of a new MRI staging classification and imaging findings as indicators of surgical management: a retrospective study of 37 patients. *Arch Orthop Trauma Surg* 2010;130(01):111–118
- Chen HC, Tzaan WC, Lui TN. Spinal epidural abscesses: a retrospective analysis of clinical manifestations, sources of infection, and outcomes. *Chang Gung Med J* 2004;27(05):351–358
- Nasto LA, Colangelo D, Mazzotta V, et al. Is posterior percutaneous screw-rod instrumentation a safe and effective alternative approach to TLSO rigid bracing for single-level pyogenic spondylodiscitis? Results of a retrospective cohort analysis. *Spine J* 2014;14(07):1139–1146
- Skaf GS, Kanafani ZA, Araj GF, Kanj SS. Non-pyogenic infections of the spine. *Int J Antimicrob Agents* 2010;36(02):99–105
- Nagata K, Ohashi T, Ariyoshi M, Sonoda K, Imoto H, Inoue A. Percutaneous suction aspiration and drainage for pyogenic spondylitis. *Spine* 1998;23(14):1600–1606
- Yu CH. Full-endoscopic debridement and drainage treating spine infection and psoas muscle abscess. *J Spine Surg* 2020;6(02):415–423
- Berbari EF, Kanj SS, Kowalski TJ, et al; Infectious Diseases Society of America. 2015 Infectious Diseases Society of America (IDSA) Clinical Practice Guidelines for the Diagnosis and Treatment of Native Vertebral Osteomyelitis in Adults. *Clin Infect Dis* 2015;61(06):e26–e46
- Yoshimoto M, Takebayashi T, Kawaguchi S, et al. Pyogenic spondylitis in the elderly: a report from Japan with the most aging society. *Eur Spine J* 2011;20(04):649–654
- Tsai TT, Yang SC, Niu CC, et al. Early surgery with antibiotics treatment had better clinical outcomes than antibiotics treatment alone in patients with pyogenic spondylodiscitis: a retrospective cohort study. *BMC Musculoskelet Disord* 2017;18(01):175

- 29 Deininger MH, Unfried MI, Vougioukas VI, Hubbe U. Minimally invasive dorsal percutaneous spondylodesis for the treatment of adult pyogenic spondylodiscitis. *Acta Neurochir (Wien)* 2009;151(11):1451–1457
- 30 Fushimi K, Miyamoto K, Fukuta S, Hosoe H, Masuda T, Shimizu K. The surgical treatment of pyogenic spondylitis using posterior instrumentation without anterior debridement. *J Bone Joint Surg Br* 2012;94(06):821–824
- 31 Fu TS, Chen LH, Chen WJ, Tsai-Sheng Fu. Minimally invasive percutaneous endoscopic discectomy and drainage for infectious spondylodiscitis. *Biomed J* 2013;36(04):168–174
- 32 Saito D, Ono K, Kotani N, Itou T, Majima T. Combined full-endoscopic debridement and drainage, and minimally invasive spine stabilization for MRSA pyogenic thoracic spondylitis. *J Spine Res* 2021;12:1002–1006