



Since January 2020 Elsevier has created a COVID-19 resource centre with free information in English and Mandarin on the novel coronavirus COVID-19. The COVID-19 resource centre is hosted on Elsevier Connect, the company's public news and information website.

Elsevier hereby grants permission to make all its COVID-19-related research that is available on the COVID-19 resource centre - including this research content - immediately available in PubMed Central and other publicly funded repositories, such as the WHO COVID database with rights for unrestricted research re-use and analyses in any form or by any means with acknowledgement of the original source. These permissions are granted for free by Elsevier for as long as the COVID-19 resource centre remains active.



IMAGES IN INTENSIVE MEDICINE

A pediatric case of severe systemic pneumatosis during airway pressure release ventilation



Un caso de neumatosis sistémica grave durante la ventilación con liberación de presión en la vía aérea

T. Ishikawa, S. Inoue*, M. Kawaguchi

Department of Anesthesiology and Division of Intensive Care, Nara Medical University, Kashihara, Nara, Japan

Available online 29 May 2020

An 8-month-old female maintained on conventional mechanical ventilation via a tracheostomy while at home was admitted to the intensive care unit of our hospital due to acute respiratory distress syndrome (ARDS). The uncuffed tracheostomy tube was replaced with a cuffed tube and airway pressure release ventilation (APRV) was initiated. Her respiratory status gradually improved over the following 2 days (Fig. 1). On the 4th day of hospitalization, the patient experienced acute respiratory deterioration; this was ultimately attributed to patient-ventilator asynchrony. APRV with higher PEEP was reinstated. On the same day, we observed sporadic hemodynamic instability and the patient developed a tense and distended abdomen. A chest-abdominal radiograph revealed free air under the diaphragm and subcutaneous emphysema with pneumothorax and pneumomediastinum (Fig. 2A). APRV was discontinued immediately and the patient was switched over to conventional PCV. The patient withstood this temporary derangement, and systemic pneumatosis resolved gradually with conservative treatment. She was ultimately weaned from mechanical ventilation at the hospital and returned to routine mechanical ventilation at home although subcutaneous emphysema persisted (Fig. 2B). In conclusion, although there are certainly benefits provided by APRV, severe lung injury may develop in pediatric patients, most notably in association with patient-ventilator asynchrony.

* Corresponding author.

E-mail address: seninoue@naramed-u.ac.jp (S. Inoue).

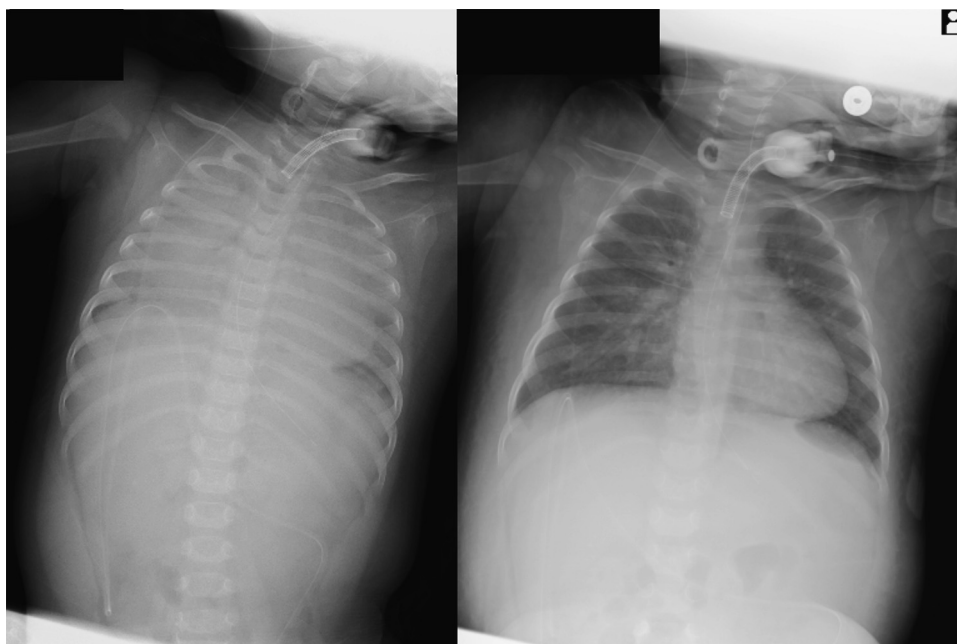


Figure 1

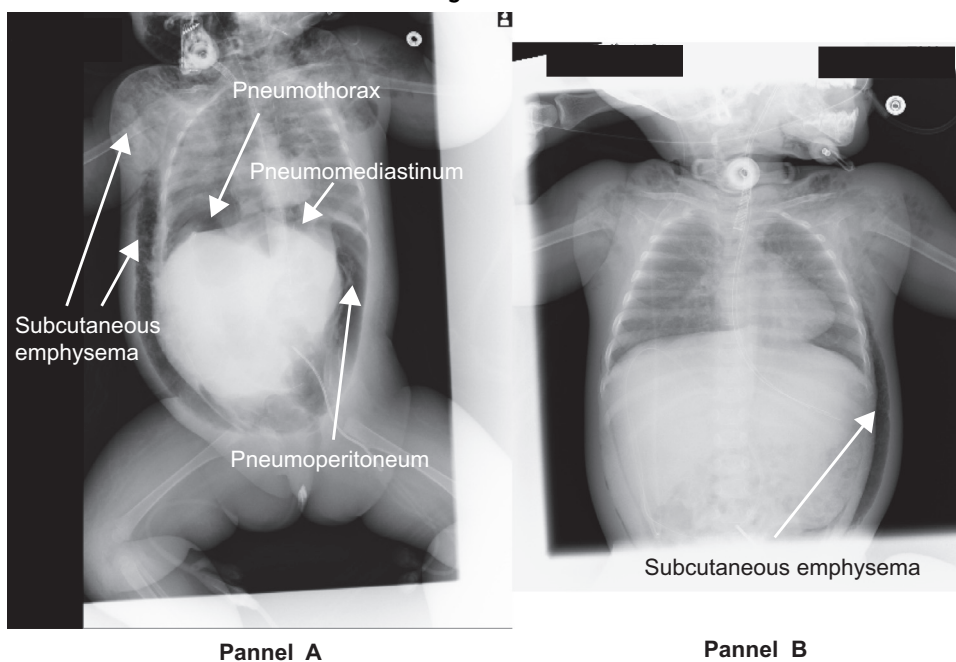


Figure 2

Authors' contributions

All authors were involved in the treatment of the patient. TI and SI collected patient data, drafted the manuscript, and obtained the consent for publication from the patient's next of kin. MK revised and edited the manuscript. All authors contributed and approved the final version.

Funding

This study was supported only by departmental funding from our institution.

Conflict of interests

The authors declare having no competing interests.