

Changes in gait parameters after femoral derotational osteotomy in cerebral palsy patients with medial femoral torsion

Ha Yong Kim, Yong Han Cha, Jae Yong Byun, Young Sub Chun and Won Sik Choy

Medial femoral torsion (MFT) is a common pathologic gait in cerebral palsy (CP) children that can be corrected by femoral derotational osteotomy (FDO). It is not clearly known as to how much various gait parameters change after FDO. The aim of this study was to quantify changes in gait parameters after FDO. The study group included 19 young CP patients (28 limbs, age < 20 years, average age: 13.2 years) with symptomatic MFT, treated with distal FDO. The study group was divided into two groups: the unilateral FDO group (UG) and the bilateral FDO group (BG). The mean degree of derotation was 24.6° (25.0° for UG, 24.4° for BG). Pre-FDO and post-FDO values of Staheli's rotational profiles and kinematic data were compared. A paired *t*-test and Pearson's correlation were used for statistical analysis. The mean internal hip rotation was 71.4 ± 6.9° before surgery and 48.6 ± 10.7° after surgery in the UG ($P < 0.05$) and it was 63.8 ± 15.8° before surgery and 40.9 ± 9.2° after FDO in the BG ($P < 0.05$). The change in the foot progression angle (FPA) was 12.9° in the UG group ($P < 0.05$) and 12.6° in the BG group ($P < 0.05$). The degree of FPA had changed by about a half of the surgical derotation angle. Changes in the mean hip rotation during gait were 14.8° in the UG ($P < 0.05$) and 6.7° in the BG ($P < 0.05$) groups. The overall pelvic rotation was not

changed after surgery. However, in patients with preoperative compensatory pelvic rotation of more than 5°, there was a change of 5.3 ± 4.8° in the UG and 6.6 ± 1.54° in the BG after surgery ($P < 0.05$). There was also a trend showing that the younger the patient, the more the pelvic rotation changed ($P = 0.069$). In-toeing gait because of MFT improved with FDO in CP patients. The expected degree of postoperative correction of FPA and hip rotation is about a half of the FDO degree. The degree of compensatory pelvic rotation should be considered to determine the correction angle of FDO, especially in young patients with preoperative pelvic rotation of more than 5°. *J Pediatr Orthop B* 27:194–199 Copyright © 2018 The Author(s). Published by Wolters Kluwer Health, Inc.

Journal of Pediatric Orthopaedics B 2018, 27:194–199

Keywords: cerebral palsy, femoral derotational osteotomy, medial femoral torsion

Department of Orthopedic Surgery, Eulji University College of Medicine, Daejeon, Korea

Correspondence to Yong Han Cha, MD, Department of Orthopedic Surgery, Eulji University College of Medicine, 1306 Dunsan-dong, Seo-gu, Daejeon 302-799, Korea
Tel: +82 42 611 3288; fax: +82 42 611 3283; e-mail: cyh@eulji.ac.kr

Introduction

In-toeing gait is a common feature of cerebral palsy (CP) children that causes poor cosmesis and function [1–3]. In-toeing is the result of abnormal muscle tone, internal torsion of the femur and tibia, and various foot deformities [4,5]. Torsional deformity of the femur or the tibia causes lever-arm disease and reduces the efficiency of muscles during walking [6]. Among these, medial femoral torsion (MFT) is the most common pathology of in-toeing gait in CP children.

Surgical correction of MFT is recommended in CP children to resolve the inefficient lever-arm of torsional deformity [1]. Femoral derotational osteotomy (FDO) could correct MFT in CP children and directly improve

the foot progression angle (FPA) and hip rotation angle in the transverse plane. In addition, it is indicated when in-toeing is principally because of MFT. Many authors have reported that various gait parameters improve or change after FDO to varying degrees [1,3,7,8]. There are, however, few papers on correlations between the amount of derotation by FDO and the degree of changes in gait parameters after FDO [9]. FDO can be performed proximally and distally. The proximal FDO is frequently performed to decrease the increased anteversion and at the same time to correct other hip problems, such as valgus angulation of femoral neck, subluxation of hip joint, and others. There may be some bias when analyzing the simple correlation between the derotation angle by proximal FDO and postoperative kinematic changes in CP patients with hip problems [1]. The aim of this study was to analyze how much the kinematic data and Staheli's rotational profiles changed after a certain degree of distal FDO in CP patients.

This is an open-access article distributed under the terms of the Creative Commons Attribution-Non Commercial-No Derivatives License 4.0 (CCBY-NC-ND), where it is permissible to download and share the work provided it is properly cited. The work cannot be changed in any way or used commercially without permission from the journal.

Patients and methods

Study population

This retrospective analysis included CP patients younger than 20 years of age who underwent distal FDO to correct MFT between 2010 and 2013. The average follow-up period was 3.8 years (2–7.5 years). The study group included 19 spastic CP patients (28 lower limbs) with the Gross Motor Function Classification System level I or II. All the patients underwent a derotational osteotomy in the distal femur. MFT and gait of the patients were evaluated with Staheli's rotational profile and gait kinematics. A preoperative evaluation was performed 1 day before surgery and a postoperative evaluation was performed 1 year after surgery. Exclusion criteria were as follows: subluxated hip, previous selective dorsal rhizotomy, and injections of botulinum toxin A in the previous 6 months. Also, CP patients who had been treated for long bone fractures or for torsional deformities in segments (tibia or foot) other than the femur were excluded.

The study group was divided into the bilateral group (BG) (nine cases, CP spastic diplegia patients) and the unilateral group (UG) (10 cases, usually CP spastic hemiplegia patients) for analysis. At the time of surgery, the mean age of the study group was 13.2 years (range: 4–20, the BG: 12.5 years, and UG: 13.9 years). There were 10 male and nine female patients in the study group. There were four male patients in the BG and six patients in the UG (Table 1).

Derotational osteotomy

All surgeries were performed by a single senior surgeon. Surgical treatment of each patient was planned according to the principles of single-event multilevel surgery by Gage or SMILE by Sussman, and various operations in different segments were performed simultaneously, including FDO (Table 1). Distal FDO was indicated for patients with symptoms and increased MFT. Patients' symptoms included tripping or a patient susceptible to fall down during walking. FDO was indicated with limited external rotation of the hip less than 15° on physical examination and hip internal rotation and internal FPA with a difference of more than 10° from the norm on kinematic data.

Preoperatively, we decided on the amount of derotation using various data such as Staheli's rotational profile, computed tomography (CT) torsional study, and kinematics of gait analysis. A CT torsional study was carried out as a routine preoperative evaluation together with the gait analysis. However, the CT torsional study was not carried out postoperatively, unlike the gait analysis, and was excluded from statistical analysis. The mean amount of derotation was 24.6° by the FDO (a mean of 25.0° for the UG and a mean of 24.4° for the BG).

Derotational osteotomy was performed at the distal femur in the supine position. The distal femur was approached on the lateral side. Two guide wires (Kirschner wire, 1.6 mm) were inserted tilted as much as the predetermined correction angle proximal and distal to

Table 1 Patients' profile in the study group

Case nos	Age	Sex	Operation (SEMLS)	Amount of FDO (deg.)	Site
1	15	Male	Left: DHR, TAL, FDO Right: DHR, Vulpius, RFT, FDO, psoas, Adductor	20/20	Both
2	14	Male	Both: STR, DHR, psoas, adductor, rectus Botox injection, FDO	30/30	Both
3	19	Female	Both FDO, DHR, RFT, TAL, SPOTT	20/25	Both
4	4	Female	Left: Vulpius, DHL, FDO Right: femur shortening, FDO	20/15	Both
5	17	Male	Both Vulpius, FDO + extension osteotomy, DHR left	15/20	Both
6	12	Female	Right: STR, TPA, DHR, FDO Left: TAL, SPLATT, psoas, Adductor, RFT, FDO, FHL lengthening	25/25	Both
7	12	Male	Both: FDO	20/20	Both
8	10	Female	Both: TAL, DHR, FDO	30/40	Both
9	10	Female	Both: STR, FDO	35/30	Both
10	11	Male	Left: TAL, lengthening of FHL and FDL, RFT, FDO	30	Left
11	20	Female	TAL, lengthening of tibialis posterior FDL FHL, SPLATT, FDO, DHR	20	Left
12	19	Male	Right: DHR, Vulpius Left: FDO with femoral shortening	20	Left
13	10	Male	Right: STR, FDO, operation for Hallux valgus	25	Right
14	11	Female	Right: TAL, TPA, DHR Left: STR, DHR, FDO	35	Left
15	14	Male	Both PLPB Right: STR, lengthening of FDL and FHL, DHR, RFT, FDO, Adductor, Kidner's procedure, Scarf osteotomy	30	Right
16	5	Male	STR, DHR, FDO	25	Right
17	17	Female	STR, DHR, FDO, adductor, calcaneus lengthening, Akin procedure, FHL lengthening	40	Right
18	19	Female	STR, SPLATT, FDO	30	Left
19	19	Male	Right: STR, DHR Left: TAL, DHR, FDO	25	Left

Adductor, Adductor tenotomy; DHR, distal hamstring release; FDL, flexor digitorum longus; FDO, femoral derotational osteotomy; FHL, flexor hallucis longus; psoas, psoas lengthening over the pelvic brim; RFT, rectus femoris transfer; SEMLS, single-event multilevel surgery; SPLATT, Split anterior tibial tendon transfer; SPOTT, split posterior tibial tendon transfer; STR, Strayer procedure; TAL, Tendo-Achilles lengthening; TPA, tibialis posterior aponeurotic lengthening.

the osteotomy site. After the osteotomy, the distal segment was externally rotated so that the two guide wires were positioned parallel to one another. Then, the osteotomy site was internally fixated using an AO locking compression plate (LCP). Narrow or broad AO LCP was chosen according to the patient's femur size. A cylinder splint was applied for 2 weeks postoperatively. Knee range-of-motion exercise was started 1 week after surgery. Partial weight bearing was allowed 2 weeks after surgery.

Evaluation of deformity

The effects of FDO were assessed by comparing preoperative Staheli's rotational profile and gait kinematics with postoperative values. Staheli's rotational profile was checked at the time of gait analysis. Among the five parameters of Staheli's rotational profile, the degree of internal and external rotation of the hip joint, which reflects the femoral torsion, was used for evaluation [10,11]. Hip rotation was measured in the prone position using a goniometer.

Gait analysis was carried out preoperatively and postoperatively. A preoperative gait analysis was carried out 1 day before the surgery and a postoperative gait analysis was carried out in patients after obtaining their informed consent when they were readmitted for the removal of internally fixated implants. The plate and screws were removed 1 year after surgery in most cases.

For gait analysis, passive reflective markers were attached using the modified Helen-Hayes method. Optical tracking of reflective markers was performed using the Eagle camera system (Eagle system; Motion Analysis, Santa Rosa, California, USA) at a capture frequency of 120 frames per second. EvaRT version 4.2 (Motion Analysis) and Orthotrak (Motion Analysis)

softwares were used for data processing to obtain kinematic data from the three-dimensional gait analysis.

Statistical analysis

We analyzed the amount of changes in various parameters after a certain amount of derotation by FDO (mean of 24.6°; 25.0° for the UG and 24.4° for the BG). The paired *t*-test was used to analyze changes in rotational profiles and kinematic data after FDO. Linear regression was used to evaluate the amount of change after derotational osteotomy. Statistical analysis of the correlation was carried out using the Pearson correlation test, with a 95% confidence interval ($P < 0.05$) for statistical significance. The SPSS (version 18.0; SPSS Inc., Chicago, Illinois, USA) program was used.

Results

Staheli's rotational profile

The mean internal hip rotation was 71.4±6.9° before surgery and 48.6±10.7° after surgery in the UG, meaning that a decrease of 22.8° occurred after surgical derotation of 25.0° ($P < 0.05$). A decrease of internal rotation in the BG was 22.9° ($P < 0.05$), with 63.8±15.8° before surgery and 40.9±9.2° after surgical derotation of 24.4°. The changes in internal rotation in both groups (22.8°, 22.9°) were almost proportional to the amount of surgical derotation (24.6°) (Table 2).

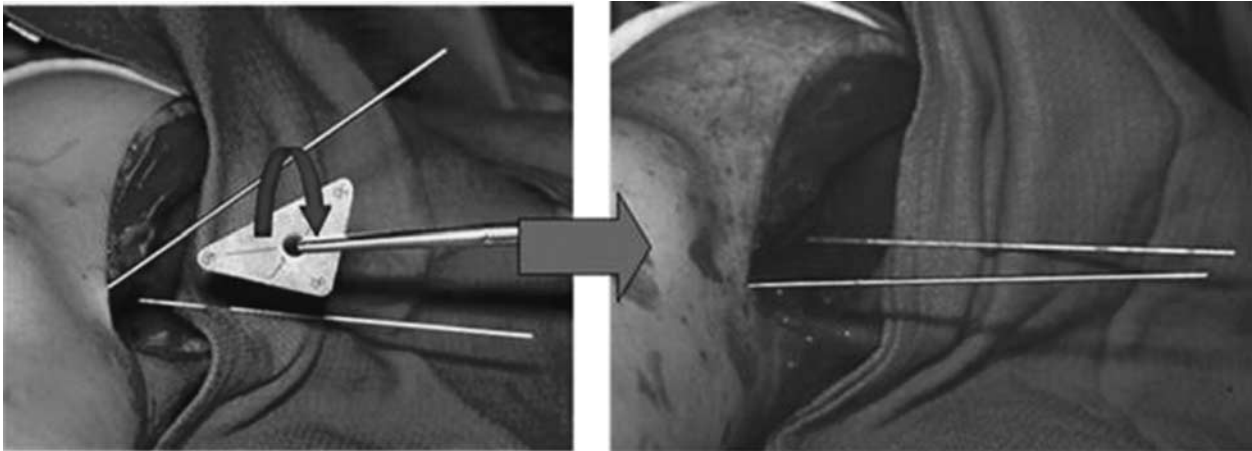
The mean external hip rotation in the UG was -14.3±15.9° before surgery and -41.4±10.3° after surgery (a minus sign denotes 'external' in this study), showing an increase of 27.1° ($P < 0.05$), which is the change almost equal to the amount of surgical derotation (25.0°). In the BG, the mean external hip rotation increased by about 16.6° ($P < 0.05$), with -32.5±14.5° before surgery and -49.1±16.4° after surgery, which is almost two-thirds of surgical derotation (24.4°).

Table 2 Postoperative changes in the rotational profile and kinematics after femoral derotational osteotomy

Parameters	Groups	Preoperative mean	Postoperative mean	Amount of changes (<i>P</i>)	Correlation		
					Linear <i>R</i>	<i>R</i> ²	<i>P</i> -value
Hip internal rotation	UG	71.4 (6.9)	48.6 (10.7)	-23.7 (0.00)	$y = 0.5x + 17$	0.4	0.95
	BG	63.8 (15.8)	40.9 (9.2)	-22.8 (0.00)	$y = 0.4x + 15$		0.00
Hip external rotation	UG	-14.3 (15.9)	-41.4 (10.3)	26.3 (0.00)	$y = 0.3x - 35$	0.8	0.21
	BG	-32.5 (14.5)	-49.1 (16.4)	16.6 (0.00)	$y = 0.9x - 21$	0.6	0.00
FPA	UG	-2.1 (11.7)	-13.8 (10.7)	-12.9 (0.00)	$y = 0.7x - 6$	0.6	0.02
	BG	3.1 (10.5)	-9.5 (6.4)	-12.6 (0.00)	$y = 0.2x - 10$	0.1	0.21
Hip rotation	UG	15.9 (20.0)	1.1 (12.0)	-14.8 (0.04)	$y = 0.04x + 4$	0.0	0.02
	BG	7.4 (8.4)	0.7 (5.5)	-6.7 (0.04)	$y = -0.2x + 2.6$	0.2	0.13
Knee rotation	UG	-12.7 (15.2)	-10.1 (13.1)	2.6 (0.78)	$y = 0.45x - 13.8$	0.4	0.27
	BG	-4.7 (10.7)	-14.3 (6.3)	-9.6 (0.00)	$y = 0.09x + 13.9$	0.0	0.58
Foot rotation	UG	-4.13 (15.1)	-5.4 (14.3)	-1.3 (0.84)	$y = -0.15x - 1.4$	0.0	0.01
	BG	2.0 (10.0)	3.0 (7.0)	1.0 (0.76)	$y = -0.02x + 3.0$	0.0	0.92
Pelvic rotation	UG	0.4 (11.2)	0.6 (12.5)	0.2 (0.86)	$y = 0.85x - 0.1$	0.8	0.01
	BG	0.5 (7.5)	0.2 (6.7)	-0.3 (0.88)	$y = 0.33x + 0.1$	0.1	0.15
PR5	UG	-	-	4.2 (0.062)	$y = 0.93x + 0.42$	0.6	0.034
	BG	-	-	6.2 (0.004)	$y = 0.34x + 0.29$	0.2	0.140
RPR	UG	-	-	-0.3 (0.87)	-	-	-
	BG	-	-	-5.8 (0.00)	-	-	-

BG, bilateral group; FPA, foot progression angle; PR5, pelvic rotation with a preoperative difference of more than 5°; RPR, range of pelvic rotation; UG, unilateral group.

Fig. 1



The distal segment was accurately derotated using two guide pins and was securely fixated using AO locking compression plate.

Gait kinematics

Foot progression angle and hip rotation

The mean FPA (a minus sign indicates 'external' for the kinematic data) was -2.1° during gait in the UG before surgery and -13.8° after surgical derotation of 25.0° ($P < 0.05$). In the BG, FPA was 3.1° preoperatively and -9.5° postoperatively ($P < 0.05$); FPA was 12.6° more outward after FDO. In both groups, FPA showed changes in parameters equal to 50% of surgical derotation.

Hip rotation during gait is a parameter directly affected by the FDO. In the UG, the mean hip rotation during gait was 15.9° before surgery and 1.1° after surgery, which meant that the hip joint was rotated more externally by 14.8° after surgical derotation of 25.0° ($P < 0.05$). The BG showed a hip rotation of 7.4° before surgery and an average of 0.7° after surgery, meaning that the hip joint rotated externally by 6.7° after derotation of the femur by 24.4° ($P < 0.05$).

Foot and knee rotation

FDO is a surgical procedure on the femur and basically it does not affect the transverse kinematics of other segments, such as foot rotation or knee rotation. In the UG, the average foot rotation (a minus sign denotes 'external' for the kinematic data) was -4.1° preoperatively and -5.4° postoperatively. In the BG, it was 2.0° before surgery and -3.0° after surgery. In both groups, foot rotation was not affected by the FDO ($P > 0.05$).

Knee rotation mostly reflects tibial torsion, and in the UG, the mean knee rotation was -12.7° before surgery and -10.1° after surgery ($P > 0.05$), which meant that it was not influenced by the FDO. However, in the BG, it was -4.7° before surgery and -14.3° after surgery, which meant that knee rotation was changed by 9.6° after FDO ($P < 0.05$).

Pelvic rotation

In the UG, the mean pelvic rotation was 0.4° preoperatively and 0.6° postoperatively ($P > 0.05$). In the BG, the mean pelvic rotation was 0.5° preoperatively and 0.2° postoperatively ($P > 0.05$). Pelvic rotation was not changed after surgery in both groups.

However, in the patients with compensatory pelvic rotation of more than 5° preoperatively, pelvic rotation showed a change of about $5.4 \pm 4.8^\circ$ in the UG and $6.6 \pm 1.5^\circ$ in the BG after surgery ($P < 0.05$). There was also a trend indicating that the younger the patient, the more the pelvic rotation changed ($P = 0.069$). The total range of pelvic rotation during gait was not meaningfully changed (16.0° – 15.7°) in the UG ($P > 0.05$). However, it showed a significant difference in the BG postoperatively (21.2° – 15.4° ; $P < 0.05$).

Complications

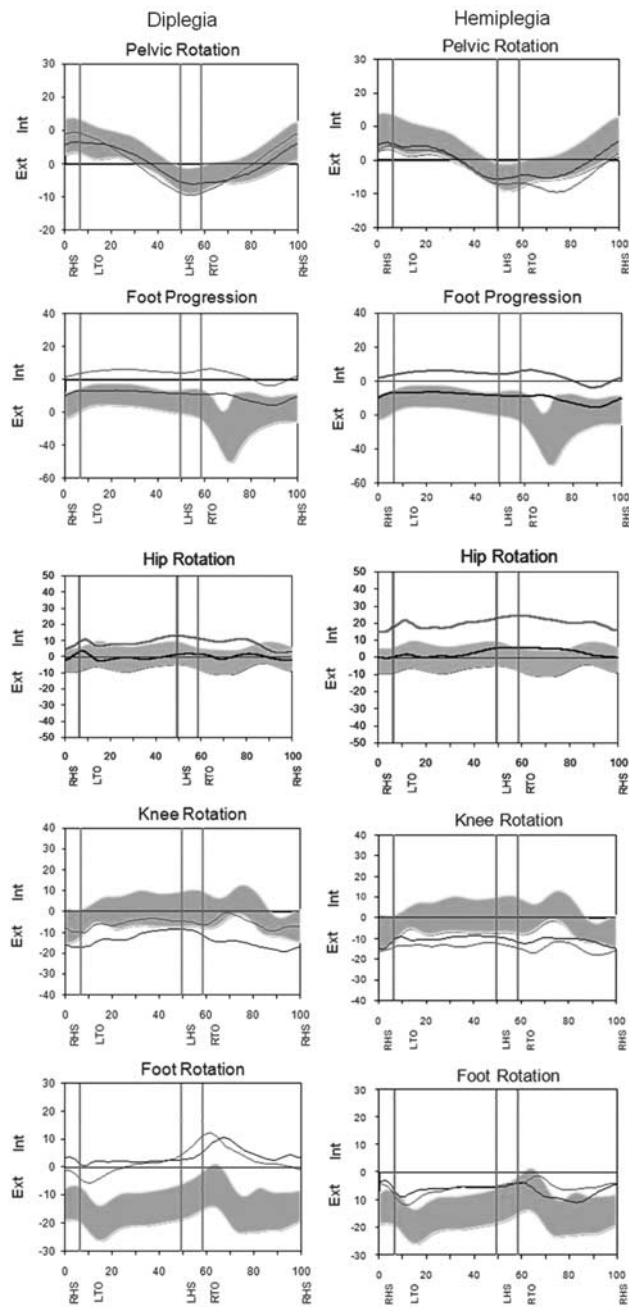
There were no complications, such as nonunion or operative wound infection, in any of the patients.

Discussion

Classifications, such as the classification of Winters and colleagues [12,13], of the pathologic gait in CP children are mostly focused on the sagittal plane. The most common pathologic gait of CP children in transverse plane is in-toeing gait caused by MFT. MFT causes lever arm dysfunction which reduces muscle efficiency by reducing the coronal plane hip abductor moment arm. And it also causes inappropriate foot clearance and tripping. [6,14].

It is well known from previous studies that MFT can be corrected with FDO. It is, however, not clear to what degree transverse gait parameters, including hip rotation, FPA, pelvic rotation, and others, are changed after surgery.

Fig. 2

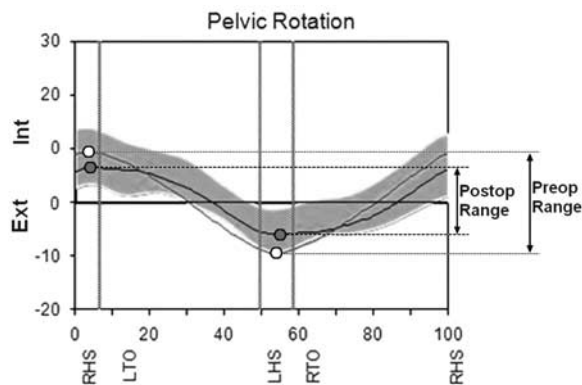


Gait parameters in the transverse plane improved to varying degrees after 24.6° of surgical derotation.

In this study, we attempted to answer these questions. FDO was performed at the distal femur and internally fixated with AO LCP. The advantage of LCP was that derotation of the distal segment could be performed accurately as planned and early rehabilitation could be started without immobilization in the long leg cast.

Parameters that are directly affected by FDO are internal and external hip rotation in Staheli's rotational profile and

Fig. 3



Ranges of pelvic rotation decreased after femoral derotational osteotomy in the bilateral group.

FPA and hip rotation in the gait analysis. Pirpiris *et al.* [1] reported that internal and external hip rotation in the prone position improved as much as the amount of FDO in CP patients, which is in agreement with this study. Chung *et al.* [15] showed that FPA improved by two-thirds of the amount of FDO after bilateral FDO in diplegic CP. In this study, FPA improved about half of the FDO in both groups. FPA improved less than the amount of FDO [15].

The change in FPA is roughly the sum of rotation changes in all the segments of lower extremity. In the UG, improvement in FPA occurred entirely at the femur (hip rotation), which was equal to half of FDO. In the BG, superficially, it appeared as if half of the FPA improvement (6.7°) took place at the femur (hip rotation) and another half of the improvement (9.6°) took place at the tibia (knee rotation) according to the kinematic data.

Knee rotation was not changed postoperatively in the UG, as expected. In the BG, knee rotation changed by as much as one-fourth of FDO, even though theoretically it should not be affected by the FDO. Transverse kinematic data of the BG were confusing as the improvement in FPA took place at the femur and tibia. This might be because of measuring error that is prone to occur in the transverse plane compared with other planes.

There are still debates on whether compensatory pelvic rotation is corrected after FDO. Some authors, including Chung *et al.* [15] and Christopher *et al.* [16], reported that pelvic rotation in spastic diplegia was not changed even after normalization of femoral torsion by FDO.

There are more debates on spastic hemiplegias. Gage *et al.* [6] reported that pelvic external rotation cannot be corrected after FDO in hemiplegic patients. He recommended a slight undercorrection during FDO for hemiplegias because of the above-mentioned reason. Meanwhile, Christopher *et al.* [16] reported that hemiplegic patients showed a significant

improvement in pelvic rotation after FDO. In this study, the overall pelvic rotation was not changed after FDO in both groups.

As the study group included many patients without compensatory pelvic rotation, we reanalyzed changes in pelvic rotation only in patients with preoperative pelvic rotation of more than 5°. In these patients, preoperatively externally rotated pelvis showed normalization of rotation after FDO in both the UG and the BG ($P < 0.05$). In addition, the degree of change tended to be larger in younger patients. These facts suggest that compensatory pelvic rotation may be corrected after FDO if the deformity is not a fixed one as in young children.

The range of pelvic rotation is a parameter that reflects the energy efficiency of ambulation. The fact that range of rotation has increased means that additional energy was used to transfer the center of gravity to achieve an adequate stride length. There was no major change in the range of rotation in the hemiplegia group (0.3° decrease, $P = 0.87$), but there was a statistically significant decrease in the diplegia group (5.8° decrease, $P < 0.05$, Figs 1–3). Therefore, a decrease in the range of pelvic motion after FDO might be an indication that FDO may improve energy efficiency during gait.

There are some limitations in this study. First, we did not analyze the effect of soft tissue procedures, such as psoas or hamstring release, and foot procedures, such as split tibialis anterior tendon transfer, heel cord lengthening, or calcaneal lengthening. However, they may mainly influence motion in the sagittal plane and seem to have a slight effect in the transverse plane. Second, two young patients (4 and 5 years old) were included in this study. This may have affected the results. Third, our results were analyzed 1 year after operation. Hence, we do not have long-term follow-up results. Further research is needed.

Conclusions and clinical significance

In-toeing gait because of MFT could be corrected with FDO. FPA and hip rotation on the kinematics were corrected and the amount of correction was about a half of the surgical derotation angle. The degree of compensatory pelvic rotation should be considered to plan the derotation and decide the correction angle. Patients with pelvic rotation larger than 5° before the surgery showed the normalization of pelvic rotation after FDO.

This phenomenon was obvious in young patients. Pelvic rotation in aged patients, whose pelvic rotation is considered to be already fixed, did not significantly change even after a surgery. Future research on FDO impact on clinical practice and the patient's quality of life is needed.

Acknowledgements

Conflicts of interest

There are no conflicts of interest.

References

- 1 Pirpiris M, Trivett A, Baker R, Rodda J, Nattrass GR, Graham HK. Femoral derotation osteotomy in spastic diplegia. Proximal or distal? *J Bone Joint Surg Br* 2003; **85**:265–272.
- 2 Dreher T, Wolf S, Braatz F, Patikas D, Doderlein L. Internal rotation gait in spastic diplegia – critical considerations for the femoral derotation osteotomy. *Gait Posture* 2007; **26**:25–31.
- 3 Ounpuu S, deLuca P, Davis R, Romness M. Long-term effects of femoral derotation osteotomies: an evaluation using three-dimensional gait analysis. *J Pediatr Orthop* 2002; **22**:139–145.
- 4 Arnold AS, Komattu AV, Delp SL. Internal rotation gait: a compensatory mechanism to restore abduction capacity decreased by bone deformity. *Dev Med Child Neurol* 1997; **39**:40–44.
- 5 Arnold AS, Liu MQ, Schwartz MH, Ounpuu S, Dias LS, Delp SL. Do the hamstrings operate at increased muscle-tendon lengths and velocities after surgical lengthening? *J Biomech* 2006; **39**:1498–1506.
- 6 Gage JR, deLuca PA, Renshaw TS. Gait analysis: principle and applications with emphasis on its use in cerebral palsy. *Instr Course Lect* 1996; **45**:491–507.
- 7 Saraph V, Zwick EB, Zwick G, Dreier M, Steinwender G, Linhart W. Effect of derotation osteotomy of the femur on hip and pelvis rotations in hemiplegic and diplegic children. *J Pediatr Orthop B* 2002; **11**:159–166.
- 8 Saraph V, Zwick EB, Zwick G, Steinwender C, Steinwender G, Linhart W. Multilevel surgery in spastic diplegia: evaluation by physical examination and gait analysis in 25 children. *J Pediatr Orthop* 2002; **22**:150–157.
- 9 Braatz F, Wolf S, Gerber A, Klotz MC, Dreher T. Do changes in torsional magnetic resonance imaging reflect improvement in gait after femoral derotation osteotomy in patients with cerebral palsy? *Int Orthop* 2013; **37**:2193–2198.
- 10 Staheli LT, Corbett M, Wyss C, King H. Lower-extremity rotational problems in children. Normal values to guide management! *J Bone Joint Surg Am* 1985; **67**:39–47.
- 11 Staheli LT. Normative data in pediatric orthopedics. *J Pediatr Orthop* 1996; **16**:561–562.
- 12 Winters TF Jr, Gage JR, Hicks R. Gait patterns in spastic hemiplegia in children and young adults. *J Bone Joint Surg Am* 1987; **69**:437–441.
- 13 Rodda J, Graham HK. Classification of gait patterns in spastic hemiplegia and spastic diplegia: a basis for a management algorithm. *Eur J Neurol* 2001; **8** (Suppl 5):98–108.
- 14 Kay RM, Rethlefsen S, Reed M, Do KP, Skaggs DL, Wren TA. Changes in pelvic rotation after soft tissue and bony surgery in ambulatory children with cerebral palsy. *J Pediatr Orthop* 2004; **24**:278–282.
- 15 Chung CY, Lee SH, Choi IH, Cho TJ, Yoo WJ, Park MS. Residual pelvic rotation after single-event multilevel surgery in spastic hemiplegia. *J Bone Joint Surg Br* 2008; **90**:1234–1238.
- 16 Carty CP, Walsh HP, Gillett JG, Phillips T, Edwards JM, deLacy M, Boyd RN. The effect of femoral derotation osteotomy on transverse plane hip and pelvic kinematics in children with cerebral palsy: a systematic review and meta-analysis. *Gait Posture* 2014; **40**:333–340.