

## Case Report

## Latarjet fracture treated with a single endobutton: A case presentation

Konstantinos Mastrantonakis<sup>\*</sup>, Charalampos Christogiannis, Dimitrios Bakaros, Georgios Velivasakis, Anastasia Garbi, Emmanouil Daskalogiannakis

Department of Orthopedics, General Hospital of Rethymnon, Rethymnon 74100, Greece

## ARTICLE INFO

**Keywords:**

Coracoclavicular ligament avulsion  
Distal clavicular fracture  
Latarjet fracture  
Endobutton  
Clavicle  
Fracture

## ABSTRACT

**Background:** Avulsion fracture of the coracoclavicular ligament accompanied by upward displacement of the medial fragment of the clavicle represents a unique fracture pattern, first described by Latarjet and colleagues in 1975. Due to the function of the underlying articulations and the ligaments found in the area, this fracture pattern results in a combination of horizontal and vertical instability that must be taken into consideration when treating. Several surgical techniques have been proposed but none has been proven superior.

**Case summary:** Herein, we present a Latarjet fracture of the distal clavicle treated with a single endobutton. A 45-year-old male underwent open surgical stabilization of distal clavicular fracture 15 days after trauma. After stabilization of the fracture, we applied a single endobutton, passing through the medial fragment, inferior fragment and coracoid process. The patient was observed for 14 mo postoperative, during which time he achieved union in all three fragments of the fracture and an excellent functional clinical score.

**Conclusion:** In Latarjet fracture treatment, augmentation of the coracoclavicular ligament is the most important parameter for a favorable result.

## Introduction

Fractures of the distal end of the clavicle represent a particular clinical entity due to the ligaments that adhere to the region. The ligaments that play an important role in this type of injury are the conoid and trapezoid ligaments that connect the coracoid process to the distal end of the clavicle, as well as the acromioclavicular (AC) ligaments. The AC ligaments form part of the joint capsule and enhance the stability of the AC articulation, especially at the horizontal plane [1]. The coracoclavicular (CC) ligaments sprout from the base of the coracoid process and rest (2–4 cm) at the distal lower end of the clavicle [2]. Their main function is to oppose upward displacement of the peripheral end of the clavicle.

Disorders of these joints can cause shoulder dyskinesia, which in turn may be a cause of pain and dysfunction in the shoulder joint. This is why surgical treatment is recommended in certain patients [3]. There are several classification systems in clinical use for subdividing these fractures, with each considering the fracture's relationship to the CC and AC ligaments; the Neer classification system is most often used. A special and rare subcategory is the Latarjet type of fracture, first described in 1975 by Latarjet et al. [4]. In fact, this type is an avulsed fracture of the CC ligaments accompanied by upward displacement of the central fragment of the clavicle.

<sup>\*</sup> Corresponding author.

E-mail address: [mastrantonakis.k@gmail.com](mailto:mastrantonakis.k@gmail.com) (K. Mastrantonakis).

Several surgical techniques have been proposed for the treatment of distal clavicular fractures, including transacromial wire fixation, Weaver-Dunn procedure, tension band wiring, CC screw fixation, plate fixation, and arthroscopic stabilization with endobuttons.

We describe herein an open procedure for stabilization of the Latarjet type fracture using a single endobutton passing through the central fragment of the clavicle and through the avulsed fragment and coracoid process.

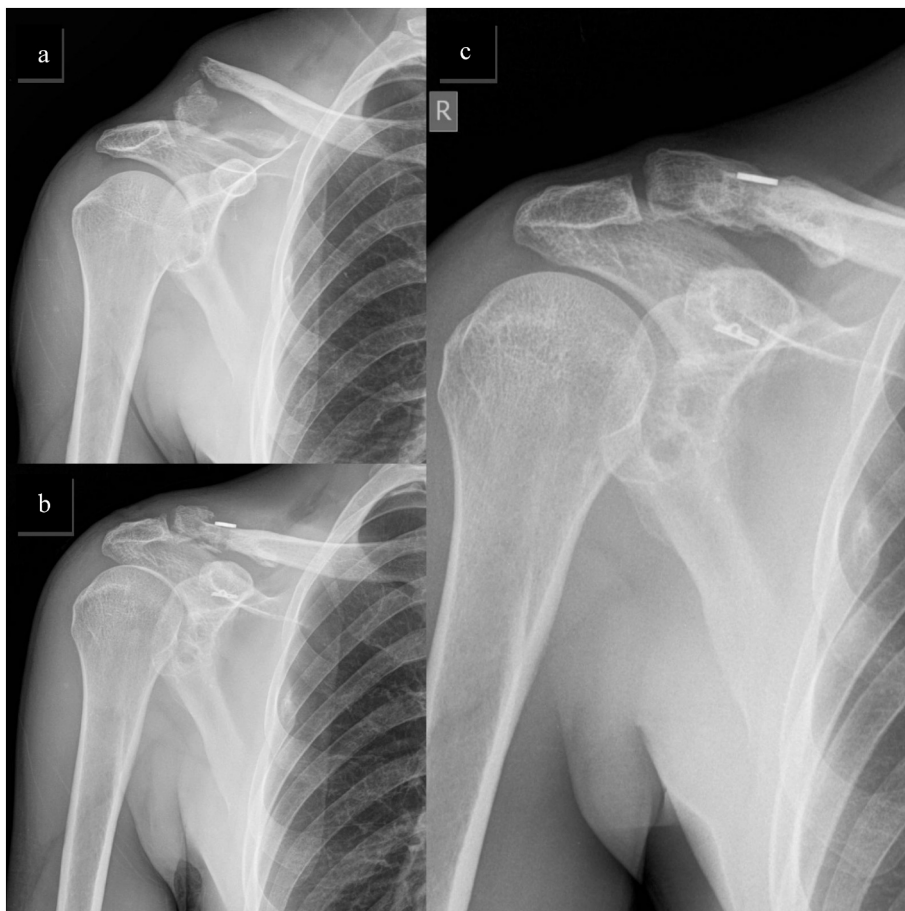### Case presentation

Case: A 45 year-old male was referred to our trauma department after a fall on outstretched right hand. On Clinical examination the patient had tenderness and edema over the distal clavicle and pain with shoulder abduction and forward flexion. The radiography revealed distal clavicle fracture (Latarjet fracture) [Fig. 1a].

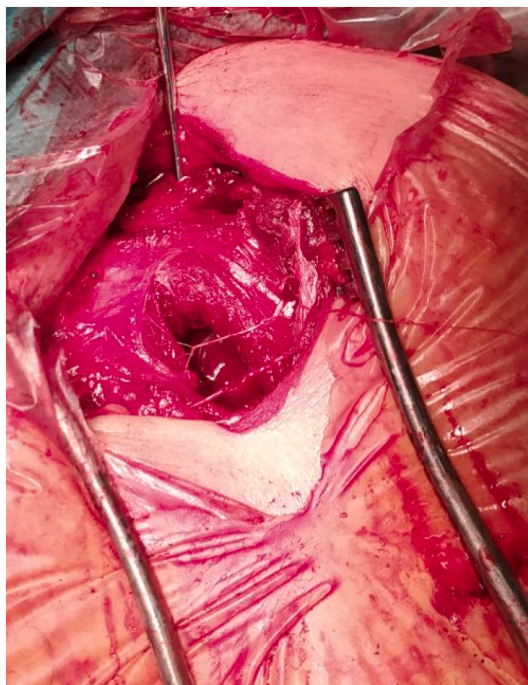
The patient underwent an open surgery for reduction of the clavicle at 15 d after the trauma event. In this, a single endobutton was passed through the clavicle, avulsed fracture and the coracoid, with the intent of providing stabilization of the fracture (Fig. 1B).

For the surgery, the patient was placed in beach chair position. A longitudinal incision was made at the distal clavicle, followed by incision to the deltotrapezial fascia to expose the distal end of the clavicle. The coracoid process was palpated and dissection of the deltoid was performed, to the right from above. A clamp was then applied for reduction of the medial fragment of the clavicle together with the avulsed inferior fragment of the CC ligaments. Next, utilizing a guide pin (Fig. 2), the clavicle and coracoid were drilled. Care was taken to pass the guide through the medial fragment and then through the center of the avulsed fragment as well as the center of the base of the coracoid process.

Under direct visualization and radiographic control, the correct placement of the pin was confirmed and a 4.5 reamer was placed over the guide pin through the clavicle and coracoid. Next, the endobutton (zip tight fixation system) was passed through the holes and ensured with pulling of the nonabsorbable sutures and tightening over the round button on the clavicle. Finally, a radiograph was



**Fig. 1.** Radiographic history of the fracture in this case. A: Latarjet fracture was diagnosed based upon the finding of an avulsed fracture of the coracoclavicular ligaments and upward displacement of the central fragment of the clavicle; B: Postoperative radiograph confirmed the endobutton passing through the medial fragment, avulsed inferior fragment and coracoid; C: Control radiograph at 18 mo after surgery showed osseous union of the fracture with alignment in acromioclavicular articulation.



**Fig. 2.** Intraoperative image showing the pin guide passing through the medial fragment, inferior fragment and coracoid process.

performed for confirmation of the reduction of the medial fragment. What was observed, was that along with the reduction of the medial with the inferior fragment, the distal part of the clavicle was reduced and there was congruence in AC articulation. In conclusion we decided not to place hardware materials on such a small and distressed distal part of the clavicle. The incision was irrigated with normal saline and the wound was closed in a normal layered fashion. Sterile dressings and a Dessault type shoulder brace was applied to the right upper limb.

### Outcome and follow-up

The immobilization by Dessault brace lasted for 4 wk. The patient attended weekly appointments for radiography screening and dressing change. The patient began physiotherapy at postoperative week 4, with passive mobilization limited to 90° of abduction for 2 wk followed by increasing active and assistive mobilization.

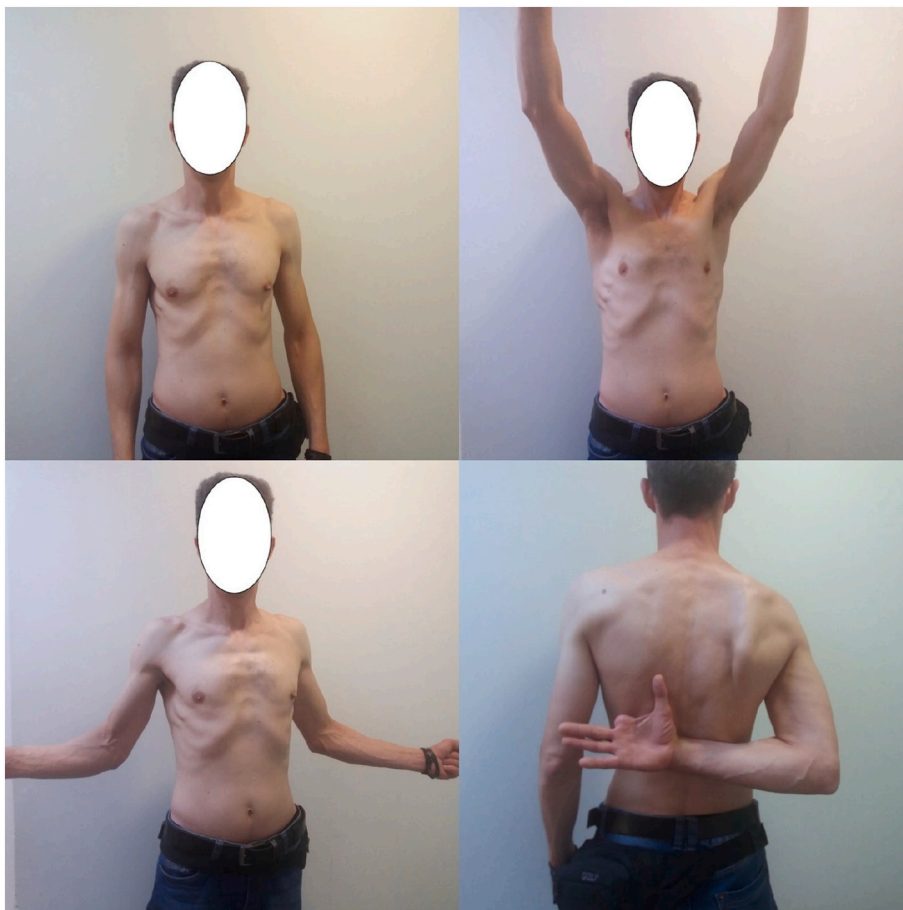The patient was observed for a total of 18 mo. At postoperative week 8, the patient had pain and limited range of motion, especially on external rotation and forward flexion. The constant shoulder score was 70, and no union of the fracture was observed on plain radiographs. At the end of the 18-mo follow-up period, the patient was pain-free, with no limitation of movement and no difference in strength compared to the contralateral side. At that time, the constant shoulder score was 100, and union was observed on radiographic screenings (Figs. 1C and 3).

### Discussion

Distal clavicle fractures represent a unique category of fracture due to the ligaments of the area and short bone length of the lateral fragment that does not allow for rational osteosynthesis methods. Numerous studies have questioned the clinical outcome of different open surgical options, like transacromial wire fixation, a modified Weaver-Dunn procedure, use of a tension band, CC screw fixation, hook plates and arthroscopic treatment. Most of them concern type II distal clavicle fractures, according to Neer's classification.

Neer [5] proposed transacromial wire fixation. However, even though this technique is one of the longest established and most commonly used, it has been associated with high incidence of complications. The Weaver-Dunn procedure has been advocated for the treatment of type II distal clavicle fracture, with excision of the lateral fragment and detachment of the coracoacromial ligament [6]. For CC screw fixation, good results were reported by Fazal et al. [7] from a study of 30 patients; nevertheless, a second procedure is required for removal of the screw and release of the rotatory movement of the clavicle. Hook plate fixation has been used in different studies, providing good union rates [8–10]; although, complications include asymptomatic osteolysis of the acromion and migration of the hook into the acromion. Alas, hook plating also requires a second procedure for plate removal. CC ligament repair with nonabsorbable suture has been reported to achieve excellent results, but all patients in those publications had Neer's type II fracture of the distal clavicle [11,12].

Suture buttons have largely been used in arthroscopic treatment of AC dislocation. In 2008, Pujol et al. [13] proposed fixation of



**Fig. 3.** Physical and functional outcomes at the end of the 18 mo follow-up period. The patient was pain-free, without restriction of range of motion, and no difference in strength compared to the contralateral arm. The constant shoulder score of the right shoulder was 100.

distal clavicular fractures with use of an arthroscopic-assisted double-endobutton. Four patients were treated with this technique, and all achieved union of the fracture and a mean constant shoulder score of 95 at 6 mo follow-up. The same author, in 2013, proposed the double-button technique for treating Latarjet fractures [14]. Arthroscopic treatment of these lesions is time consuming and a very demanding procedure but provides excellent clinical results; although, it is not superior to open surgery.

In Neer's classification type V (Latarjet) fracture, an inferior fragment remains attached to the CC ligaments, while the distal fragment forms the AC articulation and the proximal fragment migrates upwards. Separation of the inferior fragment results in a combination of horizontal and vertical instabilities, with opposing forces of the deltoid and trapezius muscles predictably displacing the fracture site. Augmentation of the CC ligament is necessary to neutralize the deforming forces and achieve union with the medial clavicular fragment.

Our preoperative plan was to stabilize the CC ligament with a single endobutton and secure both the inferior and medial fragments with a cerclage procedure using nonabsorbable suture. However, after placing the endobutton, the inferior and lateral fragments were so stable that we decided not to use the cerclage suturing procedure. We believe that the use of a second endobutton could cause fragmentation of small inferior and medial fragments, that could lead to irreversible destabilization. In addition the technique with a single endobutton and possible cerclage wiring is cheaper and easier to perform by average surgeons. The reason we didn't fix the lateral fragment was because after reduction with the endobutton we found alignment of the fragments and congruence of the AC articulation. Although we did not stabilize the lateral fragment we observed full union at the end of follow-up.

## Conclusion

Avulsion fracture involving the coracoclavicular ligament accompanied by upward displacement of the medial fragment of the clavicle represents a unique fracture pattern, known as Latarjet. The injury is difficult to manage because of the ligaments adhered to the region and small bone fragments that need to be fixed. The most important parameter for a favorable outcome is restoration of function of the coracoclavicular ligament, establishing vertical stability of the clavicle. With our case presentation, we propose an open surgery with respect to the soft tissue, which is inexpensive and easy to perform.

## References

- [1] K. Fukuda, E.V. Craig, K.N. An, R.H. Cofield, E.Y. Chao, Biomechanical study of the ligamentous system of the acromioclavicular joint, *J. Bone Joint Surg. Am.* 68 (3) (1986) 434–440 (PMID: 3949839).
- [2] K.J. Renfree, M.K. Riley, D. Wheeler, J.G. Hentz, T.W. Wright, Ligamentous anatomy of the distal clavicle, *J. Shoulder Elb. Surg.* 12 (4) (2003) 355–359, [https://doi.org/10.1016/S1058-2746\(03\)00029-6](https://doi.org/10.1016/S1058-2746(03)00029-6).
- [3] S. Oki, N. Matsumura, W. Iwamoto, H. Ikegami, Y. Kiriya, T. Nakamura, Y. Toyama, T. Nagura, The function of the acromioclavicular and coracoclavicular ligaments in shoulder motion: a whole-cadaver study, *Am. J. Sports Med.* 40 (11) (2012 Nov) 2617–2626, <https://doi.org/10.1177/0363546512458571>. Epub 2012 Sep 11. PubMed. (PMID: 22967825).
- [4] M. Latarjet, J. Michoulier, R. Kohler, Fracture of the clavicle with avulsion of the coracoid plaque. Apropos of 2 cases, *Chirurgie* 101 (4) (1975 Mar 12) 245–249, 19. (French. PubMed PMID: 1222642).
- [5] NEER CS 2nd, Fracture of the distal clavicle with detachment of the coracoclavicular ligaments in adults, *J. Trauma* 3 (1963) 99–110 [PMID: 13937900], <https://doi.org/10.1097/00005373-196303000-00001>.
- [6] K. Anderson, Evaluation and treatment of distal clavicle fractures, *Clin. Sports Med.* 22 (2) (2003) 319–326, vii, [https://doi.org/10.1016/s0278-5919\(02\)00108-4](https://doi.org/10.1016/s0278-5919(02)00108-4) (PMID: 12825533).
- [7] M.A. Fazal, J. Saksena, F.S. Haddad, Temporary coracoclavicular screw fixation for displaced distal clavicle fractures, *J. Orthop. Surg. (Hong Kong)* 15 (1) (2007) 9–11 (PMID: 17429109).
- [8] M. Kashii, H. Inui, K. Yamamoto, Surgical treatment of distal clavicle fractures using the clavicular hook plate, *Clin. Orthop. Relat. Res.* 447 (2006) 158–164, <https://doi.org/10.1097/01.blo.0000203469.66055.6a> (PMID: 16505714).
- [9] A.D. Tambe, P. Motkur, A. Qamar, S. Drew, S.M. Turner, Fractures of the distal third of the clavicle treated by hook plating, *Int. Orthop.* 30 (1) (2006) 7–10, <https://doi.org/10.1007/s00264-005-0019-1> (PMID: 16235083).
- [10] K. Muramatsu, M. Shigetomi, T. Matsunaga, Y. Murata, T. Taguchi, Use of the AO hook-plate for treatment of unstable fractures of the distal clavicle, *Arch. Orthop. Trauma Surg.* 127 (3) (2007) 191–194, <https://doi.org/10.1007/s00402-006-0284-5> (PMID: 17221230).
- [11] M.C. Webber, J.F. Haines, The treatment of lateral clavicle fractures, *Injury* 31 (3) (2000) 175–179, [https://doi.org/10.1016/S0020-1383\(99\)00276-4](https://doi.org/10.1016/S0020-1383(99)00276-4).
- [12] J.A. Goldberg, W.J. Bruce, D.H. Sonnabend, W.R. Walsh, Type 2 fractures of the distal clavicle: a new surgical technique, *J. Shoulder Elb. Surg.* 6 (4) (1997) 380–382, [https://doi.org/10.1016/S1058-2746\(97\)90006-9](https://doi.org/10.1016/S1058-2746(97)90006-9).
- [13] N. Pujol, J.M. Philippeau, J. Richou, F. Lespagnol, N. Graveleau, P. Hardy, Arthroscopic treatment of distal clavicle fractures: a technical note, *Knee Surg. Sports Traumatol. Arthrosc.* 16 (2008) 884–886, <https://doi.org/10.1007/s00167-008-0578-y>.
- [14] N. Pujol, P. Desmoineaux, P. Boisrenoult, P. Beaufils, Arthroscopic treatment of comminuted distal clavicle fractures (latarjet fractures) using 2 double-button devices, *Arthrosc. Tech.* 2 (1) (2013 Feb 21) e61–e63, 2013. Published, <https://doi.org/10.1016/j.eats.2012.11.001> (PMID: 23767010).