



Contents lists available at ScienceDirect

International Journal of Surgery Case Reports

journal homepage: www.casereports.com

Surgical debridement as a treatment strategy for cervicofacial actinomycosis—Literature review and case report

Karolyny Martins Balbinot^a, Naama Waléria Alves Sousa^b, João de Jesus Viana Pinheiro^{a,*}, André Luís Ribeiro Ribeiro^a

^a School of Dentistry, Federal University of Pará (UFPA), 01 St. Augusto Corrêa, 1- Guamá, Belém, PA, 66075-110, Brazil

^b School of Dentistry, University Centre of Para - CESUPA, Belem, PA, Brazil

ARTICLE INFO

Article history:

Received 30 April 2020

Received in revised form 9 June 2020

Accepted 14 June 2020

Available online 22 June 2020

Keywords:

Actinomycosis

Antibiotic prophylaxis

Debridement

Case report

ABSTRACT

INTRODUCTION: Actinomycosis is a rare chronic disease caused by bacterial infection of the Actinomyces genus. Standard treatment usually involves drainage and high doses of antibiotic therapy, which takes between 6–12 weeks for complete resolution.

PRESENTATION OF CASE: A 57-year-old male was admitted with soft tissue infection-like inflammation of the parasymphysis region, further diagnosed as cervicofacial actinomycosis. Treatment comprised of surgical debridement associated with antibiotic therapy, which took only 4 weeks for complete healing.

DISCUSSION: Although surgical debridement isn't part of the standard treatment, it has shown to be an interesting tool for promoting quick healing and infection control.

CONCLUSION: The authors reported a successful treatment of cervicofacial actinomycosis using surgical debridement as an adjuvant therapy, promoting faster healing, reducing antibiotic therapy time, costs and risks of bacterial resistance, which must be considered as an alternative approach in similar cases.

© 2020 The Authors. Published by Elsevier Ltd on behalf of IJS Publishing Group Ltd. This is an open access article under the CC BY-NC-ND license (<http://creativecommons.org/licenses/by-nc-nd/4.0/>).

1. Introduction

Actinomycosis is a rare, non-transmissible, infection caused by anaerobic gram-positive bacteria or microaerophiles, belonging to the genus Actinomyces, which make up the normal flora of the oral cavity [1]. About 50% of actinomycosis cases occur in the cervicofacial region and result mainly from dental infections, while the other half is divided mostly between the abdominal-pelvic and pulmonary regions [2]. In the cervicofacial region, the soft tissues of the submandibular, submental and nasogenian regions are the most commonly involved, with perimandibular involvement being the most frequent clinical presentation [3]. The treatment of actinomycosis can be challenging, given the need for long-term antibiotic therapy, leading patients to incomplete treatment, favouring recurrence [4].

Actinomyces israelii is pointed out as the main cause of this infection, with tonsillium crypts, biofilm and dental calculus, decayed dentin, gingival sulcus and periodontal pockets as its preferred sites of colonisation in healthy individuals [5].

* Corresponding author at: Rua Domingos Marreiros, 280, 3002, Belém, PA, 66055-210, Brazil.

E-mail addresses: karolbalbinot@gmail.com (K.M. Balbinot), naama.waleria@hotmail.com (N.W.A. Sousa), joaopinheiro@ufpa.br (J.d.J.V. Pinheiro), andre.ribeiro.13@ucl.ac.uk (A.L.R. Ribeiro).

<https://doi.org/10.1016/j.ijscr.2020.06.079>

2210-2612/© 2020 The Authors. Published by Elsevier Ltd on behalf of IJS Publishing Group Ltd. This is an open access article under the CC BY-NC-ND license (<http://creativecommons.org/licenses/by-nc-nd/4.0/>).

Clinically, actinomycosis is characterized as swelling of soft tissues and formation of microabscess, overtime, these microabscesses can join each other and form painful abscess, causing symptoms such as erythema, oedema and suppuration that when extended to the surface, form a fistulous path and may form multiple fistulas [6].

The differential diagnosis of actinomycosis is generally difficult because it begins slowly and has non-specific symptoms, which can be confused with cellulitis, other common infections of subcutaneous tissue or even neoplasms [7]. An important characteristic that helps in the differential diagnosis is the identification of sulphurous granules in the tissue or exudate of a suspected lesion through biopsy and subsequent histopathological analysis, which can be associated with culture of microorganisms [8].

Since these microorganisms are slow-growing and insidious, the treatment of actinomycosis is not simple and is based on antibiotic therapy, with surgical debridement indicated only in the presence of bone lesions, such as in cases associated with osteomyelitis [9,1]. In cases of soft tissue lesions, regression of infection is achieved with penicillin treatment for 5–6 weeks, when associated with surgical treatment. In patients with deep infections, treatment for up to 12 months may be required if no surgical therapy is performed [3]. Table 1 summarizes cases presented in the literature [10–20].

The need for prolonged antibiotic therapy can be a major disadvantage in standard actinomycosis therapy, especially in underdeveloped countries where the costs of this treatment is

Table 1
Literature data on treatment of actinomycosis.

Article Type	Authors/Publication Date	Sex/Age	Affected Tissue Area	Interventions	Antibiotic Therapy Time
CR	Wagner <i>et al.</i> , (2002)	M/61 years	Jaw angle	Drainage - placement of Pen Rose type drain	3 months
CR	Varghese <i>et al.</i> , (2004)	M/38 years	Left Parotid Gland	Incisional biopsy of the nodule with underlying parotid tissue	3 weeks ^b
CR	Volante <i>et al.</i> , (2005)	M/51 years	Right sub-mandibular	Surgical excision of the mass	4 weeks
CR	Menezes <i>et al.</i> , (2006)	M/77 years	Laryngeal	Hospitalization for antibiotic treatment	6 months
CR	Lancella <i>et al.</i> , (2008)	M/39 years	Cervical Right - Neck	Selective right cervical emptying	1 month and 16 days
		M/58 years	Right cervical parotid gland	Parotidectomy	1 months and 5 days
CR	Carneiro <i>et al.</i> , (2009)	F/28 years	Cervicofacial	Drainage - placement of pen rose type drain	4 months
CR	Lee <i>et al.</i> , (2011)	M/82 years	Upper lip	Complete removal of the Node	1 month
CR	Kura and Rane, (2011)	M/22 years	Right side of the chin	Skin Biopsy	5 months and 1 week
CR	Shikino <i>et al.</i> , (2014)	F/62 years	Right cheek	Excisional biopsy on the right cheek side	6 months
SC	Valour <i>et al.</i> , (2014)	F/37 years	Right maxillary sinus	Right maxillary antrostomy	5 months
CR	Kolm <i>et al.</i> , (2014)	F/86 years	Cervicofacial - cheek	Deep skin biopsy	3 months
CR	Kang <i>et al.</i> , (2015)	F/87 years	Lower lip	Extensive excision of the lesion	2 weeks ^a
CR	Puri <i>et al.</i> , (2015)	M/22 years	Right submandibular gland	Surgical excision of the right submandibular gland	4 weeks
CR	Cohn <i>et al.</i> , (2017)	F/50 years	Right maxillary sinus	Right functional endoscopic surgery, maxillary antrostomy and anterior and posterior ethmoidectomy.	2 months
SC	Bortoluzzi, <i>et al.</i> , (2020)	10 F and M/25–68 years	Cheek, Chin and Right latero-cervical region	Surgical drainage and debridement of the oral cavity	16–24 weeks

List of abbreviations: CR, case report; SC, series of cases; M, male; F, female.

^a High dosage of antibiotics: 6G of Amocycillin.

^b Patient presented scars with deformity and asymmetry of the face.

associated with difficulties for continuous evaluation and monitoring, leading to the recurrence of the lesion and increased microbial resistance. Based on issues discussed above, this study aimed to report a case of actinomycosis in the perimandibular region treated with antibiotic therapy in combination with surgical debridement. This combined treatment showed a faster resolution of the infection, which reduced the time and costs of treatment, minimising the potentially negative effects of prolonged antibiotic therapy.

This work has been reported in line with the SCARE criteria [21].

2. Presentation of case

A 57-year-old male was admitted with a swollen region of 4 cm in diameter on the right parasymphiseal region, mild local pain, no fever or other systemic symptoms (Fig. 1A). The patient reported that the lesion appeared 30 days before as a result of nail-scratching an itching area and it was treated at that time with one-week of antibiotics (sulfas and tetracyclines).

Facial examination, it was possible to observe the presence of a diffuse erythematous lesion with several clustered fistulas. The soft tissues in this region were tender and the presence of yellowish granules with different dimensions were noticed (Fig. 1B).

Upon oral examination, no periapical or bone lesions were observed on panoramic X-ray. Severe periodontal disease was found, but it was not related to the current cervicofacial infection (Fig. 2).

Combined surgical and antibiotic treatment was selected, in which surgical debridement was performed for helping drainage and for removing necrotic tissues. A biopsy sample was taken for histological evaluation (Fig. 1C). Antibiotic therapy consisted of administering 500 mg of amoxicillin 3 times a day for 30 days.

The histopathological examination was carried out using haematoxylin and eosin staining. It showed a chronic inflammatory infiltrate with granuloma formation surrounding collections of polymorphonuclear leukocytes and colonies of microorganisms (Fig. 3). The actinomyces colonies had formed a discrete pattern of radiated rosettes, and areas of haemorrhage were also present, suggesting the diagnosis of actinomycosis.

The swollen was gradually reduced and healing of fistulas stated quickly after the surgical debridement. The patient was followed-up periodically and a very favourable healing began to occur on the fourth postoperative day, with no more purulent drainage (Fig. 1D). On the 12th postoperative day, an area of fibrosis could already be seen promoting wound closure in regions where the fistulas were previously located (Fig. 4). Over a period of 4 weeks, the patient finished the antibiotic treatment, and the inflamed-infectious process healed, along with complete healing of the skin. (Fig. 5).

3. Discussion

Actinomycosis is an infection of bacterial origin, which treatment has proven quite challenging according to the few studies conducted on cervicofacial soft tissue actinomycosis. The techniques applied today are still the same as 20 years before, which include extended courses of antibiotics and, sometimes, drainage of abscess. Surgical debridement, besides of draining abscesses, allows removal of necrotic tissues, helping immune cells of doing this task and letting them to focus on bacterial killing and tissue healing. After debridement, the local blood flow is improved, which also helps the entire healing process. However, just a few authors have used this technique that showed excellent results in treating our case [22,23].

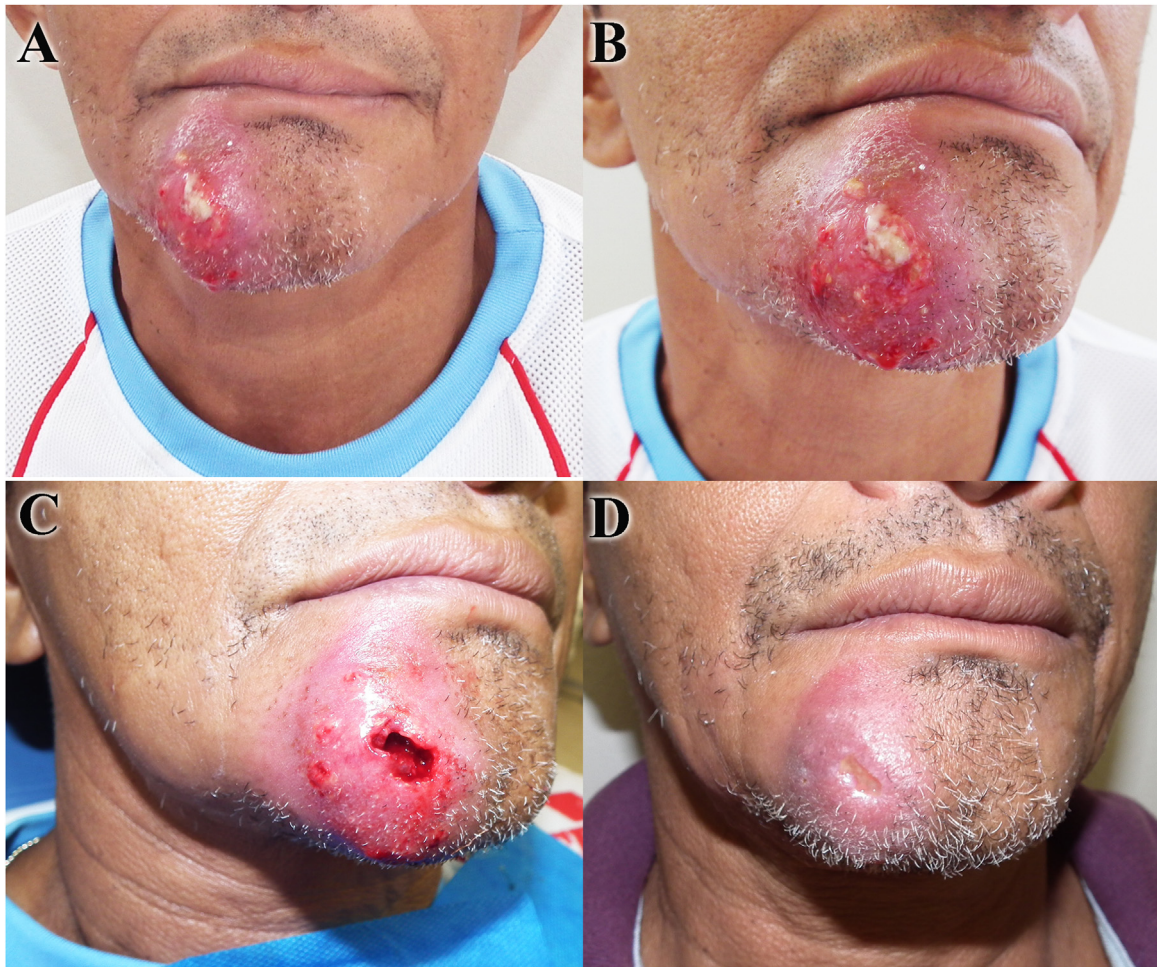

Fig. 1. Clinical aspects—Initial aspect of the infectious process (A); Erythematous lesion with the presence of granules (B); Lesion after surgical debridement (C); Initial healing 4 days after the primary intervention (D).

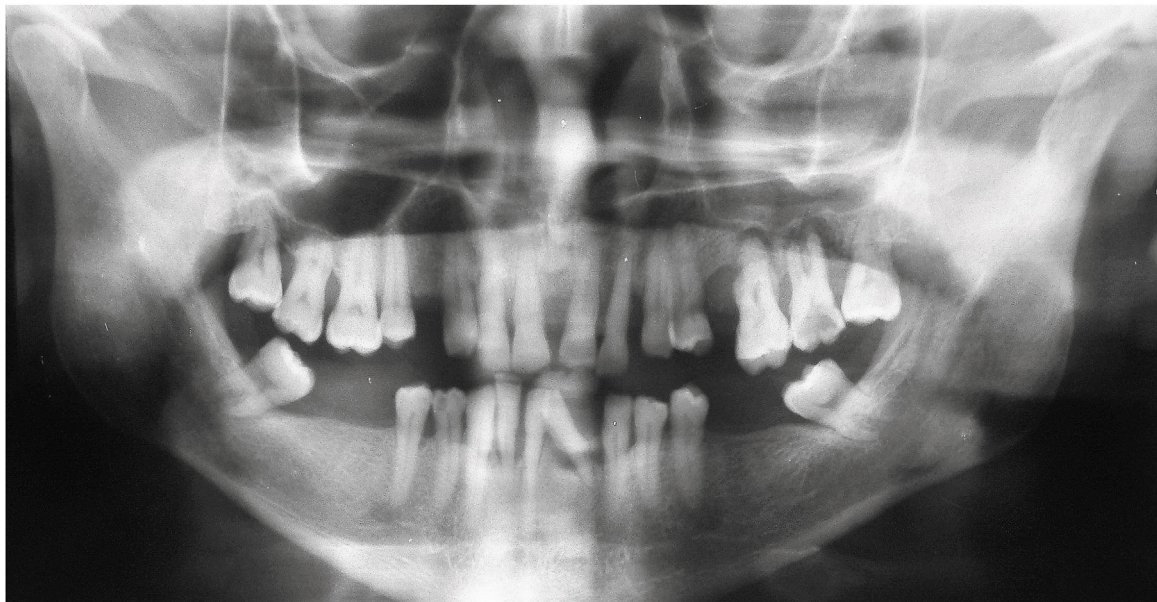

Fig. 2. Panoramic radiography: teeth with severe periodontal disease—31.41 and 42—but without the presence of bone rarefaction.

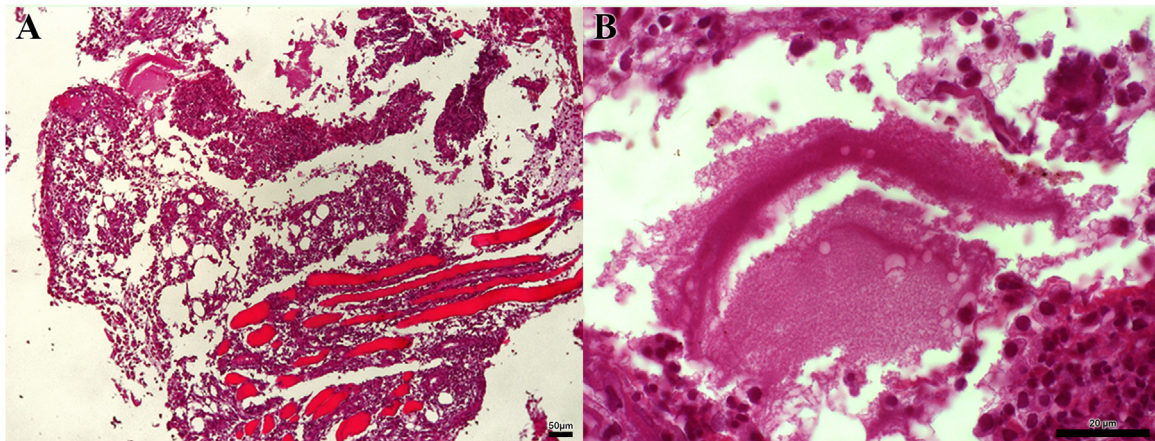


Fig. 3. Images of histological examination at 10x (A and C) and 63x (B and D).

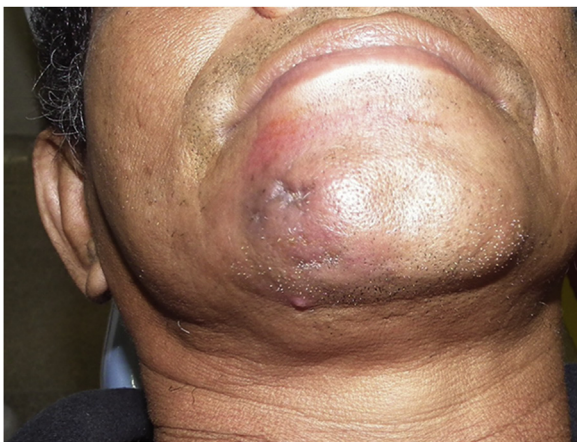

Fig. 4. Clinical aspect 12 days after surgery.

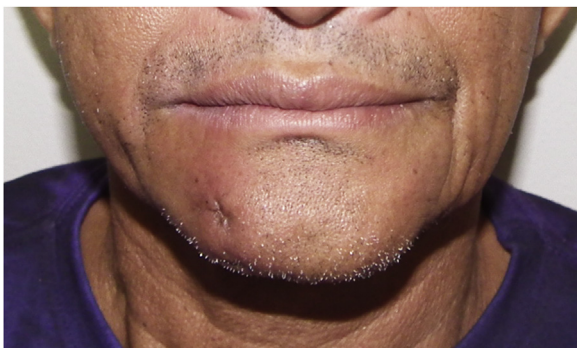

Fig. 5. Final clinical appearance after 4 weeks.

Long-term antibiotic therapy is common for treating routine cases of actinomycosis as shown in [Table 1](#). Most reports focus only in abscess drainage or tissue biopsy, somehow neglecting the advantages of surgical debridement on tissue healing. Usually, conservative management is linked to prolonged antibiotic therapy [7,9,12,15].

In this report, we present an uncommon case of actinomycosis in the parasymphysis region treated surgically with debridement and a short course of antibiotics (4 weeks). The reduction of antibiotic therapy was possible due to the use of surgical debridement, which consists of the removal of non-viable tissue, cellular debris, exudate and all foreign residues of the lesion. The technique is less invasive

compared to a complete surgical excision of the lesion; thus, the healing period is shorter and scar area becomes smaller.

In 1997, Nagler et al. [24] raised the hypothesis that patients with actinomycosis do not respond well to antibiotic therapy before degranulation and curettage or resection of the region. It was attributed to compartmentalization of microorganisms (Sulphur granules) within the granulation tissue, making it difficult to antibiotics reaching the infection site due to limited blood supply [24]. However, this study was carried out in a series of patients who had intraosseous infections, and the efficiency of the technique in soft tissue lesions was not tested.

It is worth mentioning that the use of high doses of antibiotics for a long period of time can have side effects, such as renal insufficiency or kidney stones, tooth pigmentation, liver, brain and eye damage, among others, besides promoting bacterial resistance. The cost of treatment is also higher, considering the cost of prolonged antibiotics.

4. Conclusion

Surgical debridement appeared to be a valuable technique to treat a rare case of cervicofacial actinomycosis. Surgical debridement improves infection control, tissue healing and reduces antibiotic therapy. This seems to be one of the few papers to mention the use of this simple surgical technique to treat cervicofacial actinomycosis. Based on these findings, we suggest that surgical debridement can be an alternative measure that have beneficial effects and must be considered in all cases of cervicofacial actinomycosis.

Declaration of Competing Interest

All authors declare no conflict of interest in formulating this article.

Sources of funding

This research did not receive any specific grant from funding agencies in the public, commercial, or not-for-profit sectors.

Ethical approval

We declare that our institution does not require ethical approval of clinical case reports.

Consent

Written informed consent was obtained from the patient for publication of this case report and accompanying images. A copy of the written consent is available for review by the Editor-in-Chief of this journal on request.

Author contribution

JJVP and ALRR contributed in conceptualisation, KMB contributed in study concept and design, JJVP and KMB contributed in writing the paper.

Registration of research studies

None.

Guarantor

The guarantor of this work, Joao de Jesus Viana Pinheiro, accept full responsibility for the study and the conduct of the study, had access to the data, and controlled the decision to publish.

Provenance and peer review

Not commissioned, externally peer-reviewed.

References

- [1] F. Valour, A. Sénéchal, T. Ferry, Actinomycosis: etiology, clinical features, diagnosis, treatment, and management, *Infect. Drug Resist.* 7 (2014) 183–197.
- [2] S.R. Kim, L.Y. Jung, I.J. Oh, Pulmonary actinomycosis during the first decade of 21st century: cases of 94 patients, *BMC Infect. Dis.* 13 (2013) 216.
- [3] A. Chaves, C. Madeira, S. Carvalho, Chronic mandibular actinomycosis: Anesthetic and infectious implications: about a clinical case, *Portuguese Soc. Anesthesiol.* 9 (2010) 26–29.
- [4] K.M. Shah, A. Karagir, S. Kanitkar, R. Koppikar, An atypical form of cervicofacial actinomycosis treated with short but intensive antibiotic regimen, *BMJ Case Rep.* (2013), bcr2013008733, <http://dx.doi.org/10.1136/bcr-2013-008733>.
- [5] L. Bubbico, M. Caratozzolo, F. Nardi, G. Ruoppolo, A. Greco, M. Venditti, Actinomycosis of submandibular gland: an unusual presentation, *Acta Otorhinolaryngol. Ital.* 24 (2004) 37–39.
- [6] M. Moghimi, E. Salentijn, Y. Debets-Ossenkop, K.H. Karagozoglu, T. Forouzanfar, Treatment of cervicofacial actinomycosis: a report of 19 cases and review of literature, *Med. Oral Patol. Oral Cir. Bucal* 18 (2013) e627–e632.
- [7] G. Carneiro, A.C. Barros, L.D. Fracassi, V.A. Sarmento, J.G. Farias, Actinomycose cervicofacial: clinical case report, *J. Oral Maxillofac. Surg. Traumatol.* 10 (2010) 21–26.
- [8] A.C. Ferraz, C.V.M. Melo, E.L.R. Pereira, J.N. Stávale, R.G. Nogueira, A.A. Gabbai, S.M.F. Malheiros, M.N. Prandini, Actinomycosis of the central nervous system: a rare complication of actinomycose cervicofacial, *Arch. Neuro-Psychiatry* 51 (1993) 358–362.
- [9] J.B. Wagner, J.P. Gomes, M.R. Volkweis, Imaging exams as auxiliary to diagnosis of cervicofacial actinomycosis, *Rev. Cir. Traumat. Buccomaxillofac.* 2 (2002) 9–16.
- [10] B.T. Varghese, P. Sebastian, K. Ramachandran, M. Pandey, Actinomycosis of the parotid masquerading as malignant neoplasm, *BMC Câncer* 4 (2004) 7.
- [11] M. Volante, A.M. Contucci, M. Fantoni, R. Ricci, J. Galli, Cervicofacial actinomycosis: still a difficult differential diagnosis, *Acta Otorhinolaryngol. Ital.* 25 (2) (2005) 116–119.
- [12] M.C. Menezes, O. Tornin, S. de, R.A. Botelho, J.P. de Brito Júnior, D.K. Ortellado, L.R. Torres, et al., Laryngeal actinomycosis: case report, *Braz. Radiol.* 39 (4) (2006) 309–311.
- [13] A. Lancellata, G. Abbate, A.M. Foscolo, R. Dosdegani, Two unusual presentations of cervicofacial actinomycosis and review of the literature, *Acta Otorhinolaryngol. Ital.* 28 (2) (2008) 89–93.
- [14] Y.S. Lee, H.S. Sim, S.K. Lee, Actinomycosis of the upper lip, *Ann. Dermatol.* 13 (23 Suppl 1) (2011) 1–4.
- [15] M.M. Kura, V.K. Rane, Cervicofacial actinomycosis mimicking lymphangioma circumscriptum, *Indian J. Dermatol.* 56 (2011) 321–323.
- [16] K. Shikino, M. Ikusaka, T. Takada, Cervicofacial actinomycosis, *J. Gen. Intern. Med.* 30 (2) (2014) 263.
- [17] I. Kolm, L. Aceto, M. Hombach, J. Kamarshv, J. Hafner, M. Urošević-Maiwald, Actinomycose cervicofacial: a long-standing infectious complication of immunosuppression - case report and literature review, *Dermatol. Online J.* 20 (5) (2014).
- [18] J.S. Kang, H.J. Choi, M.S. Tak, Actinomycosis and Sialolithiasis in the submandibular gland, *Arch. Craniofacial Surg.* 16 (1) (2015) 39–42.
- [19] H. Puri, V. Narang, J. Chawla, Actinomycosis of submandibular gland: an unusual presentation of a rare entity, *J. Oral Maxillofacial Pathol.: JOMFP* 19 (1) (2015) 106.
- [20] J.E. Cohn, M. Lentner, H. Li, M. Nagorsky, Unilateral maxillary sinus actinomycosis with a closed oroantral fistula, *Case Rep. Otolaryngol.* (2017).
- [21] Updating Consensus Surgical Case Report (SCARE) Guidelines, *Int. J. Surg.* 60 (2018) 132–136.
- [22] P. Bortoluzzi, G. Nazzaro, S. Giacalone, Cervicofacial actinomycosis: a report of 14 patients observed at the Dermatology Unit of the University of Milan, Italy, *Int. J. Dermatol.* (2020).
- [23] G.E. Glass, R.M.T. Staruch, K. Bradshaw, Pediatric cervicofacial actinomycosis: lessons from a craniofacial unit, *J. Craniofac. Surg.* 30 (2019) 2432–2438.
- [24] R. Nagler, M. Peled, D. Laufer, Cervicofacial actinomycosis, *Oral Surg. Oral Med. Oral Pathol. Oral Radiol. Endodontology.* 83 (1997) 652–656.

Open Access

This article is published Open Access at [sciencedirect.com](https://www.sciencedirect.com). It is distributed under the [IJSCR Supplemental terms and conditions](#), which permits unrestricted non commercial use, distribution, and reproduction in any medium, provided the original authors and source are credited.