


A case of bacterial keratitis caused by multi-drug-resistant *Shewanella algae* without marine exposure

Je Eun Song¹, Sollip Kim², Hyung Koo Kang³, Inkwon Chung⁴, Yee Gyung Kwak¹, Tae Hyun Um², Chong Rae Cho² and Jeonghyun Chang ^{2,*}

¹Inje University Ilsan Paik Hospital, Infectious Diseases, Internal Medicine, Goyang 10380, Republic of Korea

²Inje University Ilsan Paik Hospital, Department of Laboratory Medicine, Goyang 10380, Republic of Korea

³Inje University Ilsan Paik Hospital, Division of Pulmonary and Critical Care Medicine, Department of Internal Medicine, Goyang 10380, Republic of Korea

⁴Inje University Ilsan Paik Hospital, Department of Ophthalmology, Goyang 10380, Republic of Korea

*Correspondence address. Department of Laboratory Medicine, Inje University Ilsan Paik Hospital, 170, Juhwa-ro, Ilsanseo-gu, Goyang-si, Gyeonggi-do 10380, Republic of Korea. Tel: +82-31-910-0114; Fax: +82-31-910-0114; E-mail: azacsss@naver.com

Abstract

Shewanella are Gram-negative rods and marine pathogens. Here, we report a case of bacterial keratitis caused by *Shewanella algae* without marine exposure. A 66-year-old man with suspected pneumonia was sent to the emergency department from a nursing hospital. He had been in there for 2 years in a vegetative state and could not close his eyes voluntarily. Neither the patient nor his family had experienced any marine exposure. Keratitis was suspected in his right eye. Gram-negative rods grew from swab culture and identified as *S. algae* by matrix-assisted laser desorption/ionization time-of-flight mass spectrometry and 16S rRNA sequencing. The patient was treated with topical tobramycin, moxifloxacin and ofloxacin as well as steroids for 14 days, and the keratitis improved. *S. algae* is a rare human pathogen, and most human infections involve marine exposure. This is the second report of bacterial keratitis caused by *S. algae* worldwide and the first in Asia.

Keywords: *Shewanella algae*, bacterial keratitis, marine, human pathogen

INTRODUCTION

Shewanella spp. are facultatively anaerobic, Gram-negative, motile rods first described by Derby and Hammer in 1931 [1, 2]. They are typical marine pathogens found in marine, cold water environments and deep sea sediments [3]. Human infections by *Shewanella* spp. are very rare, although the number of reports has increased recently [4]. Most human infections caused by *Shewanella* spp. have a marine association, such as infection from trauma while fishing. There are more than 20 known *Shewanella* species. The species reported most frequently as human pathogens are *Shewanella putrefaciens* and *S. algae* [4]. Since first identification of *S. algae* in 1992, various human infections caused by *S. algae* have been published worldwide, including bacteremia, skin and soft tissue infection, peritonitis, pericarditis and bone infections [4]. In Korea, reported *S. algae* infections have caused endophthalmitis, tenosynovitis, peritonitis and bacteremia [5–7]; all cases were related to marine environments, including trauma while fishing, slipping on the beach and eating raw fish. Here, we report a case

of keratitis caused by multi-drug-resistant *S. algae* that was not related to a marine environment.

CASE REPORT

A 66-year-old man was sent to the emergency department from a nursing hospital because of desaturation. He had been hospitalized for more than 2 years in an unconscious state due to a cervical spine injury. He was unable to close his eyes voluntarily. Neither the patient nor his family had a history of marine exposure. At admission, pneumonia was suspected, and conjunctival injection, purulent discharge and central white opacity were detected in his right eye. He was admitted to the respiratory department, and treatment with piperacillin-tazobactam was started for pneumonia. An ophthalmologist examined the patient at the bedside. Examination of his right eye revealed 6.0 × 5.0 mm corneal opacity and hyphema with hypopyon in the anterior chamber. Fundus examination was impossible due to corneal haziness. Corneal swabs were sent for Gram staining, bacterial culture and antimicrobial sensitivity testing,

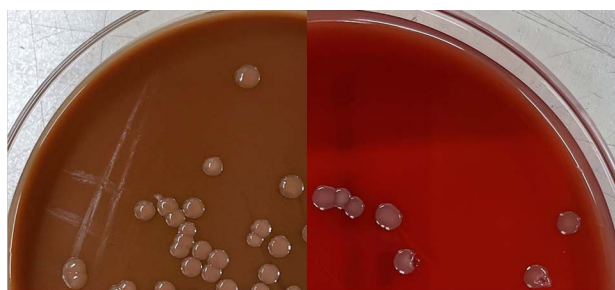Received: September 6, 2021. Revised: November 9, 2021. Accepted: December 6, 2021

© The Author(s) 2021. Published by Oxford University Press.

This is an Open Access article distributed under the terms of the Creative Commons Attribution Non-Commercial License (<http://creativecommons.org/licenses/by-nc/4.0/>), which permits non-commercial re-use, distribution, and reproduction in any medium, provided the original work is properly cited. For commercial re-use, please contact journals.permissions@oup.com

Table 1. Eye infections caused by *Shewanella* species

Year	Age	Sex	Species	Clinical manifestation	Underlying condition	Marine exposure	Country	Reference number
2007	58	M	<i>Shewanella putrefaciens</i>	Keratitis	s/p LASIK	None	USA	[11]
2013	27	M	<i>Shewanella algae</i>	Endophthalmitis	None	Trauma during fishing	Korea	[7]
2014	25	M	<i>S. putrefaciens</i>	Endophthalmitis	None	Trauma with a fishhook	India	[9]
2019	75	M	<i>S. putrefaciens</i>	Keratitis	None	None	Korea	[12]
2019	75	M	<i>S. algae</i>	Keratitis	Chronic dry eye syndrome, glaucoma	None	USA	[9]

**Figure 1.** *Shewanella algae* colonies grown on chocolate (left) and blood (right) agar plates.

KOH mount smear and fungal culture. Empirical treatment with tobramycin, moxifloxacin and ofloxacin eye drops was started. The KOH smear and Gram stain were negative. After a 2-day incubation, medium-sized gray and dark pink colonies grew on blood agar plate and chocolate agar plate (Fig. 1). Other types of colony did not grow on the plate. *S. algae* was identified by matrix-assisted laser desorption/ionization time-of-flight mass spectrometry using the Vitek system (bioMérieux, Marcy-L'Étoile, France). 16S rRNA sequencing revealed 99.93% (1410/1411 bp) identity with *S. algae* JCM 21037(T) (GenBank accession number BAL001000089). Susceptibility testing of the isolate indicated susceptible to amikacin, aztreonam, cefepime, ceftazidime, colistin and gentamicin, resistant to cefotaxime, imipenem, piperacillin and piperacillin/tazobactam, and intermediate to ciprofloxacin, levofloxacin and meropenem. We added steroid eye drops to control the inflammation and continued the antibiotic eye drops. After 14 days, his keratitis had improved.

DISCUSSION

Microbial keratitis is inflammation of the cornea caused by bacteria, fungi, or protists. The main causative bacteria are *Staphylococcus aureus*, *Pseudomonas aeruginosa*, *Streptococcus pneumoniae* and *Serratia* species [8]. Bacterial keratitis caused by *Shewanella* species is extremely rare. Only one case of *S. algae* infection has been reported worldwide; this was in the USA in 2019 [9]. In Korea, there has been one case of *S. algae* endophthalmitis but no reported keratitis cases [7]. We report the second case of *S. algae* keratitis worldwide and the first in Asia. Colonies of *Shewanella* species on medium are convex, circular, and

smooth and produce an unusual brown to tan pigment, in contrast to the white colonies of the major keratitis pathogens *S. aureus* and *P. aeruginosa* [2]. The colonies we observed were also medium-sized circular smooth colonies that were dark pink to brown on both blood agar plate and chocolate agar plate (Fig. 1). This should inform clinicians of the unusual colony morphology, which differs from that of the major keratitis pathogens observed in clinical microbiology laboratory.

This case has two exceptional aspects. First, the isolate was resistant to multiple drugs. There are no criteria for antimicrobial susceptibility testing of *Shewanella* species in international guidelines, such as the Clinical and Laboratory Standards Institute and European Committee on Antimicrobial Susceptibility Testing. Therefore, we used the criteria for *P. aeruginosa*, which is a related strain. The antimicrobial susceptibility tests showed resistance to cefotaxime, piperacillin, piperacillin/tazobactam, and carbapenem and intermediate to quinolone, which shows more resistant tendency than previous reported isolates. In a 2013 review of 239 cases since 1973, 82%, 94%, 94% and 98% of *Shewanella* species were susceptible to imipenem, ciprofloxacin, piperacillin and piperacillin/tazobactam, respectively [10]. In our case, *S. algae* was multi-drug resistant, rendering it difficult to treat, which can lead to treatment failure. Furthermore, the types of antibiotics that can be used in eye drops are limited, decreasing the treatment options.

Second, the patient had no history of seawater exposure. *Shewanella* infections are often associated with marine exposure [5, 7]. Our patient had been hospitalized in a nursing hospital for more than 2 years, and his family had no relation to the sea. Consequently, we did not suspect *S. algae* infection in this patient sooner. It is necessary to consider whether there are *S. algae* infection routes other than marine exposure. We did not perform other culture such as stool culture, therefore it was not possible to confirm that *S. algae* existed in the patient as colonization. Although *S. algae* mainly inhabit the marine environment, there is a possibility of infection even if the patient did not have marine exposure. *S. algae* is found naturally in wildlife including seawater as well as soil, fish, meat, and dairy product [6]. There have been several cases of eye infections without marine exposure in previously published reports (Table 1). Although no

other investigation has been conducted to find the source of the infection, it should be thought that various environment including care giving staff and ingestion of seafood also can be the sources of infection.

As in this case, clinical isolates can be extremely rare species with high levels of drug resistance and can involve an atypical patient history. For best clinical practice, clinicians need to keep an eye on the laboratory results after ordering cultures.

This is the second report of bacterial keratitis caused by multi-drug resistant *S. algae* worldwide and the first in Asia. Clinicians must track microbiology test results to determine appropriate antimicrobial treatment.

ACKNOWLEDGEMENT

None.

CONFLICTS OF INTEREST

No conflicts of interest.

FUNDING

This research did not receive specific funding.

ETHICAL APPROVAL

No approval was required for the case report from the local ethical committee.

CONSENT

Consent was obtained in written format from the patient's family for clinical information to be reported in the journal.

GUARANTOR

J.C. and J.E.S.

References

1. Derby HA. Bacteriology of butter. IV. Bacteriological studies on surface taint butter. Iowa Agric Home Econ Exp Station Res Bull, **11**, 1931:389–416
2. Carroll KC, Pfaller MA. *Acinetobacter*, *Chryseobacterium*, *Moraxella*, and other nonfermentative Gram-negative rods, in manual of clinical microbiology, 12th edn. ASM Press, 2019, 829–57.
3. Nealson KH, Scott J. Ecophysiology of the genus *Shewanella*. The prokaryotes in a handbook on the biology of bacteria Volume 6: proteobacteria: gamma subclass. Springer, NY, 2006, 1133–51.
4. Janda JM. *Shewanella*: A Marine Pathogen as an Emerging Cause of Human Disease. Clin Microbiol News! 2014;**36**:25–9. <https://doi.org/10.1016/j.clinmicnews.2014.01.006>.
5. Myung DS, Jung Y, Kang SJ, Song YA, Park KH, Jung SI et al. Primary *Shewanella algae* bacteremia mimicking *Vibrio* septicemia. J Korean Med Sci 2009;**24**:1192–4. <https://doi.org/10.3346/jkms.2009.24.6.1192>.
6. Kim BK, Cho SY, Kang B, Kim IK, Byun JH, Park C et al. A case of spontaneous bacterial peritonitis with bacteremia caused by *Shewanella algae*. Infect Chemother 2014;**46**:264–8. <https://doi.org/10.3947/ic.2014.46.4.264>.
7. Oh SY, Lee SJ, Park JM. A case of endophthalmitis caused by *Shewanella algae* after trauma. J Korean Ophthalmol Soc 2013;**54**:365–9. <https://doi.org/10.3341/jkos.2013.54.2.365>.
8. Lakhundi S, Siddiqui R, Khan NA. Pathogenesis of microbial keratitis. Microb Pathog 2017;**104**:97–109. <https://doi.org/10.1016/j.micpath.2016.12.013>.
9. Bravenec CA, Pandit RT, Beaver HA. *Shewanella algae* keratitis. Indian J Ophthalmol 2019;**67**:148–50. https://doi.org/10.4103/ijo.IJO_617_18.
10. Vignier N, Barreau M, Olive C, Baubion E, Théodose R, Hochedez P et al. Human infection with *Shewanella putrefaciens* and *S. algae*: report of 16 cases in Martinique and review of the literature. Am J Trop Med Hyg 2013;**89**:151–6. <https://doi.org/10.4269/ajtmh.13-0055>.
11. Park HJS, Tuli SS, Downer DM, Gohari AR, Shah M. *Shewanella putrefaciens* keratitis in the lamellar bed 6 years after LASIK. J Refract Surg 2007;**23**:830–2. <https://doi.org/10.3928/1081-597X-20071001-15>.
12. Moon TK, Ji YS, Yoon KC. Infectious keratitis caused by *Shewanella Putrefaciens*. J Korean Ophthalmol Soc 2019;**60**:787–91. <https://doi.org/10.3341/jkos.2019.60.8.787>.