

# An Intriguing Case of Post-Operative Respiratory Failure from an Occult Diaphragmatic Hernia- Be Aware of the Masquerader

## Abstract

Though respiratory complications after cardiac surgery for congenital heart disease are common, and malformations of the diaphragm can be expected in these patients, the presence of an occult diaphragmatic defect unrecognisable preoperatively and complicating the post operative course is very rare and need a high index of suspicion for diagnosis in the setting of post operative respiratory failure. We present here a case of post operative respiratory failure from a delayed presenting diaphragmatic hernia in a 2-month-old boy who underwent corrective surgery for Taussig bing anomaly and hypoplastic aortic arch. Surgical repair of the diaphragmatic defect and reduction of the bowel loops to the abdomen resulted in rapid weaning from ventilation and recovery with subsequent discharge from hospital.

**Keywords:** Congenital diaphragmatic hernia, congenital heart disease, respiratory failure

## Introduction

Respiratory complications after major intra thoracic and cardiac surgery is well documented. There are a myriad of causes of post-operative respiratory failure, and often multiple causes are in interplay simultaneously. Diaphragmatic pathology are well known factors for post-operative respiratory complications, and clues to the same are often available as clinical or imaging findings. Malformations of the diaphragm also occur commonly in patients with congenital heart disease. However, delayed presentation of congenital diaphragmatic hernia (CDH) is extremely rare,<sup>[1]</sup> there are only isolated case reports and case series on its occurrence. We present here an interesting and probably the first reported case of occurrence of post-operative respiratory failure from a delayed presenting diaphragmatic hernia in a surgical patient of complex congenital cyanotic heart disease. The case highlights the clinical significance, disguising factors, and the need for a high index of suspicion for diaphragmatic defect in the setting of post-operative respiratory failure in infants and children of congenital heart disease (CHD).

This is an open access journal, and articles are distributed under the terms of the Creative Commons Attribution-NonCommercial-ShareAlike 4.0 License, which allows others to remix, tweak, and build upon the work non-commercially, as long as appropriate credit is given and the new creations are licensed under the identical terms.

For reprints contact: reprints@medknow.com

## Case History

A 2-month-old male child was referred to our center with a diagnosis of congenital cyanotic heart disease for further management. Transthoracic echocardiography revealed situs solitus, levocardia, atrioventricular concordance, and ventriculoarterial discordance with D malposed aorta. The aorta was seen lying right and anterior to the pulmonary artery, along with a large subpulmonary VSD with bidirectional shunt. Left ventricular (LV) systolic function was normal and there was no pleural or pericardial collection. Inferior vena cava and pulmonary veins were connected normally to right and left atrium, respectively. Subsequent computerized tomography (CT) scan with radio-contrast for great vessels confirmed additional presence of a patent ductus arteriosus (PDA) with hypoplastic aortic arch. No other associated congenital anomaly was found on clinical, radiological examinations [Figure 1a], and laboratory investigations. A diagnosis of Taussig bing anomaly with hypoplastic aortic arch was established. Patient was scheduled for arterial switch operation with aortic arch augmentation. After smooth anesthesia induction, midline sternotomy was performed and aorto-bicaval cannulation was done to establish cardiopulmonary

**How to cite this article:** Borthakur B, Hanjoora VM, Mahajan V, Srivastava AR, Jyoti A, Raut M, *et al.* An intriguing case of post-operative respiratory failure from an occult diaphragmatic hernia- be aware of the masquerader. *Ann Card Anaesth* 2020;23:237-40.

**Biplob Borthakur,  
Vijay M Hanjoora,  
Viresh Mahajan<sup>1</sup>,  
Aseem R  
Srivastava<sup>2</sup>,  
Aman Jyoti,  
Monish Raut,  
Anup Nawal**

*Departments of Cardiac Anaesthesia, <sup>1</sup>Paediatric Cardiology, and <sup>2</sup>Paediatric Cardiology and Cardiac Surgery, Artemis Hospital, Sector 51, Gurugram, Haryana, India*

**Submitted:** 06-Dec-2018

**Revised:** 28-May-2019

**Accepted:** 22-Jun-2019

**Published:** 07-Apr-2020

### Address for correspondence:

*Dr. Biplob Borthakur,  
Department of Cardiac Anaesthesia, Artemis Hospital,  
Sector 51, Gurugram,  
Haryana - 122 011, India.  
E-mail: dr.biplob@yahoo.com*

### Access this article online

**Website:** www.annals.in

**DOI:** 10.4103/aca.ACA\_227\_18

### Quick Response Code:



bypass after adequate heparinization. Intra operatively there was no intra thoracic bowel loop seen by surgical team that could indicate a diaphragmatic defect. Post operatively, the child had an elective delayed chest closure on post-operative day 3. His post-operative course was complicated by development of cardiac dysrhythmias, chylothorax requiring prolonged chest tube drainage, and low cardiac output state. Patient had prolonged mechanical ventilation and tracheal extubation was done by post-operative day 19. However, development of pneumothorax, collapse of left lung, and re-accumulation of the chylothorax necessitated reinsertion of bilateral chest tube. Considering progressive hypoxia, patient was reintubated and mechanically ventilated. Subsequently, there was improvement in the clinical condition and the patient was weaned off the ventilator again and trachea was extubated. There were areas of hyperinflation in the right chest on chest X-ray which were initially diagnosed as bronchomalacia from broncho pulmonary dysplasia resulting from prolonged mechanical ventilation. The child required nasal continuous positive airway pressure (CPAP) support intermittently and later maintained saturation by oxygen through nasal prongs. However, the picture of hyperinflation on chest x rays persisted [Figure 1b]. The child was shifted to the ward care on supplemental oxygen but weaning him off the oxygen seemed to be difficult. Subsequent chest X-ray showed air spaces in lung fields suggestive of bullae formation [Figure 1c]. After 2 weeks in ward care he redeveloped respiratory compromise with increased work of breathing and needed tracheal re-intubation and mechanical ventilation. The post intubation chest X-rays done on mechanical ventilation was notable in showing decrease in size of the supposed bullae. A subsequent X-ray showed distinct retrosternal radiolucency [Figure 1d]. These findings raised a doubt of diaphragmatic hernia as the cause of the radiolucency and also previously supposed bullae. Subsequent computer tomography (CT) scan of the chest confirmed the diagnosis of Morgagni type of diaphragmatic hernia. This was surgically repaired with a GORE-TEX (W.L. Gore and associates, Inc, USA) patch after reducing the herniated gut to the abdomen [Figure 2]. The patient was subsequently weaned off ventilator and the trachea was extubated after 2 days, and had an uneventful clinical course thereafter.

The child is doing well and gaining weight at 3 months follow up of hospital discharge.

## Discussion

Taussig Bing anomaly is a variant of double outlet right ventricle with a subpulmonic ventricular septal defect. It is a congenital cyanotic heart disease (CCHD), and the treatment is surgical. This patient also had a hypoplastic aortic arch and a patent ductus arteriosus (PDA) in addition, which required ligation of the PDA and augmentation of the aortic arch. The surgical treatment of these anomalies is complex and carries a high mortality risk. A variety of extra cardiac malformations has been described to be associated with congenital birth defects, with varying frequencies in different studies.<sup>[2-5]</sup> Some of the anomalies add up to some known syndrome complexes.<sup>[3-5]</sup> The extracardiac anomalies can be cause of significant additional morbidity and mortality in these patient populations.<sup>[3]</sup>

The association of respiratory tract anomaly with congenital heart disease (CHD) has been found to be quite low in one study.<sup>[5]</sup> The most often association is of craniofacial and musculoskeletal anomalies. Congenital diaphragmatic hernia (CDH) has an overall association with CHD of 40%, which include the known syndromes involving CHD and CDH, while isolated CDH outside of the known syndromes has an association of 11–15% with CHD.<sup>[6]</sup> The incidence for the reverse, that is, CDH associated with CHD is not clearly known. Presence of CDH with pulmonary hypertension is a contraindication to corrective surgery for CHD.

CDH is of three types, posterolateral Bochdalek (75% incidence of all CDH) of which vast majority are left sided, Anterior Morgagni (23% of all CDH) and central (2% of all CDH) and has a spectrum of manifestation from none to severe respiratory and cardiovascular effect. CDH is associated with pulmonary hypoplasia and depending on severity may be associated with severe respiratory compromise requiring endotracheal intubation and mechanical ventilation, persistent pulmonary hypertension of newborn, shock, and left ventricular hypoplasia. The clinical presentation may be of respiratory distress, low oxygen haemoglobin saturation on pulse oxymetry, shock, acidosis, and low partial pressure of oxygen ( $pO_2$ ) in

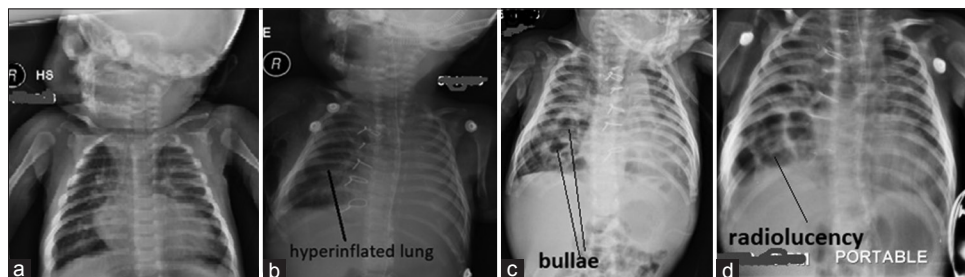
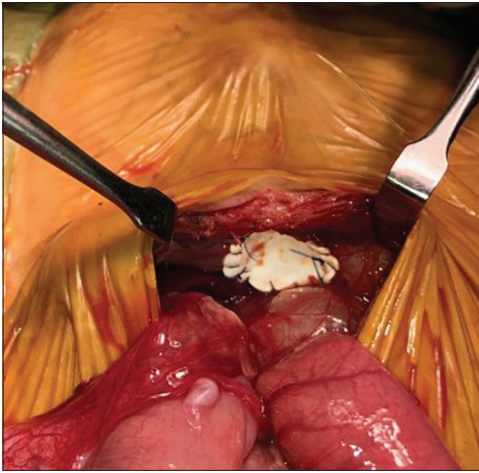


Figure 1: (a) - Preoperative X-ray, original image. (b) - Post operative X-ray showing hyperinflated right lung in X-ray, original image. (c) - post operative X-ray showing supposed bullae, original image. (d) - post operative X-ray showing retrosternal radiolucency, original image



**Figure 2: Original image, surgical field with GORE-TEX patch in diaphragmatic defect and reduced intestinal loops**

arterial blood gas (ABG) analysis, scaphoid abdomen, and decreased breath sound posteriorly on auscultating the chest in case of posterior hernia. A nasogastric tube passed to the stomach would show its tip floating above the diaphragm in a chest X-ray. CT scan of the thorax with radio contrast dye can show the anatomy more clearly.

Mild CDH with congenital cyanotic heart disease (CCHD) may pose diagnostic dilemma. The clinical features of CCHD, including low SpO<sub>2</sub>, tachypnoea, and cyanosis mask the clinical presentation of mild CDH. A scaphoid abdomen would not be found in clinical examination in mild cases, and breath sounds would be heard clearly on auscultation. In our case, the preoperative chest X-ray didn't show bowel loops or radio opacity in the thorax. The scout film of the CT pulmonary angiography also didn't pick up any diaphragmatic anomaly. The initial post-operative chest X-rays consistently showed the tip of the nasogastric tube below the diaphragm and when the CDH was suspected the nasogastric tube has already been removed and patient was on oral feeding.

In a post-operative ventilated patient with a major intrathoracic surgery, there can be multiple reasons for failure to wean from ventilation, which include cardiovascular, respiratory, neurological, musculoskeletal, and metabolic factors. A variety of common intra-thoracic conditions including pneumothorax, hydrothorax, lung collapse, etc. can divert attention from the possibility of a diaphragmatic hernia. In our case, the development of bronchomalacia with evidence of development of lung hyperinflation, a common clinical condition in ventilated neonates and infants, distracted attention from the possibility of herniated bowel loops into thoracic cavity. Similarly, air spaces seen in X-ray which were due to bowel loops in the thorax were mimicking bullae in the lungs, further delaying the diagnosis.

Given that there was no finding of CDH in clinical and imaging studies done preoperatively and the

nasogastric tube tip was consistently intra-abdominal in post-operative X-rays, we hypothesize that post-operative diaphragmatic weakness might have allowed the herniation through a small congenital defect. Diaphragmatic weakness is a well-known entity in patients receiving prolonged mechanical ventilation and is supposedly because of disuse atrophy and microstructural changes.<sup>[7]</sup> Spontaneous respiration creates negative intrathoracic pressure, and that must have promoted the herniation of the bowel loops to the thoracic cavity through the defect. This can explain the delayed presentation of the diaphragmatic hernia in our case, which occurred after weaning from a prolonged period of ventilation. Subsequent reinstatement of positive pressure ventilation may have reduced the bowel loops to abdomen to some extent, giving better X-ray pictures, till further herniation produced the supposed bullae and then the retrosternal radiolucency.

Delayed presentation of CDH is extremely rare.<sup>[1]</sup> To the best of our knowledge, this is the first reported case of a late presenting congenital diaphragmatic hernia complicating the post-operative course of a cardiac surgery patient.

CDH is a relatively common clinical condition in new-born and children and found to be associated with CHD. Perioperative clinician should be aware of CDH as a possible cause of respiratory failure in a child with complex perioperative situation. Clinical suspicion can be confirmed by inserting a nasogastric tube and confirming its placement on a chest X-ray. Also, imaging study with CT scan should be considered to rule out/confirm the diagnosis. If the child is undergoing abdominal/thoracic surgery, visual inspection of the diaphragm intra-operatively should always be preferred. This case highlights the importance of detecting the occult extracardiac anomalies in CHD children, considering the high morbidity/mortality risks attributed to these anomalies.

## Conclusion

Occult CDH can be a cause of respiratory failure or failure to wean from ventilation in postoperative infants and children and may be difficult to diagnose clinically. Awareness of the possibility and early imaging studies can be useful in identifying and providing timely intervention.

## Declaration of patient consent

The authors certify that they have obtained all appropriate patient consent forms. In the form the patient(s) has/have given his/her/their consent for his/her/their images and other clinical information to be reported in the journal. The patients understand that their names and initials will not be published and due efforts will be made to conceal their identity, but anonymity cannot be guaranteed.

### Acknowledgements

Paediatric cardiac intensive care team, Artemis Hospital, Gurugram, Haryana, India-122011.

### Financial support and sponsorship

Nil.

### Conflicts of interest

There are no conflicts of interest.

### References

1. Kim DJ, Chung JH. Late-presenting congenital diaphragmatic hernia in children: The experience of single institution in Korea. *Yonsei Med J* 2013;54:1143-8.
2. Dewangan M. Association of congenital heart diseases with extracardiac anomalies. *Int J Contemp Pediatr* 2017;4:1807-10.
3. Greenwood RD, Rosenthal A, Parisi L, Fyler DC, Nadas AS. Extracardiac abnormalities in infants with congenital heart disease. *Pediatrics* 1975;55:485-92.
4. Rosa RC, Rosa RF, Zen PR, Paskulin GA. Congenital heart defects and extracardiac malformations. *Rev Paul Pediatr* 2013;31:243-51.
5. Tennstedt C, Chaoui R, Körner H, Dietel M. Spectrum of congenital heart defects and extracardiac malformations associated with chromosomal abnormalities: Results of a seven year necropsy study. *BMJ Heart* 1999;82:1-118.
6. Lin AE, Pober BR, Adatia I. Congenital diaphragmatic hernia and associated cardiovascular malformations: Type, frequency, and impact on management. *Am J Med Genet C Semin Med Genet* 2007;145C:201-16.
7. Dres M, Demoule A. Diaphragm dysfunction during weaning from mechanical ventilation: An underestimated phenomenon with clinical implications. *Crit Care* 2018;22:73.