

CASE REPORT

Ultra-high-density mapping to guide effective His-bundle pacing

Gregorio Covino¹ | Paolo Liberato Magliano¹ | Filomena Colimodio¹ |
Claudia Auricchio²  | Ciro Provisiero¹ | Mario Volpicelli¹

¹Asl Na 1 Centro, PO S. Giovanni Bosco, Napoli, Italy

²Boston Scientific, Milan, Italy

Correspondence

Gregorio Covino, Reparto di Cardiologia, Asl NA1 centro, PO S. Giovanni Bosco, Via Filippo Maria Briganti, 255, 80144 Naples (NA), Italy.
Email: covinogregorio@gmail.com

Funding information

This research did not receive any specific grant from funding agencies in the public, commercial, or not-for-profit sectors

Abstract

Permanent His bundle pacing is a physiological alternative to right ventricular pacing, resulting in a lower probability of pacing-induced cardiomyopathy and left ventricular ejection fraction deterioration. The combined use of UHD mapping systems allows precise and detailed information on the His bundle location, possibly providing more pacing option locations.

KEYWORDS

3-D mapping, His bundle pacing, low fluoro, Rhythmia, ultra-high density

1 | INTRODUCTION

Permanent His bundle pacing is emerging as a physiological alternative to right ventricular pacing and may be associated with lower probability of pacing-induced cardiomyopathy.¹ In this report, we present a case of successful His Bundle lead placement guided by an ultra-high-density 3-D mapping system to minimize fluoroscopy time.

2 | CASE HISTORY

A 77-year-old woman, with previous left atrial appendage closure, previous mitral valvuloplasty, heart failure, and severe dilation of the left atrium, was referred to our attention for recurrent episodes of atrial fibrillation and atypical atrial flutter with symptomatic rapid ventricular response and refractoriness to drug therapy aimed at rate control. In accordance with the patient's decision and given the presence of numerous comorbidities, the strategy of implanting a permanent pacemaker with a His bundle lead and subsequent ablation of the atrioventricular node was chosen.

Baseline 12-leads ECG at the time of admission showed atypical atrial flutter with variable atrioventricular conduction ratio and QRS duration of 105ms with incomplete RBBB.

In the electrophysiology laboratory, via right femoral venous access, a ultra-high-density three-dimensional mapping of the entire course of the His Bundle was performed, using the Rhythmia HDX™ system (Boston Scientific) and the basket mapping catheter with 64 printed electrodes IntellaMap Orion™ (Boston Scientific), after placing a 6F (Dynamic XT™, Boston Scientific) decapular deflectable diagnostic catheter in the coronary sinus. The mapping window was set from -104 ms to -28 ms, with respect to the time reference set on the QRS peak of higher voltage, in order to exclude ventricular electrograms and include electrograms from the entire course of the His bundle. In the event of the presence of atrial electrograms within the mapping window, due to the variable atrioventricular conduction ratio, manual re-annotations were carried out in order to correctly mark the component of the signal attributable to His bundle. Figure 1 shows the voltage and activation maps acquired as just described. In total, around 1900 points were acquired in

This is an open access article under the terms of the Creative Commons Attribution-NonCommercial-NoDerivs License, which permits use and distribution in any medium, provided the original work is properly cited, the use is non-commercial and no modifications or adaptations are made.

© 2021 The Authors. *Clinical Case Reports* published by John Wiley & Sons Ltd.

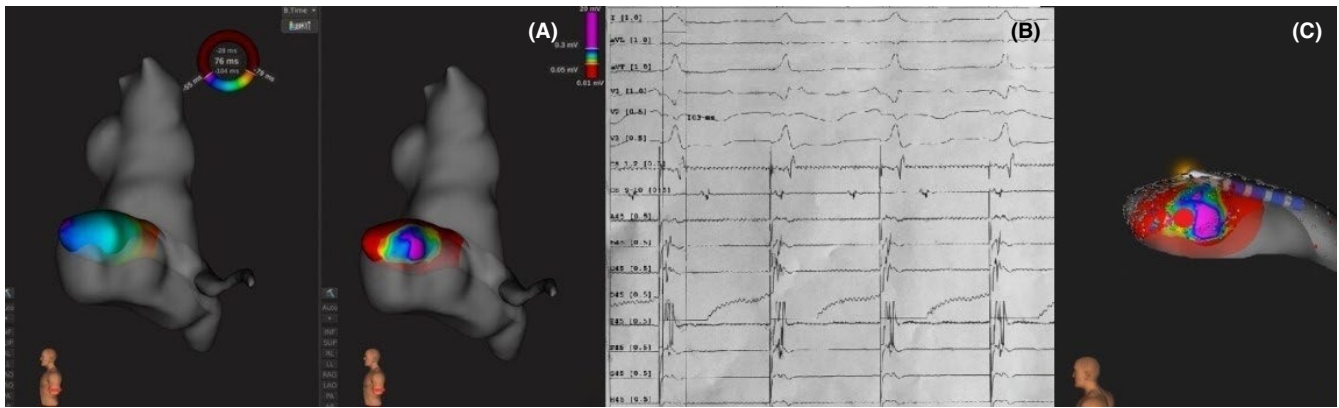


FIGURE 1 (A) Voltage and activation maps of His Bundle; (B) best-paced QRS from IntellamapOrion electrodes. This point of best-paced QRS was tagged as the target for the subsequent lead placement; (C) AV node ablation performed proximal to the position of the implanted HBP lead (red tag)

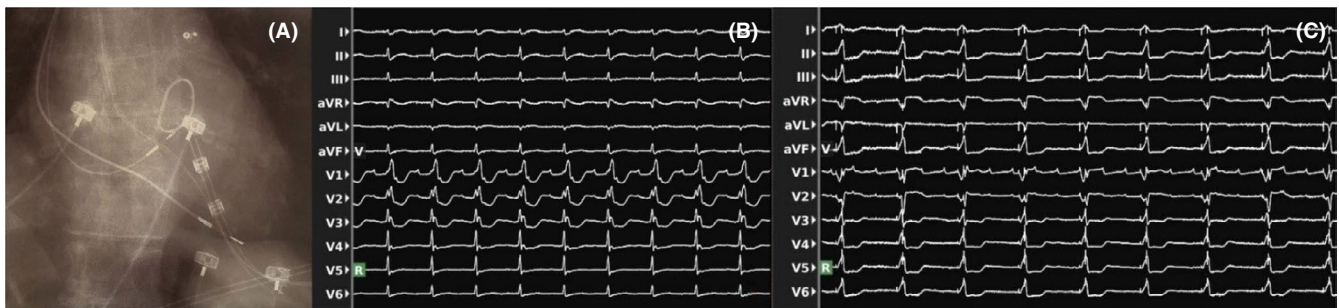


FIGURE 2 (A) Final leads placement in antero-posterior projection; (B) Twelve leads ECG preablation; (C) Twelve leads final rhythm with nonselective His bundle pacing with RV backup pacing after 30 ms, with QRS duration of 107 ms

a time of 2.8 min. By stimulating selectively from the electrodes of the Orion mapping catheter in different sites of His bundle, it was possible to "tag" on the three-dimensional map the location where the morphology and duration of the best-paced QRS complexes were obtained, so as to be able to guide the placement of the permanent pacing lead. The identified target site had a paced QRS duration of 103 ms, with selective His bundle pacing morphology (Figure 1).

Via left subclavian vein access, a dedicated C315™ fixed curve introducer (Medtronic) was used to place a SelectSecure™ (Medtronic) permanent His bundle pacing lead, which was displayed in real time on the three-dimensional map and positioned near the previously identified target zone.

The acquisition of the three-dimensional map using a magnetic technology mapping catheter is, in the case of the Rhythmia system, fundamental for the subsequent visualization of the pacing lead: this is, in fact, traced with impedance technology, but the spatial coordinates of its position are corrected based on the magnetic coordinates previously acquired via the Orion™ Mapping Catheter. This correction gives greater spatial precision to the position on the map

of the lead displayed through impedance tracking. To view the pacing lead on the map, it was sufficient to connect it via a generic two-pin terminal cable of input box A of the Rhythmia HDX™ system and, via software, set it up as any bipolar diagnostic catheter.

In the final positioning site, nonselective His bundle pacing was obtained with the presence of delta wave and QRS duration of 107 ms at energies greater than 1V for 1 ms and exclusively right ventricular pacing with QRS duration of 144 ms at lower energies. The Qr' morphology in lead V1 was attributed to an incomplete RBBB with RSR' preablation QRS morphology. As per our clinical practice, a backup lead was subsequently implanted in the apex of the right ventricle (Figure 2).

Finally, ablation of the atrioventricular node was performed using a steerable 8mm tip ablation catheter (IntellaNav Mifi XP™, Boston Scientific), identifying the ablative target at a location proximal to the His bundle lead implantation site, to avoid blocking the output of His bundle pacing (Figure 1). No peri-procedural or postprocedural complications occurred.

The use of fluoroscopy was limited to venous accesses, to the positioning of the diagnostic catheter in the coronary

sinus, to the mapping phase, and to the control of the position of the lead during fixation (screwing in to secure a stable position), a phase in which it is impossible to visualize the lead because it is necessary to disconnect the cable clamps.

The total fluoroscopy time was 13.6 min with a total dose of 16.40 G * cm². Total procedure time was 75 min, shorter times than the ones we usually need for His bundle catheter implantation without mapping system (average fluoroscopy times of 16.5 min and average procedure times of 85 min).

Three months after the procedure, the patient presents an improvement in the condition of heart failure in terms of symptoms and an increase in the ejection fraction of the left ventricle.

3 | DISCUSSION

In patients with heart failure and atrial fibrillation with rapid ventricular response, permanent implantation of the His bundle lead with subsequent ablation of the atrioventricular node appears to be a safe and effective option to improve cardiac synchrony and, therefore, avoid deterioration of pump function. The use of a mapping system with a multipolar (64 electrodes) catheter allowed us to minimize the use of fluoroscopy, as compared to our routine clinical practice and comparable to that reported with similar approaches with other mapping systems.^{2,3}

In a recent report by Keene et al⁴ approaching with conventional nonmapping approach, the authors reported exposure duration slightly shorter than the one of our experience. Interestingly, they found clear evidence of a learning curve with progressive accumulation of experience related to the reduction of fluoroscopy time and the achievement of lower His bundle capture thresholds.⁴

We are therefore confident that increasing the number of cases approached with our workflow will result in additional benefits in terms of reduction of fluoroscopy time. In addition, there are groups of patients that could benefit most from the proposed workflow, especially for whom the use of fluoroscopy should be avoided (e.g., pregnant or pediatric patients), extending the recommendations reported in the current ESC 2019 guidelines on the management of patients with supraventricular tachycardias.⁵ In addition, the high-density mapping can facilitate the positioning of the His bundle pacing lead, providing precise information on the His bundle location because of the collection of better resolution His electrograms than those detected by the pacing catheter, thus allowing quick identification of the area(s) from which the stimulated QRS has the most ideal morphology. The limits to obtaining selective His bundle pacing are possibly attributable to the choice of the positioning system of the pacing lead and not to the identification of the target site.

4 | CONCLUSIONS

The use of an UHD mapping system seems to be a safe, feasible, and especially useful approach to position a permanent His bundle pacing lead, providing information about His bundle localization and providing more options on the site from which to pace to get the desired result.

ACKNOWLEDGMENTS

We thank Maurizio Malacrida who provided us assistance in writing this report.

CONFLICTS OF INTEREST

C. Auricchio is an employee of Boston Scientific. No other conflicts of interest to declare.

AUTHOR CONTRIBUTIONS

Covino G. and Volpicelli M.; conceived the idea, performed the procedure, and wrote the manuscript with input from all authors. Auricchio C.: supported the procedure as a product specialist. Magliano P.L., Colimodio F., and Provisiero C.: worked on the supporting material. All authors provided critical feedback and helped write the manuscript.

DATA AVAILABILITY STATEMENT

The data that support the findings of this report are available from the corresponding author, C.G. upon reasonable request.

CONSENT STATEMENT

Published with written consent of the patient.

ETHICAL STATEMENT

Appropriate written informed consent was obtained for publication of this case report and accompanying images.

ORCID

Claudia Auricchio  <https://orcid.org/0000-0002-8871-212X>

REFERENCES

1. Vijayaraman P, Dandamudi G, Lustgarten D, Ellenbogen KA. Permanent His bundle pacing: electrophysiological and echocardiographic observations from long-term follow-up. *Pacing Clin Electrophysiol.* 2017;40(7):883-891. <https://doi.org/10.1111/pace.13130>
2. Imnadze G, Vijayaraman P, Bante H, et al. Novel electroanatomical map for permanent his bundle pacing: the Mont Blanc approach – influence of the learning curve and procedural outcome. *Europace.* 2020;22(11):1697-1702. <https://doi.org/10.1093/europace/euaa226>
3. Sharma PS, Huang HD, Trohman RG, et al. Low fluoroscopy permanent His bundle pacing using electroanatomic mapping: a feasibility study. *Circ Arrhythm Electrophysiol.* 2019;12(2):e006967. <https://doi.org/10.1161/CIRCEP.118.006967>

4. Keene D, Arnold AD, Jastrzębski M, et al. His bundle pacing, learning curve, procedure characteristics, safety, and feasibility: insights from a large international observational study. *J Cardiovasc Electrophysiol.* 2019;30(10):1984-1993. <https://doi.org/10.1111/jce.14064>
5. ESC Clinical Practice Guidelines: 2019 Guidelines on Supraventricular Tachycardia (for the management of patients with), <https://doi.org/10.1093/eurheartj/ehz467>. Accessed February 01, 2020.

How to cite this article: Covino G, Magliano PL, Colimodio F, Auricchio C, Provisiero C, Volpicelli M. Ultra-high-density mapping to guide effective His-bundle pacing. *Clin Case Rep.* 2021;9:e04477. <https://doi.org/10.1002/ccr3.4477>