



Original Article

Low power ablation for left coronary cusp ventricular tachycardia—Efficacy and long-term outcome

Kabilan S. Jagadheesan, Santhosh Satheesh, Ajith Ananthkrishna Pillai, Balachander Jayaraman, Raja J. Selvaraj*

Department of Cardiology, Jawaharlal Institute of Postgraduate Medical Education and Research, Puducherry, India



ARTICLE INFO

Article history:

Received 5 May 2018

Accepted 16 August 2018

Available online 1 September 2018

Keywords:

Ventricular tachycardia

Aortic cusp

Ablation

Left coronary cusp

Idiopathic ventricular tachycardia

ABSTRACT

Background: The left coronary cusp is an uncommon but well-known site for the ablation of idiopathic ventricular tachycardia (VT). Proximity to the left coronary ostium makes ablation of this arrhythmia challenging. Different power settings have been described by various operators. Our objective was to describe the outcomes with low power ablation.

Methods: Once mapping confirmed origin from the left coronary cusp, ablation was performed if the best site was situated at least 5 mm from the left coronary ostium. Ablation was started at 15 W and, if successful, was stopped after 30 s. When required, higher powers were used up to 30 W.

Results: Ten patients with VT or premature ventricular beats mapped to the left coronary cusp were included in the study. No ablation was performed in one patient because of proximity to the left coronary ostium. Successful ablation was performed in eight of the other nine patients with a mean power of 18.1 ± 5.3 W and duration of 42.2 ± 13.5 s. There were no complications. All the eight patients remained free of recurrence at 16.8 ± 16.5 months of follow-up.

Conclusions: VT can be ablated from the left coronary cusp close to the left coronary ostium. Ablation with low power is effective in achieving immediate success which is also durable with time while avoiding complications.

© 2018 Cardiological Society of India. Published by Elsevier B.V. This is an open access article under the CC BY-NC-ND license (<http://creativecommons.org/licenses/by-nc-nd/4.0/>).

1. Introduction

The coronary cusps are a relatively uncommon, but a well-described site for ablation of idiopathic ventricular tachycardia (VT) or premature ventricular complexes (PVCs).^{1–3} The left coronary cusp is the commonest site of origin for coronary cusp VT. Radiofrequency ablation is highly effective in the management of patients with symptoms, left ventricular (LV) dysfunction, or very frequent PVCs but also carries risks because of proximity to important structures, especially the proximal coronary arteries. Variable settings have been advocated for radiofrequency ablation in this location, with most operators using settings similar to those for endocardial sites.^{1,4–6} However, if VT originated from local

extensions of myocardium, lower power may be sufficient and safer. We describe our results with the use of low power radiofrequency ablation for the treatment of this arrhythmia.

2. Methods

This is a retrospective study from a single center. Records of patients who underwent radiofrequency ablation at our institute from 2010 until 2017 were screened. All patients in whom the origin of VT or PVCs was mapped to the left coronary cusp were included.

A standard 4-mm tip nonirrigated ablation catheter (Therapy, St. Jude) was used for mapping. A conventional mapping system was used in all the patients. Activation mapping was the primary mapping strategy used in these patients. A region with early local activation assessed by activation time in bipolar electrograms and qS complex in unipolar electrogram from the distal electrode was sought. In patients with outflow tract VT, the right ventricular outflow tract (RVOT) was usually mapped initially. When local activation was not found sufficiently early in the RVOT, LV outflow tract was mapped by a retrograde approach.

Abbreviations: VT, ventricular tachycardia; LCC, left coronary cusp; RCC, right coronary cusp; NCC, non coronary cusp; PVCs, premature ventricular complexes; RVOT, Right ventricular outflow tract; LVOT, Left ventricular outflow tract; RBBB, right bundle branch block; LBBB, left bundle branch block; LMCA, left main coronary artery; RF, radiofrequency.

* Corresponding author. Department of Cardiology, Jawaharlal Institute of Postgraduate Medical Education and Research, Puducherry 605006, India.

E-mail address: rajajs@gmail.com (R.J. Selvaraj).

<https://doi.org/10.1016/j.ihj.2018.08.018>

0019-4832/© 2018 Cardiological Society of India. Published by Elsevier B.V. This is an open access article under the CC BY-NC-ND license (<http://creativecommons.org/licenses/by-nc-nd/4.0/>).

If earliest activation was found in the left coronary cusp, the left main coronary artery was cannulated with a Judkins left coronary catheter introduced from a contralateral femoral arterial puncture. Left coronary angiography was performed, and the catheter was kept in the left main ostium as a marker. Distance from the left main ostium was assessed. Attempt was made to ablate at least 5 mm away and preferably 10 mm away from the ostium. A power-controlled mode was used for ablation with temperature limit of 55 °C. We started with energy of 15 W, increasing to 20 W and occasionally up to 30 W depending on the distance from the left main ostium, impedance drop, tip temperature, and response to ablation. Ablation was stopped if no response was seen within 5–10 s. When elimination of VT or PVCs was seen within 5 s of onset of ablation, power delivery was stopped after 30 s. Coronary angiography was performed after ablation to ensure there was no damage to the coronaries. The patient was monitored for a period of at least 20 min to make sure there was no recurrence.

3. Results

From January 2010 to January 2017, 143 patients underwent ablation of VT or frequent PVCs. Of these, 27 patients had outflow tract tachycardia. Ten of these patients had the origin localized to the left coronary cusp. Electrocardiogram (ECG) of eight patients showed right bundle branch block with inferior axis, while two patients had left bundle branch block with inferior axis, but with a wide R wave in V1 and transition at V2 (Fig. 1).

At the successful site in the left coronary cusp, the local activation time was 50.9 ± 4.5 ms ahead of QRS onset. In nine of 10 patients, delayed fractionated activation was seen in the bipolar

signal during sinus rhythm with reversal of activation for the PVC (Fig. 2).

Coronary angiography was performed in all patients, and no coronary disease was found. In one patient, the earliest site was 2 mm away from the left main coronary ostium. One ablation attempt at a suboptimal site 6 mm away from the left main ostium was not successful, and therefore, no further ablation was performed. In another patient, initial ablation was successful, but PVCs recurred 15 min after radiofrequency (RF) delivery. In view of infrequent PVCs and mild symptoms, no further ablation was attempted. Ablation was successful in the other eight patients. The successful site was at a distance of 8.5 ± 1.9 mm from the ostium of the left main coronary artery. Fig. 3 shows a representative fluoroscopic view of the successful site. On an average 1.4 ± 0.7 RF applications were performed with a mean power of 18.1 ± 5.3 W for a mean ablation time of 42.2 ± 13.5 s. Power of 15 W was used in five patients (62.5%), 20 W in two patients (25%), and 30 W in one patient (12.5%). No patient had any complication. At a mean follow-up of 16.8 ± 16.5 months, all eight patients who had an initial successful ablation were free of recurrences. Table 1 lists the details of all the patients.

4. Discussion

In a group of patients with VT or premature ventricular beats mapped to the left coronary cusp, we found that an approach of using low energy was associated with a high success rate without recurrences. We used power of 15 W with a duration of 30 s in most patients. Our results suggest that use of higher powers may not be necessary, thus reducing the risk of damaging important adjacent structures in this area.

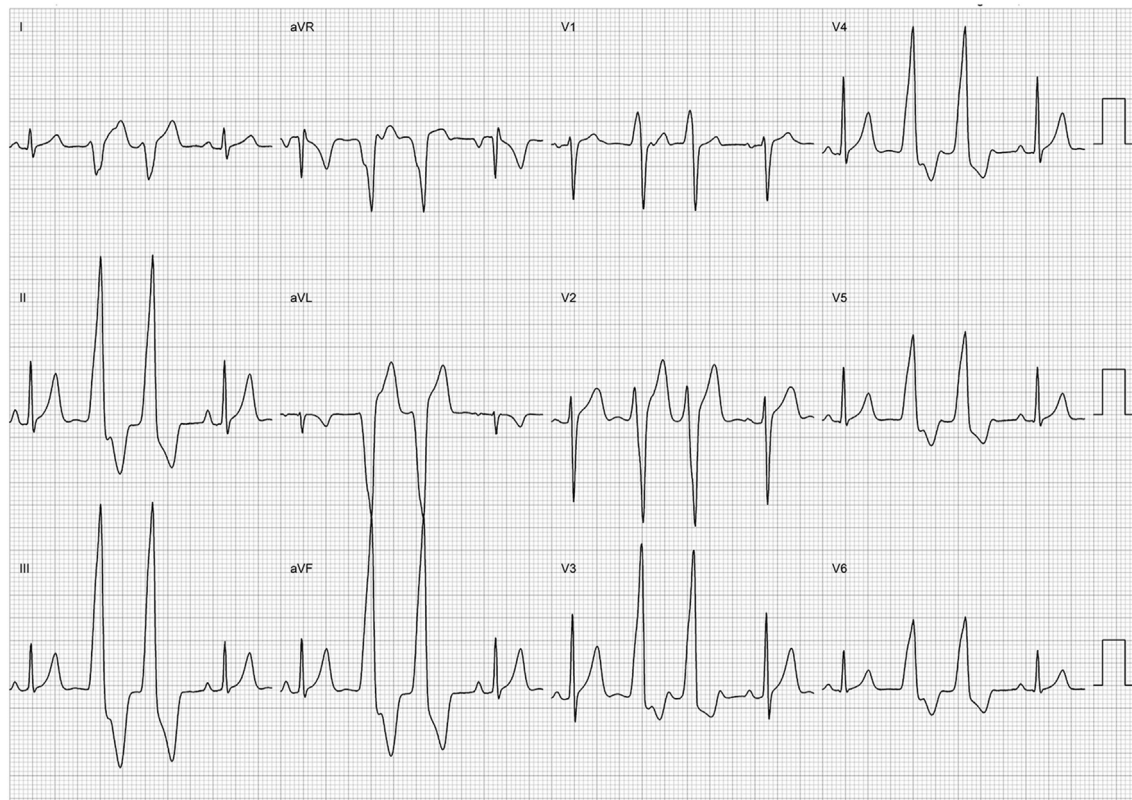

Fig. 1. Representative ECG from a patient with PVCs. Twelve-lead electrocardiogram from a patient with PVCs that were mapped to the left coronary cusp region. PVCs are seen as couplets. Frontal axis is inferior, consistent with outflow tract origin, and while the transition is at V3, a prominent R wave in V1 is suggestive of LVOT origin. ECG, Electrocardiogram; LVOT, left ventricular outflow tract; PVCs, premature ventricular complexes.

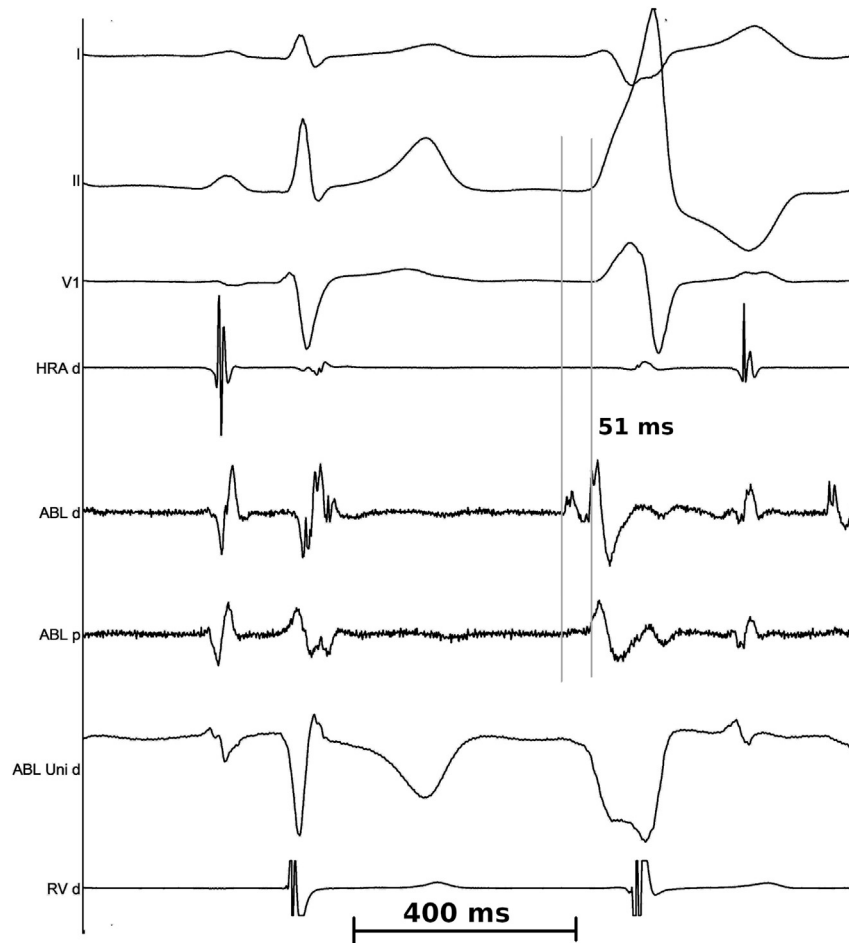

Fig. 2. Intracardiac electrograms showing the signals at the successful site in two patients. Intracardiac electrograms are shown from one patient during mapping of the PVCs. Three ECG leads are shown at the top, followed by a right atrial electrogram, bipolar electrograms from the distal and proximal bipole pairs of the mapping catheter, and a unipolar electrogram from the distal electrode. A fractionated component can be seen in the ventricular electrogram, which is late in the sinus rhythm beat and early before the PVC. ABL, ablation catheter; ECG, Electrocardiogram; PVCs, premature ventricular complexes; RV, right ventricle. HRA, High right atrium

Initial reports on ablation of VT in the aortic cusps mention the use of temperature-controlled setting, maintaining tip temperature of 55–60 °C and maximum power of 25–30 W for 60 s.^{1,4,5} Yamada et al⁶ used an initial power of 30 W and went up to a maximum

power of 50 W with a temperature target of 60 °C. We used a very conservative setting of 15 W for 30 s in most patients. The mean power we used (18.1 ± 5.3 W) and the RF time (mean 42.2 ± 13.5 s) were low, but still resulted in successful ablation with no

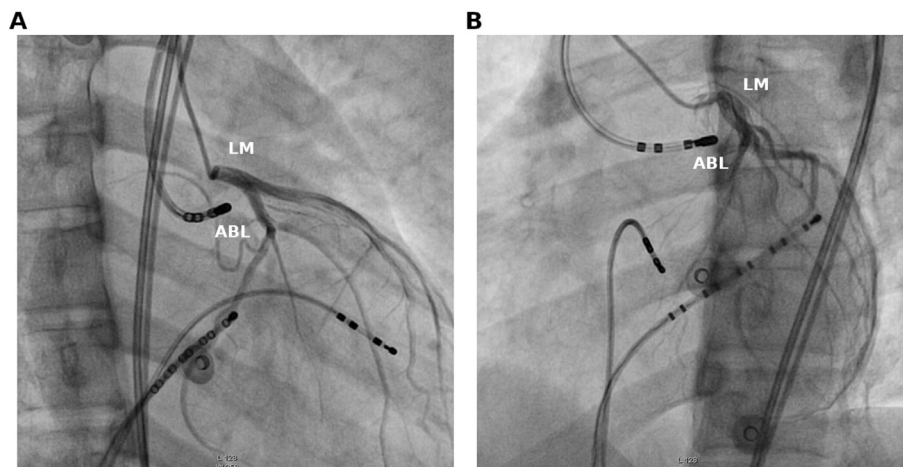


Fig. 3. Fluoroscopic images in LAO and RAO views showing the successful site in a patient with PVCs. Fluoroscopic images are shown in RAO (panel A) and LAO (panel B) views of the position of the ablation catheter at the successful site in a patient with PVCs. Left coronary injection is performed allowing assessment of the distance of the site from the left coronary ostium. ABL, ablation catheter; LM, left main ostium LAO, Left anterior oblique; RAO, Right anterior oblique.

Table 1
Patient and procedural details.

Serial number	Age/sex	Presentation	Arrhythmia	EGM to QRS onset at successful site (ms)	Distance from LMCA ostium (mm)	Max power setting (W)	Total RF number, time (seconds)	Immediate outcome	Follow-up duration (months) and outcome
1	58 y/M	Palpitations	PVCs	42	7	15	1 (30)	Successful	7, no recurrence
2	13 y/M	Palpitations, syncope	PVCs	56	10	30	1 (58)	Successful	2, no recurrence
3	18 y/F	Syncope	VT	50	10	20	3 (50)	Successful	36, no recurrence
4	16 y/M	Asymptomatic	PVCs	50	10	15	3 (103)	Unsuccessful	–
5	18 y/M	Palpitations	PVCs	50	5	15	2 (30)	Successful	47, no recurrence
6	37 y/M	Palpitations	PVCs	50	6	15	1 (30)	Unsuccessful	–
7	32 y/M	Palpitations	VT	48	10	15	1 (60)	Successful	21, no recurrence
8	17 y/M	Palpitations, syncope	VT	55	10	20	1 (30)	Successful	3, no recurrence
9	21 y/M	Palpitations	VT	58	7	15	1 (50)	Successful	7, no recurrence
10	19 y/M	Palpitations	VT	50	9	15	1 (30)	Successful	12, no recurrence

LMCA, left main coronary artery; PVCs, premature ventricular complexes; RF, radiofrequency; VT, ventricular tachycardia.

recurrences. This is similar to settings suggested by Kanagaratnam et al³, who started at 15 W, increasing to not more than 30 W to achieve an impedance drop of 10 Ω .

It was initially considered that VT mapped in the aortic cusp did not originate in the cusp itself, but in the subjacent ventricular myocardium.⁴ Therefore, higher power was considered necessary to create an effective lesion.⁶ However, the prevailing hypothesis is that in most of these patients, VT arises from extensions of muscle bundles above the aortic valve. Hasdemir et al⁸ showed that there are ventricular myocardial extensions extending into the aorta and pulmonary artery beyond the ventriculoarterial junction which were also in continuity with the underlying ventricular muscle of the outflow tract. Our finding of late potentials in sinus rhythm with reversal during VT is consistent with a small mass of myocardium that is activated significantly later than the bulk of the ventricular myocardium. This provides the rationale for using low power to ablate these foci.

Ablation in the left coronary cusp can cause collateral damage to the left main coronary ostium because of its proximity.⁹ Most operators have suggested a cutoff of 10 mm from the coronary ostium⁴ as a safe distance for ablation, although others have suggested that ablation beyond 5 mm may be considered safe.^{7,10} We found that the best site was sometimes situated at a distance of less than 10 mm from the left coronary ostium. Therefore, we attempted ablation as long as the site was a distance of at least 5 mm from the left main ostium but did not use higher powers if it was at a distance of less than 10 mm.

It is important to check the distance in two orthogonal views and preferable to use a separate angiography catheter introduced from a contralateral access to delineate the left main ostium. Intracardiac echocardiography may be an alternative to assess the catheter position in relation to the coronary artery ostia. It has the advantage of continuous monitoring of catheter position, but adds significant cost to the procedure.

We did not use irrigated catheters for ablation in any of the patients. Although ablation with an irrigated catheter may have a lower risk of thromboembolism, we did not consider it necessary as only a superficial lesion was desired. In a report on ablation of aortic cusp VT in 19 patients, an irrigated catheter was used only in three patients because of inadequate power delivery.¹¹ Others have, however, reported using irrigated catheters for ablation more often.^{3,7}

The LV outflow tract is a complex region anatomically, and it is important to map adjacent regions, especially in the left ventricle below the aortic valve and in the great cardiac vein. Ablation from one of these regions may sometimes succeed when ablation within

the cusp is unsuccessful or cannot be performed because of proximity to the coronary ostia.

5. Limitations

The number of patients is small. However, we believe the number is sufficient to ascertain the efficacy of ablation with low power in the short and long term. The proportion of outflow tract PVCs/VT that was ablated from the left coronary cusp is high in our series and may not reflect typical proportions seen in practice. We suspect that this may be because of the referral bias and our generally conservative strategy to treat idiopathic outflow tract PVCs, in which less symptomatic PVCs from RVOT are often managed medically. There may be a subset of patients in which PVCs/VT originates not only from local muscle extensions but also deeper in the LV myocardium. Higher energies and use of irrigated catheters may be required to produce an effective lesion in these patients. Future studies should look at signal characteristics and other markers to identify such patients. Long-term ECG monitoring was not performed during follow-up, and the recurrence was only based on symptoms and ECG findings. However, all these patients had frequent PVCs/non sustained ventricular tachycardia (NSVT) and were symptomatic, so any significant recurrence would have been identified.

6. Conclusions

In patients with VT mapped in the left coronary cusp, the site of ablation is usually located close to the left main coronary artery ostium. Use of low radiofrequency energy, starting at 15 W and increasing to 20 or 30 W in a few patients, was effective in producing acute success. The result was also durable, with no recurrence of tachycardia in any of the patients during a follow-up of more than a year. Our findings suggest that using low energy is sufficient for ablation of VT arising from this region.

Conflict of interest

All authors have none to declare.

Appendix A. Supplementary data

Supplementary data related to this article can be found at <https://doi.org/10.1016/j.ihj.2018.08.018>.

References

1. Shimoike E, Ohnishi Y, Ueda N, Maruyama T, Kaji Y. Radiofrequency catheter ablation of the left ventricular outflow tachycardia from the coronary cusp: a new approach to the tachycardia focus. *J Cardiovasc Electrophysiol.* 1999;10:1005–1009.
2. Sadanaga T, Saeki K, Yoshimoto T, Funatsu Y, Miyazaki T. Repetitive monomorphic ventricular tachycardia of the left coronary cusp origin. *Pacing Clin Electrophysiol.* 1999;22:1553–1556.
3. Kanagaratnam L, Tomassoni G, Schweikert R, et al. Ventricular tachycardia arising from the aortic sinus of Valsava: an underrecognized variant of left outflow tract ventricular tachycardia. *J Am Coll Cardiol.* 2001;37:1408–1414.
4. Hachiya H, Aonuma K, Yamauchi Y, Igawa M, Nogami A, Iesaka Y. How to diagnose, locate, and ablate coronary cusp ventricular tachycardia. *J Cardiovasc Electrophysiol.* 2002;13:551–556.
5. Rillig A, Meyerfeldt U, Birkemeyer R, et al. Catheter ablation within the sinus of Valsalva—a safe and effective approach for treatment of atrial and ventricular tachycardias. *Heart Rhythm.* 2008;5:1265–1272.
6. Yamada T, McElderry HT, Doppalapudi H, et al. Idiopathic ventricular arrhythmias originating from the aortic root prevalence, electrocardiographic and electrophysiologic characteristics, and results of radiofrequency catheter ablation. *J Am Coll Cardiol.* 2008;52:139–147.
7. Ouyang F, Fotugi P, Ho SY, et al. Repetitive monomorphic ventricular tachycardia originating from the aortic sinus cusp: electrocardiographic characterization for guiding catheter ablation. *J Am Coll Cardiol.* 2002;39:500e8.
8. Hasdemir C, Aktas S, Govsa F, et al. Demonstration of ventricular myocardial extensions into the pulmonary artery and aorta beyond the ventriculo-arterial junction. *Pacing Clin Electrophysiol.* 2007 Apr;30(4):534–539.
9. Friedman PL, Stevenson WG, Bihl JA, et al. Left main coronary artery occlusion during radiofrequency catheter ablation of idiopathic outflow tract tachycardia. *Pacing Clin Electrophysiol.* 1997;20:1184.
10. Callans DJ. Ablation of idiopathic ventricular tachycardia. *J Innovat Card Rhythm Manag.* 2012;3:16–23.
11. Bala R, Garcia FC, Hutchinson MD, et al. Electrocardiographic and electrophysiologic features of ventricular arrhythmias originating from the right/left coronary cusp commissure. *Heart Rhythm.* 2010;7:312–322.