

Received: 2019.08.27

Accepted: 2019.11.19

Available online: 2020.01.21

Published: 2020.02.04

Effect of Neotype Rectal Mild Hypothermia Therapy on Intestinal Bacterial Translocation in Rats with Hypoxic-Ischemic Brain Damage

Authors' Contribution:
Study Design A
Data Collection B
Statistical Analysis C
Data Interpretation D
Manuscript Preparation E
Literature Search F
Funds Collection G

BEF 1,2 **Peng Liu***
CDF 1,2 **Xing Deng***
A 3 **Ying Peng**
AD 1,2 **Fang Zhou**
AG 1,2 **Zelan Zuo**

1 Department of Pediatric Intensive Care Unit (PICU), Children's Hospital of Chongqing Medical University, Chongqing, P.R. China
2 Ministry of Education Key Laboratory of Child Development and Disorders, China International Science and Technology Cooperation Base of Child Development and Critical Disorders, Chongqing Key Laboratory of Pediatrics, Chongqing, P.R. China
3 Department of Endoscopy Center, Children's Hospital of Chongqing Medical University, Chongqing, P.R. China

* Peng Liu and Xing Deng contributed equally to this work

Corresponding Authors: Fang Zhou, e-mail: consn@163.com, Zelan Zuo, e-mail: zuozelan@126.com

Source of support: This study was supported by the Application and Development Projects of Chongqing, China

Background: Previous studies have shown that a neotype rectal cooling device can induce mild hypothermia (MH) in Sprague-Dawley rats with ischemic-hypoxic brain damage (HIBD) and inhibit cell apoptosis in the hippocampal CA1 region, and does not cause damage to rectal tissues. The present study aimed to investigate the effect of rectal MH on bacterial translocation (BT) in Sprague-Dawley rats with HIBD.





Material/Methods: A total of 60 Sprague-Dawley rats were randomly divided into 4 groups: a control group (group C), a normothermia group (group NT), a cooling blanket group (group CB), and a rectal cooling group (group RC). Rats in group CB and group RC received MH using a cooling blanket and rectal cooling device after HIBD model establishment. Then, we measured diamine oxidase (DAO) and D-lactate level separately in groups NT, CB, and RC. Finally, the spleen, liver, and mesenteric lymph nodes were collected for bacterial culture, and rectal tissues were collected for H&E staining.

Results: The therapeutic outcome was better in Sprague-Dawley rats receiving rectal MH without rectal injury compared to rats in group CB. *Escherichia coli* (*E. coli*) was found in MLNs in group RC. *E. coli*, *Proteus vulgaris*, *Stenotrophomonas maltophilia*, and *Acinetobacter lwoffii* were detected in the rats of groups CB and NT. At 12 h following rectal MH, DAO and D-lactate levels were lower than in group NT.

Conclusions: The neotype rectal MH cooling method could be a potential strategy to induce rapid, controllable hypothermia, thus reducing the possibility of inflammatory cell infiltration and BT incidence.

MeSH Keywords: Administration, Rectal • Hypothermia, Induced • Hypoxia-Ischemia, Brain

Full-text PDF: <https://www.medscimonit.com/abstract/index/idArt/919680>

 2205  1  4  27



Background

The intestine harbors approximately 500 species of microorganisms, and is considered the largest repository of bacteria and endotoxins. Intestinal bacteria are the primary source of intestinal infections [1,2]. Although intestinal mucosa barrier function plays a vital role in protecting against intestinal pathogenic and non-pathogenic bacteria, the mucosal barrier can be injured by intestinal ischemia and hypoxia, inflammatory mediators, weakened immune system, and dysbacteriosis. Intestinal bacteria enter the lamina propria through the damaged intestinal epithelial cell layer, followed by migration towards the mesenteric lymph nodes (MLNs) or distant organs, thereby resulting in bacterial translocation (BT) and causing systemic inflammation and distal organ damage [3]. Intestinal ischemic reperfusion following the attack of ischemia and hypoxia has been considered a major cause of intestinal infections, sepsis, or multiple organ dysfunction [4].

Hypothermia therapy significantly protects the organs after cardiopulmonary resuscitation in adults and hypoxic-ischemic encephalopathy in infants [5]. However, the effect of mild hypothermia on the preservation of the intestinal barrier remains controversial. Several studies have reported that hypothermia protects the gastrointestinal mucosa, improves gastrointestinal microvascular oxygenation, increases visceral blood perfusion [6], reduces intestinal mucosa microvascular permeability [7], and decreases BT [8]. Furthermore, several other authors hypothesized that hypothermia induces BT in patients with suppressed immune responses and intestinal peristalsis [9].

In a previous study, a novel neotype rectal mild hypothermia cooling method was developed [10]. This device was designed with dual-chamber and closed water storage bladders that remove heat by constant infusion of cold isotonic saline. The ideal cooling effect can be achieved by adjusting the speed of water coming out of the storage bladders. Indirect contact with isotonic saline prevents the occurrence of water intoxication. Previous rat-based studies have confirmed that this method is not only a cooling method, but also inhibits apoptosis in the hippocampal CA1 region of rats with HIBD, without resulting in apparent rectal tissue damage.

Thus, the present study investigated the effect of the neotype rectal mild hypothermia cooling method on the plasma level of D-lactate and DAO, the incidence of BT, and rectal morphology in a HIBD rat model.

Material and Methods

Experimental animals

A total of 60 male healthy Sprague-Dawley rats, weighing 220–280 g, were purchased from the Animal Center of Chongqing Medical University. These animals were housed in a specific pathogen-free (SPF) environment (22–24°C), and fasted for 8 h before the operation. The present study was approved by the Ethics Committee on Animal Experiments of the Animal Center of Chongqing Medical University (Approval Notice 008/2014, date approved 24/1/2014) and was performed in compliance with the Guidelines for Animal Experiments of Chongqing Medical University and the relevant laws.

Establishment of HIBD model

The procedure for establishing the HIBD model was similar to a previously described study [11]. The animals were rectally anesthetized using 10% chloral hydrate (0.3 ml/kg), the median skin of the neck was longitudinally incised, and the left common carotid artery was separated and ligatured twice. The rats were placed back in the chamber after the operation until recovery. Subsequently, a gas mixture (8% oxygen and 92% nitrogen) was constantly released into the chamber at a rate of 2 L/min for 2 h, and maintained at 37°C. The model was successfully established until the appearance of listlessness, hemiplegia, and rotation [11,12]. The animals were given 10% chloral hydrate (0.1 mL/kg) through the rectal route every 2 h to maintain anesthetization.

Rectal cooling group (group RC, n=15)

Approximately 0.5 mL of blood was immediately withdrawn from the femoral artery after the HIBD model was established (zero hour). Then, neotype rectal mild hypothermia cooling devices were connected to these rats through the rectum after lubrication, and cold isotonic saline (4°C) was continuously perfused in the dual chambers, which closed the water storage bladder (5 cm long, 0.8 cm wide, and 2 mL volume). The flow rate was adjusted such that the drip rate remained at a maximum of 160 drops/min. The water outlet was stabilized at 5 cm above the anus of the rat. The speeds of the influent and effluent water were the same. Tympanic temperature was continuously monitored using a tympanic thermometer (ZSGB-BIO, China). Under mild hypothermia (33–35°C) for 12 h, the rats were released back to their cages after blood withdrawal, and re-warming was achieved at a speed of 0.5°C/h for at least 5 h. The animals were sacrificed at 24 h after HIBD.

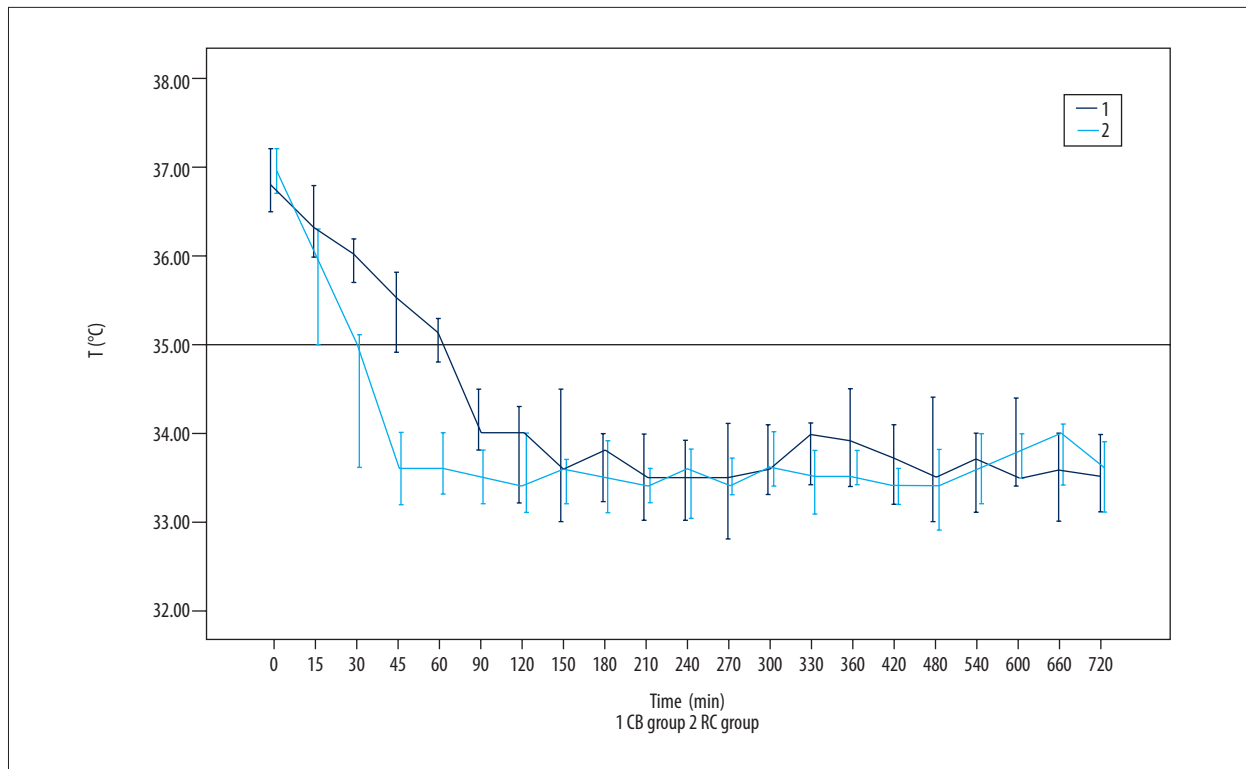


Figure 1. Efficiency of mild hypothermia in groups RC and CB. Tympanic temperature data are presented as mean±SD. During mild hypothermia therapy, the time needed to reach mild hypothermia (35°C) in group RC was 39±12.3 min, which was significantly shorter ($F=2.545$, $P<0.05$) than that in group CB (63.2±19.1 min).

Cooling blanket group (group CB, n=15)

Blood samples were withdrawn after the HIBD model was established. The rats were placed on a cooling blanket (19–22°C) for 12 h to maintain mild hypothermia, re-warmed after blood withdrawal, and sacrificed at 24 h after HIBD.

Normothermia group (group NT, n=15)

Rats with HIBD were freed in cages at room temperature after the establishment of the HIBD model. Blood and organ samples were harvested at the same time points as those in groups RC and CB.

Control group (group C, n=15)

The animals were released after separation of the left common carotid artery. Blood and organs were collected at time points similar to the other groups.

Rectal tissue analysis

Approximately 4 cm of rectal tissue was taken from each rat, fixed in 4% paraformaldehyde, and observed under a light microscope after hematoxylin and eosin (H&E) staining.

DAO and D-lactate analysis

Blood samples were drawn in sterile anticoagulant tubes during the study, and centrifuged at 3000×g for 5 min. Then, the obtained supernatants were stored at –20°C. The levels of DAO (Nanjing Jianchen Bio, China) and D-lactate (Biovision, USA) in the blood samples were quantified according to the manufacturer's protocol.

Identification of bacteria in rat tissues

After anesthetization and shaving, rats were disinfected with povidone-iodine and placed in a sterilized ultraclean cabin padded with a disposable sterile towel. The spleen, liver, and MLNs were collected after a midline incision in the abdomen, and homogenized in a sterile glass homogenizer with 0.5% thio-glycolic acid esters medium. Then, the homogenates were inoculated on blood agar and eosin-methylene blue agar plates (Pangtong Med, China) and the culture plates were incubated for 48 h at 35°C in a 6% CO₂ incubator. Afterwards, the bacterial colonies were isolated from the plates and identified using an automatic bacterial identification instrument by professional staff.

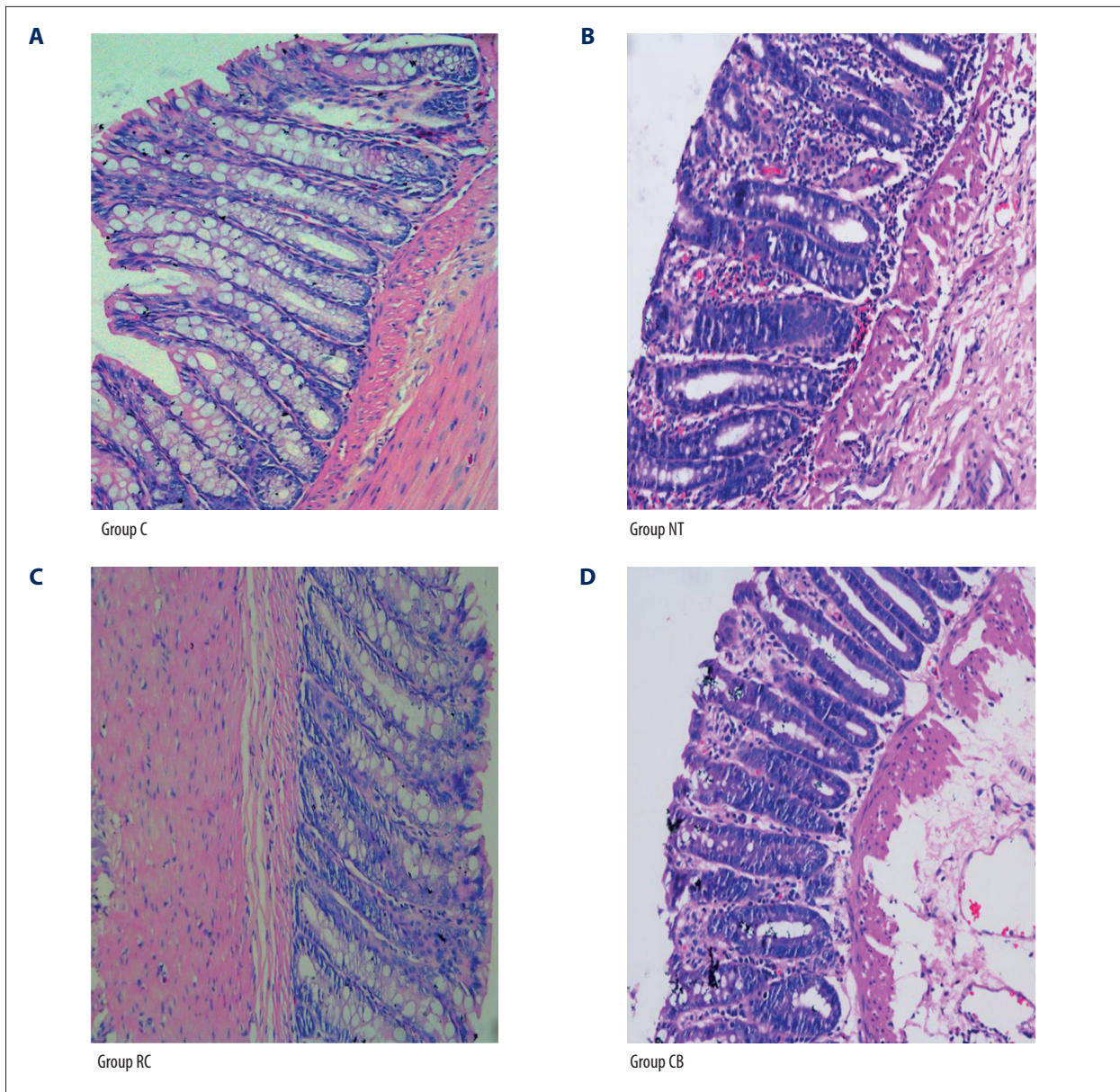


Figure 2. The rectal mucosal H&E staining results of each group ($\times 200$). (A) The rectal mucosal structure of rats was intact with goblet cells between the tightly bound simple columnar cells in group C. (B) Necrotic epithelia were observed, the mucosal structure partially disappeared, the arrangement of cells was disordered, and inflammatory cells and hyperemia were found in each layer in group NT. (C) The rectal structure in group RC was more complete, with fewer inflammatory cells in the submucosa, when compared to group NT. (D) The mucosal structure partially disappeared and many inflammatory cells were observed under the mucosa in group CB.

Statistical analysis

Statistical Product and Service Solutions (SPSS) version 21.0 was used to analyze the results. All data are presented as mean \pm standard deviation (SD). Analysis of variance was performed for comparison among groups. The count data were analyzed by chi-square test. A P -value < 0.05 was considered statistically significant.

Results

The establishment of mild hypothermia was efficient

During mild hypothermia therapy, the time needed to reach mild hypothermia (35°C) in group RC was 39 ± 12.3 min, which was significantly shorter ($F=2.545$, $P<0.05$) than that in group CB (63.2 ± 19.1 min) (Figure 1). During mild hypothermia

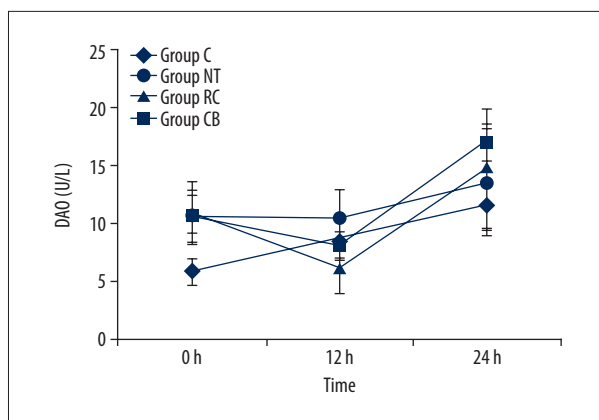


Figure 3. DAO concentrations in each group during mild hypothermia. DAO blood levels are presented as mean ± SD. DAO blood levels at 0, 12, and 24 h after HIBD model establishment were 5.65 ± 1.1, 8.53 ± 1.68, and 11.32 ± 2.05 U/L in group C, 10.43 ± 2.28, 10.31 ± 2.43, and 13.36 ± 4.61 U/L in group NT, 10.71 ± 2.72, 6.1 ± 2.3, and 14.55 ± 5.15 U/L in group RC, and 10.61 ± 1.63, 7.87 ± 1.2 and 16.78 ± 1.6 U/L in group CB.

maintenance, the tympanic temperatures of rats in both groups were maintained at 33–35°C. Due to careful monitoring, no rats died due to temperature recovery-induced adverse effects.

Rectal mild hypothermia therapy preserves intestinal integrity and reduces inflammation in HIBD rats

The rectal mucosal structure of rats in group C was intact, with goblet cells between the tightly bound simple columnar cells. In group NT, necrotic epithelia were observed, the mucosal structure partially disappeared, the arrangement of cells was disordered, and inflammatory cells and hyperemia were found in each layer. The rectal structure of rats in group RC was more complete, with fewer inflammatory cells in the submucosa, when compared to group NT. In group CB, the mucosal structure partially disappeared and many inflammatory cells were observed under the mucosa (Figure 2).

DAO levels in blood

DAO blood levels were significantly higher in groups RC, CB, and NT compared to group C at zero hour (the time point when the HIBD model was established). DAO level in group CB was higher than that in group C at 24 h. In group C, DAO was elevated at 12 and 24 h when compared to that at zero hour, and this was higher at 24 h than at 12 h. Compared to group NT, the level of DAO was significantly lower in group RC at 12 and 24 h. In group RC and CB, DAO levels were significantly decreased at 12 h and increased at 24 h (Figure 3).

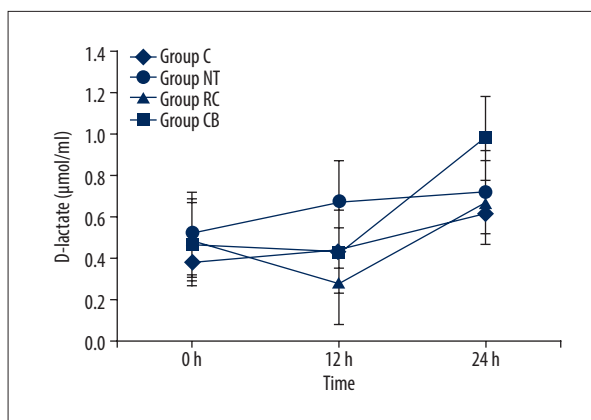


Figure 4. D-lactate concentrations in each group during mild hypothermia. D-lactate blood levels are presented as mean ± SD. D-lactate blood levels at 0, 12, and 24 h after HIBD model establishment were 0.38 ± 0.07, 0.45 ± 0.1, and 0.62 ± 0.1 µmol/ml in group C, 0.53 ± 0.1, 0.68 ± 0.18, and 0.72 ± 0.23 µmol/ml in group NT, 0.49 ± 0.07, 0.28 ± 0.14, and 0.67 ± 0.18 µmol/ml in group RC, and 0.48 ± 0.23, 0.44 ± 0.29, and 0.98 ± 0.34 µmol/ml in group CB.

D-lactate levels in blood

The D-lactate blood levels were significantly higher in groups RC and NT when compared to group C at zero hour. However, D-lactate was significantly lower in group RC than in groups NT and CB at 12 h. Although D-lactate was significantly decreased in group RC and CB at 12 h, when compared to that at zero hour, this increased again at 24 h. Furthermore, D-lactate blood level was higher in group CB at 24 h when compared to group RC and NT (Figure 4).

Bacteria isolated from the different rat groups

Although BT was detected in all groups (Table 1), no significant differences were found in BT among these groups. *Escherichia coli* (*E. coli*) was isolated from MLNs in group C and RC, while *E. coli*, *Proteus vulgaris*, *Stenotrophomonas maltophilia*, and *Acinetobacter lwoffii* were detected in group NT and CB, primarily in MLNs and in the spleen and liver (Table 1).

Discussion

We found that the rectal mild hypothermia cooling method decreased rectal inflammatory infiltration, maintained the integrity of rectal histology, and protected the rectum from injury after HIBD. The rectum in group NT was severely damaged with apparent inflammatory infiltration, indicating rectal injury as a result of HIBD. In contrast, the rectal structure in group RC was more preserved than that in groups NT and CB, with less inflammatory cell infiltration.

Table 1. BT results in each group.

	MLN	Liver	Spleen
Group C	<i>Escherichia coli</i> (3/15)	/	/
Group NT	<i>Escherichia coli</i> (9/15) <i>Proteus vulgaris</i> (2/15) <i>Stenotrophomonas maltophilia</i> (2/15) <i>Acinetobacter lwoffii</i> (1/15)	<i>Stenotrophomonas maltophilia</i> (2/15)	<i>Stenotrophomonas maltophilia</i> (2/15)
Group RC	<i>Escherichia coli</i> (7/15)	/	/
Group CB	<i>Escherichia coli</i> (10/15) <i>Proteus vulgaris</i> (2/15)	<i>Escherichia coli</i> (2/15)	<i>Escherichia coli</i> (2/15)

This table shows the types of bacteria cultured in different parts of the body, as well as the numbers of rats from which each bacterium was found, which would not have been found in a sterile celiac environment.

The intact intestinal mucosal barrier plays a major role in preventing BT [13,14]. In a normal host, intestinal bacterial translocation is associated with few pathogens. However, mesenteric-associated lymphoid tissue maintains the sterility of MLNs and distant organs [15]. Thus, the presence of bacteria in MLNs is considered an indication of bacterial translocation [16]. Bacteria can translocate to distant organs, such as the liver and spleen, via the enterohepatic circulation and lymphatic channel. Some studies have shown that bacteria detected in MLNs in patients suffering from abdominal infection after surgery were the same species isolated from the site of infection [17]. Thus, the detection of intestinal bacteria in normal sterile MLNs is considered direct evidence of BT. The most common bacteria associated with BT are *E. coli*, enterococci, and streptococci [18]. In the present study, BT was discovered in group C. Stress caused by the operation and blood withdrawal was considered to be associated with this phenomenon. Consistent with a published study, MLNs were the most frequent organs for BT in group NT and CB, followed by the liver and spleen, indicating the route of BT in HIBD. Moreover, no significant difference was observed in the incidence of BT between group RC and NT, suggesting that the neotype cooling method can maintain the integrity of the rectum without affecting BT incidence.

DAO blood level has been considered as a specific marker for the state of repair of damaged intestinal mucosa and epithelial cells [19,20]. In the present study, intestinal barrier function and intestinal permeability were impaired when the HIBD model was established. The concentration of blood DAO significantly decreased in group RC at 12 h, indicating improvement of the intestinal barrier and intestinal permeability. However, the DAO blood level increased again in groups RC and CB at 24 h, especially in group CB, which might be associated with the re-warming that might have damaged the intestinal mucosa and epithelial cells.

D-Lactate is also a valid functional indicator of intestinal barrier function [21,22]. Intestinal barrier and intestinal permeability were deemed impaired due to the increase in D-lactate at zero hour in groups RC, NT, and CB. However, in group RC, D-lactate significantly decreased at 12 h, which might be associated with the intestinal temperature decrease directly induced by the neotype mild hypothermia cooling method. Re-warming might be responsible for the elevated level of D-lactate in groups RC and CB at 24 h. The speed of re-warming to normal body temperature after mild hypothermia needs to be regulated. Thus, rapid re-warming can attenuate the protective function of mild hypothermia, while slow re-warming can increase the probability of complications. The optimal time to recovery would be ≥ 12 h at a rate of 0.25–0.5°C/h [23]. In a study of 11 patients who suffered from cerebral aneurysms and underwent removal surgery under hypothermia, 6 patients had increased endotoxin in the blood and 1 patient reached a peak concentration during surgery. The increase in endotoxin in blood might be due to the increased splanchnic perfusion during re-warming. This induces the endotoxin to pass through the intestinal barrier and enter the blood circulation system [24–26]. A study [27] suggested that perfusion of the intestinal mucosa decreases during re-warming after cardiopulmonary bypass surgery, which leads to the severe hypoxia of the intestine. Nevertheless, no standard procedures for re-warming in animals have been established. In the present study, the increasing levels of DAO and D-lactate were correlated with shorter re-warming time.

Conclusions

The neotype rectal mild hypothermia cooling method, as a new approach, can maintain the integrity of rectal endothelium, reduce rectal injury, and protect the intestinal barrier. These novel findings suggest that mild hypothermia has potential therapeutic applications.

References:

1. Young VB: The intestinal microbiota in health and disease. *Curr Opin Gastroenterol*, 2012; 28(1): 63–69
2. Hsiao WW, Metz C, Singh DP et al: The microbes of the intestine: An introduction to their metabolic and signaling capabilities. *Endocrinol Metab Clin North Am*, 2008; 37(4): 857–71
3. Berg RD, Garlington AW: Translocation of certain indigenous bacteria from the gastrointestinal tract to the mesenteric lymph nodes and other organs in a gnotobiotic mouse model. *Infect Immun*, 1979; 23(2): 403–11
4. Steinberg SM: Bacterial translocation: what it is and what it is not. *Am J Surg*, 2003; 186: 301–5
6. Hazinski MF, Field JM: 2010 American Heart Association Guidelines for cardiopulmonary resuscitation and emergency cardiovascular care science. *Circulation*, 2010; 122: 829–61
7. Vollmer C, Schwartges I, Swertz M et al: Hypothermia improves oral and gastric mucosal microvascular oxygenation during hemorrhagic shock in dogs. *Oxid Med Cell Longev*, 2013; 2013: 589–606
8. Childs EW, Udobi KF, Hunter FA: Hypothermia reduces microvascular permeability and reactive oxygen species expression after hemorrhagic shock. *J Trauma*, 2005; 58: 271–77
9. Deniz T, Agalar C, Agalar F et al: The effect of hypothermia on splanchnic flows and lung in a two-hit hemorrhagic shock model. *J Surg Res*, 2010; 158: 121–26
10. GNT0 T, Hazui H, Hoshiga M et al: Bacterial translocation after mild therapeutic hypothermia. *Resuscitation*, 2009; 80: 960
11. Liu P, Yang R, Zuo Z: Application of a novel rectal cooling device in hypothermia therapy after cerebral hypoxia-ischemia in rats. *BMC Anesthesiology*, 2015; 16(1): 77
12. Rice JE 3rd, Vannucci RC, Brierley JB: The influence of immaturity on hypoxic-ischemic brain damage in the rat. *Ann Neurol*, 1981; 9: 131–41
13. Brown AW, Brierley JB: The nature, distribution and earliest stages of anoxic-ischaemic nerve cell damage in the rat brain as defined by the optical microscope. *Br J Exp Pathol*, 1968; 49: 87–106
14. Tlaskalová-Hogenová H, Štěpánková R, Kozáková H et al: The role of gut microbiota (commensal bacteria) and the mucosal barrier in the pathogenesis of inflammatory and autoimmune diseases and cancer: Contribution of germ-free and gnotobiotic animal models of human diseases. *Cell Mol Immunol*, 2011; 8: 110–20
15. Jonker M, Hermsen J, Sano Y et al: Small intestine mucosal immune system response to injury and the impact of parenteral nutrition. *Surgery*, 2010; 9: 24–28
16. Berg RD: Bacterial translocation from gastrointestinal tract. *J Med*, 1992; 3–4: 217–44
17. Deitch AE: Bacterial translocation or lymphatic drainage of toxic products from the gut: What is important in human beings? *Surgery*, 2002; 131: 241–44
18. O'Boyle CJ, MacFie J, Mitchell CJ et al: Microbiology of bacterial translocation in humans. *Gut*, 1998; 42: 29–35
19. Almeida J, Galhenage S, Yu J et al: Gut flora and bacterial translocation in chronic liver disease. *World J Gastroenterol*, 2006; 12: 1493–502
20. Fukudome I, Kobayashi M, Dabanaka K et al: Diamine oxidase as a marker of intestinal mucosal injury and the effect of soluble dietary fiber on gastrointestinal tract. *Med Mol Morphol*, 2014; 47: 100–7
21. Laine L, Takeuchi K, Tarnawski A: Gastric mucosal defense and cytoprotection: Bench to bedside. *Gastroenterol*, 2008; 135: 41–60
22. Swank GM, Deitch EA: Role of the gut in multiple organ failure: Bacterial translocation and permeability changes. *World J Surg*, 1996; 20: 411–17
23. Johnson CD, Kudsk KA: Nutrition and intestinal mucosal immunity. *Clin Nutr*, 1999; 18: 337–44
24. Pichon N, Amiel JB, Francois B et al: Efficacy of and tolerance to mild induced hypothermia after out-of-hospital cardiac arrest using an endovascular cooling system. *Crit Car*, 2007; 11: R71
25. Gaffin SL, Dietz FB, Brock-Utne JG et al: Rewarming from hypothermia leads to elevated plasma lipopolysaccharide concentrations. *Undersea Hyperb Med*, 1999; 27: 1–7
26. Tassopoulos A, Chalkias A, Papalois A et al: The effect of antioxidant supplementation on bacterial translocation after intestinal ischemia and reperfusion. *Redox Rep*, 2017; 22: 1–9
27. Chalkias A, Scheetz MH, Gulati A, Xanthos T: Periarrest intestinal bacterial translocation and resuscitation outcome. *J Crit Care*, 2016; 31(1): 217–20