

Received: 2018.02.20
Accepted: 2018.04.18
Published: 2018.08.20

e-ISSN 1941-5923
© Am J Case Rep, 2018; 19: 978-984
DOI: 10.12659/AJCR.909569

Myocarditis Associated with Drug Reaction with Eosinophilia and Systemic Symptoms (DRESS) Syndrome: A Case Report and Review of the Literature

Authors' Contribution:
Study Design A
Data Collection B
Statistical Analysis C
Data Interpretation D
Manuscript Preparation E
Literature Search F
Funds Collection G

ABCDEF 1 **Daiki Morikawa**
ABCDEF 1 **Eiji Hiraoka**
ABCDEF 2 **Kotaro Obunai**
ABCDEF 3 **Yasuhiro Norisue**

1 Department of Internal Medicine, Tokyo Bay Urayasu Ichikawa Medical Center, Urayasu, Chiba, Japan
2 Department of Cardiology, Tokyo Bay Urayasu Ichikawa Medical Center, Urayasu, Chiba, Japan
3 Department of Critical Care Medicine and Pulmonary Medicine, Tokyo Bay Urayasu Ichikawa Medical Center, Urayasu, Chiba, Japan

Corresponding Author: Eiji Hiraoka, e-mail: eijih@jadecom.jp
Conflict of interest: None declared

Patient: Male, 33
Final Diagnosis: Perimyocarditis associated with drug reaction with eosinophilia and systemic symptoms syndrome
Symptoms: Skin rash
Medication: —
Clinical Procedure: —
Specialty: Dermatology





Objective: Rare disease
Background: Drug reaction with eosinophilia and systemic symptoms (DRESS) is a clinical syndrome that can be life-threatening, depending on the organs involved. Although DRESS commonly presents with skin lesions, myocarditis and pericarditis associated with DRESS, although rare, can be fatal. A case of DRESS associated with myocarditis is presented with a review of the literature of 43 reported cases of DRESS associated with myocarditis that included the present case, to evaluate the effectiveness of treatment of DRESS with corticosteroids.

Case Report: A 33-year-old man presented with fever, diarrhea, and a diffuse maculopapular rash, four weeks after being treated with antibiotics and a nonsteroidal anti-inflammatory drug (NSAID). He developed renal failure, liver dysfunction, and profound hypotension with severe left ventricular dysfunction that required mechanical cardiac support. A diagnosis was made of myocarditis associated with DRESS syndrome. After treatment began with prednisolone, the skin rash, multi-organ dysfunction, and cardiogenic dysfunction resolved.

Conclusions: Myocarditis is a rare complication associated with DRESS, but when it is suspected, urgent echocardiography should be performed, particularly when hemodynamic instability occurs. Early diagnosis, removal of the causative agent, and treatment with corticosteroids are important to reduce mortality from cardiac involvement in patients with DRESS.

MeSH Keywords: Drug Hypersensitivity Syndrome • Myocarditis • Pericarditis

Full-text PDF: <https://www.amjcaserep.com/abstract/index/idArt/909569>

 1840  3  2  44



Background

Drug reaction with eosinophilia and systemic symptoms (DRESS) can be a life-threatening syndrome that can involve several major organs but is usually associated with skin lesions. The scoring system for severe cutaneous adverse drug reactions (RegiSCAR) is helpful in the diagnosis of DRESS syndrome [1,2]. Myocarditis due to DRESS syndrome is rare but can be fatal in up to 55% of cases [3]. The early recognition and prompt removal of the causative agent, and treatment with corticosteroids are important for reducing patient mortality.

A rare case of myocarditis associated with DRESS syndrome is presented with a review of the literature of 43 reported cases of DRESS associated with myocarditis that included the present case, to evaluate the effectiveness of treatment of DRESS with corticosteroids. To our knowledge, this report is the first to highlight the importance of corticosteroids for the treatment of DRESS-associated myocarditis.

Case Report

A 33-year-old Japanese man, with no significant past medical history, presented to our hospital with a two-day history of fever, diarrhea, and a diffuse maculopapular rash. Four weeks prior to presentation, he had been treated with the cephalosporin antibiotic, cefaclor, and a nonsteroidal anti-inflammatory drug (NSAID) for three days after having a tooth extraction. Three weeks later, he developed a cough, nausea, diarrhea, and right parotid gland enlargement and was treated with the quinolone antibiotic, levofloxacin, for four days, but with no improvement.

Two days before admission to hospital, the patient had chills, rigors, a cough, and diarrhea, with a body temperature of 40.0°C. He also developed maculopapular rashes in both arms, which spread throughout the body, including the face, during the following two days. These symptoms resulted in hospital admission.

His vital signs on admission included a body temperature of 37.4°C, blood pressure of 87/45 mmHg, heart rate of 120 beats/min, respiratory rate of 30 breaths/min, and an oxygen saturation of 98% in room air. Erythematous macules and papules on the entire body and facial edema were noted (Figure 1). The Nikolsky sign (blistering on pressure) was negative.

Laboratory investigations showed a white blood cell (WBC) count of $40.4 \times 10^3/\mu\text{L}$, with 10.5% eosinophils and 1.5% atypical lymphocytes, and thrombocytopenia with a platelet count of $44 \times 10^3/\mu\text{L}$. Blood chemistry results showed a blood urea

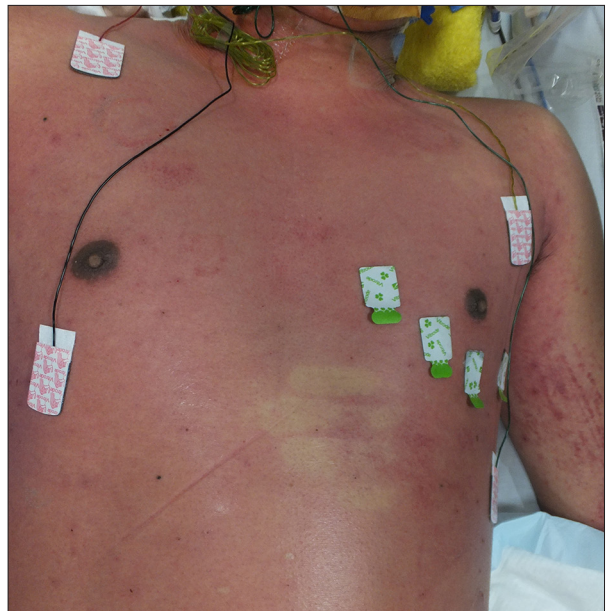

Figure 1. The patient in this case report presented with erythematous macules and papules on the body, typical of drug reaction with eosinophilia and systemic symptoms (DRESS). This macroscopic image shows the maculopapular rashes over the trunk and arm of a 33-year-old Japanese man who presented with drug reaction with eosinophilia and systemic symptoms (DRESS).

nitrogen (BUN) of 74.9 mg/dL, serum creatinine of 6.76 mg/dL, aspartate aminotransaminase (AST) of 1,763 U/mL, and alanine aminotransferase (ALT) of 2,204 U/mL. Also, troponin I was elevated to 7.623 ng/mL.

Serological tests for the presence of hepatitis A IgM antibody, hepatitis B surface antigen, hepatitis C antibody and its polymerase chain reaction (PCR) test, varicella zoster IgM antibody, and cytomegalovirus IgM antibody were all negative, indicating that these viruses were unlikely to be the cause of his condition. Serological testing for Epstein-Barr virus (EBV) was negative for EBV-VCA-IgM, but was positive for EBV-VCA-IgG, and positive for EBV-EBNA, indicating a past history of EBV infection. Serological testing for rubella virus IgM was negative but was positive for rubella virus IgG. Results of serological tests for the presence of human immunodeficiency virus (HIV) antibody were negative. No gastrointestinal parasites were detected on stool testing. The test result for antinuclear antibody (ANA) was negative. Tests for syphilis, including the *Treponema pallidum* hemagglutination assay (TPHA) and the rapid plasma reagin (RPR) test were negative. Skin biopsy and histopathology showed a superficial perivascular dermatitis with lymphocyte infiltrates. An abdominal computed tomography (CT) scan showed slight enlargement of the peri-aortic lymph nodes.

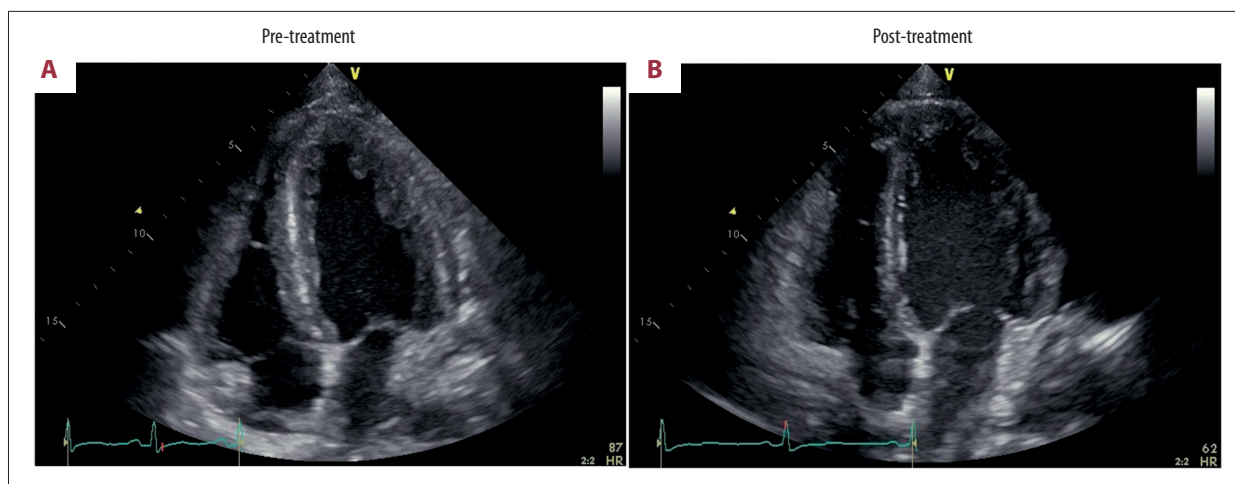


Figure 2. Four-chamber echocardiograms in a 33-year-old Japanese man who presented with drug reaction with eosinophilia and systemic symptoms (DRESS) and myocarditis, taken on hospital admission, and 11 days following treatment with corticosteroids. (A) End-diastolic, apical four-chamber echocardiogram on admission. The cardiac wall thickness, narrowing of the internal lumen, and pericardial effusion are shown. (B) End-diastolic, apical four-chamber echocardiogram 11 days following treatment with corticosteroids. The cardiac abnormalities shown in A have resolved.

Shortly after admission, he developed oliguric azotemia and profound hypotension, requiring hemodialysis and treatment with norepinephrine. Electrocardiography (ECG) showed T-wave inversion in leads II, III, aVF, and V3–6. Echocardiography on the second day following admission showed a left ventricular cavity that was reduced in size due to a thickened and edematous ventricular wall, and pericardial effusion was seen. Left ventricular systolic function was diffusely reduced with left ventricular ejection fraction (LVEF) of 52% (Figure 2A). Coronary artery angiography demonstrated normal coronary arteries.

A provisional diagnosis of cardiogenic shock due to DRESS syndrome-associated myocarditis was made. Following pericardiocentesis, veno-arterial extracorporeal membranous oxygenation (VA ECMO) was commenced. Based on the clinical findings of rash, fever, eosinophilia, and multi-organ involvement (liver, kidney, and heart), a definite diagnosis of DRESS syndrome was made, after excluding other causes of skin rash, fever, and elevated liver enzymes, negative serological panels for HAV, HBV, HCV, and ANA and negative blood culture, and according to the scoring system for severe cutaneous adverse drug reactions (RegiSCAR) (score 8) on the third day following admission (Table 1) [2]. On the same day, treatment with prednisolone, 60 mg/day was commenced.

The skin rash and cardiogenic shock resolved rapidly following treatment with prednisolone. The norepinephrine treatment and the VA ECMO were successfully discontinued two days following the initiation of prednisolone treatment (on day 5). Repeat echocardiography showed marked improvement of the myocardial edema and systolic function on day 14 following admission (Figure 2B). Hemodialysis was discontinued on day 14 following

admission. AST and ALT levels began to decrease one day after corticosteroid administration and normalized two months later. The skin rash resolved completely after five weeks following corticosteroid treatment. Corticosteroids were reduced and tapered in dose by 10 mg every week after four weeks. The patient was discharged home without any sequelae, and corticosteroids treatment was successfully discontinued nine weeks later.

Discussion

Drug reaction with eosinophilia and systemic symptoms (DRESS) syndrome is a life-threatening condition characterized by fever, skin rash, lymph node enlargement, leucocytosis with eosinophilia or atypical lymphocytosis, and multi-organ dysfunction [4,5]. DRESS usually occurs between three weeks to three months after initial treatment with certain types of drugs, and the mortality rate has been reported to be up to 10% [2]. This case report was of a 33-year-old Japanese man who presented with fever, skin rash, eosinophilia, acute renal failure, liver dysfunction, and cardiogenic shock due to myocarditis. According to the scoring system for severe cutaneous adverse drug reactions (RegiSCAR) (Table 1), the RegiSCAR score of this case was 8, and a definitive diagnosis of DRESS syndrome was made [1,2]. In this case, it is possible that previous treatment with the cephalosporin antibiotic, cefaclor, and a nonsteroidal anti-inflammatory drug (NSAID) four weeks prior to hospital admission, were probable case of DRESS, as an association with these drugs have been found in 5% previous case reports [3].

Myocarditis due to DRESS is rare. In 2012, Bourgeois et al. summarized all 22 reported cases of DRESS and myocarditis [3,6–24].

Table 1. Scoring system for classifying drug reaction with eosinophilia and systemic symptoms (DRESS) cases as definite, probable, possible, or no case.

Score	-1	0	1	2
Feve $\geq 38.5^{\circ}\text{C}$	No/U	Yes		
Enlarged lymph nodes	No	No/U	Yes	
Eosinophilia		No/U		
Eosinophils			$0.7-1.499 \times 10^9\text{L}^{-1}$	$\geq 1.5 \times 10^9\text{L}^{-1}$
Eosinophils, if leukocytes $< 4.0 \times 10^9\text{L}^{-1}$			10-19.9%	$\geq 20\%$
Atypical lymphocytes		No/U	Yes	
Skin involvement				
Skin rash extent (% body surface area)		No/U	$> 50\%$	
Skin rash suggesting DRESS		U	Yes	
Biopsy suggesting DRESS	No	Yes/U		
Organ involvement				
Liver		No/U	Yes	
Kidney		No/U	Yes	
Muscle/heart		No/U	Yes	
Pancreas		No/U	Yes	
Other organ		No/U	Yes	
Resolution ≥ 15 days	No/U	Yes		
Evaluation of other potential causes				
Antinuclear antibody				
Blood culture				
Serology for HAV/HBV/HCV				
Chlamydia/mycoplasma				
If none positive and ≥ 3 of the above negative			Yes	

DRESS – drug reaction with eosinophilia and systemic symptoms; U – unknown/unclassifiable; HAV – hepatitis A virus; HBV – hepatitis B virus; HCV – hepatitis C virus. * After exclusion of other explanations: 1, one organ; 2, two or more organs. Final score < 2 , no case; final score 2–3; possible case; final score 4–5 probable case; final score > 5 , definite case. Reproduced from Cacoub et al. [2], with permission from the American Journal of Medicine.

As part of this case report and review of the literature, a search of the PubMed database was undertaken, using the keywords and phrases, ‘DRESS,’ ‘drug-induced hypersensitivity syndrome,’ and ‘myocarditis,’ and found a further 20 case reports of DRESS-related myocarditis from 2012 to 2018 [25–43]. This literature search allowed the review of the clinical findings of a total of 43 cases of DRESS-associated myocarditis, including the present case [3,6–43]. Minocycline was the most common causative agent (seven cases), followed by allopurinol (four cases), ampicillin (three cases), dapsone (three cases), and trimethoprim-sulfamethoxazole (TMP-SMX) (two cases) [3,6–43]. Other causative agents included phenytoin, cephalexin, cefaclor,

phenobarbital, ciprofloxacin, allopurinol, carbamazepine, cephalexin, modafinil, azithromycin, vancomycin, zonisamide, pyrimethamine, diclofenac, amitriptyline, lorazepam, clozapine, clonazepam, isoniazid, lamotrigine, and sulfasalazine [3,6–43].

On review of the literature, the onset of myocarditis after the appearance of a skin rash ranged from a few hours to two years, with a median of 30 days and an interquartile range (IQR) of between 11–87 days [3,6–43]. All cases described a nonspecific rash accompanied by cardiac manifestations, including hypotension, tachycardia, dyspnea, and/or chest pain [3,6–43]. Of the 43 cases, 24 patients (56%) had tachycardia; 25 patients

Table 2. Clinical characteristics of patients with drug reaction with eosinophilia and systemic symptoms (DRESS) on admission, and outcome, from the literature.

	All N=43	No corticosteroid use N=7	Corticosteroid use N=36	P-value*
Age mean (SD)	32 (±18)	30 (±26)	33 (±16)	0.80
Male, n (%)	20 (47%)	5 (71%)	15 (41%)	0.22
Hypotension** on admission, n (%)	24 (56%)	3 (42.9%)	21 (58.3%)	0.68
EF <30%, n (%)	14 (33%)	0 (0%)	14 (41%)	0.28
Other immunosuppression or IVIG treatment, n (%)	11 (26%)	0 (0%)	11 (31%)	0.31
Outcome				
In-hospital death, n (%)	19 (44%)	6 (85.7%)	13 (36%)	0.03
Full recovery of cardiac function, n (%)	21 (49%)	1 (14%)	20 (55%)	0.09

SD – standard deviation; EF – ejection fraction; IVIG – intravenous immunoglobulin. * Dichotomous variables were analyzed and compared by using the χ^2 test. SPSS software version 22 (IBM Corporation, Armonk, NY, USA) was used to perform the statistical analysis. ** Hypotension was defined as systolic blood pressure <100 mmHg or documentation of hypotension in case no definite blood pressure was noted in each case report.

Table 3. Factors associated with in-hospital death for of patients with drug reaction with eosinophilia and systemic symptoms (DRESS), from the literature.

Factor	n	Death, n (%)	OR (unadjusted)*	OR (adjusted)**
Age >50	6	1 (17%)	0.21 (0.02–1.9)	
Hypotension on admission***	24	9 (38%)	0.54 (0.16–1.8)	
EF <30%	15	5 (35%)	0.60 (0.16–2.2)	0.97 (0.24–3.9)
No corticosteroid	7	6 (86%)	10.6 (1.1–98)#	10.5 (1.1–104)#

* Dichotomous variables were analyzed and compared by using the χ^2 test. ** Multivariate logistic regression analysis was performed. Adjusted for EF <30% and no use of corticosteroids. SPSS software version 22.0 (IBM Corporation, Armonk, NY, USA) was used to perform the statistical analysis. *** Hypotension was defined as in Table 1. EF – ejection fraction; OR – odds ratio. # P=0.044.

(58%) had dyspnea; 24 patients (56%) had hypotension; 18 patients (42%) had chest pain [3,6–43]. Twenty-five cases (58%) had elevated cardiac enzymes; 32 patients (74%) had left ventricular dysfunction on echocardiography; and 35 patients (81%) had abnormal electrocardiography (ECG) findings [3,6–43]. Mortality was recorded in 19 cases (44%), and there were two cases (5%) of long-term heart failure [3,6–43]. Considering that the overall mortality has previously been reported to be as low as 10% for DRESS syndrome [2], cardiac involvement in patients with DRESS syndrome results in poor prognosis and an increased mortality rate. Literature review showed that endomyocardial biopsy was performed in 26 cases (60%) [3,6–43]. The cardiac histology has been reported to show more intense infiltrates of lymphocytes and eosinophils and myocyte necrosis [44]. The literature review of cases of DRESS-associated myocarditis showed that the cause of

death included ventricular fibrillation, malignant tachyarrhythmia, and asystole [3,6–43]. The median time (25th, 75th percentile) between admission and death was two days (1.5, 5.5) in 19 patients studied, and 10 (52%) of 19 patients died within 72 hours. Review of the literature showed that treatment for DRESS-associated myocarditis included corticosteroids, intravenous immunoglobulin (IVIG), antihistamine, azathioprine, mycophenolate, muromonab-CD3, cyclosporine, rituximab, and plasmapheresis [3,6–43]. Some cases required pericardiocentesis, pericardiectomy, the use of an intra-aortic balloon pump (IABP), or a left ventricular assist device (LVAD) [3,6–43].

The findings of the literature review allowed the evaluation of the effectiveness of corticosteroid treatment for DRESS-associated myocarditis, which was used in 36 cases (84%), including the present case [3,6–43]. Although there was no

statistically significant difference in baseline characteristics between the corticosteroid-treated and the noncorticosteroid-treated groups, the corticosteroid group included more patients with hypotension and a low ventricular ejection fraction (EF) (Table 2) [3,6–43]. Among the corticosteroid-treated group, 11 patients (31%) received other forms of immunosuppressive treatments, including intravenous immunoglobulin (IVIG), and these forms of treatment might have contributed their improved clinical outcome (Table 2). Patient mortality was 36% and 86% in the corticosteroid-treated group and the noncorticosteroid-treated group, respectively ($p=0.03$) [3,6–43]. Corticosteroid treatment was associated with decreased mortality according to the results of multivariate logistic regression analysis (Table 3) [3,6–43].

To our knowledge, this case report, supported by a review of the literature, is the first to confirm the importance of corticosteroids for the treatment of DRESS-associated myocarditis, although only case reports have supported this finding [3,6–43]. However, because only PubMed was searched for the literature review for cases of DRESS-associated myocarditis, and some case reports may have been missed. The review of the literature has shown that only case reports have been published on DRESS-associated myocarditis and that, at this time,

no controlled clinical studies have been undertaken to evaluate the most effective treatment and treatment schedules.

Conclusions

A rare case of drug reaction with eosinophilia and systemic symptoms (DRESS) syndrome complicated by severe myocarditis has been presented, which showed a response to treatment with corticosteroids. A review of the literature of previously reported cases (42 previously reported cases) supported that myocarditis can be a fatal, but an under-diagnosed manifestation of DRESS syndrome that may occur long after the onset of symptoms of DRESS. Myocarditis should be considered, and echocardiography should be performed urgently in cases of DRESS syndrome, especially when hemodynamic instability occurs. Early recognition, prompt removal of the causative agent and treatment with corticosteroids is important for treating the potentially life-threatening condition of DRESS-associated myocarditis.

Conflict of interest

None.

References:

1. Kardaun SH, Sidoroff A, Valeyrie-Allanore L et al: Variability in the clinical pattern of cutaneous side-effects of drugs with systemic symptoms: Does a DRESS syndrome really exist? *Br J Dermatol*, 2007; 156: 609–11
2. Cacoub P, Musette P, Descamps V et al: The DRESS syndrome: A literature review. *Am J Med*, 2011; 124: 588–97
3. Bourgeois GP, Cafardi JA, Groysman V, Hughey LC: A review of DRESS-associated myocarditis. *J Am Acad Dermatol*, 2012; 66: e229–36
4. Kano Y, Shiohara T: The variable clinical picture of drug-induced hypersensitivity syndrome/drug rash with eosinophilia and systemic symptoms in relation to the eliciting drug. *Immunol Allergy Clin North Am*, 2009; 29: 481–501
5. Sullivan JR, Shear NH: The drug hypersensitivity syndrome: What is the pathogenesis? *Arch Dermatol*, 2001; 137: 357–64
6. Pursnani A, Yee H, Slater W, Sarswat N: Hypersensitivity myocarditis associated with azithromycin exposure. *Ann Intern Med*, 2009; 150: 225–26
7. Bourgeois GP, Cafardi JA, Groysman V et al: Fulminant myocarditis as a late sequelae of DRESS-2 cases. *J Am Acad Dermatol*, 2011; 65: 889–90
8. Arsenovic N, Sheehan L, Clark D, Moreira R: Fatal carbamazepine induced fulminant eosinophilic (hypersensitivity) myocarditis: Emphasis on anatomical and histological characteristics, mechanisms and genetics of drug hypersensitivity and differential diagnosis. *J Forensic Leg Med*, 2010; 17: 57–61
9. Shaughnessy KK, Bouchard SM, Mohr MR et al: Minocycline-induced drug reaction with eosinophilia and systemic symptoms (DRESS) syndrome with persistent myocarditis. *J Am Acad Dermatol*, 2010; 62: 315–18
10. Ben m'rad M, Leclerc-Mercier S, Blanche P et al: Drug-induced hypersensitivity syndrome: clinical and biologic disease patterns in 24 patients. *Medicine*, 2009; 88: 131–40
11. Eshki M, Allanore L, Musette P et al: Twelve-year analysis of severe cases of drug reaction with eosinophilia and systemic symptoms: A cause of unpredictable multiorgan failure. *Arch Dermatol*, 2009; 145: 67–72
12. Sabatine MS, Poh KK, Mega JL et al: Case records of the Massachusetts General Hospital. Case 36-2007. A 31-year-old woman with rash, fever, and hypotension *N Engl J Med*, 2007; 357: 2167–78
13. Chikwava KR, Savell VH, Boyd TK: Fatal cephalosporin-induced acute hypersensitivity myocarditis. *Pediatr Cardiol*, 2006; 27: 777–80
14. Teo RY, Tay YK, Tan CH et al: Presumed dapson-induced drug hypersensitivity syndrome causing reversible hypersensitivity myocarditis and thyrotoxicosis. *Ann Acad Med Singapore*, 2006; 35: 833–36
15. Zaidi AN: Anticonvulsant hypersensitivity syndrome leading to reversible myocarditis. *Can J Clin Pharmacol*, 2005; 12: 33–40
16. Lee CW, Mitchell RN, Horan RF, Castells MC: Cardiogenic shock and peripheral eosinophilia in a young woman. *Ann Allergy Asthma Immunol*, 2005; 95: 229–33
17. Chan YC, Tay YK, Ng SK: Allopurinol hypersensitivity syndrome and acute myocardial infarction – two case reports. *Ann Acad Med Singapore*, 2002; 31: 231–33
18. Aggarwal A, Bergin P, Jessup P, Kaye D: Hypersensitivity myocarditis presenting as cardiogenic shock. *J Heart Lung Transplant*, 2001; 20: 1241–44
19. Arima M, Kanoh T, Yamasaki A et al: Eosinophilic myocarditis associated with toxicodermis caused by phenobarbital. *Jpn Circ J*, 1998; 62: 132–35
20. Beghetti M, Wilson GJ, Bohn D, Benson L: Hypersensitivity myocarditis caused by an allergic reaction to cefaclor. *J Pediatr*, 1998; 132: 172–73
21. Parneix-Spake A, Bastuji-Garin S, Lobut J et al: Minocycline as possible cause of severe and protracted hypersensitivity drug reaction. *Arch Dermatol*, 1995; 131: 490–91
22. Garty BZ, Offer I, Livni E, Danon YL: Erythema multiforme and hypersensitivity myocarditis caused by ampicillin. *Ann Pharmacother*, 1994; 28: 730–31
23. deMello DE, Liapis H, Jureidini S et al: Cardiac Localization of eosinophil-granule major basic protein in acute necrotizing myocarditis. *N Engl J Med*, 1990; 323: 1542–45
24. Herzog CA, Snover DC, Staley NA: Acute necrotizing eosinophilic myocarditis. *Br Heart J*, 1984; 52: 343–48
25. Mitoff PR, Mesana TG, Mielniczuk LM et al: Giant cell myocarditis in a patient with a spondyloarthropathy after a drug hypersensitivity reaction. *Can J Cardiol*, 2013; 29: 1138.e1137–e1138
26. Swart LE, Koster K, Torn M et al: Clozapine-induced myocarditis. *Schizophr Res*, 2016; 174: 161–64

27. Ho C, Uzunyan M: Myocarditis in drug rash with eosinophilia and systemic symptoms. *Cardiol Young*, 2015; 25: 1210–13
28. Wu PA, Anadkat MJ: Fever, eosinophilia, and death: A case of minocycline hypersensitivity. *Cutis*, 2014; 93: 107–10
29. Jeremic I, Vujasinovic-Stupar N, Terzic T, Damjanov N, Nikolic M, Bonaci-Nikolic B: Fatal Sulfasalazine-Induced Eosinophilic Myocarditis in a Patient with Periodic Fever Syndrome. *Med Princ Pract* 2015;24: 195-197.
30. Kanno K, Sakai H, Yamada Y, Iizuka H: Drug-induced hypersensitivity syndrome due to minocycline complicated by severe myocarditis. *J Dermatol*, 2014; 41: 160–62
31. Lo MH, Huang CF, Chang LS et al: Drug reaction with eosinophilia and systemic symptoms syndrome associated myocarditis: A survival experience after extracorporeal membrane oxygenation support. *J Clin Pharm Ther*, 2013; 38: 172–74
32. Pereira CM, Vaz M, Kotha S, Santosh NH: Dapsone hypersensitivity syndrome with myocarditis. *J Assoc Physicians India*, 2014; 62: 728–31
33. Zhu KJ, He FT, Jin N et al: Complete atrioventricular block associated with dapsone therapy: A rare complication of dapsone-induced hypersensitivity syndrome. *J Clin Pharm Ther*, 2009; 34: 489–92
34. Park Y, Ahn SG, Ko A et al: Hypersensitivity myocarditis confirmed by cardiac magnetic resonance imaging and endomyocardial biopsy. *Korean J Intern Med*, 2014; 29: 236–40
35. Teo RY, Tay YK, Tan CH et al: Presumed dapsone-induced drug hypersensitivity syndrome causing reversible hypersensitivity myocarditis and thyrotoxicosis. *Ann Acad Med Singapore*, 2006; 35: 833–36
36. Bourgeois GP, Cafardi JA, Groysman V et al: Fulminant myocarditis as a late sequela of DRESS: Two cases. *J Am Acad Dermatol*, 2011; 65: 889–90
37. Hoogeveen RM, van der Bom T, de Boer HH et al: A lethal case of the dapsone hypersensitivity syndrome involving the myocardium. *Neth J Med*, 2016; 74: 89–92
38. Zhang SN, He QX, Yang NB et al: Isoniazid-induced drug rash with eosinophilia and systemic symptoms (DRESS) syndrome presenting as acute eosinophilic myocarditis. *Intern Med*, 2015; 54: 1227–30
39. Uhara H, Saiki M, Kawachi S et al: Clinical course of drug-induced hypersensitivity syndrome treated without systemic corticosteroids. *J Eur Acad Dermatol Venereol*, 2013; 27: 722–26
40. Eppenberger M, Hack D, Ammann P et al: Acute eosinophilic myocarditis with dramatic response to steroid therapy: The central role of echocardiography in diagnosis and follow-up. *Tex Heart Inst J*, 2013; 40: 326–30
41. Hirata I, Kimizu T, Ikeda T et al: [The case of baby girl who died of fulminant myocarditis by drug induced hypersensitivity syndrome caused by lamotrigine.] *No To Hattatsu*, 2013; 45: 243–44 [in Japanese]
42. Menter T, Tzankov A: Drug reaction, eosinophilia, and systemic symptoms (DRESS) syndrome associated with allopurinol leading to acute necrotizing eosinophilic myocarditis and death due to papillary muscle rupture. *J Allergy Clin Immunol Pract*, 2016; 4: 1262–64
43. Thongsri T, Chularojanamontri L, Pichler WJ: Cardiac involvement in DRESS syndrome. *Asian Pac J Allergy Immunol*, 2017; 35: 3–10
44. Shaughnessy KK, Bouchard SM, Mohr MR et al: Minocycline-induced drug reaction with eosinophilia and systemic symptoms (DRESS) syndrome with persistent myocarditis. *J Am Acad Dermatol*, 2010; 62: 315–18