

# Three-dimensional finite element analysis of temporomandibular joints in patients with jaw deformity during unilateral molar clenching before and after orthognathic surgery

Haidong Teng, BS<sup>a,b</sup>, Jingheng Shu, MS<sup>a,b</sup>, Quanyi Wang, MS<sup>a</sup>, Bingmei Shao, PhD<sup>a,b</sup>, Tinghui Zheng, PhD<sup>a,b</sup>, Zhan Liu, PhD<sup>b,\*</sup>

## Abstract

To analyze the effects of orthognathic surgery on stress distributions in the temporomandibular joint (TMJ) of patients with jaw deformity during unilateral molar clenching (UMC) by using three-dimensional (3D) finite element method.

Nine patients with jaw deformity (preoperative group,  $26.1 \pm 5.6$  years old) and 9 asymptomatic subjects (control group,  $22.0 \pm 6.0$  years old) were selected. Furthermore, the patients with jaw deformity were also considered as the postoperative group after undergoing orthognathic surgery. Finite element models for the mandible, articular disc, and maxilla were developed through cone beam computed tomography. Contact was used to simulate the interaction of the articular disc, condyle, fossa, and upper and lower dentition. The muscle forces and boundary conditions corresponding to the UMC were applied on the models.

The stresses on both TMJs of the control group were significantly different, whereas there was no significant difference on both sides for the preoperative group. All the stresses of the preoperative group were greater than those of the control and postoperative groups, except the minimum principal stress on the ipsilateral fossa.

Orthognathic surgery is beneficial for alleviating the abnormal stress distributions on TMJ.

**Abbreviations:** 3D = three-dimensional, CBCT = cone-beam computed tomography, DICOM = Digital Imaging and Communications in Medicine, DOF = degrees of freedom, SSRO = sagittal split ramus osteotomy, TMD = temporomandibular disorder, TMJ = temporomandibular joint, UMC = unilateral molar clenching, UMC-L = unilateral molar clenching by left, UMC-R = unilateral molar clenching by right.

**Keywords:** jaw deformity, orthognathic surgery, temporomandibular joint (TMJ), three-dimensional finite element analysis, unilateral molar clenching (UMC)

Editor: Kuang-Ming Liao.

This study was supported by the National Natural Science Foundation of China under Grant number 31670963, Strategic cooperation project between Sichuan University and Yibin municipal people's government under Grant number 2019CDYB-16 and Fundamental Research Funds for the Central Universities of China.

The authors declare no conflict of interest related to this study.

Supplemental Digital Content is available for this article.

The datasets generated during and/or analyzed during the current study are available from the corresponding author on reasonable request.

<sup>a</sup> Key Lab for Biomechanical Engineering of Sichuan Province, Sichuan University, Chengdu, <sup>b</sup> Yibin Institute of Industrial Technology/Sichuan University Yibin Park, Yibin, China.

\* Correspondence: Zhan Liu, Key Lab for Biomechanical Engineering of Sichuan Province, Sichuan University, Chengdu, China, No.24 South Section 1, Ring Road No.1, Chengdu 610065, China (e-mail: bmeluzhan@163.com).

Copyright © 2021 the Author(s). Published by Wolters Kluwer Health, Inc. This is an open access article distributed under the terms of the Creative Commons Attribution-Non Commercial License 4.0 (CCBY-NC), where it is permissible to download, share, remix, transform, and buildup the work provided it is properly cited. The work cannot be used commercially without permission from the journal.

How to cite this article: Teng H, Shu J, Wang Q, Shao B, Zheng T, Liu Z. Three-dimensional finite element analysis of temporomandibular joints in patients with jaw deformity during unilateral molar clenching before and after orthognathic surgery. *Medicine* 2021;100:7(e24540).

Received: 16 December 2019 / Received in final form: 30 November 2020 / Accepted: 10 January 2021

<http://dx.doi.org/10.1097/MD.00000000000024540>

## 1. Introduction

Jaw deformities not only negatively affect a patient's appearance, chewing, and other oral functions but also cause self-abasement and other psychological disorders. Moreover, they can cause temporomandibular disorder (TMD). Mandibular prognathism is the most common maxillofacial deformity, which accounts for about 43% of all maxillofacial deformities.<sup>[1]</sup> Facial asymmetry is another common jaw deformity with an incidence ranging from 8.7% to 23.3%.<sup>[2]</sup> Combined orthognathic surgeries have been often performed for these jaw deformities. Sagittal split ramus osteotomy (SSRO) is a common surgery for mandibular treatment; however, there has been a concern about its effect on temporomandibular joint (TMJ).<sup>[3–5]</sup> Le Fort I osteotomy is a treatment method for maxillary deformities,<sup>[6,7]</sup> which was first described by Obwegeser in 1969.<sup>[8]</sup> The method has been popular owing to esthetic considerations<sup>[9]</sup>; however, it can cause some issues, such as relapse, fracture, poor stability, and cranial nerve injuries.<sup>[6,10–12]</sup>

Le Fort I osteotomy, particularly its postoperative stability,<sup>[6,13–16]</sup> has always been a topic of intense discussion. Most researchers pay more attention to the impact of surgical processes on patients, such as fixation location of the inner steel plate and other materials.<sup>[7,17–21]</sup> However, the impacts of surgery on patients' TMJ are not thoroughly investigated. The TMJ, which is one of the important load-bearing organs and the only bilateral linkage joints of the human body,<sup>[22]</sup> needs our attention during

orthognathic surgery. Together, both TMJs control chewing, swallowing, speech, and other functions. Therefore, it is necessary to better understand the impacts of osteotomies on TMJs.

Previous studies have well revealed the influence of SSRO on TMJ stress distributions.<sup>[3–5]</sup> Many scholars also conducted biomechanical studies on Le Fort I.<sup>[7,17,20,21]</sup> 4-plate fixation has been proven to be better than 2-plate fixation in alleviating stresses in the mandible after treatment of Le Fort I.<sup>[7,20,21]</sup> However, studies that investigate the impact of surgery on TMJ are lacking. Previous studies did not clearly explain the influence of Le Fort I on the biomechanics of TMJs. It is known that unilateral molar clenching (UMC) is a negative habit that can easily cause malocclusion and occlusal disorder.<sup>[23]</sup> The effects of surgery on patients stress distributions during UMC were unclear. Therefore, the aim of the study was to evaluate the changes in stress distributions in TMJs during UMC after orthognathic surgery on patients with jaw deformity.

## 2. Materials and methods

### 2.1. Data source and acquisition

Nine patients with jaw deformity (five males and four females,  $22.0 \pm 6.0$  years old, 4 of them had mandibular prognathism and 5 had facial asymmetry) were selected as the preoperative group. The inclusion criteria for patients in our study were:

1. exceeding 18 years old;
2. without prior TMJ procedures;
3. diagnoses of mandibular prognathism with their upper dentitions covered by lower ones or facial asymmetry with their deviations from the facial midline were greater than 3 mm;
4. combined treatment of SSRO and Le Fort I osteotomy.

Among them, 4 patients with mandibular prognathism were all Angle Class III malocclusion. And 3 of 5 patients with facial asymmetry were also Angle Class III malocclusion, and the remaining 2 were Angle Class I malocclusion. After all the patients underwent Le Fort I and SSRO, they were further classified as the postoperative group. Only one postoperative patient, with preoperative Angle Class III malocclusion, was Angle Class I malocclusion, and the rest of patients were normal occlusion. Another nine asymptomatic subjects (5 males and 4 females,  $26.1 \pm 5.6$  years old) were recruited as the control group. And the inclusion criteria for asymptomatic subjects were:

1. no jaw deformities;
2. no TMD symptoms and degenerative joint disease;
3. without prior TMJ procedures;
4. healthy physical condition and normal occlusion.

This study was approved by the Affiliated Hospital of Stomatology of Chongqing Medical University Institutional Review Board. All the patients were followed up for more than 6 months after surgery and signed informed consent agreements.

The clinical cases showed three patients with facial asymmetry of preoperative TMD symptoms in the left TMJ. One had TMJ clicking and incongruous bilateral joint movement, and one had TMJ clicking and incomplete closure of mouth, but neither of them had postoperative TMD symptoms. Another one with TMJ clicking still had postoperative TMD symptoms. The other 6 patients had no TMD symptoms before and after surgery.

Complete head views of all the patients, including the asymptomatic subjects, were scanned using a cone-beam computed tomography (CBCT) machine (KaVo 3D exam, Germany) before and after surgeries. All the images were taken in accordance with the standardized patient orientation and exposure parameters (120 kVp, 3–8 mA, 20 second) and each CBCT scan consisted of 290 to 340 images with a section thickness of 0.4 mm. Finally, all the CBCT data were saved in Digital Imaging and Communications in Medicine (DICOM) format.

### 2.2. 3D modelling and materials

The DICOM data were imported into Mimics 15.0 (Materialize, Leuven, Belgium). The maxilla and mandible were separated according to different thresholds. Then, the 3D solid models were generated by surface triangulation technique (Fig. 1). Based on previous related studies and on the concepts of anatomy,<sup>[4,24,25]</sup> articular discs were established between the condyles and articular fossae according to the geometry and anatomical position of the discs (Fig. 1).

As the TMJ was the focus, 10-node modified quadratic tetrahedron elements (C3D10M) were used in the TMJ regions and the remaining regions were meshed by 4-node linear tetrahedral elements (C3D4).<sup>[26]</sup> Using Eq. 1,<sup>[27–32]</sup> which relates the material properties of bone tissue and grey value, the elastic modulus (Eq. 2) was calculated to simulate the heterogeneity.

$$\text{Density} = -13.41017 \times Gv, \quad (1)$$

$$E = -388.8 + 5925 \times \text{Densit}. \quad (2)$$

Where Gv is the grey value, E is the Young's modulus, and all parameters were in SI units.

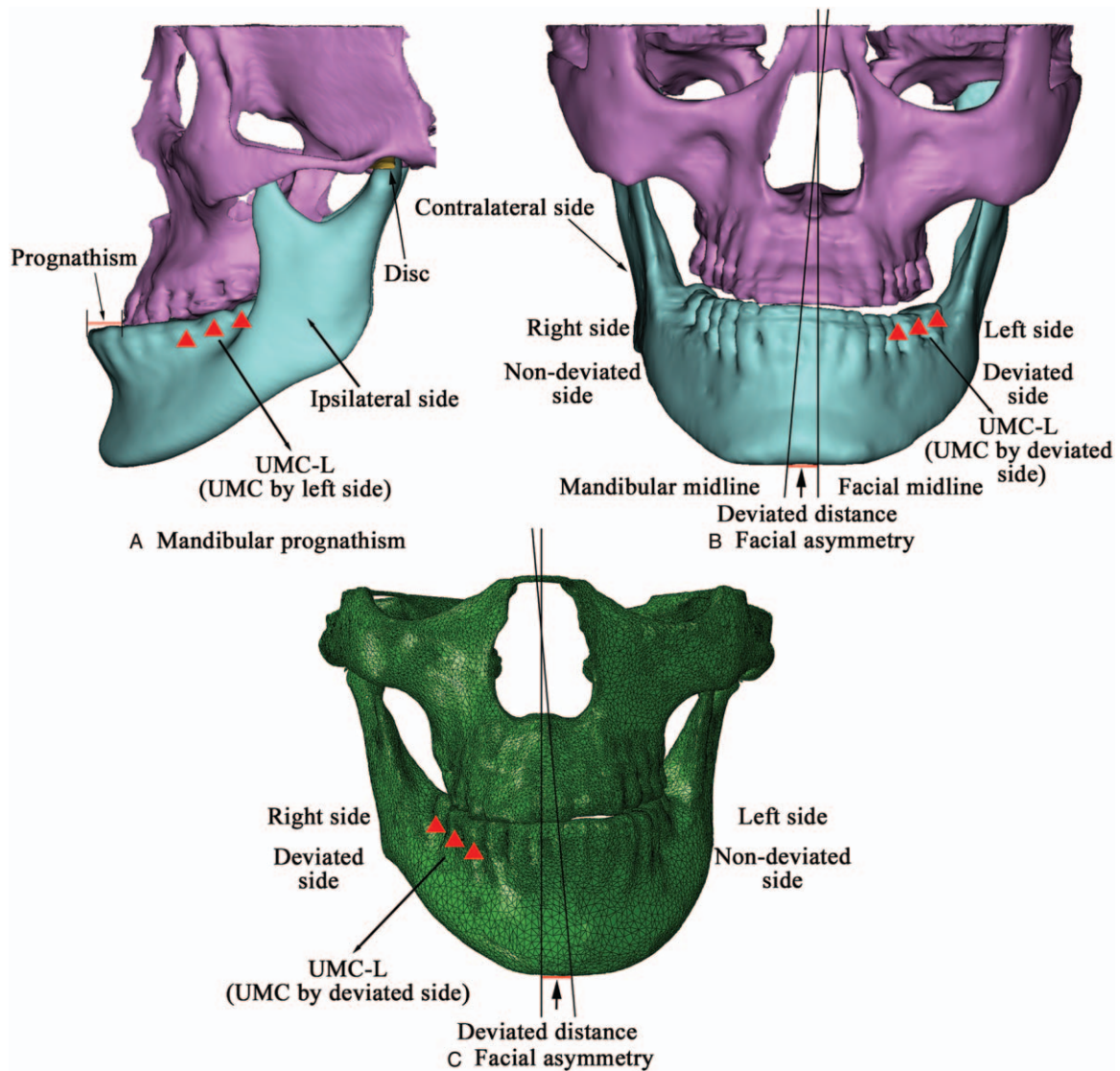
The Poisson's ratio of maxilla, mandible, and teeth was set to 0.3 based on previous related studies<sup>[33–36]</sup> while the articular disc was set to 0.4. After assigning the material properties, the model was imported to ABAQUS 6.13 (Dassault SIMULIA, RI) to generate a three-dimensional finite element model.

### 2.3. Contact, boundary conditions, and loading

Based on related finite element studies,<sup>[35,36]</sup> contact was used to simulate the interaction between articular disc-condyle, disc-fossa, and upper and lower dentition. Further, the normal contact attribute was set as hard contact and the friction coefficient of the tangential contact attribute was set as 0.001.<sup>[4,5]</sup>

Owing to the symmetry of the maxillofacial structure of the asymptomatic subjects, the stress distributions on both sides of TMJ during right side UMC were similar to those during left side UMC. Thus, a random side was selected for the analysis of the control group.

Five patients with facial asymmetry were surveyed, 3 of them had mandibular deviations to the right side and 2 had mandibular deviations to the left side.<sup>[5]</sup> The results from patients with mandibular prognathism under left side UMC were combined with those from patients with facial asymmetry under deviated side UMC. The combined group was denoted as UMC-L. Similarly, the results from right side UMC were combined with those from non-deviated side UMC, and the combined group was denoted as UMC-R.



**Figure 1.** Left view of a patient with prognathism and front view of 2 patients with mandibular deviation to the right and left. The red triangles indicated the corresponding UMC of the patients in the UMC-L group, which is UMC by left side in the patients with prognathism and by deviated side in the patients with facial asymmetry.

Furthermore, a full constraint of 6 degrees of freedom (DOF) was set on the top surface of maxilla. Based on previous studies,<sup>[4]</sup> 14 muscle forces in 7 groups were chosen.

#### 2.4. Data analysis

The stress parameters for each group of the TMJs were analyzed to explore the biomechanical effects on them. Data were statistically analyzed using SPSS 20.0 (SPSS Inc, Chicago, IL). In addition, the following comparisons were performed on the:

1. ipsilateral and contralateral sides of the control and the pre- and postoperative groups by paired-samples *t* test, and the Wilcoxon signed rank test for the groups without the normal distribution;
2. ipsilateral sides of the UMC-R in the control group and the UMC-L in the pre- and postoperative groups by independent-samples *t* test, and use the Mann-Whitney *U* test for the groups without the normal distribution;
3. contralateral sides of the UMC-R in the control group and the UMC-L in the pre- and postoperative groups by independent-samples *t* test and Mann-Whitney *U* test;
4. ipsilateral sides of the UMC-R in the control and pre- and postoperative groups by independent-samples *t* test and Mann-Whitney *U* test;
5. contralateral sides of the UMC-R in the control and pre- and postoperative groups by independent-samples *t* test and Mann-Whitney *U* test.

The difference was considered statistically significant if  $P < .05$ .

### 3. Results

The stresses on the left and right TMJs in the asymptomatic subjects were statistical different ( $P < .05$ ), while the principal stresses on the contralateral side were greater than those on the ipsilateral side (Table 1). Results from the patients showed

**Table 1**  
**Comparisons of the peak stresses on the preoperative and postoperative patients with jaw deformity and on the asymptomatic subjects at both ipsilateral and contralateral sides under unilateral molar clenching (MPa).**

	Control group	Preoperative UMC-L	Preoperative UMC-R	Postoperative UMC-L	Postoperative UMC-R
Contact stresses					
Disc					
Contralateral side	0.36	4.82 <sup>†</sup>	4.87 <sup>†</sup>	1.26 <sup>†</sup>	1.54
Ipsilateral side	1.35	4.13 <sup>†</sup>	6.28	2.01	2.53
P value	.028 <sup>*</sup>	.859	.612	.091	.264
Condyle					
Contralateral side	0.49	3.77 <sup>†</sup>	5.08 <sup>†</sup>	1.12	2.05
Ipsilateral side	1.10	3.50	6.21 <sup>†</sup>	1.70	3.65
P value	.025 <sup>*</sup>	.214	.423	.018 <sup>*</sup>	.200
Fossa					
Contralateral side	0.29	3.49 <sup>†</sup>	2.46 <sup>†</sup>	0.64	1.12
Ipsilateral side	0.77	2.86	3.61 <sup>†</sup>	0.82	1.82
P value	.012 <sup>*</sup>	.580	.333	.220	.103
Maximum principal stresses					
Disc					
Contralateral side	2.17	6.69	4.85 <sup>†</sup>	1.60	2.17
Ipsilateral side	1.15	3.82 <sup>†</sup>	5.95	1.99	1.53
P value	.005 <sup>*</sup>	.594	.594	.576	.340
Condyle					
Contralateral side	4.76	5.74	5.23	3.73	3.98
Ipsilateral side	2.55	5.83 <sup>†</sup>	5.56	1.82	2.52
P value	.000 <sup>*</sup>	.441	.594	.033 <sup>*</sup>	.006 <sup>*</sup>
Fossa					
Contralateral side	1.77	3.88	3.13	2.11	2.59
Ipsilateral side	1.03	3.78	3.26	3.07	1.43
P value	.015 <sup>*</sup>	.948	.914	.767	.201
Minimum principal stresses					
Disc					
Contralateral side	-2.79	-8.92	-6.56 <sup>†</sup>	-2.25	-2.41
Ipsilateral side	-1.25	-6.63 <sup>†</sup>	-7.82	-2.03	-1.71
P value	.008 <sup>†</sup>	.638	.859	.746	.260
Condyle					
Contralateral side	-5.64	-7.65	-7.61 <sup>†</sup>	-4.81	-6.32
Ipsilateral side	-3.72	-9.53 <sup>†</sup>	-8.97	-2.91	-4.39
P value	.003 <sup>*</sup>	.453	.482	.000 <sup>*</sup>	.000 <sup>*</sup>
Fossa					
Contralateral side	-2.25	-5.17	-3.96	-2.36	-4.75
Ipsilateral side	-0.99	-5.15 <sup>†</sup>	-4.87 <sup>†</sup>	-4.13	-1.70
P value	.008 <sup>*</sup>	.989	.444	.441	.210

\* Comparison between ipsilateral and contralateral sides of control, preoperative, and postoperative groups ( $P < .05$ ).

† Comparison between control group and preoperative or postoperative groups ( $P < .05$ ).

UMC-L = unilateral molar clenching by left, UMC-R = unilateral molar clenching by right.

differences only in the postoperative group, i.e., UMC-L on contact stress and UMCs on principal stresses of condyle.

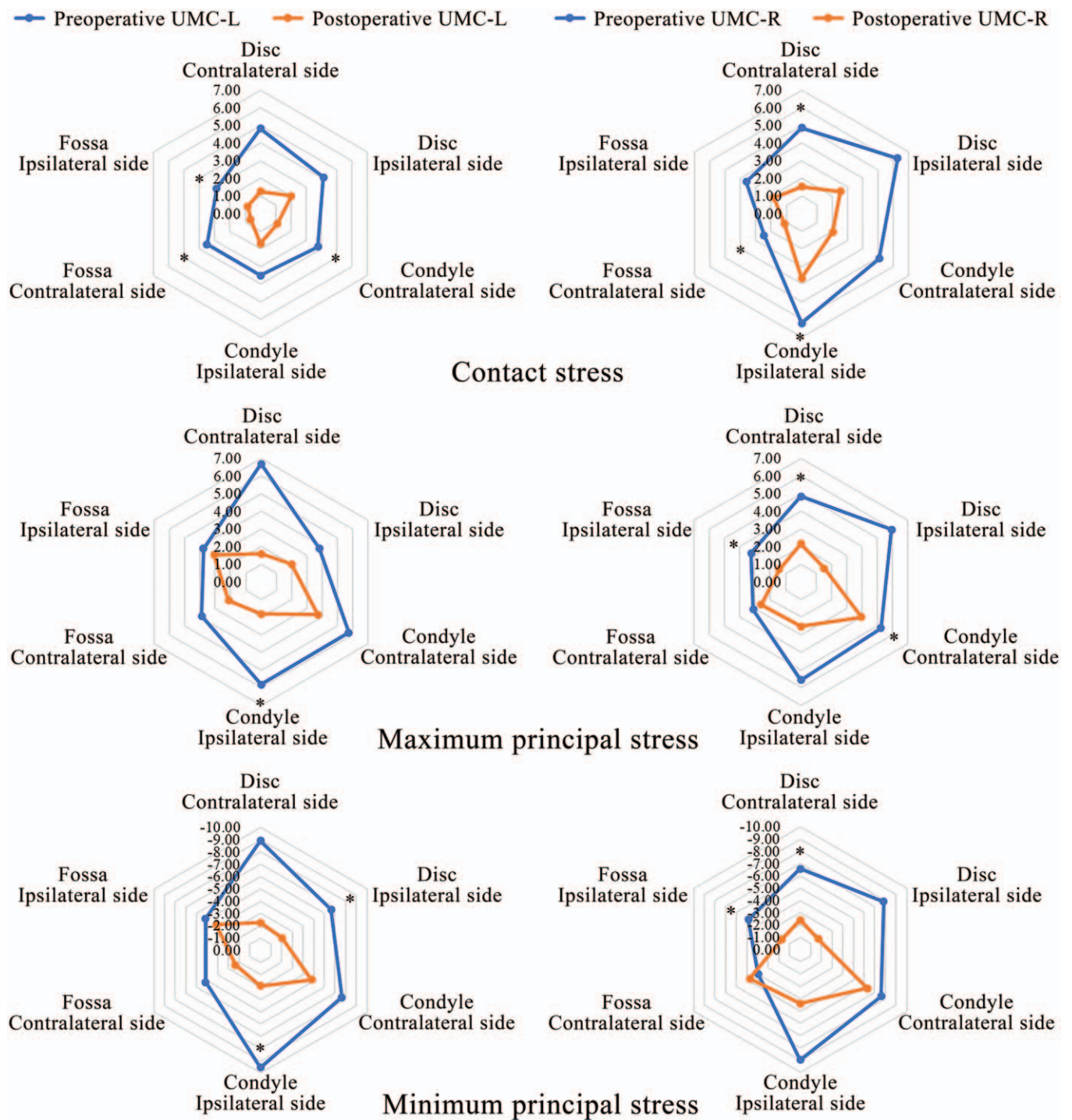
Under the UMC-L condition, the stresses on the TMJs in the postoperative group were lower than those in the preoperative group. The parameters of the TMJs were not significantly different for the control group, except for the contact stresses on the contralateral side of the disc. In addition, only the minimum principal stresses on the contralateral side of the articular fossa did not reduce under the UMC-R, and there was no significant difference between the stresses of TMJs and the control group. Furthermore, the stresses on the ipsilateral and contralateral sides of the TMJs of the preoperative group were greater than those on the corresponding sides of the TMJs of the control group under the UMC condition (Fig. 2).

Figure 3 shows the distributions of contact stress at four different conditions on asymptomatic individuals and patients (only three patients as examples). The stresses on patients with

facial asymmetry were greater than on those with UMC-R mandibular prognathism. The stresses on patients with TMD were also greater than those on the Control group and on those without TMD. Moreover, the patients with TMD manifested higher stress level than individuals without TMD after the surgeries.

#### 4. Discussion

In this study, 9 patients with jaw deformity were treated with Le Fort I and SSRO. Stresses on TMJs under UMC were simulated based on CBCT image modelling. Then, the results were compared with those from the control group in order to explore their influence on the stress distribution on the TMJs of the patients with jaw deformity. The mandible, maxilla, and disc were considered as homogeneous materials in previous studies.<sup>[34,37]</sup> In this study, Eqs. 1 and 2 given earlier were used to



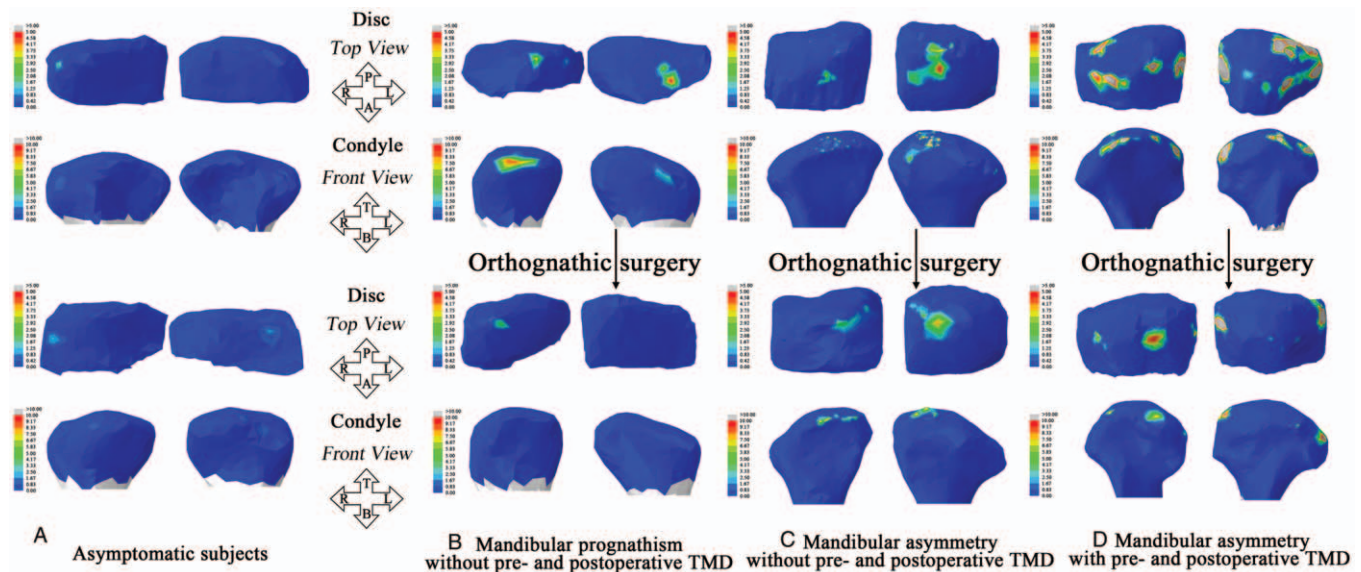
**Figure 2.** Comparisons of the peak stresses on the preoperative and postoperative patients with jaw deformity under unilateral molar clenching (MPa). \*Comparison between preoperative group and postoperative group ( $P < .05$ ).

calculate the model's Youngs modulus for the simulation of heterogeneity.

#### 4.1. Finite element verification

This study provided a reasonable simulation of the interaction between the articular disc and fossa and between the disc and condyle. In a previous research, the validity of the method was

verified through five 3D printing model experiments.<sup>[38]</sup> Five loadings of 100, 150, 200, 250, and 300 N were applied to the 3D printing models to simulate the central occlusion experiment. The finite element and the 3D printed experimental models shared the same geometry, material properties, loads, and boundary conditions. The maximum differences between the measured strain (from the 3D printed models) and predicted strain (from the finite element models) were less than 5%. Hence, it was



**Figure 3.** Contact stress distributions on TMJ for (a) 2 healthy asymptomatic individuals under the UMC-R, (b) a mandibular prognathism patient without pre- and postoperative TMD under the UMC-R, (c) a mandibular asymmetry patient without pre- and postoperative TMD under the UMC-R, (d) a mandibular asymmetry patient with pre- and postoperative TMD under the UMC-R. A = anterior, B = bottom, L = left, P = posterior, R = right, T = top.

reasonable to consider the interactions between articular discs and fossae and between discs and condyles as frictional contacts in this study.

#### 4.2. Stress distribution of the TMJs between the ipsilateral and contralateral sides

The principal stresses on the contralateral TMJs of the control group were significantly greater than those on the ipsilateral side. On the contrary, the principal stresses of the contralateral TMJs of the UMC-R preoperative patients were lower than those of the ipsilateral side (Table 1). The increased stresses of the ipsilateral side may be related to facial asymmetry.<sup>[38]</sup> It has been explained that UMC-R was not conducive to deformed patients. The stresses on the ipsilateral side were lower under the UMC, but the deformity increased the loads on the ipsilateral side. Furthermore, the contact stresses on the contralateral TMJs of the UMC-L preoperative patients were greater than those on the ipsilateral side, contrary to what was observed from the asymptomatic subjects. A related study<sup>[5]</sup> showed that the load on the contralateral side was greater than the ipsilateral side during UMC, consistent with the principal stress distributions. As the contact stress described the mutual squeezing of 2 objects in contact, the forces on the ipsilateral side was greater. The abnormal distributions were also considered to be associated with the facial asymmetry. The stress distributions on both TMJs of the postoperative patients were consistent with those of the asymptomatic subjects. From the follow up with the patients, no bilateral discomfort or limited opening were found after the surgeries. Le Fort I and SSRO could alleviate jaw deformity and abnormal stress distributions between the ipsilateral and contralateral sides of TMJ.

#### 4.3. Effects of orthognathic surgery on stress distributions of TMJs

Previous studies<sup>[3,4,38]</sup> had suggested that morphological changes in TMJ with jaw deformities were the reason for abnormal stress

distributions. The contact stresses on both TMJs of the UMC preoperative patients were greater than those of the asymptomatic subjects (Fig. 2). After surgery, the average contact stresses on TMJ were decreased to normal levels (Fig. 2). The reduction of the postoperative contact stress to normal levels would be beneficial in relieving joint pain and other symptoms caused by the increased contact stress from jaw deformity. The contact stresses on the condyle and fossa were significantly lower in the UMC-L group than those in the preoperative patients. Contact stresses on the disc were also reduced. However, only the contact stresses on the contralateral fossa of the UMC-L group were statistically different from those of the control group. At the same time, the left side was also the deviated side, so it was clear that the effect of Le Fort I and SSRO on patients with facial asymmetry was inconspicuous. Clinically, there was still one case with TMD after surgery.

The maximum and minimum principal stresses indirectly reflected the tensile and compressive properties. The maximum principal stresses on both sides of the TMJs of the UMC preoperative patients were greater than those of the asymptomatic subjects. (Fig. 2). Moreover, the maximum principal stress of the postoperative group was not significantly different from that of the control group. The results show that surgeries could alleviate the tension characteristics of the TMJs of patients with jaw deformity. The peak value of the maximum principal stresses of the UMC-L patients occurred in the disc of the contralateral side, which was about 3.06 times of that of the Control group (Fig. 2). The disc of the patients with jaw deformity bear high tension and this stress could lead to disc thinning or perforation.<sup>[4]</sup> The stresses on the condyle and fossa were correspondingly increased as well. In addition, the tensile stresses on the TMJs of the postoperative patients tended to be normal; hence, postoperative complications were avoided. Finite element analysis was performed to determine whether there were abnormal stress distributions before and after surgery.

The minimum principal stresses on the TMJs of the postoperative patients were lower than those in the UMC-L preoperative patients but the minimum principal stresses on the fossa at the contralateral side of the UMC-R postoperative patients did not decrease (Fig. 2). Furthermore, there was no significant difference between the postoperative and the control groups. It could be seen that although surgeries could improve the compression characteristics of the patients' TMJs, the effects on the fossa of the UMC patients were limited. At the same time, after surgery, the minimum principal stresses on the disc at the contralateral side were decreased by at least 55%, while the stress on the condyle was decreased by 37% (Fig. 2). Arnett et al showed that the increase of condylar compression was the key factor leading to condylar resorption and mandibular recurrence.<sup>[39]</sup> Therefore, the recurrence after surgery might be related to the weak improvement on the condylar stresses.

#### 4.4. Different deformities and TMD

The contact stress described the characteristics of extrusion, where high friction could wear the TMJ. Before surgery, the contact stresses on the TMJs of the patients with prognathism were greater than those of the asymptomatic subjects, but less than those of the patients with facial asymmetry (Fig. 3). Thus, patients with facial asymmetry are more prone to wear due to greater load. The three patients with TMD were found with facial asymmetry. Furthermore, previous studies have shown that TMD was prone to occur in patients with facial asymmetry, especially on the deviated side.<sup>[23]</sup> Hence, patients with facial asymmetry are more likely to induce TMD that are related to abnormal stresses of the TMJ. The TMJ of the patients with TMD showed symmetrical stresses under asymmetric load and the stresses on both sides were greater compared with those on the subjects without TMD. It indicated that TMD could cause not only high stresses on the affected side of the patients with facial asymmetry but also on the contralateral side.

After surgery, the abnormal stresses on patients with jaw deformity were distinctly improved, whereas for patients with TMD, stresses still remained in the affected side (Fig. 3). The clinical manifestations from the patients with TMD were still on the left side after surgery. Therefore, orthognathic surgery could help correct the stress distributions in patients with jaw deformity, but it could not improve the conditions of patients with TMD.

A major limitation of the study is that the sample size of each group is relatively low, mainly because this is a preliminary study on the effect of the orthognathic surgery combined treatment on the patients with different jaw deformities. Of course, we still need to increase the sample size to further verify the results and conclusions. Additionally, individual muscle forces cannot be detected due to the ethical consideration. Future detection of individual muscles could help improve the research.

## 5. Conclusion

Jaw deformities would cause significantly greater stresses in the TMJ of the patients, especially those accompanied by TMD. Le Fort I and SSRO could improve abnormal stress distributions on the TMJs of patients with jaw deformities, close to asymptomatic subjects. However, the improvement on TMD was not obvious. It was recommended to focus more on the stress distributions on the TMJ during surgical treatment.

Table. Subjects' detailed data (Mpa), <http://links.lww.com/MD/F620>.

## Acknowledgments

Thanks to Jinlin Song and Leilei Zheng of the Affiliated Hospital of Stomatology of Chongqing Medical University for their assistance in this study.

## Author contributions

**Conceptualization:** Zhan Liu.

**Data curation:** Haidong Teng, Jingheng Shu, Quanyi Wang, Bingmei Shao, Zhan Liu.

**Formal analysis:** Haidong Teng, Jingheng Shu, Quanyi Wang, Bingmei Shao, Zhan Liu.

**Funding acquisition:** Zhan Liu.

**Investigation:** Zhan Liu.

**Methodology:** Haidong Teng, Tinghui Zheng.

**Software:** Haidong Teng, Jingheng Shu, Bingmei Shao.

**Writing – original draft:** Haidong Teng.

**Writing – review & editing:** Jingheng Shu, Zhan Liu.

## References

- [1] Tsang WM, Cheung LK, Samman N. Cephalometric characteristics of anterior open bite in a southern Chinese population. *Am J Orthod Dentofacial Orthop* 1998;113:165–72.
- [2] Bergersen EO. Enlargement and distortion in cephalometric radiography - compensation tables for linear measurements. *Angle Orthodontist* 1980;50:230–44.
- [3] Liu Z, Shu J, Zhang Y, et al. The biomechanical effects of sagittal split ramus osteotomy on temporomandibular joint. *Comput Methods Biomech Biomed Engin* 2018;21:617–24.
- [4] Shu JH, Yao J, Zhang YL, et al. The influence of bilateral sagittal split ramus osteotomy on the stress distributions in the temporomandibular joints of the patients with facial asymmetry under symmetric occlusions. *Medicine (Baltimore)* 2018;97:e11204.
- [5] Shu J, Zhang Y, Chong DYR, et al. Effects on loads in temporomandibular joints for patients with mandibular asymmetry before and after orthognathic surgeries under the unilateral molar clenching. *Biomech Model Mechanobiol* 2019;19:533–41.
- [6] Bothur S, Blomqvist JE, Isaksson S. Stability of Le Fort I osteotomy with advancement: a comparison of single maxillary surgery and a two-jaw procedure. *J Oral Maxillofac Surg* 1998;56:1029–33.
- [7] Atac MS, Erkmen E, Yucel E, et al. Comparison of biomechanical behaviour of maxilla following Le Fort I osteotomy with 2- versus 4-plate fixation using 3D-FEA. Part 1: advancement surgery. *Int J Oral Maxillofac Surg* 2008;37:1117–24.
- [8] Obwegese HI. Surgical correction of small or retrodisplaced maxillae - the dish-face deformity. *Plast Reconstr Surg* 1969;43:351–65.
- [9] Proffit WR, Phillips C, Prewitt JW, et al. Stability after surgical-orthodontic correction of skeletal Class III malocclusion. 2. Maxillary advancement. *Int J Adult Orthodon Orthognath Surg* 1991;6:71–80.
- [10] Dowling PA, Espeland L, Sandvik L, et al. LeFort I maxillary advancement: 3-year stability and risk factors for relapse. *Am J Orthod Dentofacial Orthop* 2005;128:560–7.
- [11] Wilson MW, Maheshwari P, Stokes K, et al. Secondary fractures of Le Fort I osteotomy. *Ophthalmic Plast Reconstr Surg* 2000;16:258–70.
- [12] Kim JW, Chin BR, Park HS, et al. Cranial nerve injury after Le Fort I osteotomy. *Int J Oral Maxillofac Surg* 2011;40:327–9.
- [13] Luyk NH, Wardbooth RP. The stability of Le Fort I advancement osteotomies using bone plates without bone-grafts. *J Maxillofac Surg* 1985;13:250–3.
- [14] Yoon HJ, Rebellato J, Keller EE. Stability of the Le Fort I osteotomy with anterior internal fixation alone: a case series. *J Oral Maxillofac Surg* 2005;63:629–34.
- [15] Egbert M, Hepworth B, Myall R, et al. Stability of Le Fort I osteotomy with maxillary advancement - a comparison of combined wire fixation and rigid fixation. *J Oral Maxillofac Surg* 1995;53:243–8.

- [16] Murray RA, Upton LG, Rottman KR. Comparison of the postsurgical stability of the Le Fort I osteotomy using 2-and 4-plate fixation. *J Oral Maxillofac Surg* 2003;61:574–9.
- [17] Huang S-F, Lo L-J, Lin C-L. Factorial analysis of variables influencing mechanical characteristics in Le Fort I osteotomy using FEA and statistics-based taguchi method. *J Med Biological Engin* 2016;36:495–505.
- [18] Hingsammer L, Grillenberger M, Schagerl M, et al. Biomechanical testing of zirconium dioxide osteosynthesis system for Le Fort I advancement osteotomy fixation. *J Mech Behav Biomed Mater* 2018;77:34–9.
- [19] Kilinc Y, Erkmen E, Kurt A. Biomechanical evaluation of different fixation methods for mandibular anterior segmental osteotomy using finite element analysis, part two: superior repositioning surgery with bone allograft. *J Craniofac Surg* 2016;27:36–40.
- [20] Atac MS, Erkmen E, Yucler E, et al. Comparison of biomechanical behaviour of maxilla following Le Fort I osteotomy with 2-versus 4-plate fixation using 3D-FEA Part 2: impaction surgery. *Int J Oral Maxillofac Surg* 2009;38:58–63.
- [21] Erkmen E, Atac MS, Yucler E, et al. Comparison of biomechanical behaviour of maxilla following Le Fort I osteotomy with 2-versus 4-plate fixation using 3D-FEA Part 3: inferior and anterior repositioning surgery. *Int J Oral Maxillofac Surg* 2009;38:173–9.
- [22] Tanaka E, del Pozo R, Sugiyama M, et al. Biomechanical response of retrodiscal tissue in the temporomandibular joint under compression. *J Oral Maxillofac Surg* 2002;60:546–51.
- [23] Manfredini D, Bucci MB, Montagna F, et al. Temporomandibular disorders assessment: medicolegal considerations in the evidence-based era. *J Oral Rehabil* 2011;38:101–19.
- [24] Hansson T, Nordstrom B. Thickness of soft-tissue layers and articular disk in temporomandibular joints with deviations in form. *Acta Odontol Scand* 1977;35:281–8.
- [25] Shu J, Zhang Y, Liu Z. Biomechanical comparison of temporomandibular joints after orthognathic surgery before and after design optimization. *Med Eng Phys* 2019;68:11–6.
- [26] Kopp S, Kuzelka J, Goldmann T, et al. Modeling of load transmission and distribution of deformation energy before and after healing of basal dental implants in the human mandible. *Biomedizinische Technik. Biomed Engin* 2011;56:53–8.
- [27] Carter DR, Hayes WC. Compressive behavior of bone as a 2-phase porous structure. *J Bone Joint Surg -Am Vol* 1977;59:954–62.
- [28] Ciarelli MJ, Goldstein SA, Kuhn JL, et al. Evaluation of orthogonal mechanical-properties and density of human trabecular bone from the major metaphyseal regions with materials testing and computed-tomography. *J Orthop Res* 1991;9:674–82.
- [29] Harp JH, Aronson J, Hollis M. Noninvasive determination of bone stiffness for distraction osteogenesis by quantitative computed-tomography scans. *Clin Orthop Rel Res* 1994;301:42–8.
- [30] Rho JY, Hobatho MC, Ashman RB. Relations of mechanical-properties to density and CT numbers in human bone. *Med Engin Phys* 1995;17:347–55.
- [31] Rho JY, Hobatho MC, Ashman RB. Relations of mechanical properties to density and ct numbers in human bone. *Med Eng Phys* 1995;17:347–55.
- [32] Kopperdahl DL, Morgan EF, Keaveny TM. Quantitative computed tomography estimates of the mechanical properties of human vertebral trabecular bone. *J Orthop Res* 2002;20:801–5.
- [33] Tanne K, Tanaka E, Sakuda M. Stress distribution in the temporomandibular joint produced by orthopedic chincup forces applied in varying directions: a three-dimensional analytic approach with the finite element method. *Am J Orthod Dentofacial Orthop* 1996;110:502–7.
- [34] Liu Z, Qian Y, Zhang Y, et al. Effects of several temporomandibular disorders on the stress distributions of temporomandibular joint: a finite element analysis. *Comput Methods Biomech Biomed Engin* 2016;19:137–43.
- [35] Tanaka E, del Pozo R, Tanaka M, et al. Three-dimensional finite element analysis of human temporomandibular joint with and without disc displacement during jaw opening. *Med Eng Phys* 2004;26:503–11.
- [36] Liu Z, Fan YB, Qian YL. Comparative evaluation on three-dimensional finite element models of the temporomandibular joint. *Clin Biomech* 2008;23:S53–8.
- [37] Qi XD, Ma LM, Zhong SZ. The influence of the closing and opening muscle groups of jaw condyle biomechanics after mandible bilateral sagittal split ramus osteotomy. *J Craniofac Surg* 2012;40:E159–64.
- [38] Zhang YL. The Effect of Bilateral Sagittal Split Ramus Osteotomy on Temporomandibular Joints in Patients with Facial Asymmetry: a Morphologic and Biomechanical Study. [PhD Thesis]. Chengdu: College of Architecture and Environment, Sichuan University; 2017.
- [39] Arnett GW, Gunson MJ. Risk factors in the initiation of condylar resorption. *Semin Orthod* 2013;19:81–8.