

Non artheritic bilateral anterior ischaemic optic neuropathy (NAION) as devastating complication following Total Hip Arthroplasty: a case report

Alfonso Manzotti¹, Alice Schianchi¹, Lucia Pace², Giuliano Salvadori¹, Alessio Biazzo³, Pietro Cerveri⁴

¹Orthopaedic and Trauma Department, ASST Fatebenefratelli Sacco, University Hospital “Luigi Sacco”, Milan, Italy; ²Ophthalmology Department, ASST Fatebenefratelli Sacco, University Hospital “Luigi Sacco”, Milan, Italy; ³Orthopaedic Department, Humanitas Gavazzeni, Bergamo, Italy; ⁴Department of Electronics, Information and Bioengineering, Politecnico di Milano University, Milan, Italy

Summary.*Introduction:* Postoperative vision loss (PVL) is an extremely rare complication following major surgical procedures. Patients with systemic hypertension, diabetes, coronary diseases and smokers are generally predisposed to this complication. More frequently, it is caused by ischemic optic neuropathy (ION), central retinal artery occlusion or retinal vein occlusion. Rare cases of unilateral PVL following total joint arthroplasty surgery have been recently described in literature. *Case report:* This case report describes the first reported bilateral non-arteritic anterior ischemic optic neuropathy (NAION), which occurred 3 days following a total hip arthroplasty with a consequent post-operative hypotension. *Conclusions:* Orthopedic surgeons should be aware that in hip joint replacement procedures, selected patients present an higher risk of ION following intra/postoperative hypotension and prolonged surgical times. (www.actabiomedica.it)

Key words: bilateral visus loss, total hip arthroplasty, case report

Introduction

Postoperative vision loss (PLV) is a severe non-ocular surgical complication resulting in permanent vision loss (1). The occurrence of PVL in general surgery is very rare (0.0008%) with an higher incidence in selected procedures, such as spine surgery (0.2%) or cardiac surgery (0.11%). Only few cases have been reported following elective orthopedic procedures (2). PVL onset varies from the immediate post operative time to 10 days after surgery with an average onset time of 15 hours (0-168 hours). The most frequent causes of PVL are ischemic optic neuropathy (ION), central retinal artery occlusion (CRAO) and retinal vein occlusion (RVO) (3-5). Newman et al. identified several risk factors for bilateral sudden visual loss fol-

lowing non-ocular surgeries including diabetes mellitus, systemic hypertension, perioperative hypotension, acute anemia due to excessive blood loss, excessive liquid replacement, vasoconstrictive agents, and supine position during surgery (6).

Likewise nowadays, in accordance with the cost-saving procedures advocated by many health organization, several authors have debated the potential advantages of deliberate hypotension during anesthesia for selected surgical procedures to reduced intraoperative blood loss and facilitates an earlier uncomplicated patient discharge (7, 8) despite more frequently surgeons have to face older patients often affected by significant comorbidity (9).

In the literature, we could find very few reports dealing with unilateral PLV following hip surgery (10-

13). To our knowledge, there is just one case of a bilateral PLV managed in an Ophthalmologic center and published in a non-orthopedic journal without either mention about orthopedic management or final visual loss prognosis (14).

Our case report aims to document the clinical history of a patient, who suffered a permanent bilateral visual loss because of a non-arteritic anterior ischemic optic neuropathy (NAION) three days later after a total hip joint arthroplasty.

Case report

A 63 years old man, with BMI of 38, a history of unstable diabetes mellitus, high blood pressure, dyslipidaemia and hyperuricaemia was referred to our department to receive an uncemented total hip arthroplasty due to an unilateral severe coxarthrosis (grade IV according Kellgren-Lawrence system) (15) (Fig. 1).

Seven months before surgery, an ophthalmologic examination showed a corrected visual acuity (BCVA) of 20/20, normal intraocular pressure with no signs of diabetic retinopathy at fundus inspection. Preoperative haemoglobin (HGB) value was 16.7 g/dL and haematocrit (HCT) was 49.2%.

The patient underwent to a spinal block (ropivocaine HCL+ sufentanil) supplemented by a mild sedation (midazolam) to receive a total hip arthroplasty on a supine decubitus using a direct lateral approach. Antibiotic prophylaxis (cefazolin) was given 30 minutes

before skin incision according to the departmental protocol. The surgery was complicated by an intraoperative femoral stem exchange to an higher off-set design because of an intraoperative joint instability ending in total surgical time of 170 minutes. Intraoperatively a mild hypotension was strictly controlled with intravenous fluids (4000 ml) and at the end of surgery, the patient was in good condition with a good pain control and a blood pressure of 100/60 mmHg. During the first night, the patient suffered of an episode of hypotension (70/40 mmHg) associated to diaphoresis, both corrected using crystalloids infusion (3000 ml) and the following morning the blood pressure was 90/70 mmHg with a value of 11.2 of HGB. During the first 2 days after surgery, he had an average blood pressure, HGB and HCT of 100/70 mmHg, 10,1 g/dL and 30.2, respectively. The drain was removed 48 hours after the operation and the patient gradually started the physiotherapy program. Three days after surgery, he complained a sudden bilateral visual worsening with a BCVA of 1/40 in the right eye and of 1/20 in the left eye. Blood pressure, HGB and HCT values were 105/75 mmHg, 9.5 g/dL and 26.2% respectively. He was unsuccessfully investigated with a CT of the brain and an echo US-Doppler of the supra-aortic vessels. The fundusoscopic exam showed an oedematous optic nerve with a peripapillary haemorrhage in the right eye and a pale optic disc in the left eye. The patient underwent to both a Optical Coherence Tomography (OCT) and fluoroscopy with evidence of bilateral papilledema, peripheral hypoperfusion, and posterior pole leakage (Fig. 2). OCT showed diffuse thinning of the Retinal Nerve Fiber Layers (RNFL) and a diag-

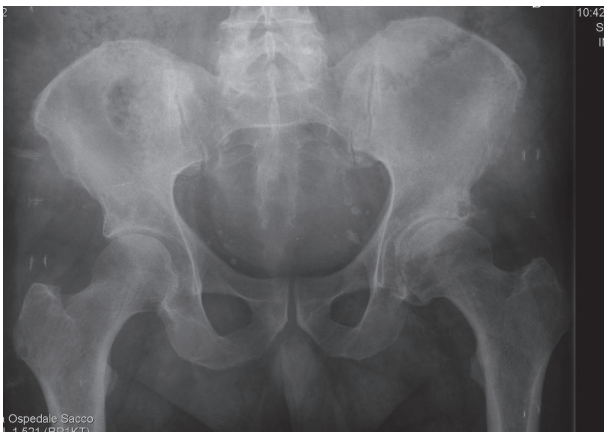


Figure 1. Preop and at 1 year follow-up AP images of the hip

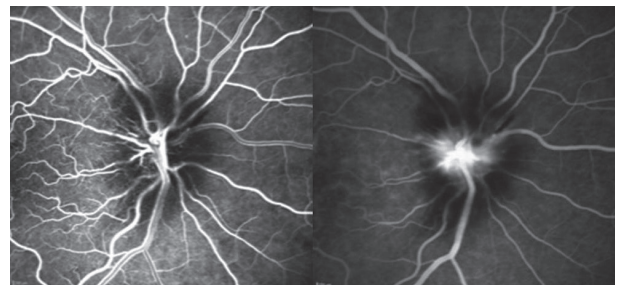


Figure 2. Fluorescein angiography with both early and late phases showing an oedematous optic nerve head with leakage in the late phases

nosis of a feasible bilateral NAION was consequently formulated. According to the international guidelines, the acute ophthalmological treatment was based on high dose of corticosteroid (60 mg/dl/day) for the first 5 days with a maintenance dose (20 mg/dl/day) for further 30 days (3). Intraocular hypotonic eye drops were administrated to modulate the 18 mmHg Intraocular Pressure (IOP).

Moved to hospital's rehabilitation department, he was discharged after 45 days and he was able to walk with a full weight-bearing using two crutches but without any sign of improvement in visual loss. The patient was checked every 2 months and at 1-year follow-up he was able to walk independently with pain-free and almost complete recovery of the hip ROM. Because of a pale papilla, the situation is now stable without any improvement regarding the bilateral visual loss.

Conclusions

In Orthopaedic surgery there are extremely rare reports of sudden perioperative vision mainly occurring few hours after surgery and mostly caused by ischemic optic neuropathy (ION) (1-4)

Patients with systemic hypertension, diabetes, coronary diseases and smokers have a higher risk of postoperative ION (2, 5). Cho et al. advised the orthopedic community about ION risk after uncomplicated hip surgery in elderly patients following femoral neck fracture surgery (12). Buono et al. reported a very poor visual prognosis in ION following non-ocular surgery, recommending a mandatory prevention (4).

In a literature review published in 2011, Kaeser et al. reported 4 unilateral visual loss cases following hip arthroplasty, although none of them caused by a non-arthritic anterior ischemic optic neuropathy (NAION) (10). Only in 2014, Yazgan et al. described a simultaneous bilateral NAION following unilateral hip arthroplasty (14). In this case the patient was referred to an ophthalmic centre with no precise data regarding intra and perioperative pressure management (13). Furthermore, at the time of the ophthalmic examination, many hours after the surgery, the patient was still anaemic (HBG:7.8 g/dl) making the blood loss and hypotension management questionable. Like-

wise visual and orthopaedic prognosis were not mentioned because patient gave up any further follow-up control (14).

Our case is the first simultaneous bilateral NAION following hip arthroplasty submitted to a scientific journal with a complete 1-year follow-up. The patient referred the visual loss onset after 3 days post-operatively despite we constantly monitored blood pressure and blood values to restore any hypotension. We observed that even a temporary mild hypotension could cause an ION occurrence even in relatively young age but complicated by some risk factors (type 2 diabetes mellitus, systemic hypertension). Furthermore we should have consider a prolonged surgical time with a consequent increased blood loss as a contributor to the first post-operative night hypotension. In literature several authors encourage a controlled hypotension in joint arthroplasty surgery remarking the potential advantages for both surgeons and patients in terms of blood loss, easier surgeries and faster discharge in accordance of a new "fast track" patient management policy even in bilateral implants(7, 8). Nevertheless nowadays surgeons have to face more often demanding surgeries either in older pluri-pathological patients or in complicated multiple hip revision procedures all requiring an accurate intra/preoperative blood and pressure management without considering any priority to an earlier discharge (9).

The aim of this case report is to advise both surgeons and anesthesiologists that ION can occur in hip replacement procedures with prolonged surgical times in selected patients suffering intra/perioperative hypotension. Patients affected by diabetes, hypertension, coronary diseases and smokers should be considered as high risk patients requiring both intra/post-operative pressure and blood loss accurate management even considering longer hospital staying.

Conflict of interest: None to declare

References

1. Lee LA, Roth S, Posner KL, Cheney FW, Caplan RA, Newman NJ, et al. The American Society of Anesthesiologists Postoperative Visual Loss Registry: analysis of 93 spine surgery cases with postoperative visual loss. *Anesthesiology* 2006; 105(4): 652-9; quiz 867-8.

2. Warner ME, Warner MA, Garrity JA, MacKenzie RA, Warner DO. The frequency of perioperative vision loss. *Anesth Analg* 2001; 93(6): 1417-21, table of contents.
3. Hayreh SS, Zimmerman MB. Non-arteritic anterior ischemic optic neuropathy: role of systemic corticosteroid therapy. *Graefes Arch Clin Exp Ophthalmol* 2008; 246(7): 1029-46.
4. Buono LM, Foroozan R. Perioperative posterior ischemic optic neuropathy: review of the literature. *Surv Ophthalmol* 2005; 50(1): 15-26.
5. Postoperative Visual Loss Study Group. Risk factors associated with ischemic optic neuropathy after spinal fusion surgery. *Anesthesiology* 2012; 116(1): 15-24.
6. Newman NJ. Perioperative Visual Loss After Nonocular Surgeries. *Am J Ophthalmol* 2008; 145(4): 604-10.
7. Lin S, McKenna SJ, Yao C-F, Chen Y-R, Chen C. Effects of Hypotensive Anesthesia on Reducing Intraoperative Blood Loss, Duration of Operation, and Quality of Surgical Field During Orthognathic Surgery: A Systematic Review and Meta-Analysis of Randomized Controlled Trials. *J Oral Maxillofac Surg* 2017; 75(1): 73-86.
8. Onodera H, Maetani S, Aung T, Kan S, Sakamoto T, Shiragami G, et al. Clinical application of a blood pressure autoregulation system during hypotensive anesthesia. *World J Surg* 1999; 23(12): 1258-63.
9. Cherian JJ, Banerjee S, Kapadia BH, Sodhi GS, Issa K, Harwin SF, et al. Nonsurgical intra-operative blood management strategies for total hip arthroplasty. *Surg Technol Int* 2014; 24: 326-32.
10. Kaeser P-F, Borruat F-X. Visual loss after orthopedic procedures. *J Arthroplasty* 2011; 26(2): 338.e17-19.
11. McGuire C, Murphy C, O'Malley N, Reidy D. Monocular blindness following elective hip arthroplasty. *Acta Orthop Belg* 2009; 75(6): 851-4.
12. Cho H-M, Park M-S, Kim K-B, Cho N-C. Ischemic optic neuropathy after hemiarthroplasty for femoral neck fracture. *J Arthroplasty* 2009; 24(8): 1292.e11-14.
13. Janarek G, Colechá JR. Visual loss after hip and shoulder arthroplasty, two case reports. *Rev Esp Anesthesiol Reanim* 2015; 62(5): 285-8.
14. Yazgan S, Ayar O, Akdemir MO, Uğurbas SH. Simultaneous Bilateral Non-Arteritic Anterior Ischaemic Optic Neuropathy and Unilateral Central Retinal Artery Occlusion after Hip Prosthesis Surgery. *Neuroophthalmology* 2014; 38(5): 257-9.
15. Kellgren JH, Lawrence JS. Radiological assessment of osteo-arthrosis. *Ann Rheum Dis* 1957; 16(4): 494-502.

Received: 23 September 2018

Accepted: 13 February 2019

Correspondence:

Alessio Biazzo

Orthopaedic Department, Humanitas Gavazzeni

Via M Gavazzeni 21 - Bergamo, Italy

E-mail: ale.biazzo@yahoo.it