

Hydropneumothorax and Pulmonary Embolism in a Patient With Shortness of Breath

Obinna Enemoh¹, Obichukwu Iwunna²

Review began 08/08/2022

Review ended 08/13/2022

Published 08/14/2022

© Copyright 2022

Enemoh et al. This is an open access article distributed under the terms of the Creative Commons Attribution License CC-BY 4.0., which permits unrestricted use, distribution, and reproduction in any medium, provided the original author and source are credited.

1. Emergency Medicine, Epsom and St Helier University Hospitals NHS Trust, Surrey, GBR 2. Emergency Medicine, Mid Cheshire Hospitals NHS Foundation Trust, Crewe, GBR

Corresponding author: Obinna Enemoh, sniftex43@yahoo.com

Abstract

This is a case of hydropneumothorax in an elderly man presenting to the emergency department with worsening respiratory symptoms one month after treatment for a chest infection and pleural effusion. Computerized tomography pulmonary angiogram (CTPA) showed an encysted hydropneumothorax and chronic pulmonary emboli. He was anticoagulated, had a chest drain with a good outcome and was discharged for a multidisciplinary team follow-up.

This report highlights hydropneumothorax occurring as a result of therapeutic or diagnostic pleural interventions. It also reiterates the importance of identifying the probable cause of a pleural effusion, with pulmonary embolism as a cause that should be ruled out.

Categories: Emergency Medicine, Internal Medicine, Pulmonology

Keywords: pneumonia, thoracentesis, pulmonary embolism, hydropneumothorax, pleural effusion, pneumothorax

Introduction

Hydropneumothorax is the collection of both fluid and air within the pleural space. It is a rare condition, however, it has been associated with a chest infection, malignancy, chest trauma and pleural procedures like thoracentesis [1]. Pulmonary embolism is an occlusion along the pulmonary artery by an embolus. Risk factors include deep vein thrombosis, previous venous thromboembolism (VTE), active cancer, significant immobility, and advanced age. [2] If untreated, the mortality rate is high and so early identification of pulmonary embolism and commencement of treatment is vital to increasing the chances of a good outcome and preventing mortality [3].

In this case, we highlight the differentials of patients presenting with respiratory symptoms, diagnostics difficulties and complications that can arise from pleural procedures. We also suggest that the hydropneumothorax in this patient may have been a result of pulmonary embolism.

Case Presentation

A 79-year-old man presented to the emergency department with sudden-onset shortness of breath. A month prior, he was managed for right-sided lobar pneumonia complicated by pleural effusion. The pleural effusion was aspirated, and the aspirate cytology analysis was negative for malignant tissue. He was discharged in stable condition and awaiting an outpatient chest CT scan until re-presentation. He is an ex-smoker with no other significant past medical history.

On re-presentation in the emergency department, he was dyspnoeic with a respiratory rate of 32 cycles per minute, hypoxic with oxygen saturation of 84% on room air and tachycardic with a heart rate of 106 beats per minute. He had unequal chest wall movement; absent breath sounds in the middle and lower zones of the right lung and dull percussion on the same side.

Laboratory results showed markedly increased white cell count of $17.9 \times 10^9/L$ and raised C-reactive protein (68.6 mg/L). This was in line with active pneumonia for which he was taking oral antibiotics. D-dimer levels, however, were dramatically high (>6000 ng/mlFEU). A 12-lead ECG on this patient showed sinus tachycardia and his Well's score was 4.5. A chest radiograph (Figure 1) done showed effusions on the right hemithorax with air leading to a diagnosis of a right-side hydropneumothorax.

How to cite this article

Enemoh O, Iwunna O (August 14, 2022) Hydropneumothorax and Pulmonary Embolism in a Patient With Shortness of Breath. Cureus 14(8): e27986. DOI 10.7759/cureus.27986

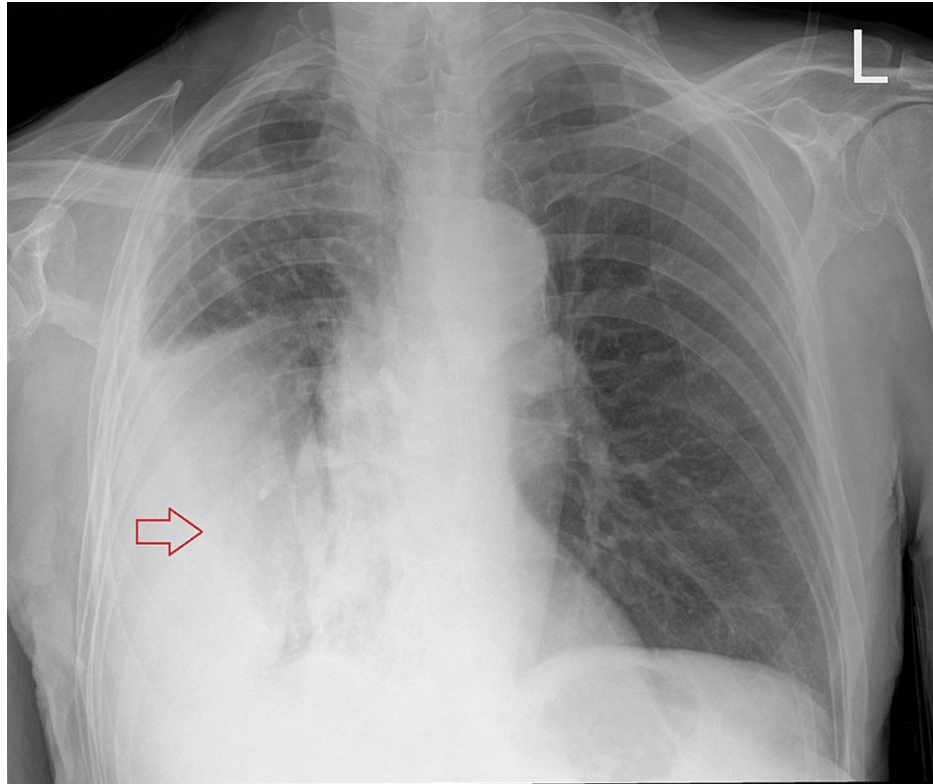


FIGURE 1: Chest radiograph shows pleural effusions with air-fluid levels in the right hemithorax (red arrow)

He was commenced on oxygen via a 28% venturi mask (with target saturations 88-92%) and intravenous fluids. In view of a diagnosis of pneumonia, he was treated with intravenous benzylpenicillin and clarithromycin according to the hospital's guidelines. Given his clinical presentation, his Well's score of 4.5 and a D-Dimer of >6,000, he had interim anticoagulation with low molecular weight heparin (LMWH) dalteparin while awaiting a CTPA to make a definitive diagnosis.

Further assessment with a CTPA (Figure 2) revealed bilateral small chronic pulmonary emboli, right-sided encysted hydropneumothorax, atelectasis and consolidation within the middle and lower zones of the right lung with broncho-centric thickening. The patient was managed with treatment doses of dalteparin for the pulmonary embolism, admitted and had a chest drain inserted while on admission with good outcomes. Repeat chest radiographs showed steady lung re-expansion (Figure 3), and he was discharged to have a multidisciplinary team (MDT) follow-up.

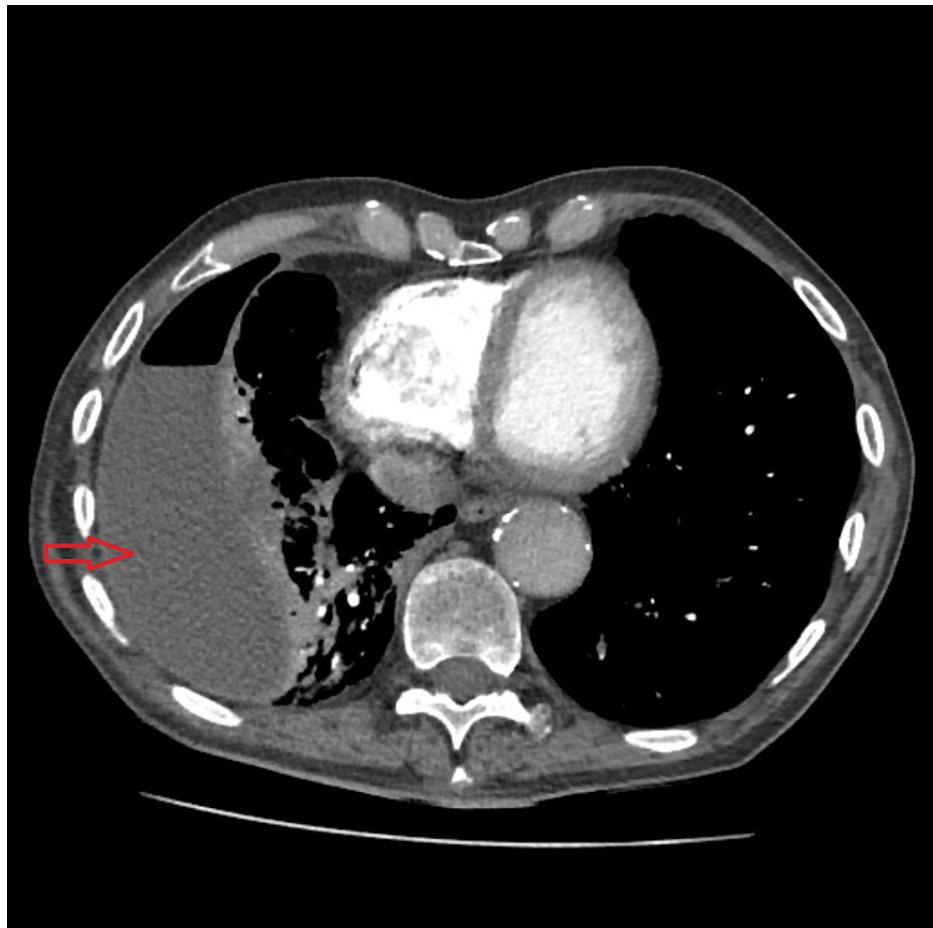

FIGURE 2: CTPA show right-sided encysted hydropneumothorax, consolidation within the right middle and lower lung zones (red arrow) and small bilateral pulmonary emboli

CTPA: computerized tomography pulmonary angiogram

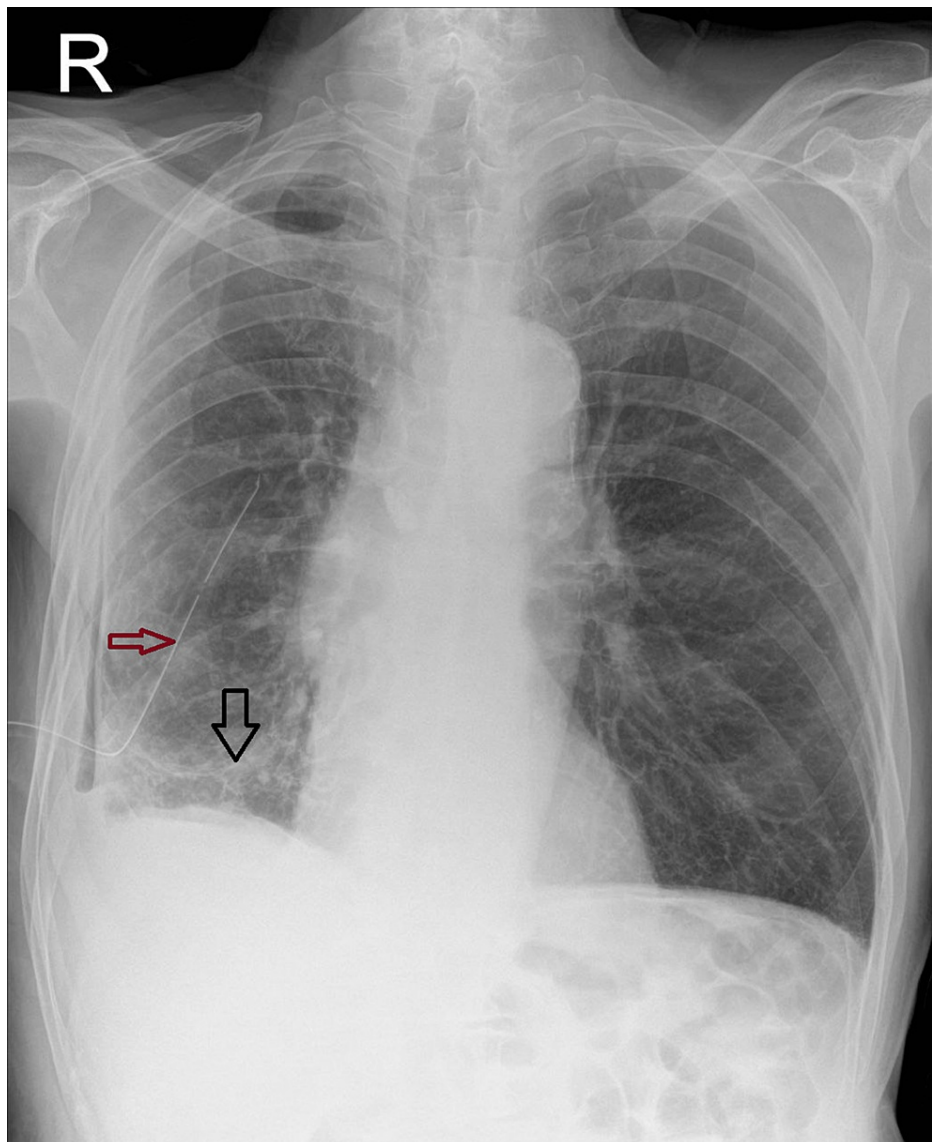


FIGURE 3: Chest radiograph with a chest tube in situ (red arrow) showing lung re-expansion (black arrow)

Discussion

Hydropneumothorax is a rare condition with varying aetiologies [4]. This case highlights some of these causes that include a complication of inflammatory processes and iatrogenic causes like thoracocentesis. Our patient had pneumonia, which was complicated by pleural effusion. He also had thoracocenteses and pleural fluid analysis. His recovery was cut short by worsening shortness of breath and on this occasion, his chest radiograph showed both fluid and air levels. While inflammatory changes can lead to structural alterations in the lung parenchyma, which ultimately lead to the development of a pneumothorax, pleural procedures, such as thoracocentesis, in this case, are an established cause [1]. We postulate that the hydropneumothorax, in this case, was a complication of the thoracocentesis done.

Pulmonary embolism is acknowledged as a leading cause of pleural effusion and is highly suggestive of pleuritic chest pain accompanied by pleural effusion [5]. CTPA done in the current presentation showed chronic pulmonary emboli. While the initial managing clinicians thought the patient's pleural effusion was a complication of his pneumonia, we believe a pulmonary embolus might be a significant causative factor. It is possible that the emboli were missed at his presentation the month before, as it was not ruled out in that presentation due to the hospital's protocols. It is, therefore, vital to have a high index of suspicion for a pulmonary embolism in a patient presenting with pleural effusion and possibly rule that out prior to discharge.

An important differential for shortness of breath is malignant processes. The pathological processes (pleural

effusion, pneumothorax and pulmonary embolism) in our patient can be explained by a malignancy; however, pleural aspirate cytology was negative for malignant cells. There is still a strong suspicion of malignancy regardless, and he will have a multidisciplinary team meeting on discharge.

It is therefore important to identify the cause, as that will determine definitive management and improve outcome.

Conclusions

This case report draws attention to hydropneumothorax occurring as a complication of therapeutic interventions and inflammatory processes. More importantly, it highlights how vital it is for clinicians to identify the probable cause of pleural effusion and provide definitive management based on the identified cause. Pulmonary embolism is an important differential diagnosis for shortness of breath, which should be excluded in the presence of risk factors, as it may be a cause of the complications.

Additional Information

Disclosures

Human subjects: Consent was obtained or waived by all participants in this study. **Conflicts of interest:** In compliance with the ICMJE uniform disclosure form, all authors declare the following: **Payment/services info:** All authors have declared that no financial support was received from any organization for the submitted work. **Financial relationships:** All authors have declared that they have no financial relationships at present or within the previous three years with any organizations that might have an interest in the submitted work. **Other relationships:** All authors have declared that there are no other relationships or activities that could appear to have influenced the submitted work.

References

1. Chaudhry M, Didenko L, Alekseyev K, Umar Farooq MU, Bilal Chaudhry B: A case of hydropneumothorax. *J Lung Pulm Respir Res.* 2021, 8:160-1. [10.15406/jlpr.2021.08.00268](https://doi.org/10.15406/jlpr.2021.08.00268)
2. NICE CKS. Pulmonary embolism: what are the risk factors? . (2022). <https://cks.nice.org.uk/topics/pulmonary-embolism/background-information/risk-factors/>.
3. Bělohávek J, Dytrych V, Linhart A: Pulmonary embolism, part I: epidemiology, risk factors and risk stratification, pathophysiology, clinical presentation, diagnosis and nonthrombotic pulmonary embolism. *Exp Clin Cardiol.* 2013, 18:129-38.
4. Corcoran JP, Psallidas I, Wrightson JM, Hallifax RJ, Rahman NM: Pleural procedural complications: prevention and management. *J Thorac Dis.* 2015, 7:1058-67. [10.3978/j.issn.2072-1439.2015.04.42](https://doi.org/10.3978/j.issn.2072-1439.2015.04.42)
5. Choi SH, Cha S-I, Shin K-M, et al.: Clinical relevance of pleural effusion in patients with pulmonary embolism. *Respiration.* 2017, 16:271-8.