



# Professional liability due to complete esophagus section during thyroidectomy: a rare case report

Cristina Mondello, Gennaro Baldino, Vincenzo Cianci, Patrizia Gualniera, Daniela Sapienza, Alessio Asmundo, Elvira Ventura Spagnolo

Section of Legal Medicine, Department of Biomedical and Dental Sciences and Morphofunctional Imaging, University of Messina, Via Consolare Valeria, Messina, Italy

*Contributions:* (I) Conception and design: E Ventura Spagnolo, A Asmundo, C Mondello; (II) Administrative support: None; (III) Provision of study materials or patients: E Ventura Spagnolo, D Sapienza; (IV) Collection and assembly of data: V Cianci, P Gualniera, G Baldino; (V) Data analysis and interpretation: C Mondello, V Cianci; (VI) Manuscript writing: All authors; (VII) Final approval of manuscript: All authors.

*Correspondence to:* Elvira Ventura Spagnolo. Section of Legal Medicine, Department of Biomedical and Dental Sciences and Morphofunctional Imaging, University of Messina, Via Consolare Valeria, 98125 Messina, Italy. Email: eventuraspagnolo@unime.it.

**Background:** Several diagnostic and therapeutic processes are regulated by guidelines and recommendations provided by International and National Societies which offer standardized indications for health-care practitioners, including the treatment of pathologies that may affect the thyroid gland. These documents are very important for patient health promotion and, also, for preventing adverse events associated with patient injuries and related malpractice litigations. Particularly, thyroid surgery can be a cause of professional liability due to complications from surgical errors. Even if the most frequent complications are hypocalcemia and recurrent laryngeal nerve injury, this surgical specialty can be also burdened by other rare and serious adverse events such as esophagus lesions.

**Case Description:** Here a case of alleged medical malpractice involving a 22-year-old woman reporting a complete esophagus section during thyroidectomy was described. The case analysis highlighted that the surgical treatment was performed for an unconfirmed Graves-Basedow disease which was then assessed as Hashimoto thyroiditis by histological exam of the removed gland. The esophagus section was treated by termino-terminal pharyngo-jejunal anastomosis and termino-terminal jejuno-esophagus anastomosis. The medico-legal analysis of the case revealed two different profiles of medical malpractice related, respectively, to the misdiagnosis of the pathology due to an inappropriate diagnostic-therapeutic procedure and the production of the complete section of the esophagus, representing an extremely rare complication of thyroidectomy.

**Conclusions:** Clinicians should ensure an adequate diagnostic-therapeutic path based on guidelines, operational procedures, and evidence-based publications. The non-observance of the “required rules” for diagnosis and treatment of thyroid disease can be associated with a very rare and severe complication that strongly compromises the patient quality of life.

**Keywords:** Thyroidectomy; esophagus injury; surgical complications; medical liability; case report

Submitted Nov 12, 2022. Accepted for publication Feb 26, 2023. Published online Apr 13, 2023.

doi: 10.21037/gs-22-670

View this article at: <https://dx.doi.org/10.21037/gs-22-670>

## Introduction

Thyroidectomy can be considered a relatively common intervention that could be performed for the treatment of neoplastic and non-neoplastic pathologies of the thyroid gland, however, as required by the Guidelines (1), the surgery should be exclusively reserved for those who could have clinical benefits.

Nowadays, the volumetric increase of the thyroid gland, the neoplastic pathology, and the autoimmune forms, are the conditions that most frequently justify the execution of this type of surgery. Indeed, in the US, numerous studies have shown that thyroidectomy is most commonly performed for symptomatic benign disease, neoplastic pathologies, and hyperthyroid conditions (2,3).

Benign conditions can lead to surgery when a volumetric increase of the organ occurs. For instance, iodine deficiency, which is known to cause goiter if not treated, can lead to surgical thyroidectomy, as it still happens today in some areas of the world, including southern Italy (4). Likewise, it is important to mention thyroid autoimmune disorders, such as Hashimoto's thyroiditis (5) and Graves-Basedow's disease (6). In the classic variant of Hashimoto's thyroiditis, where Thyroid peroxidase antibodies (TPOAB) and Thyroglobulin antibodies (TGAB) are detected, surgery is required only after the development of a voluminous goiter (7). In the same way, according to the guidelines (1), the use of surgery in Graves-Basedow's disease should be considered in those cases when antithyroid drug therapy and radioactive iodine (RAI) therapy failed. Nevertheless, surgery seems to be more effective than RAI therapy and

to improve the quality of life of these patients (8). Another condition that could lead to the thyroidectomy is cancer, which can occur in both sporadically and syndromic forms (9).

According to the most recent data in the scientific literature, it is possible to consider thyroidectomy as a low-risk surgery (10), even in patients commonly considered to be at higher surgical risk. The most common complications that are annually recorded in the post-operative phase are hypocalcemia and recurrent laryngeal nerve injury, as well as hematomas of the neck region and skin scarring abnormalities; while the vascular and other complications such as nerve plexus injuries are much less represented (11,12). Unfortunately, in the literature are reported rarer but more serious adverse events, such as bilateral recurrent nerve paralysis which result in fixation of the vocal cords and the esophagus lesion (13).

It is known that some complications are more common than others because of the relationship between the anatomical structures of the thyroid gland and the surrounding anatomical structures. On average, temporary hypoparathyroidism appeared in 20–30% of cases, which was then permanent in 1–4% of cases (14).

At the same time, recurrent laryngeal nerve dissection is responsible for permanent dysphonia in 1–3.5% (14,15). Literature evidence has shown a higher rate of surgical complications, besides being more serious, in the treatment of neoplastic pathologies of the thyroid rather than in the non-neoplastic ones (16). A meta-analysis that included 14,934 patients showed a 3.4% incidence of recurrent laryngeal nerves (RLN) paralysis for all thyroid pathologies who underwent thyroidectomy (17). The incidence was higher for malignant tumors (5.7%) where the RLN may be directly invaded. Bilateral recurrent laryngeal nerve paralysis is a life-threatening complication with an estimated incidence of approximately 0.4%.

Among the thyroidectomy complications, the literature described just a few isolated cases of tracheal or esophageal lesions (13).

The authors report a rare case of a complete lesion of the cervical esophagus during thyroidectomy. Literature describes few cases of esophagus lesion during thyroidectomy more frequently represented by perforation or partial injury, whereas only one case with complete resection is reported (18–20). Here, the case was analyzed from a medico-legal point of view, evaluating if a malpractice profile could emerge from the patient diagnostic-therapeutic process. We present this case in

### Highlight box

#### Key findings

- This study represents a medico-legal analysis of a case of professional liability during a thyroidectomy that led to the occurrence of a very rare and equally serious complication represented by the complete lesion of the esophagus.

#### What is known and what is new?

- The complete lesion of the esophagus during thyroidectomy is a very rare complication described in the literature only three times so far and due to the wrong diagnostic-therapeutic process related to non-observance of guidelines and good clinical-care practices.

#### What is the implication, and what should change now?

- The complication described may lead to serious and permanent damages that could affect the patient's life, and it is therefore important to know and follow the up-to-date recommendations.

accordance with the CARE reporting checklist (available at <https://gs.amegroups.com/article/view/10.21037/gS-22-670/rc>).

### Case presentation

A 22-year-old woman with suspicion of Graves-Basedow's disease underwent thyroidectomy. The analysis of clinical records resulted that the woman, four years earlier, carried out an endocrinological examination during which would be identified signs suggestive of hyperthyroidism, such as easy irritability, insomnia, and difficulty concentrating. Graves-Basedow's disease was diagnosed by the endocrinologist using the serum assay of the main thyroid function indicators such as thyroid-stimulating hormone (TSH), triiodothyronine (FT3), and thyroxine (FT4), which, at that time, were modestly increased. A neck ultrasound was performed, and the following description has been made: ".....*finely and diffusely inhomogeneous echo-structure of the thyroid gland with evidence of multiple hypoechoic areas*". The main thyroid autoantibodies' dosage was not requested, although they are essential in the differential diagnosis of the main thyroid autoimmune pathologies.

Then, a new serum assay of the main thyroid function indicators showed normal values of TSH (1.990 mU/mL), FT4 (1.03 ng/dL), and FT3 (4.07 pg/mL).

In November 2020, the patient consults a surgeon who suggests undergoing a thyroidectomy.

During the pre-hospitalization period, a cardiological, an anesthesiological, and a radiological examination were performed; but, even in this case, despite having blood tests performed, neither thyroid hormones nor the dosage of the main thyroid autoantibodies was requested by specialists. Therefore, the patient was hospitalized in order to undergo surgery the day after, with a diagnosis of Graves-Basedow's disease.

During surgery, trying to isolate the left lobe of the thyroid, a "*vast laceration of the cervical esophagus*" would have occurred, due to the presence of tenacious adhesions between the left lobe of the thyroid and the esophagus. Immediately, after performing the total thyroidectomy, the patient was transferred to another hospital where it was confirmed the diagnosis of "*a complete and complex laceration of the cervical esophagus at 360°*", with the two esophageal stumps, 3 cm far from each other. Moreover, it was also observed a lesion of the recurrent nerve, causes paralysis in the abduction of the ipsilateral vocal cord and compensation of the contralateral vocal cord.

A first temporary surgical repair by anastomosis of the proximal and distal esophagus was performed by an otolaryngologist (*Figure 1*) just to allow the patient to be transferred to a specific center for the definitive recanalization of the gastrointestinal tract. Thus, the patient was transferred by airplane in the high specialization and health care facility where a free jejunal loop autotransplantation with vascular microanastomosis for reconstruction of digestive continuity was performed. In particular, the Upper Gastrointestinal surgeons carried out a termino-terminal pharyngo-jejunal anastomosis and termino-terminal jejuno-esophagus anastomosis. Because of the young age of the patient, the surgical team chose not to proceed with pharyngolaryngeal-esophagectomy surgery and pharyngogastroplasty, as this surgery would have involved a definitive tracheotomy. In the future, however, tracheotomy could not be excluded, especially if rare complications will occur (i.e., anastomotic stricture).

Furthermore, the histopathological examination of the resected thyroid allowed to diagnose a Hashimoto's thyroiditis and not Graves-Basedow's disease. No clinically relevant events occurred during the post-operative period, except for the onset of a generalized anxiety disorder and depressive crises linked to the traumatic event.

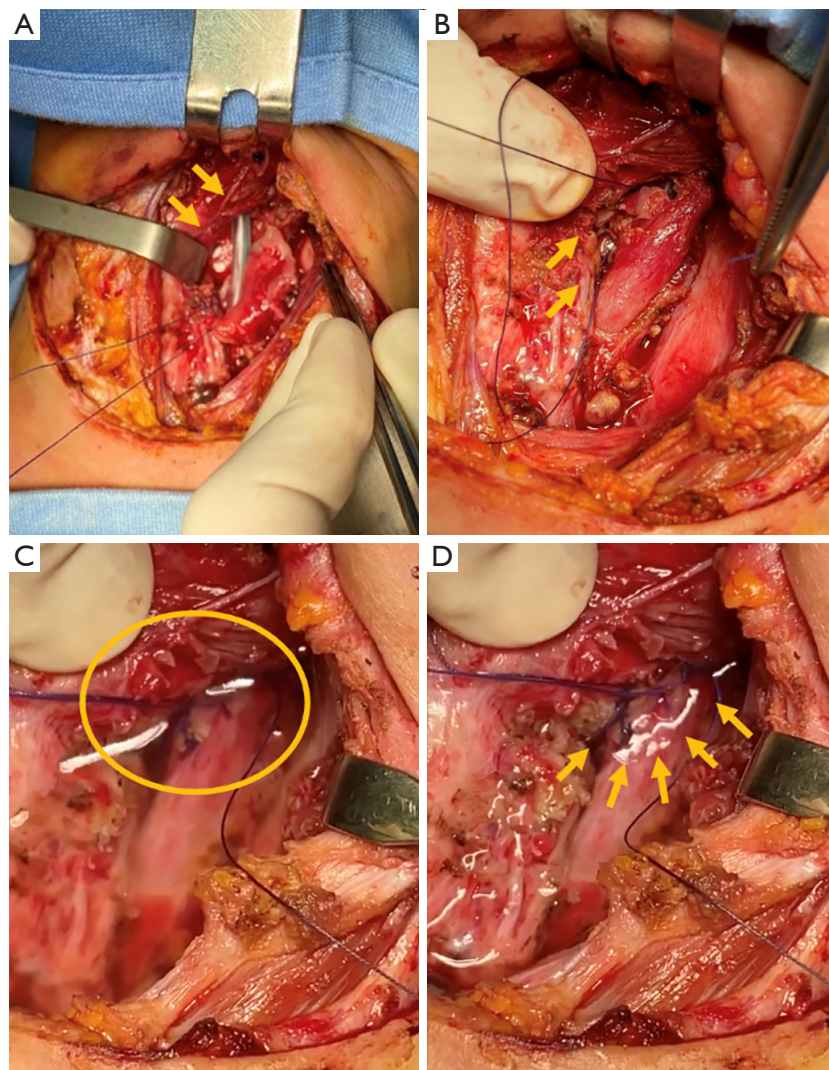
All procedures performed in this study were in accordance with the ethical standards of the institutional and/or national research committee(s) and with the Helsinki Declaration (as revised in 2013). The consent to use the clinical data and images for research purpose has been provided by the patient. The data of the case were reported respecting the anonymity of the subject. A copy of the written consent is available for review by the editorial office of this journal.

### Discussion

The analysis of the reported case has brought out two different profiles of medical malpractice related, respectively, to the misdiagnosis of the pathology due to inappropriate diagnostic-therapeutic procedures and the production of the complete section of the esophagus, representing an extremely rare complication of thyroidectomy.

Focusing on the wrong diagnostic-therapeutic process that led to the thyroidectomy, the following critical issues can be discussed.

If Graves-Basedow's disease is suspected, the finding of a high value of TSH and peripheral thyroid hormones cannot be considered a sufficient finding, and, therefore,



**Figure 1** Lesion with left displacement of the esophagus and complete nasogastric tube exposure. (A) Tubulation and anchoring of the proximal esophageal stump, (B-D) reconstruction with 3/0 vicryl stitches and control of the anastomosis using both lactated Ringer's solution and air highlighted by yellow circle and yellow arrows.

the determination of antibodies against the TSH receptor should always be performed to corroborate the diagnosis. Indeed, it is known that TSH receptor antibody (TRAb) measurement is highly sensitive and specific for the detection of Graves-Basedow's disease and is clinically useful for the differential diagnosis of autoimmune thyroiditis (21). At the same time, in the diagnostic process of the pathology, an ultrasound examination should also be performed to evaluate the echo-structural alterations of the gland (22).

The goal of the treatment of Graves-Basedow's disease is to reduce the levels of peripheral thyroid hormones. Glucocorticoids can reduce the conversion of T4 to T3 and

lower the thyroid hormone with unknown mechanisms.

The treatment of this pathology consists of anti-thyroid drugs, RAI with iodine-131 and/or surgery. The choice of treatment is based on several factors, among which are the severity of the thyrotoxicosis, age, size of the goiter, response to the treatments, and other comorbidities (23).

Once the diagnosis is confirmed, according to the Guidelines (1), the first therapeutic approach involves the use of antithyroid drugs. Two different types of anti-thyroid drugs, propylthiouracil (PTU) and methimazole can be chosen. PTU inhibits the absorption of iodides, while methimazole works by inhibiting the oxidation of iodine in



the thyroid gland. If the primary therapy is based on one of these two drugs, it should be given for at least 12–18 months and will be interrupted as the concentrations of TSH and TRAb reach normal values (24). Azizi *et al.* (25) reported that prolonged use of anti-thyroid drugs is effective and safe, especially for adults. Therefore, anti-thyroid drugs are the first choice for Graves-Basedow's disease treatment. Evidence supports the use of these drugs, such as the high rate of remission (mild clinical manifestation, woman, negative or low TRAb, mild goiter) the possibility of using them in the elderly or pregnant woman, in patients unable to follow the regulation of radioactive iodine therapy (i.e., subjects recovered in a nursing home or other health care facilities), or in subjects with a history of surgery or neck radiation, and it can be very useful in those cases when a rapid reduction of fT4 level is needed (24).

Treatment with radioactive iodine is recommended when drug therapy is ineffective, as long as the glandular volume does not exceed 43 cc. RAI can still be used in patients with risks of anti-thyroid drug side effects and with comorbidities. The main indications of RAI therapy are contraindications for anti-thyroid drugs or failure to reach euthyroidism with pharmacological treatments; women planning on pregnancy; patients with periodic thyrotoxicosis hypokalemic paralysis; right heart failure caused by pulmonary hypertension or congestive heart failure (24).

Thyroidectomy should be performed if a volumetric increase of the thyroid gland (more than 43 cc) is detected, after the failure of medical therapy for more than two months, and if severe exophthalmos occurs (24). Particularly, the main indications to execute thyroidectomy in Graves-Basedow's disease are enlarged goiter and compression of other organs surrounding the thyroid gland; hyperparathyroidism; high TRAb level (difficult to treat with anti-thyroid drugs); and moderate or severe active Graves-Basedow's ophthalmopathy (24).

The presented case highlighted weakness in the diagnostic process allowing for a wrong diagnosis of Graves-Basedow's disease which also provided an incongruous surgical treatment. The non-execution of laboratory test (TRAb measurement), recommended by both guidelines and scientific literature, lead to the diagnostic error (the histological examination revealed Hashimoto's thyroiditis). In addition, the clinicians resorted to thyroidectomy even if no conditions to justify the surgical procedure occurred.

The lesion of the cervical esophagus during thyroidectomy is an exceptionally rare complication (26),

and it becomes even rarer when a complete section is caused, as in our case.

The esophagus and the thyroid, although adjacent, are separated by an evident cleavage plane, there are conditions in which this space tends to shrink, as in invasive neoplastic phenomena and inflammatory phenomena (27) that can result in fibrotic areas making the detachment of the organ more difficult and increasing the risk of esophageal injury. However, in those cases where it occurs, the poor literature describes the esophageal lesion with partial damage of the esophageal wall and not the circumferential section. Other conditions that could make the cleavage plane less evident are bleedings, albeit small, an occurrence that has not been described in our case.

In our report, there were no anatomical and/or pathological factors that negatively affect the thyroid dissection from the esophagus in order to promote the risk of a complete esophagus section. Thus, the professional liability of the surgeons to produce the iatrogenic lesion was admitted leading to a damage compensation proposal by an extrajudicial procedure.

## Conclusions

In conclusion, the reported case highlighted that the progress in the diagnostic procedures and the management of thyroid disease, support the relevance of algorithmic, personalized, and evidence-based care.

Considering guidelines, operational procedures, evidence-based publications, and other literature data, it is possible to understand why an “ideal medical conduct” is requested by practitioners and how professional liability can arise when the performed activities do not meet the required standard of care. These considerations emerged in the described case because the non-observance of the “required rules” for the diagnosis and the treatment of thyroid disease led to a very rare and severe complication that will strongly compromise the quality of life of the subject.

## Acknowledgments

*Funding:* None.

## Footnote

*Reporting Checklist:* The authors have completed the CARE reporting checklist. Available at <https://gs.amegroups.com/>

[article/view/10.21037/gS-22-670/rc](https://doi.org/10.21037/gS-22-670/rc)

*Peer Review File:* Available at <https://gs.amegroups.com/article/view/10.21037/gS-22-670/prf>

*Conflicts of Interest:* All authors have completed the ICMJE uniform disclosure form (available at <https://gs.amegroups.com/article/view/10.21037/gS-22-670/coif>). The authors have no conflicts of interest to declare.

*Ethical Statement:* The authors are accountable for all aspects of the work in ensuring that questions related to the accuracy or integrity of any part of the work are appropriately investigated and resolved. All procedures performed in this study were in accordance with the ethical standards of the institutional and/or national research committee(s) and with the Helsinki Declaration (as revised in 2013). The consent to use the clinical data and images for research purpose has been provided by the patient. The data of the case were reported respecting the anonymity of the subject. A copy of the written consent is available for review by the editorial office of this journal.

*Open Access Statement:* This is an Open Access article distributed in accordance with the Creative Commons Attribution-NonCommercial-NoDerivs 4.0 International License (CC BY-NC-ND 4.0), which permits the non-commercial replication and distribution of the article with the strict proviso that no changes or edits are made and the original work is properly cited (including links to both the formal publication through the relevant DOI and the license). See: <https://creativecommons.org/licenses/by-nc-nd/4.0/>.

## References

- Patel KN, Yip L, Lubitz CC, et al. The American Association of Endocrine Surgeons Guidelines for the Definitive Surgical Management of Thyroid Disease in Adults. *Ann Surg* 2020;271:e21-93.
- Rubio GA, Koru-Sengul T, Vaghaiwalla TM, et al. Postoperative Outcomes in Graves' Disease Patients: Results from the Nationwide Inpatient Sample Database. *Thyroid* 2017;27:825-31.
- Sun GH, DeMonner S, Davis MM. Epidemiological and economic trends in inpatient and outpatient thyroidectomy in the United States, 1996-2006. *Thyroid* 2013;23:727-33.
- Moleti M, Sturniolo G, Trimarchi F, et al. The changing phenotype of iodine deficiency disorders: a review of thirty-five years of research in north-eastern Sicily. *Ann Ist Super Sanita* 2016;52:550-7.
- Caturegli P, De Remigis A, Rose NR. Hashimoto thyroiditis: clinical and diagnostic criteria. *Autoimmun Rev* 2014;13:391-7.
- Leporati P, Gropelli G, Zerbini F, et al. Etiopathogenesis of Basedow's disease. Trends and current aspects. *Nuklearmedizin* 2015;54:204-10.
- Weetman AP. An update on the pathogenesis of Hashimoto's thyroiditis. *J Endocrinol Invest* 2021;44:883-90.
- Genovese BM, Noureldine SI, Gleeson EM, et al. What is the best definitive treatment for Graves' disease? A systematic review of the existing literature. *Ann Surg Oncol* 2013;20:660-7.
- Davies L, Welch HG. Increasing incidence of thyroid cancer in the United States, 1973-2002. *JAMA* 2006;295:2164-7.
- Ward ND, Lee CY, Lee JT, et al. Esophageal fistula complicating thyroid lobectomy. *J Surg Case Rep* 2015;2015:rju136.
- Bawa D, Alghamdi A, Albishi H, et al. Post-thyroidectomy complications in southwestern Saudi Arabia: a retrospective study of a 6-year period. *Ann Saudi Med* 2021;41:369-75.
- Ventura Spagnolo E, Mondello C, Rocuzzo S, et al. Fire in operating room: The adverse "never" event. Case report, mini-review and medico-legal considerations. *Leg Med (Tokyo)* 2021;51:101879.
- Christou N, Mathonnet M. Complications after total thyroidectomy. *J Visc Surg* 2013;150:249-56.
- Thomusch O, Machens A, Sekulla C, et al. Multivariate analysis of risk factors for postoperative complications in benign goiter surgery: prospective multicenter study in Germany. *World J Surg* 2000;24:1335-41.
- Gualniera P, Scurria S, Mondello C, et al. Narrative review of proving the causal link of recurrent laryngeal nerve injury and thyroidectomy: a medico legal appraisal. *Gland Surg* 2020;9:1564-72.
- Caulley L, Johnson-Obaseki S, Luo L, et al. Risk factors for postoperative complications in total thyroidectomy: A retrospective, risk-adjusted analysis from the National Surgical Quality Improvement Program. *Medicine (Baltimore)* 2017;96:e5752.
- Rosato L, Avenia N, Bernante P, et al. Complications of thyroid surgery: analysis of a multicentric study on 14,934 patients operated on in Italy over 5 years. *World J Surg* 2004;28:271-6.
- Peng H, Wang SJ, Li W. Rare complication after

- thyroidectomy-cervical esophageal stenosis: a case report and literature review. *World J Surg Oncol* 2014;12:308.
19. Gómez-Ramírez J, Sitges-Serra A, Moreno-Llorente P, et al. Mortality after thyroid surgery, insignificant or still an issue? *Langenbecks Arch Surg* 2015;400:517-22.
  20. Maupoey Ibáñez J, Ballester Pla N, García-Domínguez R, et al. Surgical management of a complete section of the oesophagus during total thyroidectomy. *Cir Esp* 2017;95:118-20.
  21. Goichot B, Leenhardt L, Massart C, et al. Diagnostic procedure in suspected Graves' disease. *Ann Endocrinol (Paris)* 2018;79:608-17.
  22. Allelein S, Schott M. Morbus Basedow [Graves' Disease]. *Dtsch Med Wochenschr* 2021;146:1337-43.
  23. Subekti I, Pramono LA. Current Diagnosis and Management of Graves' Disease. *Acta Med Indones* 2018;50:177-82.
  24. Ross DS, Burch HB, Cooper DS, et al. 2016 American Thyroid Association Guidelines for Diagnosis and Management of Hyperthyroidism and Other Causes of Thyrotoxicosis. *Thyroid* 2016;26:1343-421.
  25. Azizi F, Malboosbaf R. Long-Term Antithyroid Drug Treatment: A Systematic Review and Meta-Analysis. *Thyroid* 2017;27:1223-31.
  26. Ozer MT, Demirbas S, Harlak A, et al. A rare complication after thyroidectomy: perforation of the oesophagus: a case report. *Acta Chir Belg* 2009;109:527-30.
  27. Lynch J, Parameswaran R. Management of unilateral recurrent laryngeal nerve injury after thyroid surgery: A review. *Head Neck* 2017;39:1470-8.

**Cite this article as:** Mondello C, Baldino G, Cianci V, Gualniera P, Sapienza D, Asmundo A, Ventura Spagnolo E. Professional liability due to complete esophagus section during thyroidectomy: a rare case report. *Gland Surg* 2023;12(5):716-722. doi: 10.21037/gs-22-670