

# A challenging diagnosis of malignant mesothelioma with osteosarcomatous differentiation metastasizing to bone

Michael Brown<sup>1,2</sup> , Hubertus Jersmann<sup>1,2</sup>, Thomas Crowhurst<sup>1,2</sup> , Chris Van Vliet<sup>3</sup>, Gareth Crouch<sup>4</sup> & Arash Badiei<sup>1,2</sup>

<sup>1</sup>Department of Thoracic Medicine, Royal Adelaide Hospital, Adelaide, Australia.

<sup>2</sup>Faculty of Health and Medical Sciences, Adelaide Medical School, University of Adelaide, Adelaide, Australia.

<sup>3</sup>Department of Anatomical Pathology, PathWest Laboratory Medicine, QEII Medical Centre, Nedlands, Western Australia, Australia.

<sup>4</sup>Department of Cardiothoracic Surgery, Royal Adelaide Hospital, Adelaide, Australia.

## Keywords

Mesothelioma, metastasis, pleura, pleural effusion, thoracoscopy.

## Correspondence

Michael Brown, Department of Thoracic Medicine, Royal Adelaide Hospital, Port Road, Adelaide, WA 5000, Australia. E-mail: michael.v.brown@sa.gov.au

Received: 21 July 2020; Revised: 24 August 2020;  
Accepted: 3 September 2020; Associate Editor:  
Phan Nguyen.

*Respirology Case Reports*, 8 (8), 2020, e00664

doi: 10.1002/rcr2.664

## Abstract

Malignant pleural mesothelioma (MPM) is an insidious primary neoplasm of the pleura that can be challenging to diagnose and is commonly considered to be only locally invasive. We present the case of a 74-year-old male who presented with clinical features of MPM but from whom pleural fluid and biopsies initially suggested benign pathology. He later developed diffuse bony metastases and re-examination of pleural biopsies using modern immunohistochemistry and molecular testing revealed a diagnosis of sarcomatoid and desmoplastic MPM with heterologous osteosarcomatous differentiation. This case not only demonstrates the rare potential of skeletal metastasis of MPM, but also highlights the importance of recognizing the utility of modern diagnostic tests and their potential to prevent the need for unnecessary invasive procedures. To our knowledge this is the first description of this rare histological sub-type presenting with skeletal metastases.

## Introduction

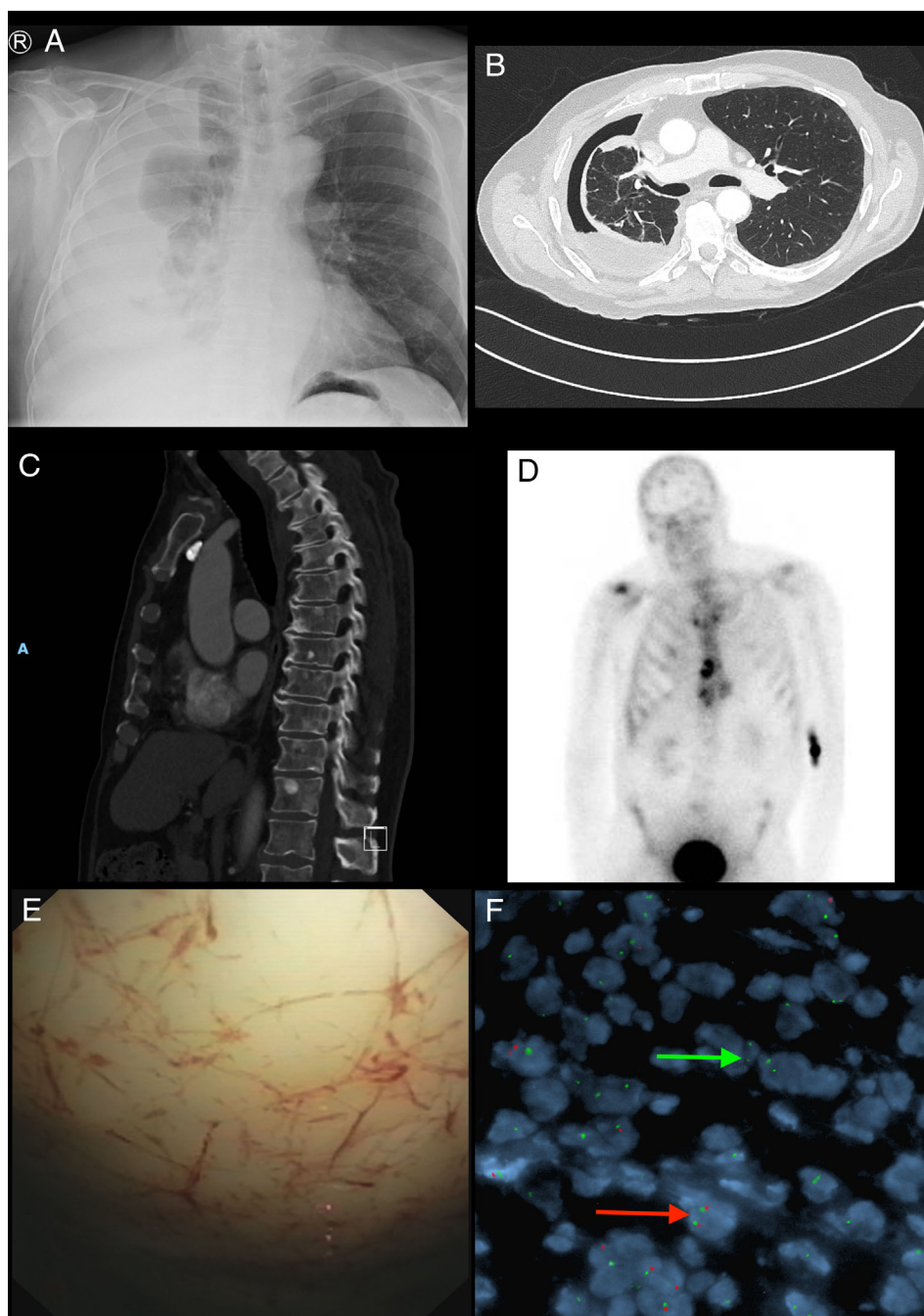
Malignant mesotheliomas are rare neoplasms arising from mesothelial surfaces (pleura, peritonea, tunica vaginalis, or pericardium). Malignant pleural mesothelioma (MPM) is the most common primary tumour of the pleura. Although traditionally associated with local spread and invasion, distant metastases to bone can rarely occur. Diagnostically, these tumours are challenging, either due to difficulties obtaining adequate malignant cellular material or similarity to adenocarcinoma. Some MPM sub-types, such as epitheloid MPM, can be diagnosed from pleural fluid cytology. Rarer sub-types like desmoplastic MPM are more challenging. We present a patient with clinical features of MPM whose pleural fluid cytology and pleural biopsies favoured a benign process despite multiple invasive procedures. Months later, the patient developed bony metastases. Biopsy of a metastasis and re-examination of the original pleural biopsies with modern immunohistochemistry and molecular testing diagnosed combined sarcomatoid and desmoplastic MPM with heterologous

osteosarcomatous differentiation. To our knowledge, this is the first description of this histological sub-type presenting with skeletal metastases.

## Case Report

A 74-year-old reformed smoker (five pack-years) presented with progressive dyspnoea over twelve months. He had immigrated to Australia from the United Kingdom in 1968. His occupations included working as an airline apprentice and industrial engraver. He had 18-months of asbestos exposure as a maintenance fitter in the 1960s, cutting asbestos sheets. There was no personal history of lung disease or malignancy. His brother was a carpenter and died of mesothelioma. His father was a stone worker who died from gastric cancer.

A right-sided pleural effusion was identified (Fig. 1A). Thoracentesis revealed blood-stained, exudative pleural fluid with negative cytology. Subsequent chest computed tomography (CT) showed non-expandable lung due to thickening of the visceral pleura (Fig. 1B). A uniport



**Figure 1.** (A) Chest X-ray showing a large right-sided pleural effusion with lung collapse; (B) computed tomography (CT) chest demonstrating non-expandable/trapped lung and pleural thickening; (C) CT chest showing vertebral metastases; (D) bone scan showing widespread osteoblastic metastasis to skull, vertebrae, ribs, sternum, and iliac crests; (E) pleuroscopy view of diffusely thickened pleura; (F) fluorescence in-situ hybridization: green arrow shows abnormal nuclei with homozygous deletion of *CDKN2A* at 9p21 (absent red signals in the presence of two green chromosome 9 centromere signals). Red arrow shows nuclei with intact *CDKN2A* (two red target signals and two green chromosome 9 centromere signals).

pleuroscopy with parietal pleural biopsies was performed (Fig. 1E). Histology demonstrated mild cytological atypia favoured to represent fibrinous pleuritis.

One-month later, persisting clinical concern and pleural effusion recurrence, prompted a right thoracotomy with parietal and visceral pleural biopsies and a lung wedge biopsy. The visceral rind was notably invading into the underlying lung. The initial pathology also favoured benign pleuritis and morphologic and immunohistochemical

evaluation did not establish a malignant neoplasm. The lung wedge was deemed non-contributory, although the biopsy consisted of parenchymal hyalinised nodules with spindle cell proliferations. Breast cancer susceptibility gene 1 (BRCA1)-associated protein-1 (BAP-1) staining was performed and did not demonstrate BAP-1 loss.

Six months later, the patient remained well, but had required two further chest drains and insertion of an indwelling tunnelled pleural catheter for recurrent effusions.

Given ongoing clinical and radiological concern for MPM, the treating team sought a second opinion on the surgical sample with fluorescence in situ hybridization (FISH) analysis from a pathology centre with MPM diagnostic expertise.

This pathology assessment reported a hypocellular spindle cell proliferation embedded within a rind of dense fibrosclerotic tissue. The spindle cells were arranged in cords, short fascicles, and storiform patterns. One cellular foci was intimately associated with osteoid. A pleural-based nodule with a hyalinized central zone with spindle cells and storiform pattern peripherally was identified. Immunohistochemistry showed that the spindle cells expressed Cytokeratin (CK) AE1 + 3 and D2-40 with limited staining for CK5/6 and calretinin. BAP-1 expression was preserved and there was no staining for Wilms' Tumour 1 (WT1). Interphase FISH studies showed homozygous loss of cyclin-dependent kinase inhibitor 2A (*CDKN2A*) at 9p21 in three separate biopsy samples, including the pleura and wedge specimens (Fig. 1F). A diagnosis of sarcomatoid and desmoplastic mesothelioma with heterologous osteosarcomatous differentiation was made. The patient declined chemotherapy.

Nine months after his initial investigations, CT chest demonstrated widespread lytic lesions of the right ribs and sternum and innumerable sclerotic lesions within the spine (Fig. 1C). Whole body bone scan showed widespread osteoblastic metastases (Fig. 1D). CT-guided biopsy of the sternum showed features consistent with metastatic MPM with sarcomatoid and desmoplastic patterns.

## Discussion

MPM has an incidence in Australia of 2.8 per 100,000 with a male–female ratio of 4:1 (1). The number of cases has been rising, correlating with high per capita asbestos exposure, which has an aetiological fraction above 80% (2). Asbestos use peaked in the 1970s and declined until its ban in 2003. The long latency between exposure and disease means the incidence of MPM has only recently plateaued in Australia (1).

MPM presents non-specifically with chest pain, dyspnoea, and cough. Pleural effusion is common. Rarely, MPM presents with local invasion or distant metastases. The prognosis is poor due to its aggressive natural history, insidious presentation, diagnostic complexity, as well as the paucity of treatment options. Survival depends on the mesothelioma type, which is categorized by the World Health Organization (WHO) into three major subtypes. Epithelioid is the most common variant, followed by sarcomatoid and biphasic, which contains both sarcomatoid and epithelioid areas. Desmoplastic mesothelioma is a subtype of the sarcomatoid form (3). Rusch et al. analysed 3101 patients and reported median survival

times at 19 months for epithelioid, 13 months for biphasic, and eight months for sarcomatoid tumours (4). Poor survival rates particularly for sarcomatous mesothelioma are documented in other studies with survival rates closer to six months and as low as 3.5 months (5). Cantin et al. analysed a desmoplastic subgroup and of their 26 patients the median survival was 5.0 months (6).

Diagnosing mesothelioma is challenging, often requiring multiple invasive pleural procedures. Recent advances in cytological and histological testing techniques have improved diagnostic pathways. Pleural effusion often provides the first opportunity for cytological analysis and this can be an adequate diagnostic test without needing further invasive tests, particularly for epithelioid and biphasic MPM (7). Sarcomatoid MPM is more difficult to diagnose because cells are not exfoliated into the pleural fluid and hence additional invasive tests are often required. The International Mesothelioma Interest Group (IMIG), endorsed by the International Academy of Cytology and the Papanicolaou Society of Cytopathology, have released diagnostic criteria for the diagnosis of epithelioid and biphasic MPM in pleural fluid (8). The sensitivity and positive predictive value for pleural fluid cytology in diagnosing MPM is reported as 86% and 99%, respectively (9). If pleural fluid cytology is negative but clinical suspicion persists, tissue biopsy should be pursued to identify characteristic histological features, which are outlined in the WHO classification (3,10).

A diagnostic challenge is differentiating MPM from adenocarcinoma and mesothelial fibrinous pleuritis. Immunohistochemistry is particularly important and can be performed on cytological (including pleural fluid) or histological specimens. The immunohistochemical markers reflected in the IMIG and WHO guidelines for tumours of mesothelial origin are calretinin, CK5/6, WT1, D2-40, and mesothelin. Epithelial markers include claudin 4, CEA, MOC31, TAG-72, Ber-EP4, and MUC4 (3,10,11).

Recently, BAP-1 immunohistochemistry has been recognized as a useful ancillary test in diagnosing mesothelioma. BAP-1 protein loss in MPM ranges from 56% to 68% (12) and is particularly common in epithelioid tumours rather than sarcomatoid subtypes (13). There are no current reports of BAP-1 protein loss in benign mesothelial proliferations; therefore, it is a useful marker to differentiate benign versus malignant (14,15).

FISH testing for *CDKN2A* is an additional test that should be performed if the diagnosis is uncertain; this was a critical diagnostic test in our case. Homozygous deletion of *CDKN2A* occurs in all forms of MPM with prevalence of 67–100% in sarcomatoid, 69–95% in biphasic and 48–70% in epithelioid subtypes (13). Importantly, *CDKN2A* FISH can reliably distinguish between sarcomatoid mesothelioma and fibrinous pleuritis (16).

**Table 1. Identified case reports of metastatic malignant mesothelioma to bone in the English literature.**

Author	Year	Age	Sex	Histology	Site of metastases
Ihara et al. (27)	2018	64	M	Epithelioid	Bone marrow, thoracic spine, lumbar spine, and sacral vertebra. Spinal cord compression at T11/12
Arslan et al. (28)	2016	59	M	Epithelioid	Retromolar trigone, C7 vertebra
Knipscheer et al. (29)	2013	64	M	Biphasic	Left humerus, bone marrow
	2013	64	M	Mesenchymal	Thoracic vertebrae, bone marrow
Lester and Xu (30)	2008	76	F	Biphasic	Right femoral neck
Terakado et al. (31)	2004	53	M	Sarcomatoid	Mandible, small intestine
Swayne et al. (32)	1992	70	F	Biphasic	Right acetabulum
Cheng and Berkman (33)	1990	71	M	Biphasic	Pericardium, thoracolumbar vertebrae and abdominal organs
Machin et al. (34)	1988	78	M	Desmoplastic	Pelvis and vertebrae
	1988	70	M	Desmoplastic	Both humeri, femurs, 8th rib bilaterally
Cedr�s et al. (35)	2013	67	M	Epithelioid	Thoracic and lumbar vertebrae and nerve root involvement compressing L3
Laurini (36)	1974	56	M	Biphasic	Right head of humerus, C7 to L5 vertebrae, pericardium
Hirano et al. (37)	2003	77	M	Desmoplastic	Thoracic vertebrae, meninges and liver (found on autopsy)
Ishikawa et al. (38)	2003	82	F	Desmoplastic	9th and 10th thoracic vertebrae (found on autopsy)
Hayashi et al. (39)	2010	70	M	Biphasic	Stomach, "spine and breast bone"
Huang et al. (40)	2009	64	M	NA	T11 vertebra
Singh et al. (41)	2013	58	F	NA	Left femur
Moskowitz et al. (42)	2016	71	M	Desmoplastic	Iliac crests, calvarium and clivus

In combination, BAP-1 immunohistochemistry and *CDKN2A* FISH analysis have 100% specificity for malignant mesothelioma (17,18). Hwang et al. reported a combined sensitivity of 85% for sarcomatoid and desmoplastic MPM (19). Hence, these tests should be pursued in challenging cases when clinical suspicion is high and the diagnosis remains uncertain after traditional analysis.

Metastatic MPM is a rare but well-documented phenomenon often only recognized at autopsy. A post-mortem study of 318 patients with MPM identified distant metastases in 55.4% of cases, including the liver (31.9%), bone (13.8%), spleen (10.8%), thyroid (6.9%), and brain (3.0%) (20). The rate of bone metastasis is documented similarly in other studies (21). Cantin et al. published a case series looking specifically at the distant spread of desmoplastic mesothelioma and of 27 autopsy cases, 11 had distant metastases to lymph nodes (33.3%), liver (27.8%), lung (16.6%), adrenal glands (16.6%), and kidneys (16.6%) (6). Other metastatic sites for MPM have been described, including cutaneous and breast metastases (22,23), bowel (24), oral cavity (25), and the central nervous system (26).

Case reports of distant skeletal metastases are uncommon. We identified 18 in the English literature (Table 1).

Skeletal metastases were more common in males (79%) and in those with biphasic sub-types (six cases). This was followed by desmoplastic (five cases), epithelioid (three cases), mesenchymal and sarcomatoid mesothelioma (one case each) subtypes. The most common site was the vertebra (56% of cases). Long bone involvement was seen in 28% of cases.

Heterologous osteosarcomatous differentiation is rare. Klebe et al. presented 27 cases of heterologous differentiation and reviewed another 23 published cases (43). Twelve of these cases were previously described by Yousem and Hochholzer (44). Itano et al. have also described the literature and a case of sarcomatoid pleural mesothelioma with osteosarcomatous differentiation (45). Including this case, 56 cases of heterologous pleural mesothelioma have currently been reported. In this group, metastatic disease was infrequently recorded. Goldstein reported lung, epicardium, and liver metastasis (46). Salgado et al. identified metastasis in the mediastinal nodes, vasculature, and pericardium (47). Shiba et al. referenced metastasis, though the location was not described (48). Itano et al. described pulmonary and intraperitoneal metastasis (45). To our knowledge, there have been no reports describing bony metastases in this histological sub-type and hence we

believe this is the first description of combined sarcomatoid and desmoplastic mesothelioma with osteosarcomatous differentiation metastasizing in this way.

MPM is a rare tumour of the pleura. Although commonly viewed as a locally invasive tumour, distant metastases are possible, but rare. We have described the first case of combined sarcomatoid and desmoplastic MPM with osteosarcomatous differentiation metastasizing to bone. This case also highlights the diagnostic challenges of mesothelioma, particularly in differentiating malignancy from fibrinous pleuritis. Employing modern immunohistochemistry assessing for BAP-1 protein loss and FISH for homozygous deletion of *CDKN2A* can be invaluable and may avoid unnecessary invasive investigations.

### Disclosure Statement

Appropriate written informed consent was obtained for publication of this case report and accompanying images.

### Acknowledgements

This report would not have been possible without the significant input from a number of individuals and organizations. In particular we acknowledge the significant work from Professor Gelareh Farshid and the Department of Anatomical Pathology at SA Pathology in South Australia.

### References

- Soeberg MJ, Leigh J, and van Zandwijk N. 2016. Malignant mesothelioma in Australia 2015: current incidence and asbestos exposure trends. *J. Toxicol. Environ. Health B Crit. Rev.* 19:173–189.
- McDonald JC, and McDonald AD. 1996. The epidemiology of mesothelioma in historical context. *Eur. Respir. J.* 9: 1932–1942.
- Travis WD, Brambilla E, Nicholson AG, et al. 2015. The 2015 World Health Organization classification of lung tumors. *J. Thorac. Oncol.* 10:1243–1260.
- Rusch VW, Giroux D, Kennedy C, et al. 2012. Initial analysis of the international association for the study of lung cancer mesothelioma database. *J. Thorac. Oncol.* 7:1631–1639.
- Klebe S, Brownlee NA, Mahar A, et al. 2010. Sarcomatoid mesothelioma: a clinical-pathologic correlation of 326 cases. *Modern Pathol* 23:470–479.
- Cantin R, Al-Jabi M, and McCaughey WT. 1982. Desmoplastic diffuse mesothelioma. *Am. J. Surg. Pathol.* 6: 215–222.
- Sanjeevan M, Helman A, Peter F, et al. 2017. Comparison of outcomes following a cytological or histological diagnosis of malignant mesothelioma. *Br. J. Cancer* 116:703–708.
- Hjerpe A, Abd-Own S, and Dobra K. 2018. Cytopathologic diagnosis of epithelioid and mixed-type malignant mesothelioma: ten years of clinical experience in relation to international guidelines. *Arch. Pathol. Lab. Med.* 142: 893–901.
- Segal A, Sterrett GF, Frost FA, et al. 2013. A diagnosis of malignant pleural mesothelioma can be made by effusion cytology: results of a 20 year audit. *Pathology* 45:44–48.
- Galateau-Salle F, Churg A, Roggli V, et al. 2016. The 2015 World Health Organization classification of tumors of the pleura: advances since the 2004 classification. *J. Thorac. Oncol.* 11:142–154.
- Husain AN, Colby TV, Ordóñez NG, et al. 2018. Guidelines for pathologic diagnosis of malignant mesothelioma 2017 update of the consensus statement from the International Mesothelioma Interest Group. *Arch. Pathol. Lab. Med.* 142:89–108.
- Hida T, Hamasaki M, Matsumoto S, et al. 2016. BAP1 immunohistochemistry and p16 FISH results in combination provide higher confidence in malignant pleural mesothelioma diagnosis: ROC analysis of the two tests. *Pathol. Int.* 66:563–570.
- Louw A, Badiei A, Creaney J, et al. 2019. Advances in pathological diagnosis of mesothelioma: what pulmonologists should know. *Curr. Opin. Pulm. Med.* 25:354–361.
- Liu J, Liao X, Gu Y, et al. 2018. Role of p16 deletion and BAP1 loss in the diagnosis of malignant mesothelioma. *J. Thorac. Dis.* 10:5522–5530.
- Sheffield BS, Hwang HC, Lee AF, et al. 2015. BAP1 immunohistochemistry and p16 FISH to separate benign from malignant mesothelial proliferations. *Am. J. Surg. Pathol.* 39:977–982.
- Wu D, Hiroshima K, Matsumoto S, et al. 2013. Diagnostic usefulness of p16/CDKN2A FISH in distinguishing between sarcomatoid mesothelioma and fibrous pleuritis. *Am. J. Clin. Pathol.* 139:39–46.
- Chai SM, and Vliet C. 2017. Cytological diagnosis of malignant pleural mesothelioma. *Curr. Pulmonol. Rep.* 6:1–8.
- Monaco S, Mehrad M, and Dacic S. 2018. Recent advances in the diagnosis of malignant mesothelioma: focus on approach in challenging cases and in limited tissue and cytological samples. *Adv Anat Pathol* 25:24–30.
- Hwang HC, Pyott S, Rodriguez S, et al. 2016. BAP1 Immunohistochemistry and p16 FISH in the Diagnosis of Sarcomatous and Desmoplastic Mesotheliomas. *Am. J. Surg. Pathol.* 40:714–718.
- Finn RS, Brims FJH, Gandhi A, et al. 2012. Postmortem findings of malignant pleural mesothelioma: a two-center study of 318 patients. *Chest* 142:1267–1273.
- Brenner J, Sordillo PP, Magill GB, et al. 1982. Malignant mesothelioma of the pleura: review of 123 patients. *Cancer* 49:2431–2435.
- Muller CS, Reichrath J, and Tilgen W. 2009. Disseminated cutaneous metastasis of a biphasic pleural mesothelioma. *J. Eur. Acad. Dermatol. Venereol.* 23:226–227.
- Shield PW, and Ribu DL. 2017. Metastatic pleural mesothelioma presenting in a breast fine needle aspiration specimen. *Cytopathology* 28:429–431.

24. Liu H, Cheng YJ, Chen HP, et al. 2010. Multiple bowel intussusceptions from metastatic localized malignant pleural mesothelioma: a case report. *World J. Gastroenterol.* 16: 3984–3986.
25. Bille A, Platania M, Pelosi G, et al. 2014. Gingival metastasis as first sign of multiorgan dissemination of epithelioid malignant mesothelioma. *J. Thorac. Oncol.* 9: 1226–1229.
26. Petrovic BD, Kozic DB, Semnic RR, et al. 2004. Leptomeningeal metastasis from malignant pleural mesothelioma. *AJNR Am. J. Neuroradiol.* 25:1223–1224.
27. Ihara H, Harada N, Shimada N, et al. 2018. Malignant pleural mesothelioma with bone marrow metastases. *Intern. Med.* 57:2541–2545.
28. Arslan A, Ozcakir-Tomruk C, Deniz E, et al. 2016. A case report of metastasis of malignant mesothelioma to the retromolar trigone. *World J. Surg. Oncol.* 14:188.
29. Knipscheer BJ, Kromontono RCR, de Bruin PC, et al. 2013. Two malignancies or an unusual presentation of a pleural malignancy? *Lung Cancer* 81:306–307.
30. Lester T, and Xu H. 2008. Malignant pleural mesothelioma with osseous metastases and pathologic fracture of femoral neck. *Appl. Immunohistochem. Mol. Morphol.* 16:507–509.
31. Terakado N, Shintani S, Nakashiro K, et al. 2004. Malignant pleural mesothelioma metastasis to the mandible. *Int. J. Oral Maxillofac. Surg.* 33:798–800.
32. Swayne LC, Hediger RG, and Wolff M. 1992. Bone scan detection of pelvic metastasis from pleural mesothelioma. *Clin. Nucl. Med.* 17:965–966.
33. Cheng WF, and Berkman AW. 1990. Malignant mesothelioma with bone metastases. *Med. Pediatr. Oncol.* 18:165–168.
34. Machin T, Mashiyama ET, Henderson JA, et al. 1988. Bony metastases in desmoplastic pleural mesothelioma. *Thorax* 43:155–156.
35. Cedrés S, Fariñas L, Stejpanovic N, et al. 2013. Bone metastases with nerve root compression as a late complication in patient with epithelial pleural mesothelioma. *J. Thorac. Dis.* 5:E35–E37.
36. Laurini RN. 1974. Diffuse pleural mesothelioma with distant bone metastasis. *Acta Pathol. Microbiol. Immunol. Scand. A* 82:296–298.
37. Hirano H, Maeda H, Sawabata N, et al. 2003. Desmoplastic malignant mesothelioma: two cases and a literature review. *Med. Electron Microsc.* 36:173–178.
38. Ishikawa R, Kikuchi E, Jin M, et al. 2003. Desmoplastic malignant mesothelioma of the pleura: autopsy reveals asbestos exposure. *Pathol. Int.* 53:401–406.
39. Hayashi H, Notohara K, Yoshioka H, et al. 2010. Localized malignant pleural mesothelioma showing a thoracic mass and metastasizing to the stomach. *Intern. Med.* 49:671–675.
40. Huang Y-C, Tu D-G, Wu J-D, et al. 2009. Malignant pleural mesothelioma presenting as low back pain: diagnosed by bone scan coordinating with F-18 FDG PET/CT. *Spine* 34:E780–E783.
41. Singh N, Madan K, Bhattacharya A, et al. 2013. Malignant pleural mesothelioma in a patient with systemic sclerosis: the first report. *Respiration* 85:66–71.
42. Moskowitz A, Vanderlaan P, Anandaiah A, et al. 2016. D46 CASE reports in environmental and occupational health: metastatic desmoplastic mesothelioma presenting with bone pain and diplopia. *Am. J. Respir. Crit. Care Med.* 193:1–2.
43. Klebe S, Mahar A, Henderson DW, et al. 2008. Malignant mesothelioma with heterologous elements: clinicopathological correlation of 27 cases and literature review. *Modern Pathol.* 21:1084–1094.
44. Yousem SA, and Hochholzer L. 1987. Malignant mesotheliomas with osseous and cartilaginous differentiation. *Arch. Pathol. Lab. Med.* 111:62–66.
45. Itano H, Takeda T, Yamada T, et al. 2020. Heterologous sarcomatoid pleural mesothelioma with osteosarcomatous differentiation: a report of autopsy case that accomplished trimodality therapy and review of the literature. *Gen. Thorac. Cardiovasc. Surg.* 68:871–879.
46. Goldstein B. 1979. Two malignant pleural mesotheliomas with unusual histological features. *Thorax* 34:375–379.
47. Salgado RA, Corthouts R, Parizel PM, et al. 2005. Malignant pleural mesothelioma with heterologous osteoblastic elements: computed tomography, magnetic resonance, and positron emission tomography imaging characteristics of a rare tumor. *J. Comput. Assist. Tomogr.* 29:653–656.
48. Shiba N, Kusumoto M, Tsuta K, et al. 2011. A case of malignant pleural mesothelioma with osseous and cartilaginous differentiation. *J. Thorac. Imaging* 26:W30–W32.