

Bronchus-Associated Lymphoid Tissue (BALT) Lymphoma of the Lung Showing Mosaic Pattern of Inhomogeneous Attenuation on Thin-section CT: A Case Report

In-Jae Lee, MD¹
Sung Hwan Kim, MD¹
Soo Hyun Koo, MD¹
Hyun Beom Kim, MD¹
Dae Hyun Hwang, MD¹
Kwan Seop Lee, MD¹
Yul Lee, MD¹
Kee Taek Jang, MD²
Duck-Hwan Kim, MD²

The authors present a case of histologically proven bronchus-associated lymphoid tissue (BALT) lymphoma of the lung in a patient with primary Sjögren's syndrome that manifested on thin-section CT scan as a mosaic pattern of inhomogeneous attenuation due to mixed small airway and infiltrative abnormalities

P rimary malignant lymphoma of the lung may develop from bronchus-associated lymphoid tissue (BALT) (1, 2). Previously reported computed tomographic (CT) features of BALT lymphoma are the presence of consolidation or nodules in the lungs (1-5). To our knowledge, however, there has been no report of BALT lymphoma which manifested on CT as a mosaic pattern of inhomogeneous attenuation. The purpose of this report is to present a case of BALT lymphoma which on thin-section CT scan manifested as a mosaic pattern of inhomogeneous attenuation, and to correlate these findings with the histological findings.

CASE REPORT

A 33-year-old housewife with primary Sjögren's syndrome was admitted for the evaluation of dyspnea and general weakness which had persisted for two years. The patient claimed to have no history of smoking, allergies or occupational exposure to noxious agents. Physical examination revealed coarse breathing sounds with inspiratory crackle extending over the whole of the both lung fields. However, the results of blood analysis were normal.

Chest radiographs demonstrated the presence of bilateral, diffuse, reticulonodular densities in both lungs (Fig. 1A). Thin-section CT scan showed diffusely distributed mosaic pattern of inhomogeneous attenuation extending over the entirety of lung zones, without zonal predominance. There was no difference in the extent of mosaic attenuation between inspiratory (Fig. 1B) and expiratory thin-section CT scans (Fig. 1C). As compared with more highly attenuated areas of the lung, however, the caliber and number of pulmonary vessels in areas of the lower attenuation were reduced. There were several foci of bronchial wall thickening, and these were more frequently found in areas of lower attenuation. In the right lower paratracheal area and subcarinal area, the presence of several small lymph nodes less than 1 cm in short axis diameter was noted.

Flexible fiberoptic bronchoscopy revealed no remarkable finding, though transbronchial multiple biopsies obtained from the right anterior segmental bronchus showed some lymphocytic infiltration. Cytologic analysis showed that the composition of bronchoalveolar lavage fluid was 45% lymphocytes, 1% eosinophils, and 54% macrophages. Open lung biopsy was performed in areas of both higher and lower at-

Index words:

Lung, diseases
Lung neoplasms, CT
Lymphoma, CT

Korean J Radiol 2000; 1: 159-161

Received March 14, 2000; accepted after revision July 18, 2000.

Departments of ¹Radiology and ²Pathology, Hallym University Sacred Heart Hospital.

Address reprint requests to:

In-Jae Lee, MD, Department of Radiology, Hallym University Sacred Heart Hospital, 896 Pyungchon-dong, Anyang-city, Kyungki-do 431-070, Korea.
Telephone: (8231) 380-3885
Fax: (8231) 380-3878
e-mail: ijlee@www.hallym.or.kr

tenuation. Histologic examination disclosed focal collections of lymphoid cells around bronchioles and extension of lymphoma cells from bronchiolar epithelium toward alveolar space. Immunocytochemically, the neoplastic cells reacted positively for CD 20 antigen and were focally positive for UCHL 1 antigen. Monoclonal antibody against cytokeratin indicated multiple lymphoepithelial lesions. The histologic diagnosis was consistent with low grade marginal zone B-cell lymphoma originating in BALT.

DISCUSSION

Primary malignant non-Hodgkin's lymphomas arising in mucosa-associated lymphoid tissue (MALT) develop most frequently in the stomach, but also in the bowel, salivary glands, larynx, thyroid gland, and lung (1, 2). Accordingly, when located in the lung, this lymphoma appears to arise from bronchus-associated lymphoid tissue (BALT) (1, 2).

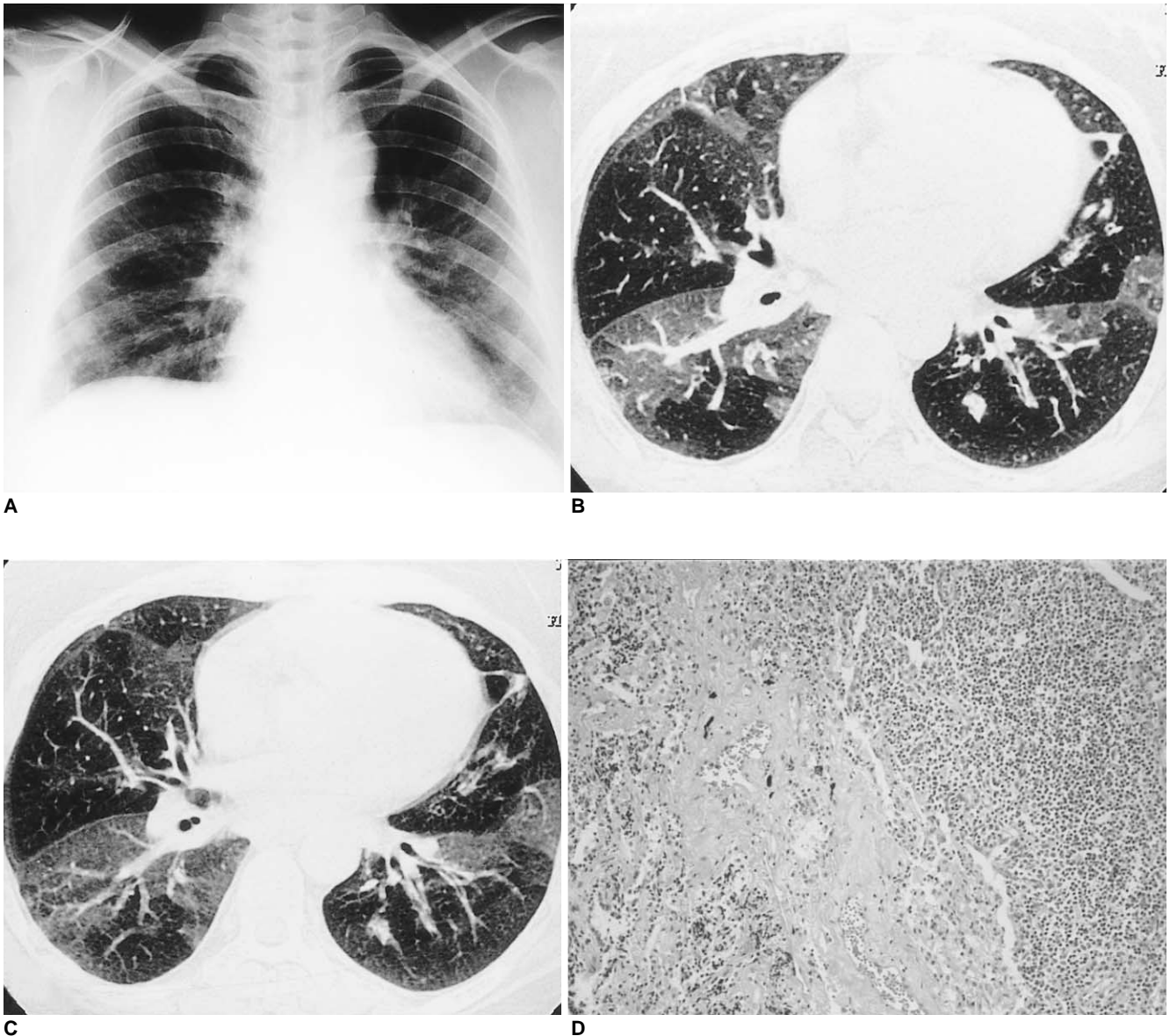


Fig. 1. BALT lymphoma of the lung in a 33-year-old housewife with primary Sjögren's syndrome.
A. Posterior-anterior chest radiograph shows diffuse reticulonodular densities in both lungs.
B. Inspiratory thin-section CT scan shows mosaic pattern of inhomogeneous attenuation. Note the smaller caliber of pulmonary vessels within the area of lower attenuation than within the higher. Note too the presence of bronchial wall thickening in the lingular division of the upper lobe of the left lung.
C. Expiratory thin-section CT scan shows no difference in the extent of mosaic pattern of inhomogeneous attenuation.
D. Light microscopic examination of resected specimen shows diffuse infiltration of marginal zone lymphocytes into peribronchiolar alveolar space (H and E, $\times 100$).

BALT lymphoma represents a low-grade B-lymphocyte lymphoma composed of monotonous small lymphocytes with focal plasmacytoid features (6). Since lymphomas at this site tend to be localized until late in the course of the disease, prognosis is considerably better than for nodal tumors of similar histologic grade (6).

Meanwhile, lymphoid infiltration of extranodal sites is a prominent feature of Sjögren's syndrome, and lymphoid proliferation in the respiratory system may take various forms: lymphocytic bronchitis and bronchiolitis, lymphocytic interstitial pneumonitis, pseudolymphoma, or malignant lymphoma (7, 8). Moreover, the risk of occurrence of lymphoma is much greater in such patients than in the general population (7). MALT lymphomas are also known to be associated with Sjögren's syndrome, AIDS, dysgammaglobulinemia, and collagen vascular diseases (1).

Previously reported CT features of BALT lymphoma are the presence of consolidation with poorly defined margins and air bronchograms (1, 4, 5). Other findings include nodules, diffuse bilateral air space consolidation, and segmental or lobar atelectasis (1-5). Pulmonary lymphoma associated with Sjögren's syndrome may appear as a diffuse interstitial process or as multiple nodular infiltrates (8). To our knowledge, however, BALT lymphoma manifesting on thin-section CT scan as a mosaic pattern of inhomogeneous attenuation has not been reported.

A mosaic pattern of inhomogeneous attenuation is non-specific and may be seen on thin-section CT scans of the lungs when various airway, vascular, or infiltrative lung diseases are present (9, 10). In cases of infiltrative lung disease, the mosaic pattern of inhomogeneous attenuation results from patchy areas of ground-glass attenuation and interposed normal lung parenchyma (9). Moreover, the size of vessels within the areas of ground-glass attenuation is usually similar to that seen in uninvolved lung, permitting distinction from airway or vascular diseases (9, 10). In cases involving such diseases, however, areas of increased attenuation have relatively large vessels, while areas of decreased attenuation have small vessels (9, 10). In cases of airway disease, the mosaic pattern of inhomogeneous attenuation results from reflex vasoconstriction secondary to hypoventilation of alveoli distal to airway obstruction and blood flow redistribution to adjacent normal areas of the lung (9). Moreover, bronchial dilatation and air trapping in abnormal lung may exist in cases of airway disease (9, 10). Though air trapping might not be present in cases of infiltrative or vascular lung disease (10).

In this case, the histologic diagnosis of the area of higher attenuation was low grade marginal zone B-cell lymphoma of BALT. Extension of lymphoma cells from bronchiolar epithelium toward alveolar space was noted, and bronchio-

lar lymphoepithelial lesion and infiltration of lymphoma cells within this space thus contributed to the increased attenuation of the lesion. There was, moreover, no difference in the extent of mosaic pattern of inhomogeneous attenuation between inspiratory and expiratory thin-section CT scan. Meanwhile, the histologic finding in the area of lower attenuation was focal collections of lymphoid cells around bronchioles. As compared with areas of higher attenuation, the caliber and number of pulmonary vessels in those of lower attenuation were reduced, being more pronounced on CT scan obtained at suspended full expiration. There were several foci of bronchial wall thickening, and these were more frequently found in areas of lower attenuation. The mechanism of airway disease causing mosaic pattern of inhomogeneous attenuation thus contributed to the decreased attenuation of the lesion. BALT lymphoma may, therefore, manifest on thin-section CT scan as a mosaic pattern of inhomogeneous attenuation. This is due to both small airway and infiltrative disease, as in cases of hypersensitivity pneumonitis.

References

1. Lee DK, Im J-G, Lee KS, et al. B-cell lymphoma of bronchus-associated lymphoid tissue (BALT): CT features in 10 patients. *J Comput Assist Tomogr* 2000;24:30-34
2. O'Donnell PG, Jackson SA, Tung KT, Hassan B, Wilkins B, Mead GM. Radiological appearance of lymphomas arising from mucosa-associated lymphoid tissue (MALT) in the lung. *Clin Radiol* 1998;53:258-263
3. Knisely BL, Mastey LA, Mergo PJ, et al. Pulmonary mucosa-associated lymphoid tissue lymphoma: CT and pathologic findings. *AJR* 1999;172:1321-1326
4. Wislez M, Cadranet J, Antoine M, et al. Lymphoma of pulmonary mucosa-associated lymphoid tissue: CT scan findings and pathological correlations. *Eur Respir J* 1999;14:423-429
5. McCulloch GL, Sinnatamby R, Stewart S, Goddard M, Flower CDR. High-resolution computed tomographic appearance of MALToma of the lung. *Eur Radiol* 1998;8:1669-1673
6. Chow WH, Ducheine Y, Hilfer J, Brandstetter RD. Chronic pneumonia. Primary malignant non-Hodgkin's lymphoma of the lung arising in mucosa-associated lymphoid tissue. *Chest* 1996;110:838-840
7. Franquet T, Gimenez A, Monill JM, Diaz C, Geli C. Primary Sjögren's syndrome and associated lung disease: CT findings in 50 patients. *AJR* 1997;169:655-658
8. Hansen LA, Parkash UBS, Colby TV. Pulmonary lymphoma in Sjögren's syndrome. *Mayo Clin Proc* 1989;64:920-931
9. Worthy SA, Müller NL, Hartman TE, Swensen SJ, Padley SPG, Hansell DM. Mosaic attenuation pattern on thin-section CT scans of the lung: differentiation among infiltrative lung, airway, and vascular disease as a cause. *Radiology* 1997;205:465-470
10. Shah RM, Sexauer W, Ostrum BJ, et al. High-resolution CT in the acute exacerbation of cystic fibrosis: evaluation of acute findings, reversibility of those findings, and clinical correlation. *AJR Am J Roentgenol* 1997;169:375-380