



# Computational analysis in epilepsy neuroimaging: A survey of features and methods



Lohith G. Kini<sup>a,\*</sup>, James C. Gee<sup>b,1</sup>, Brian Litt<sup>a,c,1</sup>

<sup>a</sup>Department of Bioengineering, University of Pennsylvania, 240 Skirkanich Hall, 210 South 33rd Street, Philadelphia, PA 19104-6321, USA

<sup>b</sup>Department of Radiology, Hospital of the University of Pennsylvania, Richards - 6th Floor, 3700 Hamilton Walk, Philadelphia, PA 19104-6116, USA

<sup>c</sup>Department of Neurology, Hospital of the University of Pennsylvania, 3400 Spruce Street, 3 West Gates Bldg, Philadelphia, PA 19104, USA

## ARTICLE INFO

### Article history:

Received 10 December 2015

Received in revised form 11 February 2016

Accepted 22 February 2016

Available online 23 February 2016

### Keywords:

Multimodal neuroimaging

Epilepsy

Drug resistant epilepsy

Focal cortical dysplasia

Malformations of cortical development

Machine learning

## ABSTRACT

Epilepsy affects 65 million people worldwide, a third of whom have seizures that are resistant to anti-epileptic medications. Some of these patients may be amenable to surgical therapy or treatment with implantable devices, but this usually requires delineation of discrete structural or functional lesion(s), which is challenging in a large percentage of these patients.

Advances in neuroimaging and machine learning allow semi-automated detection of malformations of cortical development (MCDs), a common cause of drug resistant epilepsy. A frequently asked question in the field is what techniques currently exist to assist radiologists in identifying these lesions, especially subtle forms of MCDs such as focal cortical dysplasia (FCD) Type I and low grade glial tumors. Below we introduce some of the common lesions encountered in patients with epilepsy and the common imaging findings that radiologists look for in these patients. We then review and discuss the computational techniques introduced over the past 10 years for quantifying and automatically detecting these imaging findings. Due to large variations in the accuracy and implementation of these studies, specific techniques are traditionally used at individual centers, often guided by local expertise, as well as selection bias introduced by the varying prevalence of specific patient populations in different epilepsy centers. We discuss the need for a multi-institutional study that combines features from different imaging modalities as well as computational techniques to definitively assess the utility of specific automated approaches to epilepsy imaging. We conclude that sharing and comparing these different computational techniques through a common data platform provides an opportunity to rigorously test and compare the accuracy of these tools across different patient populations and geographical locations. We propose that these kinds of tools, quantitative imaging analysis methods and open data platforms for aggregating and sharing data and algorithms, can play a vital role in reducing the cost of care, the risks of invasive treatments, and improve overall outcomes for patients with epilepsy.

© 2016 The Authors. Published by Elsevier Inc. This is an open access article under the CC BY-NC-ND license (<http://creativecommons.org/licenses/by-nc-nd/4.0/>).

## Contents

1. Introduction . . . . .	516
1.1. Malformations of cortical development. . . . .	516
2. What are features radiologists look for in imaging? . . . . .	517
2.1. T1W/T2W imaging. . . . .	517
2.2. Electrophysiology . . . . .	519
2.3. PET imaging . . . . .	519
2.4. Cerebral blood flow imaging . . . . .	519
2.5. Diffusion imaging . . . . .	519

**Abbreviations:** FCD, focal cortical dysplasia; GM, gray matter; WM, white matter; T1W, T1-weighted MRI; T2W, T2-weighted MRI; DRE, drug resistant epilepsy; FLAIR, fluid-attenuated inversion recovery; VBM, voxel-based morphometry; SBM, surface-based morphometry; DWI, diffusion weighted imaging; DTI, diffusion tensor imaging; PET, positron emission tomography; GW, gray-white junction; HARDI, high angular resolution diffusion imaging; MEG, magnetoencephalography; MRS, magnetic resonance spectroscopy imaging; PNH, periventricular nodular heterotopia.

\* Corresponding author.

E-mail addresses: [lkini@mail.med.upenn.edu](mailto:lkini@mail.med.upenn.edu) (L.G. Kini), [gee@mail.med.upenn.edu](mailto:gee@mail.med.upenn.edu) (J.C. Gee), [littb@mail.med.upenn.edu](mailto:littb@mail.med.upenn.edu) (B. Litt).

<sup>1</sup> Co-senior authors.

2.6.	Functional imaging using MRI and EEG . . . . .	519
2.7.	Network analysis using functional (fMRI/EEG/MEG) and structural imaging (DTI). . . . .	520
2.8.	Other modalities: CEST/MTI/MRS. . . . .	520
2.9.	Summary . . . . .	520
3.	How are features computed by machine? . . . . .	520
3.1.	Signal intensity change and subcortical presence of abnormal gray matter . . . . .	520
3.2.	Increased cortical thickness . . . . .	521
3.3.	Gray-white junction blurring . . . . .	521
3.4.	Sulcal and gyral abnormalities . . . . .	522
3.5.	Diffuse/multifocal hyperintensities . . . . .	522
3.6.	Summary . . . . .	522
4.	How well can computational analysis identify lesions based on these features? . . . . .	522
4.1.	Segmentation . . . . .	522
4.2.	Supervised learning. . . . .	522
4.3.	Recent computational models . . . . .	523
4.4.	Summary . . . . .	523
5.	Discussion . . . . .	524
5.1.	Multi-centric data-sharing platform . . . . .	524
5.2.	Feature selection . . . . .	525
5.3.	Gaps in knowledge of pathophysiologic mechanisms. . . . .	525
5.4.	Imaging technique challenges . . . . .	525
5.5.	Next steps: gold standard metrics for lesion localization and quantification. . . . .	525
5.6.	Next steps: make computational pipelines available to clinicians . . . . .	526
5.7.	Summary . . . . .	526
	Acknowledgments . . . . .	526
	References. . . . .	526

## 1. Introduction

Epilepsy affects 65 million people in the world and has been estimated to cost the US upwards of \$12.5 billion annually, based on a 1995 epidemiology study (Schachter, 2015; Kwan et al., 2011; Begley et al., 2000). Patients with drug resistant epilepsy (DRE) account for only 20–40% of patients with epilepsy but contribute a large portion of the epilepsy-associated cost due to risk of premature death, seizure-related injuries, psychosocial dysfunction and general reduction in quality of life measures (Kwan et al., 2011).

Resective surgical therapy has been the mainstay of therapy, but surgical candidacy depends on the clinical team's ability to identify and fully delineate structural and functional lesions, such as regions of dysplastic cortex. Overall, the odds of seizure freedom after surgery for epilepsy are 2–3 times higher in cases that exhibit an identifiable lesion on histopathology or MRI (Télez-Zenteno et al., 2010). Thus, the overall goal of neuroimaging in epilepsy is to monitor therapy and identify biomarkers of disease, candidates for surgery, and predictors of post-surgical outcomes (Bernasconi and Bernasconi, 2014).

Currently, the gold standard for outlining lesions in epilepsy patients is through identifying the epileptogenic zone, defined as the region recruited to seize on EEG, either measured on the scalp or in conjunction with invasive intracranial monitoring utilizing subdural strips, grids, depth or stereo EEG electrodes (Najm et al., 2002). The irritative zone is defined as the region near the structural or functional lesion that generates interictal epileptiform discharges identified by ECoG and fMRI (Koepp and Woermann, 2005). In these cases, the location of the epileptogenic zone, determined by electrophysiology, is compared with the irritative zone, determined by possible lesions discovered on imaging, to guide therapy. A majority of these are caused by malformations of cortical development.

### 1.1. Malformations of cortical development

Malformations of cortical development (MCD), which describe a variety of structural and metabolic abnormalities of brain arising during gestation, were traditionally thought to cause a significant proportion of epilepsy (~15%) (Sisodiya, 2000; Lerner et al., 2009). Some lesions

remain undetected, even at high resolution MRI, and are only discovered on histopathology after resective surgery (Sisodiya, 2000). As a result, previous estimates of the incidence of MCD have been low, and now at least 25% of all cases are thought to be due to MCD lesions. Histopathology of resected lesions show that these are mostly focal cortical dysplasias (45%), gliosis (22%), and hippocampal sclerosis (13%) (Wang et al., 2013).

Table 1 shows the distribution of malformations of cortical development and their incidence. Few studies have looked at the incidence of the different possible malformations, but focal cortical dysplasias is considered to account for the majority of the cases (Wang et al., 2013; Raymond et al., 1995). Focal cortical dysplasias (FCD) are a

**Table 1**

Incidence of different malformations of cortical development organized by groupings (Barkovich et al., 2012). Group 1 includes malformations due to abnormal cell proliferation, Group 2 includes malformations due to abnormal cell proliferation, and Group 3 includes malformations due to abnormal cortical organization. These incidence data are adapted from Papayannis et al. (2012).

Group I (49%)	
Focal cortical dysplasia (Type I and II)	48%
Focal cortical dysplasia + glioneural tumors	14%
Dual or triple pathology: focal cortical dysplasia + tumors + hippocampal sclerosis	14%
Glioneural tumors	10%
Tuberous sclerosis	10%
Hemimegalencephaly	1%
Focal hemimegalencephaly versus possible focal cortical dysplasia	3%
Group II (40%)	
Periventricular nodular heterotopia	55%
Subcortical heterotopia	18%
Mixed forms of heterotopia	10%
Dual pathology: periventricular nodular heterotopia + hippocampal sclerosis	13%
Double cortex or subcortical band heterotopia	5%
Group III (11%)	
Schizencephaly	37%
Polymicrogyria (bilateral)	26%
Polymicrogyria (unilateral)	37%

heterogeneous group of disorders that have been classified in three tiers: FCD type I, FCD type II and FCD type III. FCD type I is caused by abnormal neuronal migration, FCD type II is caused by abnormal neural proliferation or apoptosis, and FCD type III are dysplasias associated with hippocampal sclerosis, vascular malformations (1–2%), tumors (10%) and other principal lesions (Barkovich et al., 2012; Jackson and Badawy, 2011). These tiers are listed in order of how readily they are visualized on imaging. For instance, FCD type II, which histopathologically resemble tuberous sclerosis lesions (Kumar et al., 2011), are more easily visible on conventional MRI imaging compared to the milder FCD type I (Krsek et al., 2008). T1-weighted imaging (T1WI) is abnormal in FCD type II showing altered cortical thickness and gray-white junction blurring. Fig. 1 shows an example MRI from a patient with type II FCD. For the other types of FCDs, structural MRI is insufficient to diagnose a substantial proportion cortical dysplasias, particularly those associated with FCD type I (Hauptman and Mathern, 2012). Even within FCD type II, MRI features may be insufficient to detect more specific histopathological subforms, such as FCD type IIA (Colombo et al., 2012). This makes delineating these lesions difficult.

There is strong evidence suggesting that patients with a focal lesion on MRI have a better outcome after epilepsy surgery compared to patients with no abnormal findings on MRI. When complete resections are performed on patients with cortical dysplasias, 80% of the patients become seizure-free compared to 20–50% in patients with incomplete resections performed due to lack of imaging findings or involvement of eloquent cortex (Lerner et al., 2009). The key to reducing the extent of resection while optimizing clinical outcomes, including minimizing side effects of surgery, is accurately mapping the brain region to be resected and minimizing the resection of eloquent or uninvolved regions (Okonma et al., 2011). A different set of studies of patients with FCDs and low grade neuroglial tumors showed that determining the extent of the lesion is important, since its complete removal correlates with good surgical outcome (83% seizure-free (Engel class I) outcome) (Chassoux and Daumas-Duport, 2013; Cossu et al., 2013; Rowland et al., 2012). This target region for resection can be defined by electrocorticography findings, neuroimaging & computational identification of abnormalities (Begley et al., 2000), histology and (Télez-Zenteno et al., 2010) metabolic imaging in cases where structural imaging is normal (Okonma et al., 2011). Function of these targets can be difficult to assess a-priori. Patient risk of deficits from surgery is minimized by electrical stimulation testing, functional imaging, and advanced structural imaging (such as HARDI-DTI) though these techniques may not adequately image fibers of passage through the zone of resection (Okonma et al., 2011). Thus, it is important for current

imaging and computational techniques to identify, assess and delineate epileptogenic lesions.

Despite recent improvements in imaging technology and computational methods (Madan and Grant, 2009), the ability to detect focal lesions has significant room for improvement. MRI findings are abnormal in only 50–70% of patients with MCD. Some modalities such as PET imaging become sensitive only when fused with MRI (Lerner et al., 2009). In addition, re-examination of MRI images demonstrated lesions that were missed during initial interpretation in some cases. This highlights the urgent need for advances in imaging and computational techniques that can detect subtle epileptic pathologies in MRI-negative epilepsies (Rosenow and Lüders, 2001). Standard clinical imaging protocol is limited in its efficacy.

In the next two sections, we discuss important radiological features and the latest computational techniques used to identify and delineate lesions in patients with epilepsy.

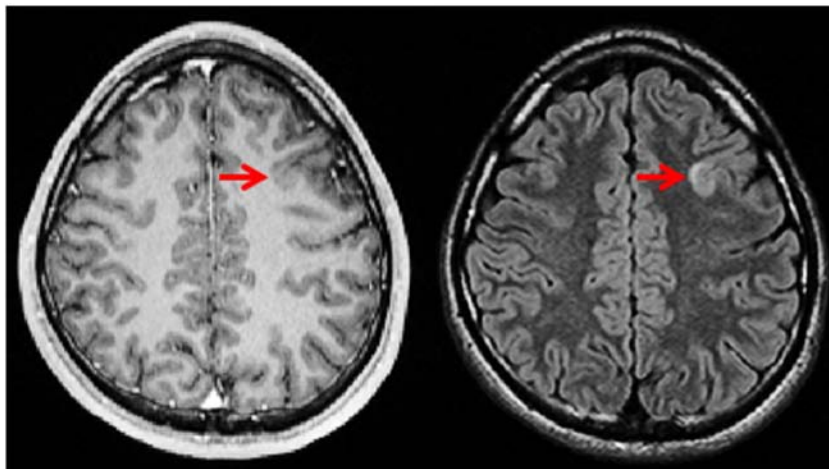
## 2. What are features radiologists look for in imaging?

Neuroradiologists look for certain distinct image biomarkers in order to diagnose the focal lesion contributing to a patient's refractory epilepsy. Most epilepsy centers use an imaging protocol, typically involving fluid attenuated inversion recovery (FLAIR), T2W, T1W, and hemosiderin/calcification-sensitive sequences. The T1W image should be acquired in three-dimensional technique at 1 mm isotropic voxels size. For T2W and FLAIR, at least two slice orientations are needed to image at an angulation perpendicular to the long axis of the hippocampus (Wellmer et al., 2013). Slice thickness for T2W and FLAIR must not exceed 3 mm in order to best visualize this angulation. In addition, some institutions use different imaging modalities such as FDG-PET, SPECT of ictal-interictal cerebral blood flow (SISCOM), and MEG to isolate the focus of the seizure. Higher field imaging can also improve detection of key image findings in MCD (Mellerio et al., 2014a). This section gives an overview of these different imaging modalities and image used in the diagnosis of MCD.

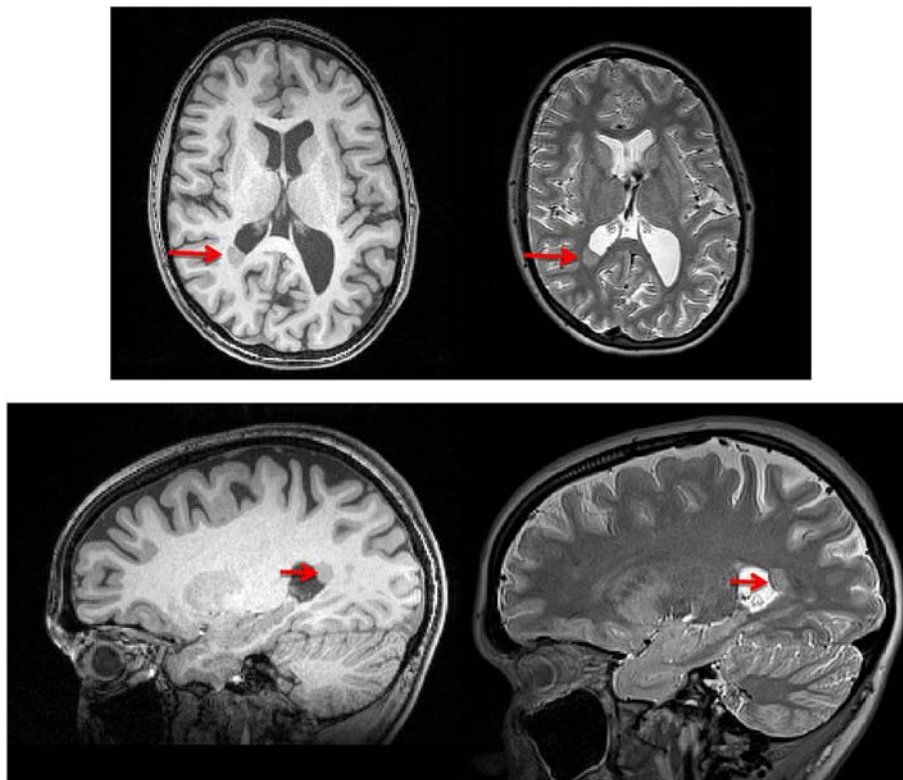
### 2.1. T1W/T2W imaging

Neuroradiologists look for the following common findings to assist them in the diagnosis of MCD in epilepsy patients:

- Abnormal signal hyperintensity/hypointensity
- Subcortical presence of abnormal gray matter (see Fig. 2)
- Increased cortical thickness/pseudo-thickness
- Gray-white junction blurring



**Fig. 1.** Sample T1-weighted (left) and T2-weighted (right) axial MRI images taken from a 21-year old male epilepsy patient. The focal cortical dysplasia (red arrows) present as loss of gray-white contrast on T1-weighted imaging as well as a hyperintensity on T2-weighted imaging.



**Fig. 2.** Sample T1-weighted (left) and T2-weighted (right) axial and sagittal images taken from a patient with a smaller right hemisphere and periventricular nodular heterotopia (red arrow). Note that the heterotopia is located on the temporal horn and has subcortical abnormal gray matter in areas where usually only white matter is found.

- Sulcal abnormalities such as increased sulcal depth
- Structural/lobar atrophy – this includes hippocampal sclerosis and atrophy
- Abnormal gyrification pattern
- Abnormal asymmetry in structural patterns
- Diffuse or multifocal occurrence of any of the above features

In MRI images of patients with cortical dysplasia, 60% will show thickening or pseudo-thickening of gray matter, 74% will show blurring of the gray-white junction, 63% will have increased T2W signal in white matter, 19% will have structural atrophy visible, and 34% will have other signal changes (Lerner et al., 2009). These changes include the transmantle sign, which is a hyperintensity (on T2-weighted images) of subcortical white matter often tapering towards the ventricle (Colombo et al., 2003). These features occur together and make the lesion more visible. A combination of cortical thickening, gray-white junction blur, and transmantle sign were found in 64% of patients with FCD type II (Mellerio et al., 2012). In fact, there is a significant association between the presence of cortical thickening ( $p = 0.002$ ) and the “transmantle sign” ( $p < 0.001$ ) and a correct MRI diagnosis (Colombo et al., 2012).

FCD type I lesions, on the other hand, tend to have regional reduction of the white matter (Krsek et al., 2009). For instance, lobar hypoplasia/atrophy are reported to be most frequent (Freeman et al., 2004). Mild blurring at the GM (gray matter)/WM (white matter) junction with normal cortical thickness and abnormal gyral/sulcal patterns can also be present (Krsek et al., 2008).

Some FCDs can have abnormal sulcal patterns, such as a cleft dimple with CSF or an unusual central sulcal pattern that resembles a “power” button symbol (Bronen et al., 2000; Mellerio et al., 2014b). These lesions have been shown to be located near deep sulci where the mean and maximum depth of sulci is higher than that of the corresponding sulci in controls (Besson et al., 2008a). These deep sulcal dysplasias often

have a positive transmantle sign, hyperintensity on T2/FLAIR, and abnormal gyral patterns (Hofman et al., 2011).

Sometimes, they can present as a multifocal occurrence (Fauser et al., 2009). Neuroradiologists aim to identify any abnormal image findings in all regions of the cortex and subcortical volumes. New imaging sequences such as double inversion recovery and MP2RAGE have been proposed to reduce signal from CSF and provide high T1 weighting, allowing for improved contrast in the cortex and detection of subtle lesions (Rugg-Gunn et al., 2006; Winston et al., 2014; Pardoe and Kuzniecky, 2014).

These radiological features manifest because of the way tissue microstructure is affected by MCD. In FCD type II, these microstructural abnormalities include neuronal hypertrophy with compromised cell motility (Thom et al., 2005), presence of immature balloon cells, and pathologic myelin arborization (Shultz et al., 2014). In addition, pathophysiological mechanisms such as gliosis and edema manifest as hyperintensities on T1WI and T2WI (Shultz et al., 2014). These features have been validated through histopathological studies of neuronal density, count, and aberrant neuronal patterns that contributed to gray-white blurring (Mühlebner et al., 2012). Some of the other MCDs, such as periventricular nodular heterotopia (PNH), have similar histopathological findings but present with gray matter signal in CSF and white matter regions on imaging.

Neuroglial tumors such as DNETs often have different imaging findings: the lesion is supratentorial, often well demarcated, and usually found in the temporal or frontal lobe (Velez-Ruiz and Klein, 2012). The characteristic MRI finding is increased signal on T2WI and decreased signal on T1WI. Contrast enhancement has been described in up to one-third of patients and is often located adjacent to a FCD (Velez-Ruiz and Klein, 2012). Certain subtypes often have cystic-like appearance, are well-delineated, and are strongly hypointense on T1 (Chassoux and Daumas-Duport, 2013).

Despite this extensive list of findings, MRI is only moderately sensitive in detecting these lesions regardless of histopathological subtype.



No MRI abnormalities are found in 31–41% of patients with FCD type I and 21–33% of patients with FCD type II (Velez-Ruiz and Klein, 2012). In a retrospective study of all histopathologically confirmed FCDs at a regional pediatric comprehensive epilepsy center, the majority of cases (58%) did not have any MRI abnormalities highlighting the need for better imaging techniques (Leach et al., 2014).

## 2.2. Electrophysiology

Electrophysiology is the current gold standard for isolating the epileptic networks and the seizure onset zone(s) during presurgical evaluation, especially invasive electrocorticography through the use of subdurally placed electrodes. This, in combination with imaging, is used to determine the resection zone. Additional studies such as magnetoencephalography (MEG) may be used to localize the epileptogenic zone, focusing primarily on interictal epileptiform activity, and to map eloquent cortex (Widjaja et al., 2008). In one study the surgical outcome following complete removal of areas containing clustered MEG sources and MR lesions were same, indicating MEG was approximately equally sensitive to MRI (Wilenius et al., 2013). It is important to note that the epileptic network, as defined by electrophysiology, may not exactly correspond to lesions on MRI, but also involve their microstructure and interface with more normal brain tissue. These border zones have been identified, by intracranial electrophysiology, to be at the border or just outside of the border of lesions defined by imaging, where microscopic pathology is often present (Mukae et al., 2014).

## 2.3. PET imaging

Positron emission tomography (PET) uses radiotracers to identify pathological metabolic and neuroinflammatory processes (Shultz et al., 2014). Local decrease and increase in radiotracer uptake are potential biomarkers for these processes. The most common radiotracer that is used is (Okonma et al., 2011) FDG-PET, though other radiotracers have been shown to be useful in imaging inflammation ((11C)-PK11195 PET (Butler et al., 2013)), abnormal metabolism of amino acids (Alpha-[11C]methyl-L-tryptophan (Natsume et al., 2008)) and epileptogenic tubers (CAMt (Asano et al., 2000, Kumar et al., 2011)). Cerebral glucose hypometabolism is associated with mitochondrial dysfunction in intractable epileptic patients (Tenney et al., 2014).

Many studies have shown that FDG-PET/MRI coregistration improves detection of cortical dysplasia in patients, especially those where the MRI is read as normal (Salamon et al., 2008). FCDs visualized on MRI usually coincide with the epileptogenic zone but the full extent is not visible. This can be resolved by fusing together PET images with MRI (Colombo et al., 2009). The presence of regional interictal hypometabolism can help radiologists guide their search for a lesion (Velez-Ruiz and Klein, 2012). It is important to note that FDG-PET can show normal or even hypermetabolic regions corresponding to FCD for unclear reasons. This has been attributed by some investigators to localized epileptiform activity (Colombo et al., 2009).

## 2.4. Cerebral blood flow imaging

Another standard imaging modality is SPECT imaging, which measures cerebral blood flow during ictal and interictal periods. The difference of these blood flow maps, termed SISCOM when co-registered to MRI, is used to isolate the seizure onset zone. Studies have shown that complete resection of onset regions identified by SISCOM is at least as good as MRI and EEG in terms postsurgical outcome, though this requires rapid injection of tracer proximate to seizure onset and focal uptake of the SPECT tracer (Krsek et al., 2013). This technique is variably employed in academic centers due to the cost and technical challenges of having the radioactive tracer on hand waiting for spontaneous seizure onset in inpatient epilepsy monitoring units.

Some institutions also use arterial spin labeling (ASL) imaging fused with 3D FLAIR sequences in order to measure relative cerebral blood flow in regions of interest and their contralateral counterparts. This helps demarcate primary lesions such as glial tumors and vascular malformations associated with FCDs, though perfusion abnormalities are not always consistent across patient groups, especially those with mesial temporal sclerosis (Toledo et al., 2013). More generally, interictal ASL findings in focal epilepsy resemble those of PET; that is, focal hypoperfusion in ASL resemble hypometabolism on PET (Toledo et al., 2013).

## 2.5. Diffusion imaging

Unlike conventional structural MR imaging that provides images resulting from magnetic relaxation parameters, diffusion imaging (DWI and DTI) provides contrast images based upon the extent, directionality and organization of the motion of free (unbound) water (Colombo et al., 2009). Malformations of cortical development often affect the microstructure of underlying white matter tracts (Colombo et al., 2009). In addition, presence of heterotopic neurons, abnormal myelination (myelin pallor on histology), edema, axonal injury and gliosis affect the diffusion properties of tracts originating from the lesion (Colombo et al., 2009; Shultz et al., 2014). Often, there is significant increase in perpendicular diffusivity, increased apparent diffusion coefficient and a significant reduction in anisotropy within the white matter near the lesion (Eriksson et al., 2001; Rugg-Gunn et al., 2001; Lee et al., 2004; Gross et al., 2005; de la Roque et al., 2005; Widjaja et al., 2007). There is also a decrease in the volume of white matter bundles, even in patients who have shown normal T2W MRI (Lee et al., 2004; Gross et al., 2005). These features can also be found when compared with the contralateral hemisphere (Princich et al., 2012).

Newer diffusion imaging sequences have the potential to better characterize lesions. High angular resolution diffusion imaging (HARDI-DTI), which resolves multiple intravoxel fiber populations (Tuch et al., 2002; Behrens et al., 2003), can more accurately perform fiber mapping and allow for the evaluation of white matter abnormalities near lesions. Advanced methods such as NODDI can give maps of neuronal density, though few studies have looked at the accuracy of detecting epileptogenic lesions (Winston et al., 2014). Other diffusion techniques such as diffusion kurtosis imaging (DKI) provides improved GM-WM contrast, and is sensitive to changes in GM (unlike DTI, as the apparent diffusion coefficient in GM is essentially isotropic) (Feindel, 2013).

## 2.6. Functional imaging using MRI and EEG

Functional MRI methods image temporal changes in blood flow (blood-oxygenation-level-dependent [BOLD] contrast imaging) (Kwong et al., 1992). Clinically, EEG is acquired during fMRI acquisition, and the timed EEG events are used to simultaneously map or signal average BOLD changes (Pardoe and Kuzniecky, 2014). These events are usually interictal epileptiform discharges, or spikes, because of the difficult logistics associated with recording seizures and ictal events in the MRI scanner. Studies have shown that BOLD response in EEG-fMRI can help delineate the epileptogenic zone and can quantify network changes in the brain (Pardoe and Kuzniecky, 2014; Zijlmans et al., 2007). The sensitivity of these techniques have ranged from 55% - 88% (Pardoe and Kuzniecky, 2014; Moeller et al., 2009). There are extensive studies that have used EEG-fMRI to help with lateralization of seizure onset, detection of lesions as well as assessment of neurocognitive battery tests. A combination of EEG-fMRI with other imaging modalities can potentially uncover structural and functional lesions that are often missed on standard imaging alone.

### 2.7. Network analysis using functional (fMRI/EEG/MEG) and structural imaging (DTI)

Brain networks in epilepsy have been increasingly investigated in recent years. Network analysis characterizes the organization of brain networks, either structural or functional, and studies the evolution of these networks interictally, preictally and ictally (Bullmore and Sporns, 2009; Ponten et al., 2007; van Diessen et al., 2013). There are other reviews geared towards clinicians as well as network scientists that introduce this paradigm of research and discuss future applications (van Diessen et al., 2013). Different modalities of brain mapping, including DTI, fMRI, EEG and MEG are used to correlate network characteristics of patients with epilepsy, such as those with FCDs (Bandt et al., 2014; Holmes and Tucker, 2013; Jeong et al., 2014; Caciagli et al., 2014; Bernhardt et al., 2011; Guye et al., 2010; Pedersen et al., 2015; Thornton et al., 2011; Englot et al., 2015). These connectivity measures have promising potential as an adjunctive tool to aid in identifying the epileptogenic zone as well as the extent of lesions in epilepsy patients being considered for resective surgery (Weaver et al., 2013). The questions remain as to what constraints exist between functional and structural networks and how this interplay guides seizure initiation and propagation. More studies need to consider network characteristics of structural networks (DTI, cortical thickness or gray matter derived graphs), and correlate them to network characteristics of functional networks, regional and global, derived from ECoG and fMRI. Highly informative network features will serve as predictive biomarkers for surgery outcome to clinicians.

### 2.8. Other modalities: CEST/MTI/MRS

Other imaging acquisition sequences have been studied in epilepsy patients but very few of them are used routinely for clinical purposes. Magnetic resonance proton spectroscopy (MRS) can image metabolite concentrations throughout the brain and is sensitive to neuronal dysfunction by showing reduced NAA (N-acetylaspartate) levels, increase in choline and other heterogeneous metabolic biomarkers in focal areas (Mueller et al., 2005). These image findings can also be asymmetric between hemispheres and can help lateralize the epileptogenic zone (Krsek et al., 2007). These act as biomarkers indicating mitochondrial dysfunction, total compartmental neurotransmitter concentrations, neuronal death and glial activation (Kuzniecky, 2004; Shultz et al., 2014). These can also separate etiologies since some such as FCD demonstrate metabolic abnormalities whereas heterotopias and polymicrogyrias do not often demonstrate these biomarkers (Kuzniecky et al., 1997). Other lesions, such as hypothalamic hamartomas tend to have reduced NAA and increased myo-inositol (Freeman et al., 2004). Another study has shown that postsurgical outcome was better if resected tissue was metabolically abnormal compared to resected tissues that were metabolically normal (Pan et al., 2013).

Other imaging sequences such as magnetization transfer imaging (MTI) can be very sensitive to detecting MCDs, though the specificity of MTI has not been well studied (Rugg-Gunn et al., 2003). Chemical exchange saturation techniques (CEST) can study specific neurotransmitter and macromolecular concentrations, such as glutamate (Cai et al., 2012). Areas with increased extracellular glutamate and with decrease glutamate-glutamine cycling have been associated with increase seizure likelihood, such as in areas of hippocampal sclerosis (Pan et al., 2008; Davis et al., 2015).

### 2.9. Summary

Current clinical epilepsy imaging protocols are primarily structural and diffusion imaging modalities. Specifically, T1W, T2W, FLAIR, DWI and sometimes MRS sequences are used to identify possible epileptogenic lesions, usually malformations of cortical development. In

addition, many institutions combined these structural images with functional imaging using PET, MEG, and SPECT. There have been many studies that have looked at quantitative MRI techniques, such as T2 mapping, HARDI-DTI, DKI, DIR and MP2RAGE, as possible ways to improve contrast-to-noise ratios especially in the gray matter but few studies have been able to improve sensitivity/specificity or correlate image findings with postsurgical seizure outcome.

## 3. How are features computed by machine?

In recent years, improvements in imaging technology such as parallel imaging MRI and high field scanners have improved the detection of malformations of cortical development, a large proportion of which can lead to epilepsy. However, visual analysis of these images by radiologists is a challenging task and there is considerable variability in the interpretation of these images. Recent trends in medical computer vision have tried to semi-automate the computation of these features and detection of these lesions, primarily through the use of voxel-based morphometry (VBM) as well as surface-based morphometry. Some methods attempt to detect them using textural features. Most methods compute these features with respect to a nominal distribution (z score) or with respect to the contralateral hemisphere (asymmetry analysis (Yang et al., 2011)). An exhaustive list of the image features used by different papers is laid out in Table 2.

Each of the above techniques has strengths and limitations, but the combination of such techniques could improve the detection of dysplastic lesions that are undetectable by MRI (Zhang et al., 2014). Still, some of them are easily missed, and the use of computational techniques is often not sufficient to detect them (Zhang et al., 2014). This section surveys the different methods that have been developed to outline the common image findings listed in the previous section. In most studies, sensitivity is defined as the fraction of patients who had lesions identified using computational analysis that went on to be resected. Specificity is defined as the fraction of normal healthy controls that failed to elicit any detection by these automated tools.

### 3.1. Signal intensity change and subcortical presence of abnormal gray matter

The most common image finding is an abnormality like a hyper- or hypo-intensity on standard imaging sequences (T1W, T2W, FLAIR). The most common method to detect these abnormalities is a voxel-wise approach which involves calculating z- or t-score statistical maps using a nominal distribution from normal healthy controls (Bernasconi, 2004; Colliot et al., 2005; Colliot et al., 2006b; Colliot et al., 2006c; Colliot et al., 2006a). Scores are computed either on the intensity itself or, more often, on a computed relative intensity score (Colliot et al., 2005; Colliot et al., 2006c; Besson et al., 2008b; Colliot et al., 2006b). Another common method to detect signal abnormalities is a type of surface-based method. A recent surface-based approach computed surface-based features of FCD morphology and was able to detect abnormal gray matter in patients initially read as MRI-negative with high sensitivity and specificity (Hong et al., 2014). Other methods detect hyperintensities by calculating the difference between voxel intensities and voxels on the gray and white boundaries to find signal abnormalities at the gray-white junction (Antel et al., 2002).

These techniques can be adapted to identify other malformations, such as subcortical band heterotopia (“double cortex” syndrome) (Huppertz et al., 2008) or periventricular heterotopia, where ventricle masks are used to look for abnormal gray matter outlining the ventricles (92.5% sensitivity and 91.5% specificity) (Pascher et al., 2013). In addition, these methods have been sensitive to detecting co-occurring neoplasia with focal cortical dysplasia (87% sensitivity) (Bruggemann et al., 2007).

Some important caveats to using voxel-based morphometry are: (Schachter, 2015) statistical maps depend on the control population

**Table 2**

List of features and sample methods used to compute the features. Different combinations of these features were used to isolate and identify lesions (usually focal cortical dysplasias).

Computable features for detection of epileptogenic lesions		
Feature		Algorithms to compute feature
Image intensity		Voxel-based morphometry (Ashburner and Friston, 2000), difference maps (Wilke et al., 2003), laplacian intensity gradient (Colliot et al., 2006a), other statistical measures (mean, median, variance, skewness, kurtosis, energy, entropy)
Cortical thickness		Diffeomorphic registration based cortical thickness (Tustison et al., 2014), distance between gray/white and pial isocontour surfaces (Dale et al., 1999; Besson et al., 2008b)
Gray-white blur		Gradient map using gaussian smoothing, identify areas with highest cortical thickness (Qu et al., 2013), MAP (Wagner et al., 2011), iterated local searches on neighborhood (Xiaoxia et al., 2014)
Sulcal reconstruction		Graph matching (Rivière et al., 2002), gyrification index (Dale et al., 1999), spherical wavelets (Yu et al., 2007; Nain et al., 2007)
Lobar or volume atrophy/enlargement		Deformation based morphometry, jacobian of heat equation vector field applied to spherical harmonics with a point distribution model (Kim et al., 2005; Bernhardt et al., 2015)
Curvature		Gaussian intrinsic curvature (Kim et al., 2013; Pienaar et al., 2008), extrinsic curvature (Pienaar et al., 2008), integral measures of curvature (Van Essen and Drury, 1997), orientation fields from gradient structure tensors (Rieger and van Vliet, 2002; Rieger et al., 2004), area-minimizing flows to spherical registration (Besson et al., 2008b)
Asymmetry analysis (Goffin et al., 2010)		Asymmetry index, asymmetry analysis on cortical folding (Van Essen et al., 2006)
Other cortical measures		Fractal analysis of the cortex (Bernasconi, 2004), metric distortions on spherical registration (Wisco et al., 2007)
Texture analysis		
3D texture analysis		Directional Riesz wavelets (Jiménez Del Toro et al., 2013)
Gray-level co-occurrence	Contrast, homogeneity, inverse difference, energy, entropy	Haralick et al. algorithm
Gray-level run-length	Short/long run emphasis, gray level distribution, run-length distribution	Haralick et al. (Haralick et al., 1973) algorithm (Haralick et al., 1973)

used for analysis (Kwan et al., 2011), the results of VBM depend on the accuracy of intrasubject registration and normalization (Bookstein, 2001; Begley et al., 2000), there have been studies that showed a lack of correlation between gray matter probability values and the cortical neuropathological measures in normal-appearing gray matter, suggesting that intrinsic neuropathological cortical changes do not necessarily influence gray matter probability maps used for VBM analyses (Eriksson et al., 2009).

Other methods of detecting intensity change and abnormal presence of gray matter in white matter include computation of difference maps (Wilke et al., 2003), fractal analysis of the cortex (Bernasconi, 2004),

analysis of intensity gradients (Colliot et al., 2006a), asymmetry analysis of intensities (Goffin et al., 2010), and analysis of textures (Bernasconi, 2004; El Azami et al., 2013). Studies using texture analysis compute cubic volume sampling around each voxel to calculate second and third order textural features, and compare them to the contralateral side (Yang et al., 2011; Jiménez Del Toro et al., 2013). These methods were able to easily identifiable lesions in 85% of patients in one study.

Signals can also be abnormal in other modalities, such as DTI ADC, when compared to controls. For instance, VBM on T2 mapping had 87% sensitivity (Rugg-Gunn et al., 2005) and VBM on FLAIR imaging had 88% sensitivity/96% specificity (Focke et al., 2008) in detecting hyperintensities. One study identified a lesion in a test patient using 7 T VBM (Speck et al., 2009). The few studies that have applied VBM to DTI found reduced fractional anisotropy, increased trace of tensor eigenvalues, and elevation in perpendicular eigenvalues in lesional voxels (Widjaja et al., 2007). Another study looked at probabilistic reconstruction of PET-MR data using asymmetry as a way to detect hypo-/hyper-metabolic regions (Goffin et al., 2010). This study was able to detect lesions correctly in 71% of the patients though specificity was hard to determine since the other positive findings could not be verified as false positives. Fewer studies have reported segmentation accuracy in terms of coverage of lesional voxels but the study with the best results has reported 73% segmentation accuracy (Bergo et al., 2008). More research needs to be done in applying morphometric methods to newer modalities of imaging.

### 3.2. Increased cortical thickness

Cortical thickness measures the radial distance between white and gray matter surfaces (Thesen et al., 2011). Increased cortical thickness is a sensitive finding in malformations of cortical development, specifically FCDs (Thesen et al., 2011). In past studies, increased cortical thickness has been reported in 91% of patients (Bernasconi and Bernasconi, 2011). Early studies focused on cortical thickness computed as the distance between isosurfaces corresponding to the gray-white junction and the gray-CSF junction, utilizing Laplace's equation to identify these intensity-based contours (Antel et al., 2002; Bernasconi, 2004; Colliot et al., 2005; Colliot et al., 2006b). Currently, the most commonly used cortical thickness tools include Civet-CLASP (MacDonald et al., 2000; Kim et al., 2005), Freesurfer (Dale et al., 1999) and diffeomorphic registration based thickness measures (Tustison et al., 2014; Das et al., 2009).

Cortical thickness can be measured through a voxel wise approach or by utilizing tools that compute it using surface-based morphometry. A recent study that utilized surface-based morphometry showed that with cortical thickness as a feature, "a surface-based detection method identified 92% of cortical lesions (sensitivity) with few false positives (96% specificity), successfully discriminating patients from controls 94% of the time" (Thesen et al., 2011).

### 3.3. Gray-white junction blurring

Another important image finding sensitive to malformations of cortical development is blurring of the junction between outer gray matter and inner white matter, which contributes to a pseudo-thickening of the cortex (see Fig. 1). Up to 72–96% of lesions will have this finding on MRI (Bernasconi and Bernasconi, 2011). In addition, the majority of patients (up to 83%) who have FCDs but no imaging findings have subtle GW junction blurring that is initially missed by the neuroradiologist.

Techniques used to model GW blur include computing a gradient map after convolution with a Gaussian kernel (Antel et al., 2002; Colliot et al., 2005; Colliot et al., 2006b) and computing VBM of GM intensity across a nominal distribution from healthy controls (Huppertz et al., 2005). Another technique approximated areas of blur by finding regions with the highest cortical thickness, which would find pseudo-



thick regions of the cortex as a result of GW blur. This technique has 70% sensitivity in detecting blurred regions (Qu et al., 2013).

The most well-studied and successful technique is the MAP technique (Huppertz et al., 2005) which creates a “junction” image. Junction images are calculated by computing the histograms of classified gray and white matter voxels. Next, those with intensities that fall in between the two histogram means are isolated. These are used to identify voxels that are not definitively gray or white matter. The resulting binary image is convolved with a smoothing kernel, revealing areas of ambiguous gray voxels. This image is subtracted from similarly created junction images from a nominal distribution of healthy controls, showing areas of abnormal “junction” (Huppertz et al., 2005). One study that used the MAP technique was able to identify a lesion in one patient’s imaging that was initially read as normal. This led to resection of the identified abnormal tissue and the patient has been seizure-free post surgery (Wang et al., 2012). Another study similarly found subtle lesions in the orbitofrontal region of a patient with FCD and gliosis (Wang et al., 2013). This technique helps in redirecting the reviewer to suspicious areas rather than generating new diagnostic information for clinicians (Wang et al., 2012; Wang et al., 2015).

Other more advanced methods exist to quantitatively measure GW blur. For instance, a recent study utilized an “iterated local searches on neighborhood” technique to improve the specificity of these approaches, specifically the gradient method, by measuring the GW border width and creating a potential map based on the probability distributions of GM and WM in each voxel (Xiaoxia et al., 2014). This potential map is then converted into a distance map between the gray and white matter surfaces using an iterative optimization approach that optimally searches in a cubic neighborhood to find the shortest distance. This distance metric represented the GW junction width and highlighted abnormally thickened regions of the cortex (Xiaoxia et al., 2014).

### 3.4. Sulcal and gyral abnormalities

Patients with malformations of cortical development will show many different sulcal and gyral abnormalities. For instance, some FCDs are located in the deep sulcus (Besson et al., 2008a). Other malformations, such as lissencephaly and polymicrogyria will have abnormally shaped sulci and gyral structure. Other radiological findings include specific image findings when the cortical surface is reconstructed, such as polymicrogyria, pachygyria and the power-button sign, which occurs in 62% of FCD type II patients due to a particular elongation of the precentral sulcus (Mellerio et al., 2014b).

Early methods of sulcal mapping used graph matching algorithms, driven by minimization of a global cost function derived from intensity-based potentials (Rivière et al., 2002). Voxel-based methods have also been used to determine these abnormal gyration patterns that stand out when compared to normal health control gyri (Wagner et al., 2011). Similarly, surface based methods (e.g. Freesurfer) allows for quantification of surface-based features such as gyrification index, curvature and sulcal depth (Dale et al., 1999). Gyrification index quantifies the gyral anatomy in a circular region around any surface vertex. This surface-based feature was found to be helpful in detecting epileptogenic malformations but were not specific to this condition (Thesen et al., 2011). More recent sulcal morphometric methods have been used to identify regions with deep sulci or broad gyri (Hong et al., 2014).

### 3.5. Diffuse/multifocal hyperintensities

Any of the above features can be present in different lobes of the brain. There have been studies confirming multi-focal occurrence of MCD (Fauser et al., 2009). Other malformations of cortical development such as periventricular heterotopia or subcortical band heterotopia can have abnormal gray matter signal around the ventricles or near the gray-white junction at multiple locations of the brain (see Fig. 2). All

the above methods be applied throughout the brain but suffer in specificity.

### 3.6. Summary

Most of the imaging findings that radiologists look for in patients with epilepsy can be computed and detected sufficiently well, though with questionable specificity. The most common methods of computation and detection involved voxel-based morphometry or a statistical mapping of features compared to a nominal distribution from normal controls. Other surface-based morphometric techniques exist to compute other anatomical features, such as gyrification, sulcal depth, and cortical thickness. While many studies have combined some of these features with variable success on FCD type II, future studies should focus on identifying all malformations of cortical development like low-grade glial tumors. In addition, future studies should combine some of these features or compute these features across multiple imaging modalities to gain better specificity. This can better identify epileptogenic lesions.

## 4. How well can computational analysis identify lesions based on these features?

Automated analysis provides an effective way to simplify the analysis and diagnosis of malformations of cortical development in epilepsy patients. It can reduce the burden on radiologists in their practice and improve diagnostic accuracy (Wang and Summers, 2012). Many studies have attempted to fully automate the detection of MCDs, specifically cortical dysplasias, by applying supervised and unsupervised learning techniques based on the features discussed in the previous section. Below we review the techniques tried as well as the accuracy of these automated techniques.

### 4.1. Segmentation

Many studies attempted to segment cortical boundaries of lesions based on changes in image gradients, especially in cases where they caused significant gray-white blurring or increased cortical thickness. Despotović et al. (2011) integrated Markov random field-based energy functions with a graph cuts algorithm to more accurately segment cortices with focal cortical dysplasias (Despotović et al., 2011). These investigators confirmed their accuracy through comparison to other segmentation techniques, such as SPM and FSL, using Dice scores, a common metric of overlap and similarity used with segmentation algorithms.

Shen et al. (2011) used fuzzy c-means segmentation algorithm to create a fuzzy index matrix that quantified degree of gray-white blurring (Shen et al., 2011). This technique identified the lesion correctly in 5 of 7 patients with FCDs. These positive results indicate further research is needed to investigate the utility of advanced techniques in segmentation.

### 4.2. Supervised learning

In supervised learning, each sample contains two parts: one is a set of input features and the other is output observations or labels (Wang and Summers, 2012). The purpose of supervised learning is to deduce a functional relationship from training data that generalizes well to testing data (Wang and Summers, 2012). The following studies used different forms of supervised learning to correctly classify voxels as lesional or normal. They primarily looked at FCD type II.

El Azami et al. (2013) utilized multiple textural features to compute symmetric textural patches taken from both hemispheres. These features were trained using a reduced coulomb energy classifier that attempts to fit the best hypersphere that would correctly classify each voxel based on their feature set. Their training data was a small sample



(1%) of voxels (from both healthy controls and patients) along with features corresponding to each one. The test data was run using a leave-one-out cross validation scheme. This was followed by outlier removal via thresholding of cluster size and distance to nearby lesional clusters. This resulted in 77% coverage of correctly identified lesional voxels that were concordant with manually drawn ROIs in study patients.

Strumia et al. (2013) computed textural based features such as image gradient, skewness of local cortical thickness histograms, and spatial tissue probability maps on patients with FCDs and normal healthy controls. These features were used in a Naive-Bayes classifier to calculate probabilities at each voxel. The accuracy of classification of this method was 51% with a dice score of 0.13. This was compared to the MAP technique (Huppertz et al., 2005), which only had an accuracy of 17%.

Antel et al. (2003) computed the following features: cortical thickening, blurring of gray-white junction, gray-level hyperintensity through image gradient, and textural features such as statistics on gray-level co-occurrence matrices (angular second momentum, difference entropy, contrast). As a first step, the intensity-based features were trained in a Bayesian classifier to classify as lesional or normal. Voxels classified as lesional were then reclassified based on Fisher's discriminant ratio using textural features. This boosting technique was performed using a leave-one-out cross validation approach and resulted in an average sensitivity of 83% detection in the test patient population. There were no lesions classified in the normal healthy control population (100% specificity). There were some additional ones detected in the patient population, though further study is required to determine whether these correlated with clinical disease.

Another study, Besson et al. (2008b), took a similar approach but used surfaced-based features, including cortical thickness, curvature and sulcal depth. In addition, the authors of the study modeled voxel-based features, such as gray-white blur and signal hyperintensity, on these surface contours outlining the gray and white matter. They applied a four-layer feed forward neural network to classify each vertex as lesional or healthy. To avoid overfitting, a cross-validation method was used to optimize the neural networks. The mean and standard deviation of all surface features of clusters of vertices classified as lesional were then reclassified using a fuzzy k-nearest neighbor to remove false positives in healthy controls. The sensitivity of the first classifier, which was 95%, reduced to 68% once the second classifier was implemented to ensure no false positives were detected in healthy controls (100% specificity).

Yang et al. (2011) computed statistical features on cortical thickness and gradient vectors and applied them to a Naïve Bayes classifier. This classifier resulted in 62% sensitivity, 81% specificity after parameters were optimized.

#### 4.3. Recent computational models

Recent methods have refocused the problem of detecting lesions as an outlier detection problem. This follows from the idea that a lesion is an outlier in the feature space when compared to the same region across control populations. This outlier detection approach has been successful in other fields (e.g. seizure prediction (Gardner et al., 2006)) and overcomes the need to collect large amounts of training data and fine-tune parameters of the model. The most recent supervised algorithm (Ahmed et al., 2014) classified segmented patches of the cortex, obtained using unsupervised segmentation of the flattened cortex, which clusters regions with homogeneous feature values. As a result, their study corrected their method for 3 issues: All voxels in previous learning models are assumed to be independent of each other, most learning models use a second reclassifier to improve specificity but in the process lose sensitivity of the delineation of the epileptogenic lesion and better models need to be able to detect lesions in patients who are MRI negative instead of on imaging with visible lesions.

Another outlier detection method trained a one-class SVM (OC-SVM) to classify voxels as normal based on 6 features (probability maps of GM, WM, CSF, gray matter intensity, gray-white blurring). Then, a test image was inspected using the classifier and a threshold to the distance metric was applied to identify voxels that were “outliers”, or very different, compared to the normal distribution for these feature values (El Azami et al., 2013). This method did similarly well to previously described techniques, such as SPM and MAP (Huppertz et al., 2005), and was able to detect lesions that were missed during initial reading. The authors concluded the study by saying that with better and larger normal control population, their method would be able to detect smaller lesions (El Azami et al., 2013).

In unsupervised learning, there is only one set of features and no label information for each sample (Wang and Summers, 2012). The main purpose of unsupervised learning is to discover interrelationship between the features to uncover latent variables behind the observations (Wang and Summers, 2012). One study used unsupervised techniques to model multiscale cortical surface patches derived from coarse to fine resolutions of the image. These patches were then fed into a random forest, specifically a hierarchical conditional random field, which considers patches that overlap with each other at all scales. This method resulted in detection of lesions in 90% of MR+ images and an impressive 80% of MR- images (Ahmed et al., 2014).

Very few studies have looked at extending these techniques to other modalities. One study looked at the power of combining diffusion weighted imaging with magnetic resonance spectroscopy. Using a linear discriminant analysis on images obtained from pediatric patients with FCD, DNETs and gangliomas, the study found that combining features from different modalities is more powerful than taken individually. When taken alone, none of the MRI parameters was able to distinguish FCD from DNET and gangliomas. When apparent diffusion coefficient variable was added to the model, one patient was still misclassified. The complete separation of all three groups of patients was possible only when conventional MRI, diffusion, and MRS were combined together (Fellah et al., 2012).

#### 4.4. Summary

This section surveyed a number of automated techniques that detect and define areas of MCD, mostly focal cortical dysplasia. Though most of the methods were supervised, all used different set of features, including voxel-, surface- and texture-based features. Most studies applied their techniques to standard imaging (T1W, T2W), and focused on FCDs. It is important to note that studies applying these techniques are almost all relatively recent, and some of the most promising are published as machine learning or computer science conference papers, speaking to the novel nature of the work. In addition, most of these studies could be applied to other modalities as well.

There is a need to consider other data-driven approaches in the future including dimensionality reduction, which decreases the number of features and increases relevant information. This has shown promise in complementing current clinical diagnostic tools. For instance, in a study of asthmatics versus non-asthmatics, textural features and other second order image features had higher predictive power of diagnosis as compared to spirometry values (Tustison et al., 2010). Interestingly, it was also found that spirometric values are relatively orthogonal to these image feature values in terms of informational content (Tustison et al., 2010). The same lesson can be applied to the problem of detecting epileptogenic regions, where the current gold standard for seizure localization is through electrophysiology, brain imaging, clinical information, neuropsychological testing, and the physical examination; all felt to give orthogonal information. Utilizing complementary information can help narrow the solution space for search algorithms, so that the underlying structural lesion can be best described through use of minimally-redundant maximally-relevant image features.

## 5. Discussion

A number of methods have emerged over the last decade to detect malformations of cortical development, such as T2W hyperintensity, T1W hypointensity, increased cortical thickness, increased blur of the gray-white junction, and abnormal cortical folding patterns. Technological innovations in imaging such as diffusion imaging and computing techniques such as voxel-based morphometry have converged to make this tremendous advancement. In addition, automated methods like applying machine learning techniques, most commonly supervised learning schemes, have shown impressive results in detecting the most common lesion that may be present in a patient with drug resistant epilepsy.

### 5.1. Multi-centric data-sharing platform

The large variability in which lesion was detected across studies is one of the drawbacks of this field. Another is our lack of knowledge as to how much of the epileptic network must be removed to render patients seizure-free, as it may be that more focal resection of better-localized regions would yield better overall outcome. Additionally, variability in patients across studies and institutions, different protocols for pre-surgical evaluation at different centers, different imaging equipment used at each center, and the underlying pathology of the patients included in each study (Zhang et al., 2014) are the contributing factors to the varying accuracies of the different methods mentioned in this review.

The authors of this review believe a multi-centric data-sharing platform with computational pipeline analysis (example in Fig. 3) is the natural next step in the line of research. This will be critical to standardizing neuroimaging data analyses across institutions, avoiding bias and allowing algorithms to be improved to detect multiple types of lesions, not just FCDs. This pipeline would ideally satisfy the following criteria:

1. The pipeline should have the capability to analyze large-scale neuroimaging data across multiple modalities and time points utilizing the most accurate algorithms to provide regions of interest for further study.

2. The pipeline should be capable of identifying important radiological features that are of interest to radiologists, such as cortical atrophy, pseudothickening of the GM, ventricular abnormalities, etc.

3. The pipeline should be designed with a modular structure to allow easy plug-and-play of different machine learning algorithms in order to serve as a benchmarking platform, where different algorithms can be compared to “gold standard” training data. In addition, this will be important to clinically validate newer sequences and imaging technologies that are discovered, such as ultrahigh field imaging (Madan and Grant, 2009) and advanced diffusion sequences (Winston et al., 2014).

4. Finally, the pipeline should also be able to take in other electrophysiology and clinical metadata in order to better adapt to the clinician’s need. This would also allow researchers to study how well their algorithms correlate with electrophysiological and clinical findings or to apply novel network analysis methods on ECoG-derived networks as well as fMRI and DTI whole-brain networks.

Analyzing the amount of neuroimaging data collected at standard epilepsy centers requires a substantial amount of computational resources. Leveraging elastic cloud resources can be a cost effective solution to advance this field into one that is more collaborative and transpires across multiple clinical institutions. There are multiple resources in the neurology community that utilize these cloud resources, such as <http://ieeg.org> (Kini et al., 2015), Human Connectome Project (Van Essen et al., 2013), the European EEG database (<http://epilepsy-database.eu>) (Klatt et al., 2012) and LONI IDA (Dinov et al., 2010).

Still, it is a challenge to implement such a multi-centric approach without proper incentives (e.g. federal funding) or appropriate guidance from clinical and scientific leadership. In addition, standardization of imaging data can be a challenge in the clinical epilepsy domain

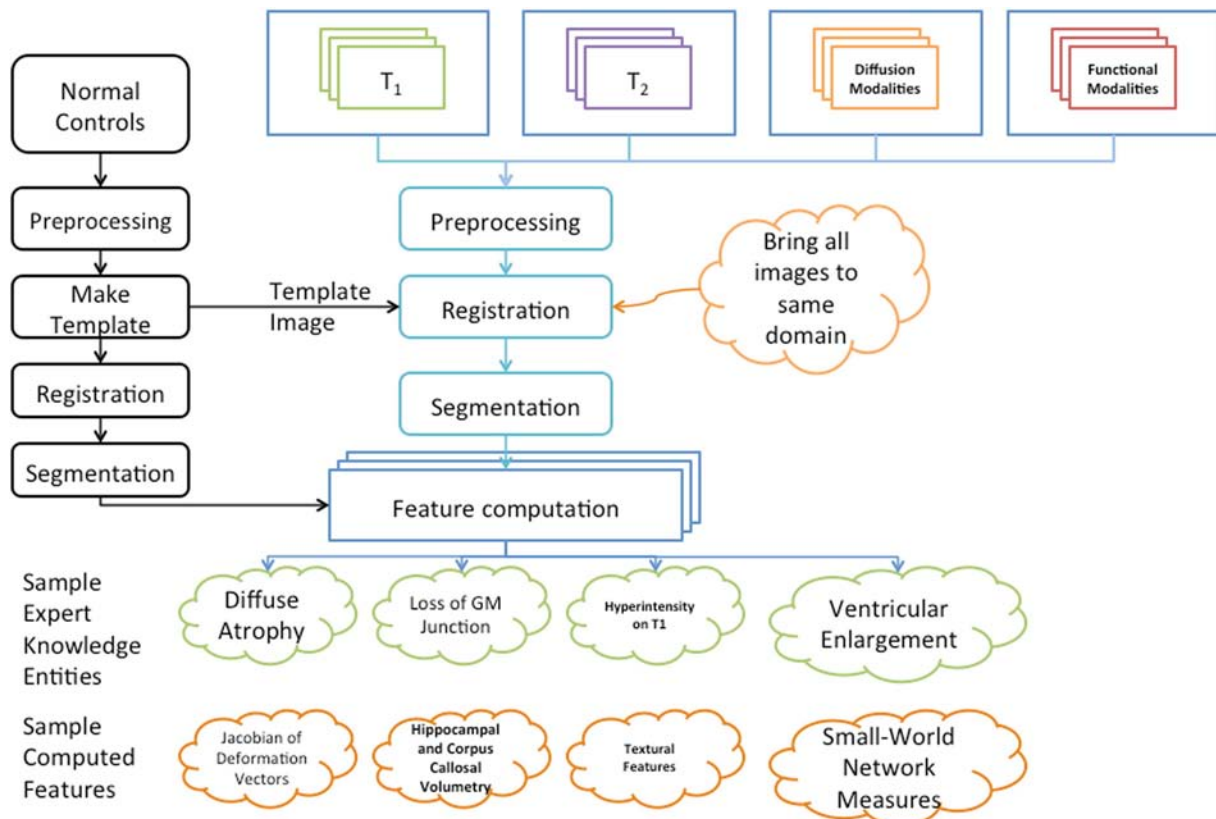


Fig. 3. Sample outline of a pipeline to identify key features in multi-modal imaging from patients with drug-resistant epilepsy.

because of the large variability in clinical imaging sequences in the patient workup. All pipelines would have to ensure data format interoperability, de-identification of protected health information (PHI), and adherence to mandated government regulations. Imaging data would have to be manually curated to remove any incomplete data that is of poor quality (e.g. images with artifact distortions) before being uploaded to data sharing platform used by these pipelines. Institutions that would like to contribute would have to make sure they get appropriate consent from patients and have approval from their institutional ethics board (e.g. IRB).

Over the past 4 years, our team of neuroscience and computer science experts has established a cloud-based resource, <http://IEEG.org>, that we believe can be a potential solution to these challenges. This platform provides data sharing and analysis capabilities to the neuroscience community, with additional imaging analysis tools planned for the near future. This collaborative platform allows researchers to have tight control over data access and allows researchers to share algorithms and data. We hope solutions like this platform will address these challenges and promote multi-centric work that can make significant impact on clinical practice.

For now, future studies should at least try to ensure proper feature selection in their methods and include newer imaging modalities that provide insight into pathophysiologic mechanisms. In addition, any research study should attempt to make their computational pipelines publicly available to scientists and clinicians so they can be applied in a clinical setting.

## 5.2. Feature selection

Features that were used in most studies were more important than the classifier itself because these were derived from important knowledge-guided radiological markers. It is useful to carefully consider which features should be used in any model because slight changes in feature set can cause considerable variability in the resulting prediction model. Proper feature selection will reduce the computation cost of including irrelevant features as well as prevent overfitting.

The brute-force method of feature selection is to exhaustively search through all possible combinations of input features and find the best subset. The computational cost associated with this is too high with significant danger of overfitting. Instead, methods that would allow for a ranking of different computational image features in conjunction with clinical values (e.g. radiological or electrophysiological) would yield useful feature subsets that can greatly improve accuracy.

For instance, cortical thickness and gray-white junction blur are useful features to predict cortical dysplasia. Thus, a straightforward approach for feature selection would be to choose features similar to this which best characterize the observed data and agree with expert clinical classification of the target image. This would quantify to clinicians what minimally-redundant information each feature uniquely provides. This might additionally unveil key radiomarkers of disease extent that are better indicators than standard radiological markers. This class of methods is getting more traction in the field of epilepsy. For example, experts in the computational imaging field have uncovered a surprising subpopulation of temporal lobe epilepsy patients who have bilateral hippocampal hypertrophy using surface-based volumetry (Bernhardt et al., 2015). They found this subgroup was high correlated with surgical outcome (Bernhardt et al., 2015).

All future studies should also consider adding features obtained from newer modalities such as 7 T T1 MRI or DTI. In addition, applying the same features as before can uncover potentially important radiomarkers in newer modalities that better explain the pathophysiology. It would be intriguing to study how multi-modal imaging features affect the prediction models of lesion localization.

It is important to note that other more automated approaches to feature selection have been applied to EEG and other feature selection problems and may have applicability here. These include the use of

genetic algorithms to search a feature space, including testing a range of secondary features (i.e. features of features (D'Alessandro et al., 2003)).

## 5.3. Gaps in knowledge of pathophysiologic mechanisms.

The pathophysiologic mechanisms and the full clinical spectrum of syndromes associated with malformations of cortical development are unknown. The fact that some lesions can be invisible in structural and functional imaging means that imaging technology has not advanced far enough to understand for investigators to understand MCD pathophysiology. For instance, S.H. Eriksson et al. found that there is lack of correlation between SPM derived gray matter probability values and quantitative cortical neuropathological measures in normal-appearing gray matter, which suggests that there are underlying intrinsic cortical changes that are not reflected in the computed gray matter maps (Eriksson et al., 2009). In addition, lesions in the seizure zone may not be generating seizures, but may require interaction with normal cells outside the seizure region of structural disorganization in order to initiate a seizure (Schwartzkroin and Wenzel, 2012). This has been shown to happen in the perituberal tissue in patients with tuberous sclerosis complex (Sosunov et al., 2015). Thus, delineating the full extent of the epileptogenic zone may be difficult, especially when imaging is incapable of rendering these interactions. Further, it may be necessary to combine different modalities of imaging, including structural, functional, metabolic and EEG to gain insight into the extent of the “critical mass” of the lesion that should be resected (Schwartzkroin and Wenzel, 2012).

Studies that have looked at lesion histopathology from patients whose images were read as normal indicate that a majority of these lesions were mild forms of malformations (45% FCD, 22% gliosis, 13% hamartia and gliosis, and 9% hippocampal sclerosis). Thus, imaging techniques need to improve in order to detect these milder forms of malformation earlier in the clinical treatment phase.

## 5.4. Imaging technique challenges

Existing technological improvements in imaging have greatly improved the sensitivity to malformations. For instance, the phased array coil in high and ultra-high field MRI improves signal-to-noise ratio (SNR) and allows for radiologists to more easily detect lesions (Knake et al., 2005). The current state of 7 T MRI allows for improved contrast to noise ratio, especially at the gray-white junction (Duyn et al., 2007). This modality has been shown to correlate well with microscopic pathology in hippocampal pathologies like sclerosis (Coras et al., 2014). But, few studies have tested the benefit of this technique and correlated with outcomes (Speck et al., 2009). As a result, even fewer studies have combined images obtained at 7 T with other modalities of imaging. These image techniques should be able to capture features visible on histology such as cortical laminar disorganization and the presence of dysmorphic neurons with/without characteristic “balloon cells (BCs)” (Miyata et al., 2013).

## 5.5. Next steps: gold standard metrics for lesion localization and quantification

The studies mentioned in this review differ in the way they approach quantifying accuracy of their methods. Currently, there is no gold standard metric to assess if a lesion has been correctly identified. In addition, there is no gold standard metric to quantify its extent. As a result, we cannot be sure if current methods are correctly detecting their target regions. In addition, if a lesion is detected, we cannot measure the accuracy of its estimated extent.

In most studies, sensitivity is defined as the proportion of patients in which there is overlap between predicted lesions and surgical resection volume in patients. These are measured in a patient cohort with favorable outcomes (e.g. Engel I). There is no confirmatory histopathology



or electrophysiology for the other “positive” findings in volumes that were not resected. Similarly, specificity is defined as the proportion of healthy controls in which the method failed to find any “false positive” lesion.

In order to ensure standardization of these definitions, all patients should have exact lesion localization and seizure onset maps cross-validated across different neuroimaging modalities, surgical histopathology, surface/depth electrode recording and other clinical metadata. The full spatial extent of the lesion pathology should be accurately mapped to allow researchers to measure the volume overlap. These standardizations should be set as guidelines by the clinical leadership (e.g. similar to the ILAE histopathological classification system (Blümcke et al., 2011)).

Any findings that do not overlap with these ground truth lesion and SOZ maps should be marked as false positives to get a better estimate of specificity. This allows specificity to be measured at the voxel-level versus at the weaker subject-level (where normal healthy controls are used as a test of specificity).

### 5.6. Next steps: make computational pipelines available to clinicians

Most current research methods use computational neuroimaging pipelines to preprocess data, compute features and input into a supervised or semi-supervised classifier. These pipelines are useful for researchers and clinicians alike. Researchers can use these pipelines to improve on others work and apply these methods to other patient cohorts. Clinicians can use these pipelines as part of the clinical decision workflow, thereby uncovering lesions that might have been missed by radiologists. Thus, it is important than any research study that builds such a pipeline makes the code easily available and usable for clinicians, who are often not fully versed in the technical details of the image computation. This will encourage clinicians to put these pipelines in their clinical practice and study its impact on patient outcome.

### 5.7. Summary

In summary, this integrated data-sharing platform will serve as an adaptable and powerful platform for clinicians and computer scientists. We envision a future in which the use of such modular, clinically validated pipelines will become commonplace in epilepsy centers alongside the advances in imaging and electrophysiology. We strongly believe that this big data approach to semi-automating the detection of subtle lesions will be an important ingredient of next-generation computer vision breakthroughs in epilepsy neuroimaging.

### Acknowledgments

The authors would like to acknowledge Mr. Hoameng Ung for his support in reviewing the final manuscript. The International Epilepsy Electrophysiology Portal is funded by the NIH 5-U24-NS-063930-05. Additional grant funding provided by NIH 1-T32-NS-091006-01 (Training Program in Neuroengineering and Medicine), Neil and Barbara Smit, and the Mirowski Family Foundation.

### References

Ahmed, B., Thesen, T., Blackmon, K.E., et al., 2014. Hierarchical conditional random fields for outlier detection: an application to detecting epileptogenic cortical malformations. In: Lawrence, N., Reid, M. (Eds.), 31st Proceedings of the International Conference on Machine Learning. Beijing: JMLR: Workshop and Conference Proceedings <http://jmlr.csail.mit.edu/proceedings/papers/v32/ahmed14.pdf>.

Antel, S.B., Bernasconi, A., Bernasconi, N., et al., 2002. Computational models of MRI characteristics of focal cortical dysplasia improve lesion detection. *NeuroImage* 17, 1755–1760. <http://dx.doi.org/10.1006/nimg.2002.1312>.

Antel, S.B., Collins, D.L., Bernasconi, N., et al., 2003. Automated detection of focal cortical dysplasia lesions using computational models of their MRI characteristics and texture analysis. *NeuroImage* 19, 1748–1759. [http://dx.doi.org/10.1016/S1053-8119\(03\)00226-X](http://dx.doi.org/10.1016/S1053-8119(03)00226-X).

Asano, E., Chugani, D.C., Muzik, O., et al., 2000. Multimodality imaging for improved detection of epileptogenic foci in tuberous sclerosis complex. *Neurology* 54, 1976–1984. <http://dx.doi.org/10.1212/WNL.54.10.1976>.

Ashburner, J., Friston, K.J., 2000. Voxel-based morphometry – the methods. *NeuroImage* 11 (6 Pt 1), 805–821.

Bandt, S.K., Bundy, D.T., Hawasli, A.H., et al., 2014. The role of resting state networks in focal neocortical seizures. *PLoS ONE* 9 (9), e107401. <http://dx.doi.org/10.1371/journal.pone.0107401>.

Barkovich, A.J., Guerrini, R., Kuzniecky, R.I., Jackson, G.D., Dobyns, W.B., 2012. A developmental and genetic classification for malformations of cortical development: update 2012. *Brain* 135 (Pt 5), 1348–1369. <http://dx.doi.org/10.1093/brain/aws019>.

Begley, C.E., Famulari, M., Annegers, J.F., et al., 2000. The cost of epilepsy in the United States: an estimate from population-based clinical and survey data. *Epilepsia* 41 (3), 342–351 <http://www.ncbi.nlm.nih.gov/pubmed/10714408>. Accessed January 8, 2015.

Behrens, T.E.J., Johansen-Berg, H., Woolrich, M.W., et al., 2003. Non-invasive mapping of connections between human thalamus and cortex using diffusion imaging. *Nat. Neurosci.* 6 (7), 750–757.

Bergo, F.P.G., Falcão, A.X., Yasuda, C.L., Cendes, F., 2008. FCD segmentation using texture asymmetry of MR-T1 images of the brain. 2008 5th IEEE International Symposium on Biomedical Imaging: From Nano to Macro, Proceedings, ISBI, pp. 424–427.

Bernasconi, A., 2004. Quantitative MR imaging of the neocortex. *Neuroimaging Clin. N. Am.* 14 (3), 425–436.

Bernasconi, A., Bernasconi, N., 2011. Unveiling epileptogenic lesions: the contribution of image processing. *Epilepsia* 52 (Suppl. 4), 20–24.

Bernasconi, N., Bernasconi, A., 2014. Epilepsy: imaging the epileptic brain—time for new standards. *Nat. Rev. Neurol.* 10 (3), 133–134 <http://www.ncbi.nlm.nih.gov/pubmed/24419681>. Accessed January 20, 2015.

Bernhardt, B.C., Chen, Z., He, Y., Evans, A.C., Bernasconi, N., 2011. Graph-theoretical analysis reveals disrupted small-world organization of cortical thickness correlation networks in temporal lobe epilepsy. *Cereb. Cortex* 21 (9), 2147–2157. <http://dx.doi.org/10.1093/cercor/bhq291>.

Bernhardt, B.C., Hong, S.-J., Bernasconi, A., Bernasconi, N., 2015. Magnetic resonance imaging pattern learning in temporal lobe epilepsy: classification and prognostics. *Ann. Neurol.* 77 (3), 436–446 <http://www.ncbi.nlm.nih.gov/pubmed/25546153>. Accessed June 24, 2015.

Besson, P., Andermann, F., Dubeau, F., Bernasconi, A., 2008a. Small focal cortical dysplasia lesions are located at the bottom of a deep sulcus. *Brain* 131 (12), 3246–3255.

Besson, P., Bernasconi, N., Colliot, O., Evans, A., Bernasconi, A., 2008b. Surface-based texture and morphological analysis detects subtle cortical dysplasia. *Lecture Notes in Computer Science (including Subseries Lecture Notes in Artificial Intelligence and Lecture Notes in Bioinformatics)*. Vol 5241 LNCS, pp. 645–652.

Blümcke, I., Thom, M., Aronica, E., et al., 2011. The clinicopathologic spectrum of focal cortical dysplasias: a consensus classification proposed by an ad hoc Task Force of the ILAE Diagnostic Methods Commission. *Epilepsia* 52 (1), 158–174.

Bookstein, F.L., 2001. “Voxel-based morphometry” should not be used with imperfectly registered images. *NeuroImage* 14, 1454–1462. <http://dx.doi.org/10.1006/nimg.2001.0770>.

Bronen, R.A., Spencer, D.D., Fulbright, R.K., 2000. Cerebrospinal fluid cleft with cortical dimple: MR imaging marker for focal cortical dysgenesis. *Radiology* 214, 657–663. <http://dx.doi.org/10.1148/radiology.214.3.r00mr40657>.

Bruggemann, J.M., Wilke, M., Som, S.S., Bye, A.M.E., Bleasel, A., Lawson, J.A., 2007. Voxel-based morphometry in the detection of dysplasia and neoplasia in childhood epilepsy: combined grey/white matter analysis augments detection. *Epilepsy Res.* 77 (2–3), 93–101.

Bullmore, E., Sporns, O., 2009. Complex brain networks: graph theoretical analysis of structural and functional systems. *Nat. Rev. Neurosci.* 10 (3), 186–198. <http://dx.doi.org/10.1038/nrn2575>.

Butler, T., Ichise, M., Teich, A.F., et al., 2013. Imaging inflammation in a patient with epilepsy due to focal cortical dysplasia. *J. Neuroimaging* 23 (1), 129–131.

Caciagli, L., Bernhardt, B.C., Hong, S.-J., Bernasconi, A., Bernasconi, N., 2014. Functional network alterations and their structural substrate in drug-resistant epilepsy. *Front. Neurosci.* 8, 411. <http://dx.doi.org/10.3389/fnins.2014.00411>.

Cai, K., Haris, M., Singh, A., et al., 2012. Magnetic resonance imaging of glutamate. *Nat. Med.* 18 (2), 302–306. <http://dx.doi.org/10.1038/nm.2615>.

Chassoux, F., Daumas-Duport, C., 2013. Dysembryoplastic neuroepithelial tumors: where are we now. *Epilepsia* 54 (Suppl. 9), 129–134.

Colliot, O., Mansi, T., Bernasconi, N., Naessens, V., Klironomos, D., Bernasconi, A., 2005. Segmentation of focal cortical dysplasia lesions using a feature-based level set. *Lecture Notes in Computer Science (including Subseries Lecture Notes in Artificial Intelligence and Lecture Notes in Bioinformatics)*. Vol 3749 LNCS, pp. 375–382.

Colliot, O., Mansi, T., Bernasconi, N., Naessens, V., Klironomos, D., Bernasconi, A., 2006a. Segmentation of focal cortical dysplasia lesions on MRI using level set evolution. *NeuroImage* 32 (4), 1621–1630.

Colliot, O., Antel, S.B., Naessens, V.B., Bernasconi, N., Bernasconi, A., 2006b. In vivo profiling of focal cortical dysplasia on high-resolution MRI with computational models. *Epilepsia* 47 (1), 134–142.

Colliot, O., Bernasconi, N., Khalili, N., Antel, S.B., Naessens, V., Bernasconi, A., 2006c. Individual voxel-based analysis of gray matter in focal cortical dysplasia. *NeuroImage* 29 (1), 162–171.

Colombo, N., Tassi, L., Galli, C., et al., 2003. Focal cortical dysplasias: MR imaging, histopathologic, and clinical correlations in surgically treated patients with epilepsy. *AJNR Am. J. Neuroradiol.* 24 (4), 724–733.

Colombo, N., Salamon, N., Raybaud, C., Özkara, Ç., Barkovich, A.J., 2009. Imaging of malformations of cortical development. *Epileptic Disord.* 11 (3), 194–205.

Colombo, N., Tassi, L., Deleo, F., et al., 2012. Focal cortical dysplasia type IIa and IIb: MRI aspects in 118 cases proven by histopathology. *Neuroradiology* 54 (10), 1065–1077.

- Coras, R., Milesi, G., Zucca, I., et al., 2014. 7 T MRI features in control human hippocampus and hippocampal sclerosis: an ex vivo study with histologic correlations. *Epilepsia* 55 (12), 2003–2016.
- Cossu, M., Fuschillo, D., Bramero, M., et al., 2013. Epilepsy surgery of focal cortical dysplasia-associated tumors. *Epilepsia* 54 (Suppl. 9), 115–122.
- Dale, A.M., Fischl, B., Sereno, M.I., 1999a. Cortical surface-based analysis. I. Segmentation and surface reconstruction. *NeuroImage* 9 (2), 179–194 <http://www.ncbi.nlm.nih.gov/pubmed/9931268>. Accessed December 17, 2014.
- D'Alessandro, M., Esteller, R., Vachtsevanos, G., Hinson, A., Echaz, J., Litt, B., 2003. Epileptic seizure prediction using hybrid feature selection over multiple intracranial EEG electrode contacts: a report of four patients. *IEEE Trans. Biomed. Eng.* 50 (5), 603–615.
- Das, S.R., Avants, B.B., Grossman, M., Gee, J.C., 2009. Registration based cortical thickness measurement. *NeuroImage* 45 (3), 867–879. <http://dx.doi.org/10.1016/j.neuroimage.2008.12.016>.
- Davis, K.A., Nanga, R.P., Das, S., et al., 2015. Glutamate imaging (GluCEST) lateralizes epileptic foci in nonlesional temporal lobe epilepsy. *Sci. Transl. Med.* 7 (309) 309ra161.
- de la Roque, A.D., Oppenheim, C., Chassoux, F., et al., 2005. Diffusion tensor imaging of partial intractable epilepsy. *Eur. Radiol.* 15 (2), 279–285.
- Despotović, I., Segers, I., Platisa, L., et al., 2011. Automatic 3D graph cuts for brain cortex segmentation in patients with focal cortical dysplasia. *Conf. Proc. IEEE Eng. Med. Biol. Soc.* 2011, 7981–7984 <http://www.ncbi.nlm.nih.gov/pubmed/2256192>.
- Dinov, I., Lozev, K., Petrosyan, P., et al., 2010. Neuroimaging study designs, computational analyses and data provenance using the LONI pipeline. *PLoS One* 5 (9). <http://dx.doi.org/10.1371/journal.pone.0013070> e13070.
- Duyn, J.H., van Gelderen, P., Li, T.-Q., de Zwart, J.A., Koretsky, A.P., Fukunaga, M., 2007. High-field MRI of brain cortical substructure based on signal phase. *Proc. Natl. Acad. Sci. U. S. A.* 104 (28), 11796–11801.
- El Azami, M., Hammers, A., Costes, N., Lartizien, C., 2013. Computer aided diagnosis of intractable epilepsy with MRI imaging based on textural information. *Proceedings - 2013 3rd International Workshop on Pattern Recognition in Neuroimaging, PRNI 2013*, pp. 90–93.
- Englot, D.J., Hinkley, L.B., Kort, N.S., et al., 2015. Global and regional functional connectivity maps of neural oscillations in focal epilepsy. *Brain* awv130 <http://dx.doi.org/10.1093/brain/awv130>.
- Eriksson, S.H., Rugg-Gunn, F.J., Symms, M.R., Barker, G.J., Duncan, J.S., 2001. Diffusion tensor imaging in patients with epilepsy and malformations of cortical development. *Brain* 124, 617–626.
- Eriksson, S.H., Free, S.L., Thom, M., et al., 2009. Quantitative grey matter histological measures do not correlate with grey matter probability values from in vivo MRI in the temporal lobe. *J. Neurosci. Methods* 181 (1), 111–118.
- Fauser, S., Sisodiya, S.M., Martinian, L., et al., 2009. Multi-focal occurrence of cortical dysplasia in epilepsy patients. *Brain* 132 (8), 2079–2090.
- Feindel, K.W., 2013. Can we develop pathology-specific MRI contrast for “MR-negative” epilepsy? *Epilepsia* 54 (Suppl 2(2009)), 71–74 <http://www.ncbi.nlm.nih.gov/pubmed/23646976>.
- Fellah, S., Callot, V., Viout, P., et al., 2012. Epileptogenic brain lesions in children: the added-value of combined diffusion imaging and proton MR spectroscopy to the presurgical differential diagnosis. *Child's Nerv. Syst.* 28 (2), 273–282.
- Focke, N.K., Symms, M.R., Burdett, J.L., Duncan, J.S., 2008. Voxel-based analysis of whole brain FLAIR at 3 T detects focal cortical dysplasia. *Epilepsia* 49 (5), 786–793.
- Freeman, J.L., Coleman, L.T., Wellard, R.M., et al., 2004. MR imaging and spectroscopic study of epileptogenic hypothalamic hamartomas: analysis of 72 cases. *AJNR Am. J. Neuroradiol.* 25 (3), 450–462 <http://www.ncbi.nlm.nih.gov/pubmed/15037472>. Accessed January 21, 2015.
- Gardner, A.B., Krieger, A.M., Vachtsevanos, G., Litt, B., 2006. One-class novelty detection for seizure analysis from intracranial EEG. *J. Mach. Learn. Res.* 7, 1025–1044.
- Goffin, K., Van Paesschen, W., Dupont, P., et al., 2010. Anatomy-based reconstruction of FDG-PET images with implicit partial volume correction improves detection of hypometabolic regions in patients with epilepsy due to focal cortical dysplasia diagnosed on MRI. *Eur. J. Nucl. Med. Mol. Imaging* 37 (6), 1148–1155.
- Gross, D.W., Bastos, A., Beaulieu, C., 2005. Diffusion tensor imaging abnormalities in focal cortical dysplasia. *Can. J. Neurol. Sci.* 32 (4), 477–482.
- Guye, M., Bettus, G., Bartolomei, F., Cozzone, P.J., 2010. Graph theoretical analysis of structural and functional connectivity MRI in normal and pathological brain networks. *MAGMA* 23 (5–6), 409–421. <http://dx.doi.org/10.1007/s10334-010-0205-z>.
- Haralick, R.M., Shanmugam, K., Dinstein, I., 1973. Textural features for image classification. *IEEE Trans. Syst. Man, Cybern.* 3 (6), 610–621. <http://dx.doi.org/10.1109/TSMC.1973.4309314>.
- Hauptman, J.S., Mathern, G.W., 2012. Surgical treatment of epilepsy associated with cortical dysplasia: 2012 update. *Epilepsia* 53 (Suppl. 4), 98–104.
- Hofman, P.A.M., Fitt, G.J., Harvey, A.S., Kuzniecky, R.I., Jackson, G., 2011. Bottom-of-sulcus dysplasia: imaging features. *Am. J. Roentgenol.* 196 (4), 881–885.
- Holmes, M.D., Tucker, D.M., 2013. Identifying the epileptic network. *Front. Neurol.* 4, 84. <http://dx.doi.org/10.3389/fneur.2013.00084>.
- Hong, S.J., Kim, H., Schrader, D., Bernasconi, N., Bernhardt, B.C., Bernasconi, A., 2014. Automated detection of cortical dysplasia type II in MRI-negative epilepsy. *Neurology* 83 (1), 48–55.
- Huppertz, H.J., Grimm, C., Fauser, S., et al., 2005. Enhanced visualization of blurred gray-white matter junctions in focal cortical dysplasia by voxel-based 3D MRI analysis. *Epilepsia Res.* 67 (1–2), 35–50.
- Huppertz, H.J., Wellmer, J., Staack, A.M., Altenmüller, D.M., Urbach, H., Kröll, J., 2008. Voxel-based 3D MRI analysis helps to detect subtle forms of subcortical band heterotopia. *Epilepsia* 49 (5), 772–785.
- Jackson, G.D., Badawy, R.A.B., 2011. Selecting patients for epilepsy surgery: identifying a structural lesion. *Epilepsy Behav.* 20 (2), 182–189.
- Jeong, W., Jin, S.-H., Kim, M., Kim, J.S., Chung, C.K., 2014. Abnormal functional brain network in epilepsy patients with focal cortical dysplasia. *Epilepsia Res.* 108 (9), 1618–1626. <http://dx.doi.org/10.1016/j.eplepsyres.2014.09.006>.
- Jiménez Del Toro, O.A., Foncubierta-Rodríguez, A., Vargas Gómez, M.I., Müller, H., Depeursinge, A., 2013. Epileptogenic lesion quantification in MRI using contralateral 3D texture comparisons. *Lecture Notes in Computer Science (including Subseries Lecture Notes in Artificial Intelligence and Lecture Notes in Bioinformatics)*. Vol 8150 LNCS, pp. 353–360.
- Kim, J.S., Singh, V., Lee, J.K., et al., 2005. Automated 3-D extraction and evaluation of the inner and outer cortical surfaces using a Laplacian map and partial volume effect classification. *NeuroImage* 27 (1), 210–221. <http://dx.doi.org/10.1016/j.neuroimage.2005.03.036>.
- Kim, H., Mansi, T., Bernasconi, N., 2013. Disentangling hippocampal shape anomalies in epilepsy. *Front. Neurol.* 4, 131 <http://www.pubmedcentral.nih.gov/articlerender.fcgi?artid=3769634&tool=pmcentrez&rendertype=abstract> Accessed January 25, 2016.
- Kini, L.G., Davis, K.A., Wagenaar, J.B., 2015. Data integration: Combined imaging and electrophysiology data in the cloud. *NeuroImage* 124 (Pt B), 1175–1181.
- Klatt, J., Feldwisch-Drentrup, H., Ihle, M., 2012. The EPILEPSIAE database: an extensive electroencephalography database of epilepsy patients. *Epilepsia* 53 (9), 1669–1676. <http://dx.doi.org/10.1111/j.1528-1167.2012.03564.x>.
- Knake, S., Triantafyllou, C., Wald, L.L., et al., 2005. 3 T phased array MRI improves the presurgical evaluation in focal epilepsies: a prospective study. *Neurology* 65 (7), 1026–1031.
- Koeppe, M.J., Woermann, F.G., 2005. Imaging structure and function in refractory focal epilepsy. *Lancet Neurol.* 4 (1), 42–53 <http://www.ncbi.nlm.nih.gov/pubmed/15620856>. Accessed January 20, 2015.
- Krsek, P., Hajek, M., Dezortova, M., et al., 2007. 1H MR spectroscopic imaging in patients with MRI-negative extratemporal epilepsy: correlation with ictal onset zone and histopathology. *Eur. Radiol.* 17 (8), 2126–2135.
- Krsek, P., Maton, B., Korman, B., et al., 2008. Different features of histopathological subtypes of pediatric focal cortical dysplasia. *Ann. Neurol.* 63 (6), 758–769.
- Krsek, P., Pieper, T., Karlmeier, A., et al., 2009. Different presurgical characteristics and seizure outcomes in children with focal cortical dysplasia type I or II. *Epilepsia* 50 (1), 125–137.
- Krsek, P., Kudr, M., Jahodova, A., et al., 2013. Localizing value of ictal SPECT is comparable to MRI and EEG in children with focal cortical dysplasia. *Epilepsia* 54, 351–358. <http://dx.doi.org/10.1111/epi.12059>.
- Kumar, A., Asano, E., Chugani, H.T., 2011. Tryptophan PET for tracer localization of epileptogenic brain regions: clinical studies. *Biomark. Med.* 5 (5), 577–584.
- Kuzniecky, R., 2004. Clinical applications of MR spectroscopy in epilepsy. *Neuroimaging Clin. N. Am.* 14 (3), 507–516.
- Kuzniecky, R., Hetherington, H., Pan, J., et al., 1997. Proton spectroscopic imaging at 4.1 tesla in patients with malformations of cortical development and epilepsy. *Neurology* 48, 1018–1024. <http://dx.doi.org/10.1212/WNL.48.4.1018>.
- Kwan, P., Schachter, S.C., Brodie, M.J., 2011. Drug-resistant epilepsy. *N. Engl. J. Med.* 365 (10), 919–926 <http://www.ncbi.nlm.nih.gov/pubmed/21899452>. Accessed January 21, 2015.
- Kwong, K.K., Belliveau, J.W., Chesler, D.A., et al., 1992. Dynamic magnetic resonance imaging of human brain activity during primary sensory stimulation. *Proc. Natl. Acad. Sci. U. S. A.* 89, 5675–5679. <http://dx.doi.org/10.1073/pnas.89.12.5675>.
- Leach, J.L., Miles, L., Henkel, D.M., et al., 2014. Magnetic resonance imaging abnormalities in the resection region correlate with histopathological type, gliosis extent, and post-operative outcome in pediatric cortical dysplasia. *J. Neurosurg. Pediatr.* 14 (1), 68–80 <http://www.ncbi.nlm.nih.gov/pubmed/24866708>.
- Lee, S.K., Kim, D.J., Mori, S., et al., 2004. Diffusion tensor MRI visualizes decreased subcortical fiber connectivity in focal cortical dysplasia. *NeuroImage* 22 (4), 1826–1829.
- Lerner, J.T., Salamon, N., Hauptman, J.S., et al., 2009. Assessment and surgical outcomes for mild type I and severe type II cortical dysplasia: a critical review and the UCLA experience. *Epilepsia* 50 (6), 1310–1335.
- MacDonald, D., Kabani, N., Avis, D., Evans, A.C., 2000. Automated 3-D extraction of inner and outer surfaces of cerebral cortex from MRI. *NeuroImage* 12 (3), 340–356. <http://dx.doi.org/10.1006/nimg.1999.0534>.
- Madan, N., Grant, P.E., 2009. New directions in clinical imaging of cortical dysplasias. *Epilepsia* 50 (Suppl. 9), 9–18 <http://www.ncbi.nlm.nih.gov/pubmed/19761449>. Accessed January 21, 2015.
- Mellerio, C., Labeyrie, M., Chassoux, F., et al., 2012. Optimizing MR imaging detection of type 2 focal cortical dysplasia: best criteria for clinical practice. *AJNR Am. J. Neuroradiol.* 33 (10), 1932–1938. <http://dx.doi.org/10.3174/ajnr.A3081>.
- Mellerio, C., Labeyrie, M.A., Chassoux, F., et al., 2014a. 3 T MRI improves the detection of transmantle sign in type 2 focal cortical dysplasia. *Epilepsia* 55 (1), 117–122.
- Mellerio, C., Roca, P., Chassoux, F., et al., 2014b. The power button sign: a newly described Central Sulcal pattern on surface rendering MR Images of type 2 focal cortical dysplasia. *Radiology* 140773. <http://dx.doi.org/10.1148/radiol.14140773>.
- Miyata, H., Hori, T., Vinters, H.V., 2013. Surgical pathology of epilepsy-associated non-neoplastic cerebral lesions: a brief introduction with special reference to hippocampal sclerosis and focal cortical dysplasia. *Neuropathology* 33 (4), 442–458. <http://dx.doi.org/10.1111/neup.12028>.
- Moeller, F., Tyvaert, L., Nguyen, D.K., et al., 2009. EEG-fMRI: adding to standard evaluations of patients with nonlesional frontal lobe epilepsy. *Neurology* 73 (23), 2023–2030.
- Mueller, S.G., Laxer, K.D., Barakos, J.A., et al., 2005. Metabolic characteristics of cortical malformations causing epilepsy. *J. Neurol.* 252 (9), 1082–1092.
- Mühlbner, A., Coras, R., Kobow, K., et al., 2012. Neuropathologic measurements in focal cortical dysplasias: validation of the ILAE 2011 classification system and diagnostic implications for MRI. *Acta Neuropathol.* 123 (2), 259–272.



- Mukae, N., Suzuki, S.O., Morioka, T., et al., 2014. ILAE focal cortical dysplasia type IIc in the ictal onset zone in epileptic patients with solitary meningioangiomatosis. *Epileptic Disord.* 16 (4), 533–539. <http://dx.doi.org/10.1684/epd.2014.0695>.
- Nain, D., Haker, S., Bobick, A., Tannenbaum, A., 2007. Multiscale 3-D shape representation and segmentation using spherical wavelets. *IEEE Trans. Med. Imaging* 26 (4), 598–618. <http://dx.doi.org/10.1109/TMI.2007.893284>.
- Najm, I.M., Bingaman, W.E., Lüders, H.O., 2002. The use of subdural grids in the management of focal malformations due to abnormal cortical development. *Neurosurg. Clin. N. Am.* 13 (1), 87–92.
- Natsume, J., Bernasconi, N., Aghakhani, Y., et al., 2008.  $\alpha$ -[11C]methyl-L-tryptophan uptake in patients with periventricular nodular heterotopia and epilepsy. *Epilepsia* 49 (5), 826–831.
- Okonma, S.V., Blount, J.P., Gross, R.E., 2011. Planning extent of resection in epilepsy: limited versus large resections. *Epilepsy Behav.* 20 (2), 233–240.
- Pan, J.W., Williamson, A., Cavus, I., et al., 2008. Neurometabolism in human epilepsy. *Epilepsia* Vol 49, 31–41.
- Pan, J.W., Duckrow, R.B., Gerrard, J., et al., 2013. 7 T MR spectroscopic imaging in the localization of surgical epilepsy. *Epilepsia* 54 (9), 1668–1678.
- Papayannis, C.E., Consalvo, D., Kauffman, M.A., et al., 2012. Malformations of cortical development and epilepsy in adult patients. *Seizure* 21, 377–384. <http://dx.doi.org/10.1016/j.seizure.2012.03.009>.
- Pardoe, H., Kuzniecky, R., 2014. Advanced imaging techniques in the diagnosis of nonlesional epilepsy: MRI, MRS, PET, and SPECT. *Epilepsy Curr.* 14 (3), 121–124. <http://dx.doi.org/10.5698/1535-7597-14.3.121>.
- Pascher, B., Kröll, J., Mothersill, I., Krämer, G., Huppertz, H.J., 2013. Automated morphometric magnetic resonance imaging analysis for the detection of periventricular nodular heterotopia. *Epilepsia* 54 (2), 305–313.
- Pedersen, M., Omidvarnia, A.H., Walz, J.M., Jackson, G.D., 2015. Increased segregation of brain networks in focal epilepsy: an fMRI graph theory finding. *NeuroImage: Clin.* 8, 536–542. <http://dx.doi.org/10.1016/j.nicl.2015.05.009>.
- Pienaar, R., Fischl, B., Caviness, V., Makris, N., Grant, P.E., 2008. A methodology for analyzing curvature in the developing brain from preterm to adult. *Int. J. Imaging Syst. Technol.* 18 (1), 42–68. <http://www.pubmedcentral.nih.gov/articlerender.fcgi?artid=2779548&tool=pmcentrez&rendertype=abstract> Accessed January 25, 2016.
- Ponten, S.C., Bartolomei, F., Stam, C.J., 2007. Small-world networks and epilepsy: graph theoretical analysis of intracerebrally recorded mesial temporal lobe seizures. *Clin. Neurophysiol.* 118 (4), 918–927. <http://dx.doi.org/10.1016/j.clinph.2006.12.002>.
- Princich, J.P., Consalvo, D., Kauffman, M., Seifer, G., Blenkman, A., Kochen, S., 2012. Contribution of diffusion tensor magnetic resonance imaging to the diagnosis of focal cortical dysplasias. *Rev. Neurol.* 54 (8), 453–460.
- Qu, X., Kumcu, A., Platasa, L., et al., 2013. Blur estimation at the gray-white matter boundary for focal cortical dysplasia in magnetic resonance imaging. 35th Annual International Conference of the IEEE Engineering in Medicine and Biology Society (EMBC 2013). [http://www.researchgate.net/publication/264713589\\_Blur\\_estimation\\_at\\_the\\_gray-white\\_matter\\_boundary\\_for\\_focal\\_cortical\\_dysplasia\\_in\\_magnetic\\_resonance\\_imaging](http://www.researchgate.net/publication/264713589_Blur_estimation_at_the_gray-white_matter_boundary_for_focal_cortical_dysplasia_in_magnetic_resonance_imaging) Accessed January 20, 2015.
- Raymond AA, Fish DR, Sisodiya SM, Alsanjari N, Stevens JM, Shorvon SD. Abnormalities of gyration, heterotopias, tuberous sclerosis, focal cortical dysplasia, microdysgenesis, dysembryoplastic neuroepithelial tumour and dysgenesis of the archicortex in epilepsy. Clinical, EEG and neuroimaging features in 100 adult patients. *Brain.* 1995; 118 (Pt 3:629–660). <http://www.ncbi.nlm.nih.gov/pubmed/7600083>. Accessed January 21, 2015.
- Rieger, B., van Vliet, L.J., 2002. Curvature of n-dimensional space curves in grey-value images. *IEEE Trans. Image Process.* 11 (7), 738–745. <http://dx.doi.org/10.1109/TIP.2002.800885>.
- Rieger, B., Timmermans, F.J., van Vliet, L.J., Verbeek, P.W., 2004. On curvature estimation of ISO surfaces in 3D gray-value images and the computation of shape descriptors. *IEEE Trans. Pattern. Anal. Mach. Intell.* 26 (8), 1088–1094. <http://dx.doi.org/10.1109/TPAMI.2004.50>.
- Rivière, D., Mangin, J.F., Papadopoulos-Orfanos, D., Martinez, J.M., Frouin, V., Régis, J., 2002. Automatic recognition of cortical sulci of the human brain using a congregation of neural networks. *Med. Image Anal.* 6, 77–92. [http://dx.doi.org/10.1016/S1361-8415\(02\)00052-X](http://dx.doi.org/10.1016/S1361-8415(02)00052-X).
- Rosenow, F., Lüders, H., 2001. Presurgical evaluation of epilepsy. *Brain* 124, 1683–1700. <http://dx.doi.org/10.4103/1817-1745.40593>.
- Rowland, N.C., Englot, D.J., Cage, T.A., Sughrue, M.E., Barbaro, N.M., Chang, E.F., 2012. A meta-analysis of predictors of seizure freedom in the surgical management of focal cortical dysplasia. *J. Neurosurg.* 116 (5), 1035–1041.
- Rugg-Gunn, F.J., Eriksson, S.H., Symms, M.R., Barker, G.J., Duncan, J.S., 2001. Diffusion tensor imaging of cryptogenic and acquired partial epilepsies. *Brain* 124, 627–636.
- Rugg-Gunn, F.J., Eriksson, S.H., Boulby, P.A., Symms, M.R., Barker, G.J., Duncan, J.S., 2003. Magnetization transfer imaging in focal epilepsy. *Neurology* 60 (10), 1638–1645.
- Rugg-Gunn, F.J., Boulby, P.A., Symms, M.R., Barker, G.J., Duncan, J.S., 2005. Whole-brain T2 mapping demonstrates occult abnormalities in focal epilepsy. *Neurology* 64 (2), 318–325.
- Rugg-Gunn, F.J., Boulby, P.A., Symms, M.R., Barker, G.J., Duncan, J.S., 2006. Imaging the neocortex in epilepsy with double inversion recovery imaging. *NeuroImage* 31 (1), 39–50.
- Salamon, N., Kung, J., Shaw, S.J., et al., 2008. FDG-PET/MRI coregistration improves detection of cortical dysplasia in patients with epilepsy. *Neurology* 71 (20), 1594–1601. <http://dx.doi.org/10.1212/01.wnl.0000334752.41807.2f>.
- Schachter S. Overview of the management of epilepsy in adults. *UpToDate, Inc.* 2015. <http://www.uptodate.com/contents/overview-of-the-management-of-epilepsy-in-adults>. Accessed January 20, 2015.
- Schwartzkroin, P.A., Wenzel, H.J., 2012. Are developmental dysplastic lesions epileptogenic? *Epilepsia* 53 (Suppl. 1), 35–44.
- Shen, T.W., Hsin, Y.L., Harnod, T., 2011. Using fuzzy C-means index matrix to depict for the focal cortical dysplasia region on T1 brain MRI images. 2011 5th International Symposium on Medical Information and Communication Technology, ISMICT 2011, pp. 117–121.
- Shultz, S.R., O'Brien, T.J., Stefanidou, M., Kuzniecky, R.I., 2014. Neuroimaging the epileptogenic process. *Neurotherapeutics* 11 (2), 347–357.
- Sisodiya SM. Surgery for malformations of cortical development causing epilepsy. *Brain.* 2000;123 (Pt 6:1075–1091). <http://www.ncbi.nlm.nih.gov/pubmed/10825348>. Accessed January 21, 2015.
- Sosunov, A.A., McGovern, R.A., Mikell, C.B., et al., 2015. Epileptogenic but MRI-normal peritubular tissue in tuberous sclerosis complex contains tuber-specific abnormalities. *Acta Neuropathol. Commun.* 3, 17. <http://dx.doi.org/10.1186/s40478-015-0191-5>.
- Speck, O., Tempelmann, C., Matzen, J., Huppertz, H., 2009. Morphometric MRI analysis based on high resolution 3D imaging at 7 Tesla highlights focal cortical dysplasia in epilepsy. Proceedings 17th Scientific Meeting, International Society for Magnetic Resonance in Medicine. Vol Honolulu, p. 970 (/MyPathway2009/0970).
- Strumia, M., Ramantani, G., Mader, I., Henning, J., Bai, L., Hadjidemetriou, S., 2013. Analysis of structural MRI data for the localisation of focal cortical dysplasia in epilepsy. In: Drechsler, K., Erdt, M., Linguraru, M.G., et al. (Eds.), *Clinical Image-Based Procedures. From Planning to Intervention*, 7761st ed. Lecture Notes in Computer Science, Berlin, pp. 25–31. [http://link.springer.com/chapter/10.1007%2F978-3-642-38079-2\\_4](http://link.springer.com/chapter/10.1007%2F978-3-642-38079-2_4).
- Télez-Zenteno, J.F., Ronquillo, L.H., Moien-Afshari, F., Wiebe, S., 2010. Surgical outcomes in lesional and non-lesional epilepsy: a systematic review and meta-analysis. *Epilepsy Res.* 89 (2–3), 310–318.
- Tenney, J.R., Rozhkov, L., Horn, P., Miles, L., Miles, M.V., 2014. Cerebral glucose hypometabolism is associated with mitochondrial dysfunction in patients with intractable epilepsy and cortical dysplasia. *Epilepsia*.
- Thesen, T., Quinn, B.T., Carlson, C., et al., 2011. Detection of epileptogenic cortical malformations with surface-based MRI morphometry. *PLoS ONE* 6 (2), e16430. <http://dx.doi.org/10.1371/journal.pone.0016430>.
- Thom, M., Martinian, L., Sen, A., Cross, J.H., Harding, B.N., Sisodiya, S.M., 2005. Cortical neuronal densities and lamination in focal cortical dysplasia. *Acta Neuropathol.* 110 (4), 383–392.
- Thornton, R., Vulliemoz, S., Rodionov, R., et al., 2011. Epileptic networks in focal cortical dysplasia revealed using electroencephalography-functional magnetic resonance imaging. *Ann. Neurol.* 70 (5), 822–837.
- Toledo, M., Sarria-Estrada, S., Quintana, M., et al., 2013. 3 Tesla MR imaging in adults with focal onset epilepsy. *Clin. Neurol. Neurosurg.* 115 (10), 2111–2116.
- Tuch, D.S., Reese, T.G., Wiegell, M.R., Makris, N., Belliveau, J.W., Wedeen, V.J., 2002. High angular resolution diffusion imaging reveals intravoxel white matter fiber heterogeneity. *Magn. Reson. Med.* 48 (4), 577–582. <http://dx.doi.org/10.1002/mrm.10268>.
- Tustison, N.J., Altes, T.A., Song, G., De Lange, E.E., Mugler, J.P., Gee, J.C., 2010. Feature analysis of hyperpolarized helium-3 pulmonary MRI: a study of asthmatics versus nonasthmatics. *Magn. Reson. Med.* 63 (6), 1448–1455.
- Tustison, N.J., Cook, P.A., Klein, A., et al., 2014. Large-scale evaluation of ANTs and FreeSurfer cortical thickness measurements. *NeuroImage* 99, 166–179. <http://www.ncbi.nlm.nih.gov/pubmed/24879923>. Accessed November 19, 2014.
- van Dießen, E., Diederer, S.J.H., Braun, K.P.J., Jansen, F.E., Stam, C.J., 2013. Functional and structural brain networks in epilepsy: what have we learned? *Epilepsia* 54 (11), 1855–1865. <http://dx.doi.org/10.1111/epi.12350>.
- Van Essen, D.C., Drury, H.A., 1997. Structural and functional analyses of human cerebral cortex using a surface-based atlas. *J. Neurosci.* 17 (18), 7079–7102. <http://www.ncbi.nlm.nih.gov/pubmed/9278543>. Accessed January 25, 2016.
- Van Essen, D.C., Smith, S.M., Barch, D.M., Behrens, T.E.J., Yacoub, E., Ugurbil, K., for the WU-Minn HCP Consortium, 2013. The WU-Minn Human Connectome Project: An overview. *NeuroImage* 80, 62–79.
- Van Essen, D.C., Dierker, D., Snyder, A.Z., Raichle, M.E., Reiss, A.L., Korenberg, J., 2006. Symmetry of cortical folding abnormalities in Williams syndrome revealed by surface-based analyses. *J. Neurosci.* 26 (20), 5470–5483. <http://dx.doi.org/10.1523/JNEUROSCI.4154-05.2006>.
- Velez-Ruiz, N.J., Klein, J.P., 2012. Neuroimaging in the evaluation of epilepsy. *Semin. Neurol.* 32 (4), 361–373.
- Wagner, J., Weber, B., Urbach, H., Elger, C.E., Huppertz, H.-J., 2011. Morphometric MRI analysis improves detection of focal cortical dysplasia type II. *Brain* 134 (Pt 10), 2844–2854. <http://www.ncbi.nlm.nih.gov/pubmed/21893591>.
- Wang, S., Summers, R.M., 2012. Machine learning and radiology. *Med. Image Anal.* 16 (5), 933–951.
- Wang, Z.I., Jones, S.E., Ristic, A.J., et al., 2012. Voxel-based morphometric MRI post-processing in MRI-negative focal cortical dysplasia followed by simultaneously recorded MEG and stereo-EEG. *Epilepsy Res.* 100 (1–2), 188–193.
- Wang, Z.I., Alexopoulos, A.V., Jones, S.E., Jaisani, Z., Najm, I.M., Prayson, R.A., 2013. The pathology of magnetic-resonance-imaging-negative epilepsy. *Mod. Pathol.* 26 (8), 1051–1058. <http://www.ncbi.nlm.nih.gov/pubmed/23558575>.
- Wang, Z.I., Ristic, A.J., Wong, C.H., et al., 2013. Neuroimaging characteristics of MRI-negative orbitofrontal epilepsy with focus on voxel-based morphometric MRI postprocessing. *Epilepsia* 54 (12), 2195–2203.
- Wang, Z.I., Jones, S.E., Jaisani, Z., et al., 2015. Voxel-based morphometric magnetic resonance imaging (MRI) postprocessing in MRI-negative epilepsies. *Ann. Neurol.* 77 (6), 1060–1075. <http://dx.doi.org/10.1002/ana.24407>.
- Weaver, K.E., Chaovalitwongse, W.A., Novotny, E.J., Poliakov, A., Grabowski, T.G., Ojemann, J.G., 2013. Local functional connectivity as a pre-surgical tool for seizure focus identification in non-lesion, focal epilepsy. *Front. Neurol.* 4, 43. <http://dx.doi.org/10.3389/fneur.2013.00043>.
- Wellmer, J., Quesada, C.M., Rothe, L., Elger, C.E., Bien, C.G., Urbach, H., 2013. Proposal for a magnetic resonance imaging protocol for the detection of epileptogenic lesions at



- early outpatient stages. *Epilepsia* 54 (11), 1977–1987. <http://dx.doi.org/10.1111/epi.12375>.
- Widjaja, E., Blaser, S., Miller, E., et al., 2007. Evaluation of subcortical white matter and deep white matter tracts in malformations of cortical development. *Epilepsia* 48 (8), 1460–1469.
- Widjaja, E., Otsubo, H., Raybaud, C., et al., 2008. Characteristics of MEG and MRI between Taylor's focal cortical dysplasia (type II) and other cortical dysplasia: surgical outcome after complete resection of MEG spike source and MR lesion in pediatric cortical dysplasia. *Epilepsy Res.* 82 (2–3), 147–155. <http://dx.doi.org/10.1016/j.epilepsyres.2008.07.013>.
- Wilenius, J., Medvedovsky, M., Gaily, E., et al., 2013. Interictal MEG reveals focal cortical dysplasias: special focus on patients with no visible MRI lesions. *Epilepsy Res.* 105 (3), 337–348 <http://www.ncbi.nlm.nih.gov/pubmed/23587673>. Accessed March 17, 2015.
- Wilke, M., Kassubek, J., Ziyeh, S., Schulze-Bonhage, A., Huppertz, H.J., 2003. Automated detection of gray matter malformations using optimized voxel-based morphometry: a systematic approach. *NeuroImage* 20 (1), 330–343.
- Winston, G.P., Micallef, C., Symms, M.R., Alexander, D.C., Duncan, J.S., Zhang, H., 2014. Advanced diffusion imaging sequences could aid assessing patients with focal cortical dysplasia and epilepsy. *Epilepsy Res.* 108 (2), 336–339.
- Wisco, J.J., Kuperberg, G., Manoach, D., et al., 2007. Abnormal cortical folding patterns within Broca's area in schizophrenia: evidence from structural MRI. *Schizophr. Res.* 94 (1–3), 317–327. <http://dx.doi.org/10.1016/j.schres.2007.03.031>.
- Xiaoxia, Qu, Platisa, L., Despotovic, I., et al., 2014. Estimating blur at the brain gray-white matter boundary for FCD detection in MRI. *Conf Proc. Annu Int Conf IEEE Eng Med Biol Soc IEEE Eng Med Biol Soc Annu Conf.* 2014, pp. 3321–3324 <http://www.ncbi.nlm.nih.gov/pubmed/25570701>. Accessed January 20, 2015.
- Yang, C.A., Kaveh, M., Erickson, B.J., 2011. Automated detection of Focal Cortical Dysplasia lesions on T1-weighted MRI using volume-based distributional features. *Proceedings – International Symposium on Biomedical Imaging*, pp. 865–870 <http://dx.doi.org/10.1109/ISBI.2011.5872541>.
- Yu, P., Grant, P.E., Qi, Y., et al., 2007. Cortical surface shape analysis based on spherical wavelets. *IEEE Trans. Med. Imaging* 26 (4), 582–597. <http://dx.doi.org/10.1109/TMI.2007.892499>.
- Zhang, J., Liu, W., Chen, H., et al., 2014. Multimodal neuroimaging in presurgical evaluation of drug-resistant epilepsy. *NeuroImage Clin.* 4, 35–44 <http://www.pubmedcentral.nih.gov/articlerender.fcgi?artid=3840005&tool=pmcentrez&rendertype=abstract>. Accessed January 21, 2015.
- Zijlmans, M., Huiskamp, G., Hersevoort, M., Seppenwoolde, J.H., Van Huffelen, A.C., Leijten, F.S.S., 2007. EEG-fMRI in the preoperative work-up for epilepsy surgery. *Brain* 130 (9), 2343–2353.