

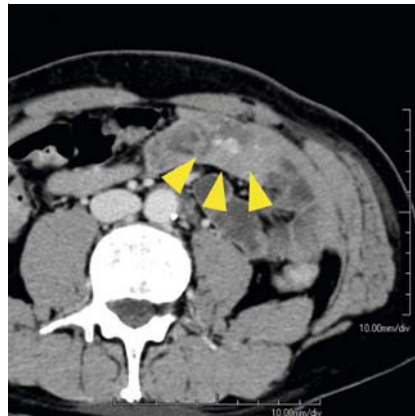


Eradication of angiomas by nylon loop snare ligation under total enteroscopy, in disseminated intravascular coagulation associated with blue rubber bleb nevus syndrome

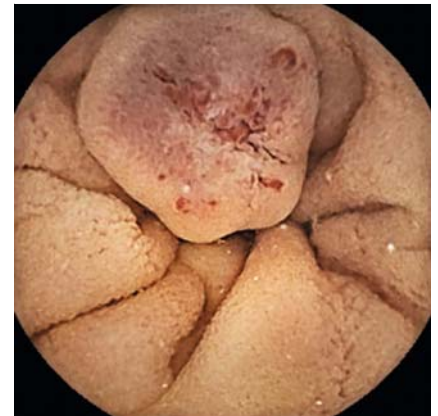Blue rubber bleb nevus syndrome (BRBNS) is a rare congenital disease characterized by multiple systemic venous malformations on the skin and internal organs, including the gastrointestinal (GI) tract [1]. The GI lesions sometimes cause severe bleeding episodes, which require urgent care. In addition, BRBNS is complicated by focal and systemic disseminated intravascular coagulation, leading to hemorrhagic diathesis, which makes physicians decide against surgical procedures or endoscopic sclerotherapy [2].

A 57-year-old man who had previously been diagnosed with BRBNS complicated by disseminated intravascular coagulation, complained of repeated melena. Enhanced computed tomography revealed multiple vascular malformations in the intestine (► **Fig. 1**), and capsule endoscopy (PillCam SB3; Covidien Japan, Tokyo, Japan) demonstrated numerous angiomas in the intestine (► **Fig. 2**). He received conservative therapy with transfusions, iron supplementation, and antihyperfibrinolytic treatment for disseminated intravascular coagulation, including direct oral anticoagulants, without improvement. Apixaban was also ineffective in controlling GI bleeding and anemia, and the patient was referred to our department.

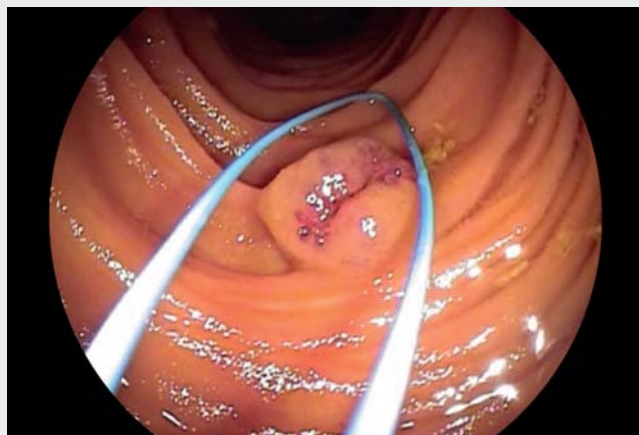
Because apixaban prevented intravascular consumptive coagulopathy that might increase the risk of bleeding paradoxically, we decided to perform nylon loop snare ligation (PolyLoop; Olympus, Tokyo, Japan) [3,4] under anticoagulant therapy with apixaban. The patient underwent retrograde and antero- grade double-balloon enteroscopy (DBE) (EN-450T5/W; Fujifilm, Tokyo, Japan) to achieve total enteroscopy [5] and loop ligation for every possible lesion (two and eight lesions; retrograde and antero- grade, respectively) (► **Video 1**). Subsequent capsule endoscopy revealed resi-



► **Fig. 1** Dynamic contrast-enhanced computed tomography (portal-venous phase) in a patient with blue rubber bleb nevus syndrome complicated by disseminated intravascular coagulation, showing multiple enhanced nodules in the intestine (yellow arrowheads).



► **Fig. 2** Capsule endoscopy identified jejunal angiomas. The surface of the angiomas is erosive, and abnormally dilated vessels are visible.

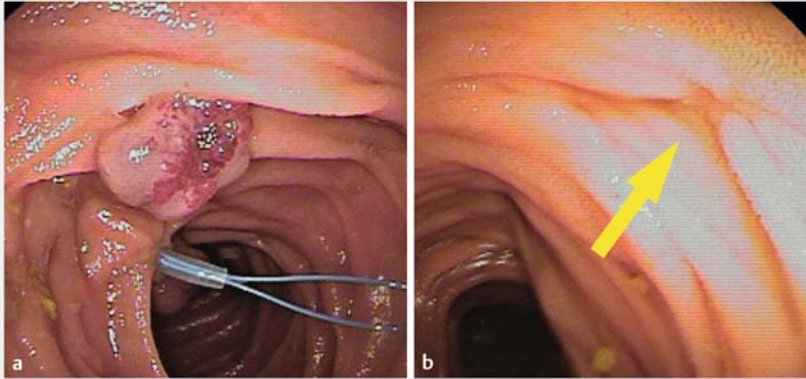


► **Video 1** Nylon loop snare ligation of small-bowel venous malformations in a patient with blue rubber bleb nevus syndrome complicated by disseminated intravascular coagulation.



dual lesions in the jejunum. Therefore, we performed additional antero- grade DBE (ligation for three lesions) and accomplished radical removal of potential bleeding sources in the small bowel (► **Fig. 3**). In the series of endoscopic in-

terventions, we experienced no complications, including that of severe bleeding. During the 2-year follow-up, the patient did not complain of anemia or melena.



▶ Fig. 3 Anterograde double-balloon enteroscopy identified the jejunal angioma that was a possible cause of gastrointestinal bleeding. **a** The surface of the angioma appears hyperemic and erosive. **b** The same location 3 weeks after ligation. The angioma has completely disappeared (yellow arrow).

Nylon loop snare ligation facilitated by DBE is a curative and safe tool to treat small-bowel lesions in BRBNS under anticoagulant therapy.

Endoscopy_UCTN_Code_TTT_1AP_2AD



Acknowledgments

We thank Jane Charbonneau, DVM, from Edanz (<https://jp.edanz.com/ac>) for editing a draft of this manuscript.

Competing interests

The authors declare that they have no conflict of interest.

The authors

Hidetoshi Nakagawa  **Hajime Takatori**, **Tomoyuki Hayashi**  **Shinya Yamada**, **Kuniaki Arai**, **Taro Yamashita**, **Eishiro Mizukoshi**
Department of Gastroenterology, Kanazawa University Hospital, Ishikawa, Japan

Corresponding author

Hajime Takatori, MD

Department of Gastroenterology, Kanazawa University Hospital, 13-1 Takaramachi, Kanazawa, Ishikawa 920-8641, Japan
Fax: 81-76-2344250
takatori@m-kanazawa.jp

References

- [1] Bean W. Vascular spiders and related lesions of the skin. *AMA Arch Derm* 1959; 80: 131. doi:10.1001/arch-derm.1959.01560190133034
- [2] Yamada S, Arahata M, Morishita E et al. Blue rubber bleb nevus syndrome complicated by enhanced-fibrinolytic-type DIC: a case report. *Ann Vasc Dis* 2021; 14: 252–255
- [3] Jin J, Pan J, Zhu L. Therapy for hemangiomas of blue rubber bleb nevus syndrome in the small intestine with single balloon endoscopy. *Dig Endosc* 2015; 27: 781–781
- [4] Campos-Murguía A, Zamora-Nava LE. An endoscopic multimodal approach in a patient with blue rubber bleb nevus syndrome and acute bleeding. *Endoscopy* 2021; 53: E338–E339

- [5] Yamamoto H, Sekine Y, Sato Y et al. Total enteroscopy with a nonsurgical steerable double-balloon method. *Gastrointest Endosc* 2001; 53: 216–220

Bibliography

Endoscopy 2023; 55: E137–E138

DOI 10.1055/a-1953-7026

ISSN 0013-726X

published online 28.10.2022

© 2022. The Author(s).

This is an open access article published by Thieme under the terms of the Creative Commons Attribution-NonDerivative-NonCommercial License, permitting copying and reproduction so long as the original work is given appropriate credit. Contents may not be used for commercial purposes, or adapted, remixed, transformed or built upon. (<https://creativecommons.org/licenses/by-nc-nd/4.0/>)

Georg Thieme Verlag KG, Rüdigerstraße 14, 70469 Stuttgart, Germany



ENDOSCOPY E-VIDEOS

<https://eref.thieme.de/e-videos>



Endoscopy E-Videos is an open access online section, reporting on interesting cases

and new techniques in gastroenterological endoscopy. All papers include a high quality video and all contributions are freely accessible online. Processing charges apply (currently EUR 375), discounts and waivers acc. to HINARI are available.

This section has its own submission website at

<https://mc.manuscriptcentral.com/e-videos>