

# Role of sclerotherapy in management of vascular malformation in the maxillofacial region: Our experience

### ABSTRACT

The management of vascular anomalies is an extremely challenging area and is as divergent as the nature of lesions. Traditionally, embolization with the resection of the lesion has been used. The purpose of this report is to present cases treated successfully using sclerosing solution injections alone. Management of the vascular malformation using intralesional injections of sodium tetradecyl sulfate to the lesion is discussed. The procedure was performed two times at 2 weeks interval. Complete resolution of the lesion was found following sclerotherapy. Conservative interventional management using intralesional injection of sclerosing solution was successful in treating vascular anomaly.

**Keywords:** Sclerotherapy, setrol, vascular malformation

### INTRODUCTION

Vascular anomalies are a wide range of conditions that result in an abnormal number, structure, or position of blood vessels. Many classifications have been proposed, but James Wardrop first recognized the differences between true hemangiomas and the less common vascular malformations (VMs) in 1818.<sup>[1]</sup>

VMs remain difficult both diagnostically and therapeutically despite continued efforts over the decades. This is chiefly due to their variety, with a wide range of clinical presentations from a simple birthmark to a life-threatening condition containing embryonic remnants of a developmental defect. Further, the condition has been complicated by various factors such as an unpredictable clinical course, confusing nomenclature, erratic response to treatment, frequent recurrence, and high morbidity following conventional treatment.<sup>[2-5]</sup> Vascular lesions of the maxillofacial region are classified by Mulliken and Glowacki (1982) as either: (1) hemangiomas or (2) VMs.<sup>[1]</sup> Hemangiomas are the most common cutaneous tumor of infancy and demonstrate rapid growth followed by a slow spontaneous involution or regression within 5–7 years. While VMs enlarge with the growth of the child, they do not undergo spontaneous involution. VMs are subdivided based on blood flow rate: “slow-flow” (capillary, venous, lymphatic,

or mixed) versus “fast-flow” (arteriole, arteriovenous, fistulae, or shunt) subtypes.<sup>[6]</sup>

VMs are caused by a disturbance in the late stages of angiogenesis (truncal stage) and result in the persistence of arteriovenous anastomoses present during embryonic life. They may be capillary, lymphatic, venous, arterial, or mixed. VMs of arterial or arteriovenous origin are often referred to as “high-flow VMs” and are often the cause of massive, sometimes fatal hemorrhages. VMs, which usually present as developmental anomalies from birth, develop in proportion to physical growth. The increase in size of these VMs, asymptomatic and imperceptible at an early age, is promoted by local hemodynamic factors. Areas of low vascular resistance cause a shunting of the blood with decreased perfusion of the peripheral tissue in favor of collateral flow, gradual dilatation of the nutrient arteries

**MADAN MISHRA, GAURAV SINGH, AMIT GAUR, SAPNA TANDON, ABHISHEK SINGH**

Department of Oral and Maxillofacial Surgery, Sardar Patel Postgraduate Institute of Dental and Medical Sciences, Lucknow, Uttar Pradesh, India

**Address for correspondence:** Dr. Madan Mishra, 15-C/29, Vrindavan Yojna, Telibagh, Lucknow - 226 025, Uttar Pradesh, India.  
E-mail: mm.15mds@gmail.com

#### Access this article online

**Website:**  
www.njms.in

**DOI:**  
10.4103/0975-5950.208973

#### Quick Response Code



This is an open access article distributed under the terms of the Creative Commons Attribution-NonCommercial-ShareAlike 3.0 License, which allows others to remix, tweak, and build upon the work non-commercially, as long as the author is credited and the new creations are licensed under the identical terms.

**For reprints contact:** reprints@medknow.com

**How to cite this article:** Mishra M, Singh G, Gaur A, Tandon S, Singh A. Role of sclerotherapy in management of vascular malformation in the maxillofacial region: Our experience. *Natl J Maxillofac Surg* 2017;8:64-9.

with atrophy of their musculo-elastic wall and decreased resistance, and dilatation and arterialization of the draining veins, owing to the increase in intraluminal pressure. The blood shunted to the malformation causes the lesion to grow, which in turn causes increased shunting of the blood, hence a vicious circle.<sup>[7]</sup> Diagnostic imaging such as color Doppler ultrasonography helps in differentiating between these subtypes by flow analysis. Thus, one can determine flow rates.<sup>[8]</sup> Some of the imaging modalities for diagnosing VMs include magnetic resonance imaging (MRI; with or without intravenous gadolinium enhancement) to evaluate the relation of the lesion to the surrounding tissues. The other major diagnostic tool includes magnetic resonance angiography which provides detailed information regarding flow characteristics and the extent of local tissue involvement.<sup>[9]</sup> Although plain radiographs are of little use for evaluation of VMs, they are reported to show calcified phleboliths or cortical erosion of bone in approximately 6% of cases.<sup>[10]</sup> Upon physical examination, VMs appear as purple or bluish compressible tumor-like formations devoid of arterial murmur or beat.<sup>[11]</sup>

The management of vascular lesions depends on the lesion's location, blood flow characteristics, symptoms, functional disability, and cosmetic deformity.<sup>[12]</sup> Traditionally, surgical excision is frequently advocated for lesions with pain, functional impairment, progressive growth, compressive neuropathy, or mass-related complications.<sup>[13]</sup> If the lesion is >2 cm in dimension with an arteriovenous shunt and local tissue infiltration of the lesion, the risk of recurrence after surgical excision increases.<sup>[14]</sup> Sclerosing agents are substances that cause a marked tissue irritation or thrombosis with subsequent local inflammation and tissue necrosis resulting in fibrosis and tissue contraction. Some of the sclerosing agents include sodium morrhuate, boiling water, nitrogen mustard, and sodium tetradecyl sulfate (STS). They have been used both to treat symptomatic hemangiomas and for embolization of high-flow VM.<sup>[6,15,16]</sup> Here, in this report, we describe the case of VM and its treatment with intralesional injection of sclerosing agent (STS).

## CASE REPORTS

### Case 1

We present a 30-year-old female referred to our Oral and Maxillofacial Surgery Clinic by a general dentist on account of swelling of the upper lip and discoloration of birth duration [Figure 1] which posed a diagnostic and management challenge. The patient claimed, and she had been treated by a spiritualist before presenting to the general dentist that referred her to our center. No previous history of trauma or use of medications known to

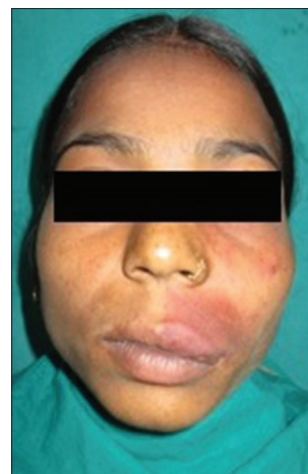

Figure 1: Profile view of the patient showing swelling in the left side upper lip

cause lip swelling on general examination, and the patient showed unilateral port-wine stain on the left side of her face extending from the superior border of the upper lip to the bridge of the nose superoinferiorly and from the left philtrum to the left corner of mouth anteroposteriorly since her birth. On clinical examination, the patient revealed about 17 mm × 6 mm approximately sized solitary extraoral swelling on vermilion border of the upper lip irregular boundary extends from cupid's bow to the left oral commissures. Swelling was nonfluctuant, nontender on palpation. Temperature of swelling was not raised. No palpable lymph nodes were felt, and intraoral tissues appeared clinically normal. During intraoral examination of hard tissue, all permanent teeth were present. The ultrasound examination showed slow-flow VM. MRI showed lobulated enhancing lesion measuring 12.8 × 8.8 mm approximately noted in left half of the upper lip reaching upto midline. MRI features suggestive of VM. A provisional diagnosis of VM was consequently made.

Management of the lesion was executed with the injection of STS with the brand name (Setrol). The possibility of recurrence and ineffectiveness of the treatment was explained to the patient. After an infiltration of local anesthesia, STS (Thrombovar; Aventis Pharma France, Laboratoires, Chiesi S.A., Courbevoie, France) was administered twice at 2 weeks of interval. Each time, 2 ml of STS was injected using a 26-gauge syringe. A decrease in the size of lesion was apparent after each session, with complete resolution. Follow-up at 5 months showed no recurrence of the symptoms [Figure 2].

### Case 2

Another case of a 21-year-old male presented with swelling in the right lateral border of the tongue of size 1.5 cm × 1 cm approximately [Figure 3]. Swelling was nonfluctuant and

nontender on palpation. A provisional diagnosis of VM was consequently made.

Management of the lesion was executed with the injection of STS with the brand name (Setrol). After an infiltration of local anesthesia, STS (Thrombovar; Aventis Pharma France, Laboratoires, Chiesi S.A., Courbevoie, France) was administered twice at 2 weeks of interval. Each time, 2 ml of STS was injected using a 26-gauge syringe [Figure 4]. A decrease in the size of lesion was apparent after each session, with complete resolution. Follow-up at 5 months showed no recurrence of the symptoms [Figure 5].

### Case 3

Another case of a 34-year-old female presented with swelling in the left buccal mucosa of size 2 cm × 1 cm approximately [Figures 6 and 7]. Swelling was nonfluctuant and nontender on palpation. The ultrasound examination showed slow-flow VM. MRI showed moderate size well-defined lesion of the left masseter muscle. A provisional

diagnosis of VM of the left masseter muscle was consequently made [Figure 7].

Management of the lesion was executed with the injection of STS. After an infiltration of local anesthesia, STS (Thrombovar; Aventis Pharma France, Laboratoires, Chiesi S.A., Courbevoie, France) was administered twice at 2 weeks of interval. Each time, 2 ml of STS was injected using a 26-gauge syringe [Figure 8]. A decrease in the size of lesion was apparent after each session, with complete resolution. Follow-up at 5 months showed no recurrence of the symptoms [Figure 9].

### DISCUSSION

VMs comprise the second major category of congenital vascular lesions. This group of lesions reflects abnormalities in blood and lymphatic vessel morphogenesis. Histologically, these vascular lesions are characterized by normal endothelial

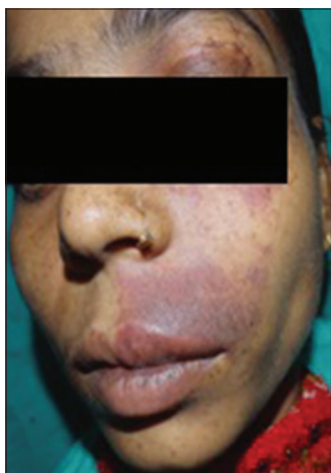

Figure 2: Follow-up at 5 months showed no reoccurrence of symptoms

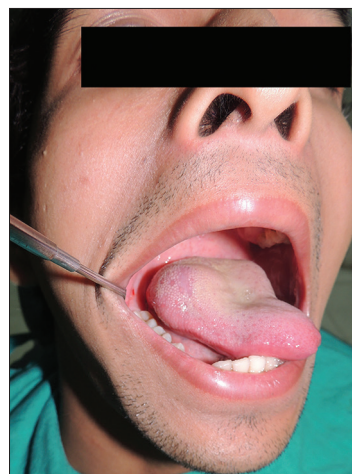

Figure 3: Profile view of the patient showing swelling in the right lateral border of the tongue of size 1.5 cm × 1 cm approximately

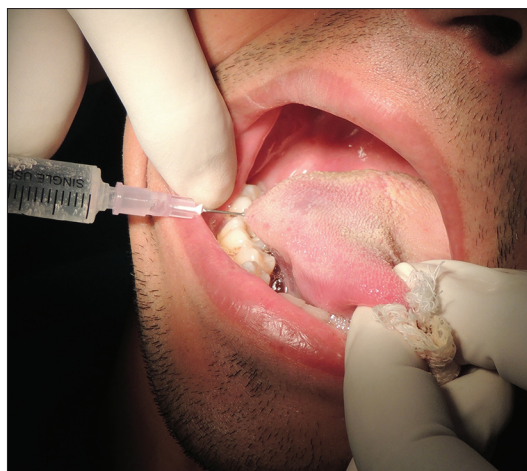

Figure 4: Injection of sodium tetradecyl sulfate brand name (Setrol)

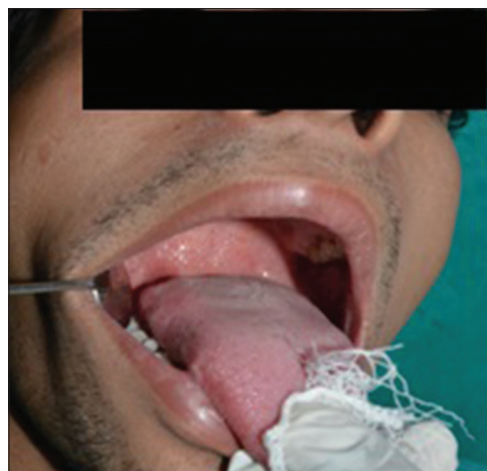

Figure 5: Follow-up at 5 months showed no reoccurrence of symptoms



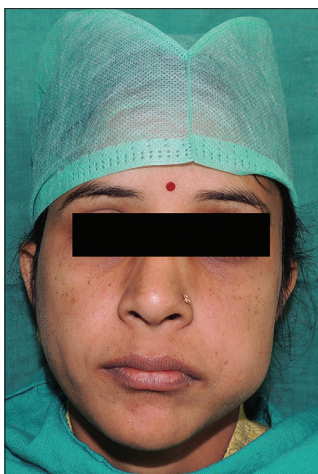


Figure 6: Profile view of the patient showing in the left side of the face

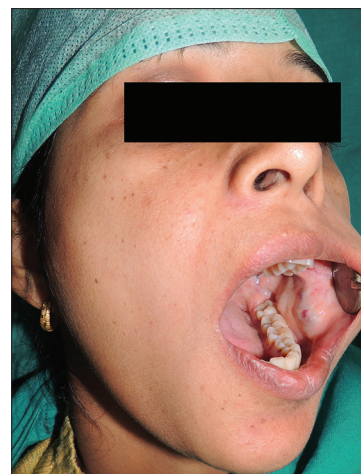

Figure 7: Intraorally swelling in the left buccal mucosa of size 2 cm x 1 cm approximately

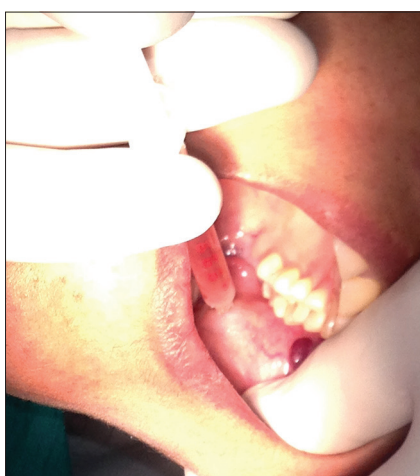

Figure 8: Injection of sodium tetradecyl sulfate brand name (Setrol)

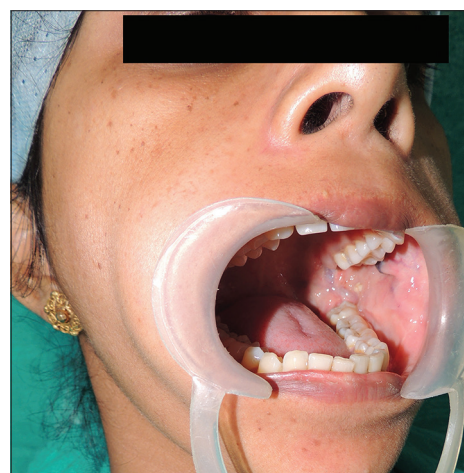

Figure 9: Follow-up at 5 months showed no recurrence of the symptoms

cells and normal numbers of mast cells throughout their natural history. Unlike hemangiomas, VMs are present at birth although they may not be clinically evident until late infancy or childhood. The growth of these lesions is commensurate with that of the patient, and they do not regress or involute. Rapid enlargement of these malformations may occur as a result of trauma, infection, or endocrine changes (e.g., pregnancy and puberty). Skeletal abnormalities are more commonly seen in association with VMs (35%) than with hemangioma. The classification scheme of these lesions is based on the predominant type of anomalous vessel involved and includes low-flow lesions (capillary, venous, and lymphatic malformations) and high-flow lesions (arteriovenous malformations). Complex VMs sharing features of multiple types of lesions also occur, termed combined VMs.<sup>[17]</sup>

VMs are comprised abnormally formed channels that are lined by quiescent endothelium. Although VMs are congenital in nature, they may not be seen at birth and may not be evident until additional growth or vascular

engorgement is seen as a response to trauma, thrombosis, infection, or endocrine fluctuations. Unlike hemangiomas, which involute, the size of VMs generally increases in size proportionately as the child grows. The mean age at presentation is 19 years with equal predilection for both males and females. VMs in the maxillofacial skeleton are common with approximately 31% presenting in the head and neck. Histologically, they present with chromosomal-induced errors in endothelial development but demonstrate normal endothelial turnover and thin-walled, dilated channels with sparse smooth muscle cells and adventitial fibrosis. The clinical presentation of vascular abnormalities varies from an asymptomatic birthmark to life-threatening congestive heart failure or an exsanguinating hemorrhage. The afflicted, it is observed, often seek help from a number of different physicians and undergo repetitive examination for diagnosis, and frequent failed attempts at “definitive” treatment which results in exacerbation of symptoms, lesion recurrences, and disability. Intraosseous VMs of the maxillofacial

region can lead to dental emergencies and may cause disfigurement, morbidity, and even death.<sup>[15,16]</sup> Classification of VM histologically includes capillary or small vessel which presents with prominent mitotic figures, plump endothelial nuclei, and intraluminal projections of endothelial cells that simulated vascular or perineural invasion. They have a prevalence of 30% in the head and neck region with a local recurrence rate of 20%.<sup>[18]</sup>

VM can be treated in several ways, such as irradiation, cryotherapy, laser therapy, surgical excision, and sclerotherapy. Sclerotherapy is effective for small superficial VMs and surgical resection for localized well-defined lesions. Extensive lesions are difficult to demarcate during surgery, and radical excision is associated with significant functional impairments, cosmetic disfigurement, and high recurrence rates. Sclerotherapy is an effective treatment modality for VM and can be performed with a variety of sclerosing agents. Pingyangmycin (bleomycin hydrochloride), a chemotherapy drug, used to treat oral cancer. STS (Sotradecol) is currently being employed as a sclerosing agent which interferes with cell surface lipids causing endothelial damage, with resulting thrombosis and fibrosis.<sup>[2]</sup>

Once the lesion is confirmed, the therapeutic path does not become any clearer. The multiplicity of approaches contrasts with the rareness of this type of malformation but is in direct relation to the urgency of the required intervention and the permanency of the measures to be applied. Recent accounts in favor of the direct intralesional injection of STS offer us a new perspective. There seems to be less morbidity reported with this approach even though limited outcome data are available. The greatest advantage of this approach may lie in its intrinsic ability to eliminate the whole vascular latticework feeding the lesion, promoting, especially in children, full expression of the regenerative potential of somatic growth to replace the vascular anomaly. The choice of this approach, therefore, depends not only on the lesion's size, accessibility, or anatomic contiguity to the important structures but also on the patient's regenerative capacity.<sup>[7]</sup>

## CONCLUSION

The rareness of VMs is equaled only by the morbidity they cause and the urgency of the measures to be taken once detected, in all circumstances. A high degree of suspicion leads to their diagnosis and considerably reduces the risks of a catastrophe once identified. Treatment by direct intralesional injection of STS allows for conservative anatomic and functional recovery. It is relatively noninvasive and safe when the anatomy and clinical status permit its use.<sup>[7]</sup>

In this study, the use of sclerosing agent as a treatment resulted in complete regression of the lesion without any collateral anastomosis. The benefits of the unconventional, noninvasive technique applied in the patients treated for VM include a more esthetic outcome, decreased likelihood of blood loss and danger of transfusion, and inexpensive – as the patient can be treated on an outpatient status. However, further investigations are suggested to better determine the appropriate selection of patients for this approach.<sup>[6]</sup>

## Declaration of patient consent

The authors certify that they have obtained all appropriate patient consent forms. In the form the patient(s) has/have given his/her/their consent for his/her/their images and other clinical information to be reported in the journal. The patients understand that their names and initials will not be published and due efforts will be made to conceal their identity, but anonymity cannot be guaranteed.

## Financial support and sponsorship

Nil.

## Conflicts of interest

There are no conflicts of interest.

## REFERENCES

1. Adewole R, Adetayo A, Irurhe N, Ayodele A. Diagnostic dilemma in vascular malformation of the upper lip: A case report and review of literature. *Int J Med Biomed Res* 2014;3:178-84.
2. Lee BB, Kim DI, Huh S, Kim HH, Choo IW, Byun HS, *et al.* New experiences with absolute ethanol sclerotherapy in the management of a complex form of congenital venous malformation. *J Vasc Surg* 2001;33:764-72.
3. Mulliken JB. Cutaneous vascular anomalies. *Semin Vasc Surg* 1993;6:204-18.
4. Malan E. *Vascular Malformations (Angiodysplasias)*. Milan: Carlo Erba Foundation; 1974. p. 17.
5. Belov S. Anatomopathological classification of congenital vascular defects. *Semin Vasc Surg* 1993;6:219-24.
6. Deepa V, David CM, Lidiya A. A management of arterio venous vascular malformation masquerading as a mucocele using sclerotherapy – Review of literature and a case report. *Int J Pharm Sci Invent* 2013;2:1-6.
7. Noreau G, Landry PE, Morais D. Arteriovenous malformation of the mandible: Review of literature and case history. *J Can Dent Assoc* 2001;67:646-51.
8. Gold L, Nazarian LN, Johar AS, Rao VM. Characterization of maxillofacial soft anomalies by ultrasound and color Doppler imaging: An adjunct to computed tomography and magnetic resonance imaging. *J Oral Maxillofac Surg* 2003;61:19-31.
9. Disa JJ, Chung KC, Gellad FE, Bickel KD, Wilgis EF. Efficacy of magnetic resonance angiography in the evaluation of vascular malformations of the hand. *Plast Reconstr Surg* 1997;99:136-44.
10. Palmieri TJ. Subcutaneous hemangioma of the face. *J Hand Surg (Am)* 1983;8:201-4.
11. Orlando JL, Mendes Pereira Caldas JG, Campos HG, Nishinari K,

- Krutman M, Wolosker N, *et al.* Ethanol sclerotherapy of head and neck venous malformations. *Einstein* 2014;12:181-5.
12. McClinton MA. Tumors and aneurysms of the upper extremity. *Hand Clin* 1993;9:151-69.
13. Larsen PE, Peterson LJ. A systematic approach to management of high-flow vascular malformations of the mandible. *J Oral Maxillofac Surg* 1993;51:62-9.
14. Niechajev IA, Karlsson S. Vascular tumours of the hand. *Scand J Plast Reconstr Surg* 1982;16:67-75.
15. Mohammadi H, Said-al-Naief NA, Heffez LB. Arteriovenous malformation of the mandible: Report of a case with a note on the differential diagnosis. *Oral Surg Oral Med Oral Pathol Oral Radiol Endod* 1997;84:286-9.
16. Schneider C, Wagner A, Hollmann K. Treatment of intraosseous high flow arteriovenous malformation of the mandible by temporary segmental osteotomy for extra corporal tumor resection: A case report. *J Craniomaxillofac Surg* 1996;24:271-5.
17. Baker LL, Dillon WP, Hieshima GB, Dowd CF, Frieden IJ. Hemangiomas and vascular malformations of the head and neck: MR characterization. *AJNR Am J Neuroradiol* 1993;14:307-14.
18. Clemis JD, Briggs DR, Changus GW. Intramuscular hemangioma in the head and neck. *Can J Otolaryngol* 1975;4:339-46.