

## Primary Germ Cell Tumor of the Mediastinum - Presenting as a Huge Mass

Usha Dalal, Manjit Singh Jora<sup>1</sup>, Ashwani K. Dalal, Ashok K. Attri, Rikki Singal<sup>2</sup>, Samita Gupta<sup>3</sup>

Department of Surgery, Government Medical College and Hospital, Chandigarh, India,

<sup>1</sup>Department of Radio-oncology, Government Medical College, Punjab, India, <sup>2</sup>Department of Surgery, M. M. Institute of Medical Sciences and Research, Mullana, (Distt - Ambala), Haryana, India, <sup>3</sup>Department of Radiology, M. M. Institute of Medical Sciences and Research, Mullana, (Distt - Ambala), Haryana, India

### Correspondence to:

Dr. Rikki Singal,  
Department of Surgery, M.M. Institute  
of Medical Sciences and Research,  
Mullana, (Distt -Ambala) - 133 203,  
Haryana, India.  
E-mail: singalsurgery@yahoo.com

Date of Submission: Apr 14, 2012

Date of Acceptance: Apr 28, 2012

**How to cite this article:** Dalal U, Jora MS, Dalal AK, Attri AK, Singal R, Gupta S. Primary germ cell tumor of the mediastinum - presenting as a huge mass. *Int J Prev Med* 2014;5:230-2.

### ABSTRACT

Germ cell tumors compromise 15-20% of all anterior mediastinal masses; 50-60% of these are benign mediastinal teratoma. There may be mature, immature, and rarely with malignant component within the tumor mass. There are more chances of malignancy with immature type. We are reporting a case in 20-year young male diagnosed as giant benign cystic teratoma which was adherent to superior vena cava. The patient underwent surgical excision. In follow up of 2 years, the patient is not having any complaints.

**Keywords:** Benign teratoma, bronchoscopy, cystic mass, extragonadal, surgery

### INTRODUCTION

In 1953, Willis defined the teratomas as true tumors composed of tissues that are foreign to the part or organ of the body, in which they are found.<sup>[1]</sup> Anterior mediastinum is the most frequent site of occurrence of the tumors in thorax, and benign teratomas constitute about 3-12% of mediastinal tumors.<sup>[2-4]</sup> A few surgeons in the late 18<sup>th</sup> century attempted and described surgical approaches to the mediastinum. In 1888, Nassiloff first showed that the esophagus was accessible using a posterior approach.<sup>[5]</sup> In 1893, Bastinelli described the removal of an anterior mediastinal dermoid cyst by resection of the manubrium, with successful recovery of the patient.<sup>[5]</sup>

### CASE REPORT

A 20-year young male patient admitted with complaints of chest pain on right side and cough since 3 months. The patient did not have any other associated complaints. On chest examination, breath sounds were decreased on right side. Rest of systems was normal. Blood investigations were within normal limits. Chest X-ray revealed a large well-defined opacity of approximate 15 × 13 cm in size, seen in the right mid and lower zone with broad base toward mediastinum with calcifications [Figure 1]. The contrast-enhanced computed tomography (CECT) scan of thorax showed a large heterogeneous well-defined cystic mass of 14 × 10 cm in size on the right side abutting the chest wall. Fat planes with superior vena cava appear to be lost? Invasion [Figure 2]. On bronchoscopy, there was indentation of

the mass over the tracheobronchial tree with lateral displacement toward left.

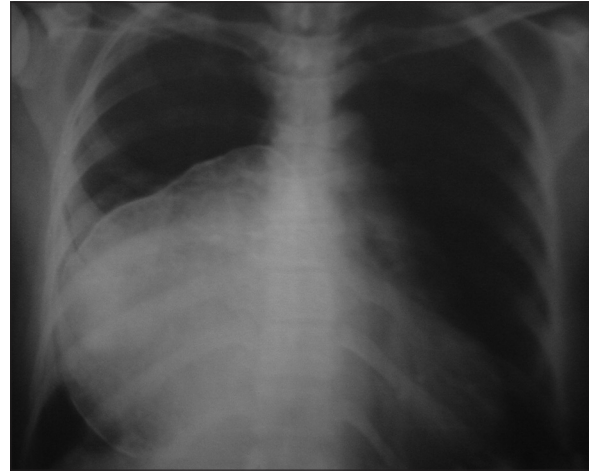
Computed tomography-guided percutaneous aspiration was done and it revealed cellularity mixed origin with no malignant components suggestive of benign teratoma. Right posterolateral thoracotomy was done with excision of the rib and a large cystic mass excised from within the anterior mediastinum which was projecting into the right side of the chest wall anteriorly and was adherent to it. Mass was also adherent to superior vena cava. Mass was consist of hairs and cartilages, but no bone was found inside of mass. Histopathological examination of the specimen came out as benign teratoma. Post-op chest X-ray showed complete excision of the right-sided mass and haziness in left lung. Intercostal tubes seen *in situ* [Figure 3]. In 2 years of follow-up, the patient is doing well without any recurrence.

## DISCUSSION

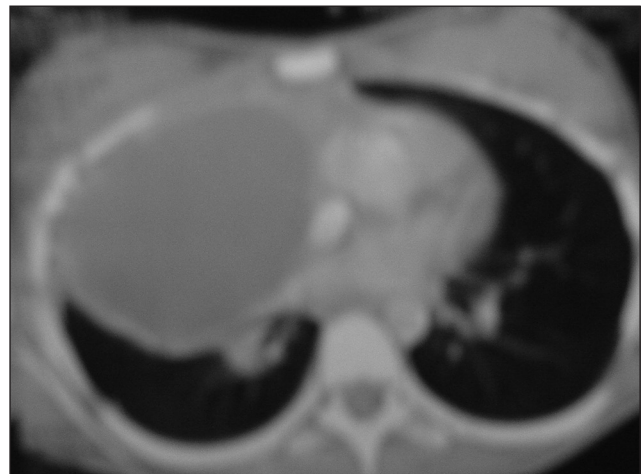In 1897, Milton wrote extensively on mediastinal surgery using the median sternotomy approach.<sup>[5]</sup> Germ cell tumors typically occur in young adults in their second to fourth decade with equal sex distribution. Benign teratomas are usually well encapsulated and are composed of either a single large cystic cavity or several smaller intercommunicating spaces.<sup>[6]</sup> They may be mature in about 80% of cases and also immature and rarely teratomatous with malignant components in remaining 20% of the cases. There are more chances of malignancy in immature type.

In 1986, Mullen and Richardson classified mediastinal germ cell tumors into three categories benign germ cell tumors, seminomas, and nonseminomatous germ cell tumors, also called malignant teratomas.<sup>[7]</sup> Germ cell tumors compromise 15-20% of all anterior mediastinal tumors and benign mediastinal teratomas accounts for 60% of all germ cell tumors.<sup>[6]</sup> These tumors consists of multiple tissue types from totipotent cells containing three embryonic layers i.e. ectoderm, mesoderm, and endoderm, out of these ectodermal component are found predominantly and are composed of tissue foreign to the organ or anatomical site in which they arise.<sup>[6,7]</sup>

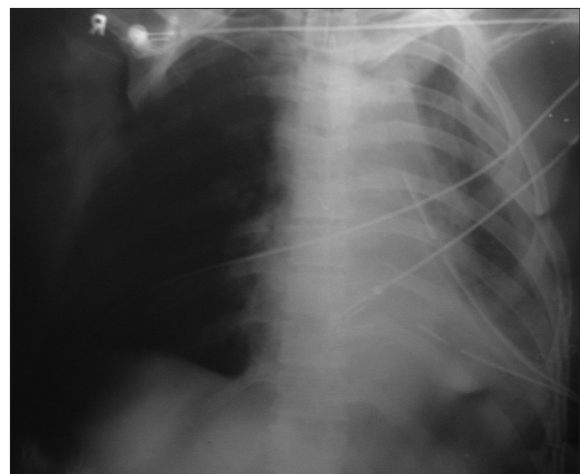
Benign teratomas which are also known as teratodermoids are among the benign germ cell



**Figure 1:** Chest X-ray revealed a large well-defined opacity in the right mid and lower zone



**Figure 2:** Computed tomography scan of thorax showed a large well-defined cystic mass adherent to superior vena cava



**Figure 3:** Post-op chest X-ray showed complete excision of the right-sided mass

tumors.<sup>[1,8]</sup> They are divided into three groups as epidermoid cysts, dermoid cysts, and teratomas. Mediastinal teratomas are slowly growing tumors and approximately 95% of them are found in anterior mediastinum. The presence of a structure resembling tooth, and fat tissue, lymphoid tissue, collagen, vessels, and ductal structures are suggestive of teratoma.<sup>[1]</sup> About 60% of teratomas are asymptomatic and diagnosed with chest radiograms. The most common symptoms are chest pain, and dyspnea and cough are among other symptoms.<sup>[1]</sup> In the presented case report, the patient presented with dyspnea and cough for 3 months either due to tumor-induced compression or the total atelectasis of the lung, following recurrent pulmonary infections. Benign mediastinal teratomas may be secondarily infected following rupture into neighboring structures.

Rupture of benign mediastinal teratomas into the bronchial tree is evident by expectoration of hair (trichoptysis) and the other contents of the cystic teratoma. Benign mediastinal teratomas may also rupture to pleural cavity leading to development of empyema. Pressure effects to neighboring organs may be evident even in the absence of infection due to enlarging lesion.<sup>[1]</sup> Chest X-ray and CECT scan are the preferred investigation for screening and diagnosis.<sup>[9]</sup> On CECT scan of chest showed well-defined, thick-walled cystic masses containing a variable admixture of densities: Fat 96%, water 83%, soft tissue and calcium 53%.<sup>[1,7]</sup> Macroscopically the tumors are spherical, lobulated, with a well-defined capsule, and contain a variety of material, lipid-rich fluid, cheese-like substances, teeth, hair, and cartilage.<sup>[7]</sup> The treatment of choice for benign mediastinal teratomas is surgery.<sup>[1]</sup> Median sternotomy is usually preferred for tumor removal, but access via either posterolateral or anteroposterior thoracotomy depends on the size, location, and expansion of the tumor.<sup>[7]</sup> CT shows the location and extent of the tumors as well as intrinsic elements including soft tissue, fat, fluid, and calcification. Definitive diagnosis requires histopathological examination supplemented with chest X-ray, CT and MRI of the affected system.<sup>[9,10]</sup> CT is the modality of choice for the diagnostic evaluation of these tumors.<sup>[9]</sup> Total excision of the tumor is the sufficient treatment teratoma and the prognosis is excellent.

## CONCLUSIONS

A teratoma is a non-homogeneous pathological entity, clinically, radiologically, or histologically. Although benign mediastinal teratomas are uncommon, they may present as a mass with bulging from mediastinum to chest wall as seen in our case. In cases of cystic masses, containing fat and calcific densities, in unusual locations, the diagnosis of teratoma should be considered. Radiologically, chest X-ray and CECT scan are the helpful investigations for treatment. Surgical excision is the treatment of choice, and though these cannot be removed totally, their recurrence rate is very low.

## REFERENCES

1. Soysal O, Sarac K, Kutlu R, Aydin A, Benli A. A case of mediastinal teratoma presenting as a cystic lesion on chest wall. *East J Med* 1998;3:32-3.
2. Sinclair DS, Bolen MA, King MA. Mature teratoma within the posterior mediastinum. *J Thorac Imaging* 2003;18:53-5.
3. Lewis BD, Hurt RD, Payne WS, Farrow GM, Knapp RH, Muhm JR. Benign teratomas of the mediastinum. *J Thorac Cardiovasc Surg* 1983;86:727-31.
4. Hainsworth JD, Greco FA. Mediastinal germ cell neoplasms. In: Roth JA, Ruckdeschel JC, Weisenburger TH, editors. *Thoracic Oncology*. Philadelphia: W.B. Saunders Co; 1989. p. 478-89.
5. Mueller DK. Teratomas and Other Germ Cell Tumors of the Mediastinum: Follow up, (eMedicine). Available from: <http://medscape.com> [Last updated on 2008 Sep 04].
6. Lakhota S, Dewan RK. Benign cystic teratoma of mediastinum. *Indian J Surgery* 2008;70:244-6.
7. Zisis C, Rontogianni D, Grigorios S, Konstantinos V, Konstantinos S, Mihalios A, *et al.* Teratoma occupying the left hemithorax. *World J Surg Oncol* 2005;3:1477-8.
8. Takeda S, Miyoshi S, Ohta M, Minami M, Masaoka A, Matsuda H. Primary germ cell tumors in the mediastinum. A 50-year experience at a single Japanese institution. *Cancer* 2003;97:367-76.
9. Singal R, Dalal U, Dalal AK, Attri AK, Gupta S, Raina R. Solitary plasmacytoma of the rib: A rare case. *Lung India* 2011;28:309-11.
10. Dalal AK, Singal R, Dalal U, Attri AK, Sahu P, Gupta A. An unusual case of chest wall desmoid tumor. *Indian J Surg* 2010;72(Suppl 1):336-8.

**Source of Support:** Nil, **Conflict of Interest:** None declared.