



Published in final edited form as:

*Int J Clin Res Trials*. 2019 ; 4(1): . doi:10.15344/2456-8007/2019/132.

## Marijuana and Cardiac Arrhythmias: A Scoping Study

Pramod Theetha Kariyanna<sup>1</sup>, Perry Wengrofsky<sup>2</sup>, Apoorva Jayarangaiah<sup>3</sup>, Syed Haseeb<sup>2</sup>, Louis Salciccioli<sup>1</sup>, Sudhanva Hegde<sup>1</sup>, Jonathan D. Marmur<sup>1</sup>, Yasmin Soliman<sup>2</sup>, Sama Al-Bayati<sup>2</sup>, Samy I. McFarlane<sup>2,\*</sup>

<sup>1</sup>Division of Cardiovascular Disease, Department of Internal Medicine, State University of New York, Downstate Medical Center, Brooklyn, NY 11203, USA

<sup>2</sup>Department of Internal Medicine, State University of New York, Downstate Medical Center, Brooklyn, NY 11203, USA

<sup>3</sup>Department of Internal Medicine, NYC Health and Hospitals/Jacobi Medical Center, Bronx, NY 10461, USA

### Abstract

With increasing legalization, marijuana has become the most commonly abused substance in the United States. Together with the introduction of more potent marijuana products over the years, more adverse events are being reported and clinically characterized. Delta-9-tetrahydrocannabinol (THC) is the active psychotropic component of marijuana, which acts mainly on G-protein cannabinoid receptors CB1 and CB2. Multiple isolated cases of arrhythmias associated with marijuana use have been published. In this manuscript we conduct a scoping study of a total of 27 cases of arrhythmia associated with marijuana. Most cases were reported in young males (81%) with a mean age of  $28 \pm 10.6$  years. Atrial fibrillation (26%) and ventricular fibrillation (22%) were the most common arrhythmias reported. Brugada pattern was reported in 19% of the patients. Marijuana associated arrhythmia resulted in a high mortality rate of 11%. While the exact mechanisms of arrhythmias associated with marijuana are not clear, several hypothesis have been introduced including the effect of marijuana on cardiac ion channels as well as its effects on the central nervous system. In this paper we discuss the possible mechanisms of marijuana induced arrhythmia citing the evidence available to-date.

### Keywords

Marijuana; Cannabis; Marijuana abuse; Arrhythmia; Ventricular tachycardia; Ventricular fibrillation; Brugada pattern; Sudden cardiac death

---

This is an open-access article distributed under the terms of the Creative Commons Attribution License, which permits unrestricted use, distribution, and reproduction in any medium, provided the original author and source are credited.

\***Corresponding Author:** Prof. Samy I. McFarlane, Divisions of Cardiovascular Disease, and Endocrinology, Department of Internal Medicine, State University of New York, Downstate Medical Center, Brooklyn, New York, 11203, USA, Tel: 718-270-6707, Fax: 718-270-4488; smcfarlane@downstate.edu.

Competing Interests

The authors declare that they have no competing interests.

## Introduction

Marijuana is the most common drug of abuse in the United States [1]. In 2016, a national drug survey indicated that lifetime marijuana use in ages 12 years or older was approximately 118 million in the United States [2]. The potency of marijuana has seen a tenfold rise in the past decade [3]. Implementation of medical marijuana laws in the period from 2004–2012 lead to an overall 15 percent increase in the probability of almost daily or daily marijuana use among adults aged 21 years or above [4]. Certain states in the United States of America which have legalized marijuana for recreational use have reported a higher rates of marijuana use when compared to states where all forms of marijuana is illegal [5,6,7]. Multiple isolated cases of arrhythmias associated with marijuana use have been reported. We present a scoping of the same.

## Methods

On August 27th, 2018, a systematic search was conducted using Pubmed, Google Scholar, CINAHL, Cochrane CENTRAL and Web of Science databases. Studies listing the keywords “Marijuana, cannabis, arrhythmias, atrial arrhythmia, ventricular arrhythmia” were used to identify cases of myocardial arrhythmias associated with marijuana use (Figure 1). The reference list of each report was reviewed for potential additional cases. All cases were reviewed in detail. Data reviewed included demographic data, cardiovascular (CV) risk factors, electrocardiography (EKG) findings, troponin levels, transthoracic echocardiography, electrophysiology study, urine drug screen findings, and management when available.

## Results

A total of 27 cases of arrhythmias associated with marijuana use were identified from 24 papers (Table 1) (8–31). The mean age was  $28 \pm 10.6$  years (median age 24 years) and 81% were males. The other reported risk factors were: smoking in 22%, hypertension in 11%, alcohol abuse in 11%, use of other drugs of abuse in 11%, hyperlipidemia in 7.4%, coronary artery disease in 3.7%, and family history of sudden cardiac death in 3.7%. Atrial fibrillation was the most common arrhythmia (26%) followed by ventricular fibrillation (22%). Brugada pattern was reported in 19%. All reported arrhythmias have been summarized in table 2. Urine toxicology screen was positive for marijuana in 41% of the cases. The management strategy employed has been summarized in table 1. Death occurred in 3 cases (11%) of which ventricular fibrillation was the cause in 2 cases (7.4%) sudden cardiac death in one (3.7%).

## Discussion

Delta-9-tetrahydrocannabinol (THC) is the active psychotropic component of marijuana, which mainly acts on G-protein cannabinoid receptors CB1 and CB2. Endogenous cannabinoids such as anandamide and 2-arachidonoylglycerol act on CB1 and CB2 too [32]. CB1 receptors are present in heart, brain, vascular smooth muscles and liver and CB2

receptors primarily occur in immune cells [33]. Mechanisms of arrhythmogenesis following marijuana use are not fully understood, with various mechanisms proposed.

Tachycardia following marijuana use has been attributed to sympathetic stimulation [34]. Reflex tachycardia has been proposed from vasodilation secondary to parasympathetic stimulation [35]. Animal models have described CB1 agonist mediated sympathetic inhibition and enhanced cardiac vagal tone leading to bradycardia and hypotension [36]. Sympathetic stimulation and parasympathetic inhibition may result in faster generation (automaticity) and conduction of impulses [37]. Norepinephrine released by sympathetic nerve terminals inhibit acetylcholine release by parasympathetic nerve fibers and vice versa. Such inhibition is mediated by release of neuropeptides [38]. The net effect may further vary because of differences in regional neuronal distribution in the heart. Vagal influences predominate in SA node while sympathetic neurons in ventricle [39]. Lower doses are known to cause sympathetic stimulation while higher doses drive parasympathetic stimulation [40].

Myocardial ischemia is a known substrate of arrhythmogenesis [41]. Marijuana induces myocardial ischemia and infarction by various mechanisms [42]. CB1 agonists and CB2 antagonists are proatherogenic, while CB2 agonists are antiatherogenic. The underlying mechanism has been discussed elsewhere [42]. Marijuana smoking leads to elevated carboxyhemoglobin in blood [43], slow coronary flow [44], and no coronary flow [45] in the absence of coronary artery stenosis. Tachycardia induced myocardial oxygen demand [34,35], coronary vasospasm [46], and increase platelet activation [47] all create ischemic milieu and thus may cause ischemia induced arrhythmias. Scar that results from myocardial infarction can further act as a substrate for reentry and thus is arrhythmogenic [41]. Myocardial ischemia and infarction can modulate cardiac neurons and thus may lead to arrhythmogenesis [48]. Ischemia induced alteration in cardiac ion channel expression and function may create a milieu for arrhythmia [49].

A change in P wave morphology has been noted following marijuana use suggesting effects on the atrium [50]. Decrease sinoatrial (SA) conduction, delay in A-H (atrium to bundle of His) interval and decrease in atrioventricular (AV) node refractory period are known effects of THC [51]. However, another study reported autonomic nervous system mediated increase in SA node automaticity, and facilitation of SA and AV nodal conduction [52]. Little is known about the effect of cannabinoids on ion channels. Anandamide is known to inhibit  $\alpha$ -subunit of neuronal sodium channels Nav 1.2, Nav 1.6, Nav 1.7 and Nav 1.8 [53]. Cannabidiol is known to inhibit bacterial homomeric Nav channel (NaChBac) and voltage-gated potassium channel subunit Kv2.1 (54). A patch clamp study showed that the human cardiac Ito 1 channels and Kv4.3 channels are inhibited by endocannabinoids [55]. Inhibitory effect on sodium and potassium channels may explain Brugada pattern induced by marijuana, however it may also be secondary to high vagal tone [56]. Image 2 summarizes the mechanisms of arrhythmias discussed. The scoping study is based on published case reports and hence suffers from selection bias which may affect the reported age, sex and type of arrhythmias reported.

## Conclusion

In conclusion, these mechanisms alone or synergistically may contribute to initiation and maintenance of arrhythmia following marijuana use. A detailed history obtained from patients helps to identify marijuana as precipitant of arrhythmia and urine screening for THC may further confirm the same. Due to trends towards increase in marijuana use we recommend toxicology screening for marijuana/THC in patients who present with new onset arrhythmia. Further patch clamp and animal studies are required to understand the effects of marijuana on cardiac ion channels and the conduction system of the heart

## Funding

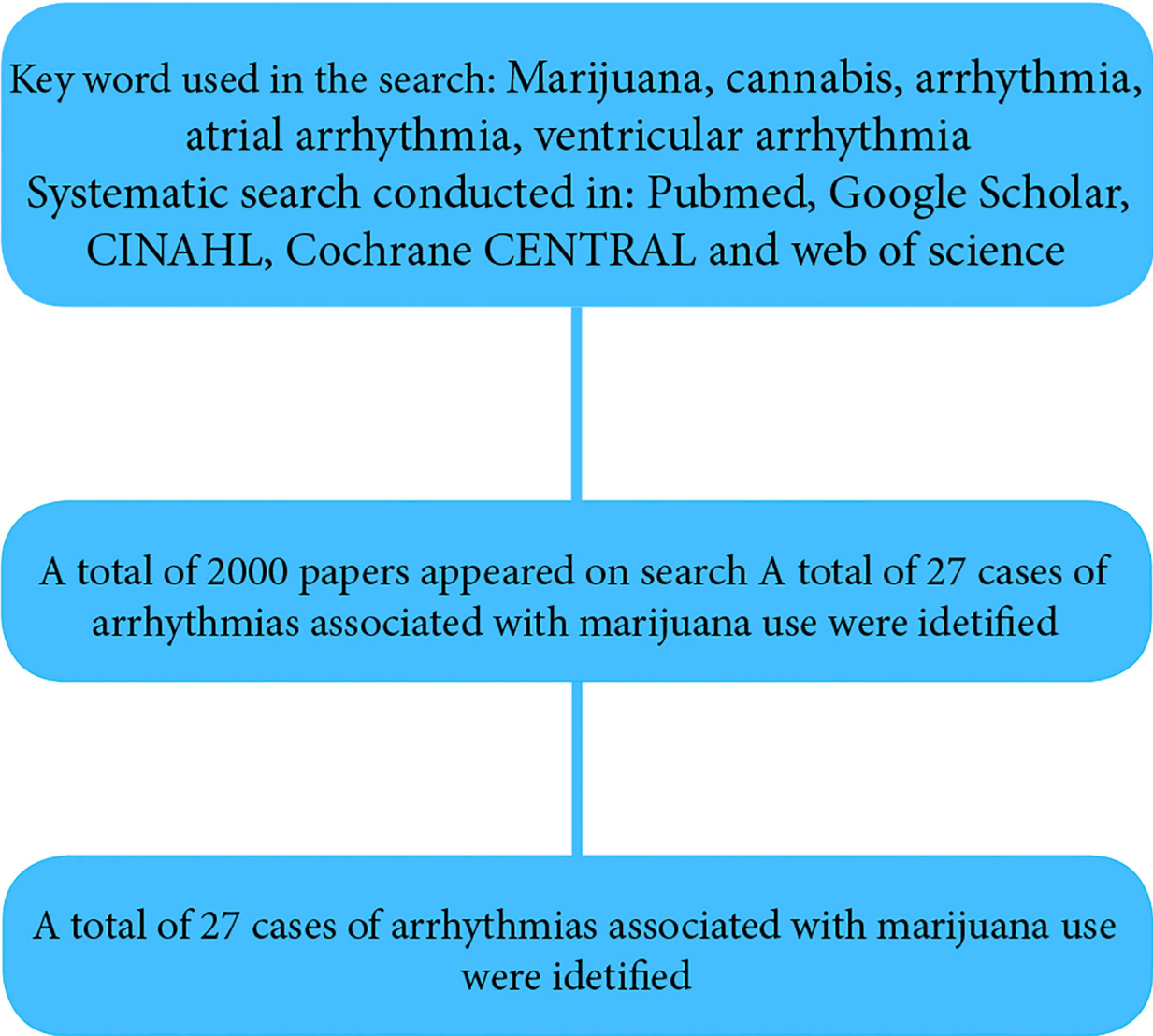
This work is supported, in part, by the efforts of Dr. Moro O. Salifu M.D., M.P.H., M.B.A., M.A.C.P., Professor and Chairman of Medicine through NIH Grant number S21MD012474.

## References

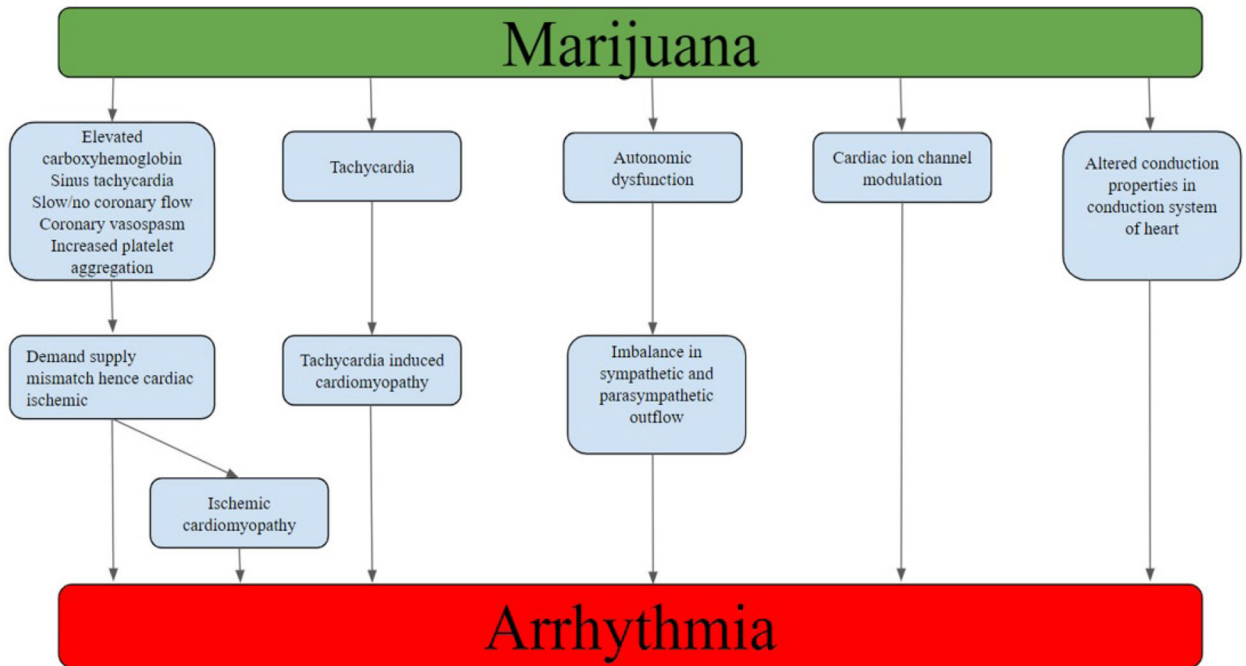
1. Abuse, Substance, and Mental Health Services Administration (2014) "National survey on drug use and health."
2. Ahrnsbrak R, Bose J, Hedden SL, Lipari RN, Park-Lee E (2017) Key substance use and mental health indicators in the United States: Results from the 2016 National Survey on Drug Use and Health. Center for Behavioral Health Statistics and Quality, Substance Abuse and Mental Health Services Administration: Rockville, MD, USA.
3. World Health Organization (2016) The health and social effects of nonmedical cannabis use.
4. Wen H, Hockenberry JM, Cummings JR (2015) The effect of medical marijuana laws on adolescent and adult use of marijuana, alcohol, and other substances. *Journal of health economics* 42: 64–80. [PubMed: 25863001]
5. Choo EK, Benz M, Zaller N, Warren O, Rising KL, et al. (2014) The impact of state medical marijuana legislation on adolescent marijuana use. *J Adolesc Health*. 55:160–166. [PubMed: 24742758]
6. Wall MM, Poh E, Cerdá M, Keyes KM, Galea S, Hasin DS (2011) Adolescent marijuana use from 2002 to 2008: higher in states with medical marijuana laws, cause still unclear. *Ann Epidemiol* 21:714–716. [PubMed: 21820632]
7. Cerdá M, Wall M, Keyes KM, Galea S, Hasin D (2012) Medical marijuana laws in 50 states: investigating the relationship between state legalization of medical marijuana and marijuana use, abuse and dependence. *Drug Alcohol Depend* 120: 22–27. [PubMed: 22099393]
8. Akins D, Awdeh MR (1981) Marijuana and second-degree AV block. *South Med J* 74: 371–373. [PubMed: 6261403]
9. Kosior DA, Filipiak K, Stolarz P, Opolski G (2000) Paroxysmal atrial fibrillation in a young female patient following marijuana intoxication—a case report of possible association. *Med Sci Monit* 6: CS386–CS389.
10. Singh GK (2000) Atrial fibrillation associated with marijuana use. *Pediatr Cardiol* 21: 284. [PubMed: 10818197]
11. Kosior DA, Filipiak KJ, Stolarz P, Opolski G (2001) Paroxysmal atrial fibrillation following marijuana intoxication: a two-case report of possible association. *Int J Cardiol* 78: 183–184. [PubMed: 11398765]
12. Rezkalla SH, Sharma P, Kloner RA (2003) Coronary no-flow and ventricular tachycardia associated with habitual marijuana use. *Ann Emerg Med* 42: 365–369. [PubMed: 12944889]
13. Fisher BA, Ghuran A, Vadimalai V, Antonios TF (2005) Cardiovascular complications induced by cannabis smoking: a case report and review of the literature. *Emerg Med J* 22: 679–680. [PubMed: 16113206]

14. Charbonney E, Sztajzel JM, Poletti PA, Rutschmann O (2005) Paroxysmal atrial fibrillation after recreational marijuana smoking: another "holiday heart"? *Swiss Med Wkly* 135: 412–414. [PubMed: 16220412]
15. Daccarett M, Freih M, Machado C (2007) Acute cannabis intoxication mimicking brugada-like ST segment abnormalities. *Int J Cardiol* 119: 235–236. [PubMed: 17291603]
16. Baranchuk A, Johri AM, Simpson CS, Methot M, Redfearn DP (2008) Ventricular fibrillation triggered by marijuana use in a patient with ischemic cardiomyopathy: a case report. *Cases J* 1: 373. [PubMed: 19055771]
17. Lázaro JJ, Bonet LA, Sancho-Tello MJ, Martínez-Dolz L (2009) Ventricular tachycardia due to marijuana use in a heart transplant patient. *Rev Esp Cardiol* 62: 459–461.
18. Sattout AH, Nicol MF (2009) Cardiac arrest following cannabis use: a case report. *Cases J* 2: 208. [PubMed: 19946452]
19. Fernández-Fernández FJ, Caínzos-Romero T, Mesías AP, Sesma P (2011) Ectopic atrial rhythm associated with cannabis use. *Minerva Cardioangiol* 59: 119–120. [PubMed: 21285939]
20. Romero-Puche AJ, Trigueros-Ruiz N, Cerdán-Sánchez MC, Pérez-Lorente F, Roldán D, Vicente-Vera T (2012) Brugada electrocardiogram pattern induced by cannabis. *Revista Española de Cardiología* 65:856–858. [PubMed: 22542484]
21. Diffley M, Armenian P, Gerona R, Reinhartz O, Avasarala K (2012) Catecholaminergic polymorphic ventricular tachycardia found in an adolescent after a methylenedioxymethamphetamine and marijuana-induced cardiac arrest. *Crit Care Med* 40: 2223–2226. [PubMed: 22584762]
22. Menahem S (2013) Cardiac asystole following cannabis (marijuana) usage—Additional mechanism for sudden death? *Forensic Sci Int* 233: e3–e5. [PubMed: 24200372]
23. Khouzam RN, Kabra R, Soufi MK (2013) Marijuana, bigeminal premature ventricular contractions and sluggish coronary flow: Are they related? *J Cardiol Cases*. 8:121–124. [PubMed: 30546761]
24. Hartung B, Kauferstein S, Ritz-Timme S, Daldrup T (2014) Sudden unexpected death under acute influence of cannabis. *Forensic Sci Int* 237: e11–e13. [PubMed: 24598271]
25. Singh D, Huntwork M, Shetty V, Sequeira G, Akingbola O (2014) Prolonged atrial fibrillation precipitated by new-onset seizures and marijuana abuse. *Pediatrics* 133: e443–e446. [PubMed: 24420812]
26. Brancheau D, Blanco J, Gholkar G, Patel B, Machado C (2016) Cannabis induced asystole. *J Electrocardiology* 49: 15–17.
27. Alonso JV, Teo BH, del Pozo FJ, Aguayo MA, Sanchez A (2016) Brugada electrocardiogram pattern induced by cannabis; is cannabis safe? *Am J Emerg Med* 34: 1738.e1–1738.e4.
28. Orsini J, Blaak C, Rajayer S, Gurung V, Tam E, et al. (2016) Prolonged cardiac arrest complicating a massive ST-segment elevation myocardial infarction associated with marijuana consumption. *J Community Hosp Intern Med Perspect* 6: 31695. [PubMed: 27609717]
29. Yalçın M, Aparcı M, Ero lu M, İlak Z, Özmen N (2017) Giant J (Osborn) Wave due to Bonsai Abuse: Comments on Clinical Practice. *Balkan Med J* 34: 81–84. [PubMed: 28251030]
30. Doctorian T, Chou E (2017) Cannabis-Induced Brugada Syndrome Presenting as Cardiac Arrest. *J Cardiol & Cardiovasc Ther* 6: 555678.
31. Kariyanna PT, Jayarangaiah A, Hegde S, Marmur JD, Wengrofsky P, et al. (2018) Marijuana Induced Type I Brugada Pattern: A Case Report. *Am J Med Case Rep* 6: 134. [PubMed: 30294671]
32. Mechoulam R, Gaoni Y (1967) The absolute configuration of delta-1-tetrahydrocannabinol, the major active constituent of hashish. *Tetrahedron letters*. 8:1109–1111.
33. Jiang LS, Pu J, Han ZH, Hu LH, He B (2008) Role of activated endocannabinoid system in regulation of cellular cholesterol metabolism in macrophages. *Cardiovasc Res* 81: 805–813. [PubMed: 19074161]
34. Beaconsfield P, Ginsburg J, Rainsbury R (1972) Marihuana smoking: cardiovascular effects in man and possible mechanisms. *N Engl J Med* 287: 209–212. [PubMed: 4402574]
35. Gash A, Karliner JS, Janowsky D, Lake CR (1978) Effects of smoking marihuana on left ventricular performance and plasma norepinephrine: studies in normal men. *Ann Intern Med* 89: 448–452. [PubMed: 697222]

36. Niederhoffer N, Schmid K, Szabo B (2003) The peripheral sympathetic nervous system is the major target of cannabinoids in eliciting cardiovascular depression. *Naunyn-Schmiedeberg's Arch Pharmacol* 367: 434–443. [PubMed: 12709782]
37. Ben-David J, Zipes DP (82) Alpha-adrenoceptor stimulation and blockade modulates cesium-induced early afterdepolarizations and ventricular tachyarrhythmias in dogs. *Circulation* 82: 225–233. [PubMed: 1973083]
38. Warner MR, Levy MN (1990) Role of neuropeptide Y in neuronal control of heart. *J Cardiovasc Electrophysiol* 1: 80–91.
39. Zipes Douglas P (1991) Sympathetic stimulation and arrhythmias. *N Engl J Med* 325: 656–657. [PubMed: 1861701]
40. Fisher BA, Ghuran A, Vadamalai V, Antonios TF (2005) Cardiovascular complications induced by cannabis smoking: a case report and review of the literature. *Emerg Med J* 22: 679–680. [PubMed: 16113206]
41. Ghuran AV, Camm AJ (2001) Ischaemic heart disease presenting as arrhythmias. *Br Med J* 59: 193–210.
42. Kattoor A, Mehta JL (2016) Marijuana and Coronary Artery disease. *JACC*.
43. Wu TC, Tashkin DP, Djahed B, Rose JE (1988) Pulmonary hazards of smoking marijuana as compared with tobacco. *N Engl J Med* 318: 347–351. [PubMed: 3340105]
44. Karabulut A, Cakmak M (2010) ST segment elevation myocardial infarction due to slow coronary flow occurring after cannabis consumption. *Kardiologia Polska* 68: 1266–1268. [PubMed: 21108208]
45. Rezkalla SH, Sharma P, Kloner RA (2003) Coronary no-flow and ventricular tachycardia associated with habitual marijuana use. *Ann Emerg Med* 42: 365–369. [PubMed: 12944889]
46. Herath J, Rajapakse S, Amarasena N, Gunawardena MD (2014) Myocardial infarction following cannabis induced coronary vasospasm. *BMJ Case Rep*. 12: 2014.
47. Franz CA, Frishman WH (2016) Marijuana Use and Cardiovascular Disease. *Cardiol Rev* 24: 158–162. [PubMed: 26886465]
48. Zipes DP (1990) Influence of myocardial ischemia and infarction on autonomic innervation of heart. *Circulation* 82:1095–1105. [PubMed: 2205413]
49. Carmeliet E (1999) Cardiac ionic currents and acute ischemia: from channels to arrhythmias. *Physiol Rev* 79: 917–1017. [PubMed: 10390520]
50. Beaconsfield P, Ginsburg J, Rainsbury R (1972) Marijuana smoking: cardiovascular effects in man and possible mechanisms. *N Engl J Med* 287: 209–212.
51. Miller RH, Dhingra RC, Kanakis C Jr, Amat-y-Leon F, Rosen KM (1977) The electrophysiological effects of delta-9-tetrahydrocannabinol (cannabis) on cardiac conduction in man. *Am Heart J* 94: 740–747. [PubMed: 920582]
52. Okura D, Horishita T, Ueno S, Yanagihara N, Sudo Y, et al. (2014) The endocannabinoid anandamide inhibits voltage-gated sodium channels Nav1. 2, Nav1. 6, Nav1. 7, and Nav1. 8 in *Xenopus* oocytes. *Anesth Analg* 118: 554–562. [PubMed: 24557103]
53. Bialer M, Johannessen SI, Levy RH, Perucca E, Tomson T, et al. (2015) Progress report on new antiepileptic drugs: a summary of the Twelfth Eilat Conference (EILAT XII). *Epilepsy Res* 111: 85–141. [PubMed: 25769377]
54. Bialer M, Johannessen SI, Levy RH, Perucca E, Tomson T, et al. (2015) Progress report on new antiepileptic drugs: a summary of the Twelfth Eilat Conference (EILAT XII). *Epilepsy Res* 111: 85–141. [PubMed: 25769377]
55. Nerbonne JM, Kass RS (2005) Molecular physiology of cardiac repolarization. *Physiol Rev* 85: 1205–1253. [PubMed: 16183911]
56. Mizumaki K, Fujiki A, Tsuneda T, Sakabe M, Nishida K, et al. (2004) Vagal activity modulates spontaneous augmentation of ST elevation in the daily life of patients with Brugada syndrome. *J Cardiovasc Electrophysiol* 15: 667–673. [PubMed: 15175062]



**Figure 1:**  
Summary of method.



**Figure 2:**  
Summary of mechanisms of marijuana induced arrhythmia.

Author Manuscript

Author Manuscript

Author Manuscript

Author Manuscript



**Table 1:** Table summarizing cases or arrhythmias associated with marijuana use, EKG and Echo findings and management employed.

Case	Year and author	Reported arrhythmia in EKG	Trans thoracic echocardiogram	Coronary angiography	Chemical / electrical Cardioversion/ Defibrillation	Medical management	Device implantation
1	1981, Akins (8)	Sinus bradycardia, first degree atrioventricular block, second degree atrioventricular block	-	-	-	-	-
2	2000, Kosior (9)	Atrial fibrillation	-	-	Propafenone	-	-
3	2000, Singh (10)	Atrial fibrillation	Normal	-	Digitalization	-	-
4	2001, Kosior (11)	Supraventricular tachycardia, atrial fibrillation	Normal	-	-	Beta-blockers	-
5	2001, Kosior (11)	Atrial fibrillation	Normal	-	-	-	-
6	2003, Rezkella (12)	Ventricular tachycardia	-	Normal coronaries, slow flow (TIMI I-II)	Propafenone	-	-
7	2005, Fischer (13)	Atrial flutter converted to Atrial fibrillation after adenosine was given	-	-	-	-	-
8	2005, Charbonney (14)	Atrial fibrillation	-	-	Flecainide	-	-
9	2007, Dacarett (15)	Brugada pattern	Normal	-	Procainamide	-	-
10	2008, Baranchuk (16)	Ventricular fibrillation	-	-	Defibrillation	Amiodarone	-
11	2009, Sanchez-Lazaro (17)	Ventricular tachycardia	Normal ejection fraction Moderate pericardial effusion	40% lesion in the mid-LAD and 100% lesion in the distal LAD	-	-	-
12	2009, Sattout (18)	Asystole, Ventricular tachycardia	-	-	Defibrillation	-	-
13	2011, Fernandez-Fernandez (19)	Asystole, ventricular fibrillation	-	-	-	-	-
14	2012, Ramero-Punche (20)	Brugada pattern, frequent ventricular premature complexes	-	-	-	-	-
15	2012, Diffley (21)	Ventricular tachycardia	Normal	Normal coronaries	Cardioversion	-	Implantable cardioverter defibrillator
16	2013, Menahem (22)	Incomplete right bundle branch block pattern, asystole, ectopic atrial tachycardia	Normal	-	-	-	-

Case	Year and author	Reported arrhythmia in EKG	Trans thoracic echocardiogram	Coronary angiography	Chemical / electrical Cardioversion/ Defibrillation	Medical management	Device implantation
17	2013, Kouzam (23)	Nonsustained ventricular tachycardia	Normal ejection fraction Abnormal left ventricular filling pattern Trace mitral regurgitation	Slow coronary flow in LAD (TIMI II) and RCA (TIMI II-III)	-	Metoprolol	-
18	2014, Hartung (24)	Ventricular fibrillation	-	-	Defibrillation	-	-
19	2014, Hartung (24)	Sudden cardiac death	-	-	-	-	-
20	2014, Singh (25)	Atrial fibrillation	Normal except for The size of the right ventricle was reported to be 1.5 cm, and the estimated right ventricle systolic pressure was 32 mm Hg	-	Cardioversion	-	-
21	2016, Brancheau(26)	Asystole /sinus arrest	Normal	-	-	-	Permanent pacemaker implantation
22	2016, Valle-Alonzo (27)	Brugada pattern	Normal	-	Flecainide	-	-
23	2016, Orsini (28)	Ventricular fibrillation	Left ventricular ejection fraction 20%, global hypokinesia, septal akinesia	-	Defibrillation	-	-
24	2017, Yalsin (29)	J waves (type III pattern)	-	-	-	-	-
25	2017, Yalsin (29)	J waves (type II pattern)	-	-	-	-	-
26	2017, Doctorian (30)	Ventricular fibrillation, Brugada pattern	Normal	Normal coronaries	-	Quinidine	Implantable cardioverter defibrillator
27	2018, Theetha Kariyanna (31)	Brugada pattern	Normal	-	-	-	-

**Table 2:**

Arrhythmias reported with marijuana use.

Supraventricular arrhythmia	Ventricular arrhythmias	Others
Atrial fibrillation 7 (26%)	Ventricular fibrillation 6 (22%)	Brugada pattern 5 (19%)
Atrial flutter 1 (3.7%)	Ventricular tachycardia 3 (11%)	Asystole 4 (14.8%)
Sinus bradycardia 1 (3.7%)	Non-sustained ventricular tachycardia 1 (3.7%)	J-waves 2 (7.4%)
Sinus arrest 1 (3.7%)	Ventricular premature complex 1 (3.7%)	Incomplete right bundle branch block pattern 1 (3.7%)
Ectopic atrial tachycardia 1 (3.7%)		Sudden cardiac death 1 (3.7%)
Supraventricular tachycardia 1 (3.7%)		
I degree AV block 1 (3.7%)		
II degree AV block 1 (3.7%)		