

# Post-inflammatory hyperpigmentation after carbon dioxide laser: review of prevention and risk factors

Alhanouf Bin Dakhil,<sup>1</sup> Asem Shadid,<sup>2</sup> Saad Altalhab<sup>1</sup>

<sup>1</sup>Department of Dermatology, College of Medicine, Imam Mohammad Ibn Saud Islamic University, Riyadh;

<sup>2</sup>Department of Dermatology, King Fahad Medical City, Riyadh, Saudi Arabia

## Abstract

The CO<sub>2</sub> laser has been widely utilized in dermatology; its expanding clinical applications include the management of neoplastic lesions, benign growths, cosmetic conditions, and reactive disorders. The laser's popularity is mainly due to the high precision and short recovery time this technology provides. However, post-inflammatory hyperpigmentation (PIH) has been one of the challenging adverse effects of the CO<sub>2</sub> laser. Therefore, several modalities have been studied for the prevention of PIH following CO<sub>2</sub> laser treatment. This review aims to analyze the incidence of PIH after CO<sub>2</sub> laser therapy, identify its risk factors, and assess the efficacy of the examined treatment modalities in preventing PIH. Pubmed and Embase databases were searched for this study, and relative

clinical trials were included in the review. Descriptive findings – including age, gender, skin type, types of intervention, and incidence of PIH – were reported. When appropriate, the incidence of PIH was compared across each possible individual factor, such as skin type, gender, and type of intervention. A total of 211 articles were identified, and 14 relevant articles were included in this review. Seventy percent of the subjects were females (n=219), and 30% were males (n=94), with a mean age of 30 years (SD=7.8). The most common skin types were type IV (59%) followed by type III (25%). In total, eight studies investigated the prevention of PIH. The incidence of PIH after CO<sub>2</sub> laser significantly varies between studies and differs based on the type of intervention. The studies indicate that the use of Clobetasol propionate 0.05% and fusidic acid cream appeared to effectively reduce PIH, recording an incidence rate of 39% and 53.3%, respectively. The Fitzpatrick-skin-phenotype did not appear to influence the risk of PIH. There is a lack of high-powered clinical studies analyzing the incidence of PIH after CO<sub>2</sub> laser treatment and the associated risk factors. PIH occurrence may be related to inflammation resulting from thermal damage by the CO<sub>2</sub> laser. Consequently, the use of postoperative topical medications with anti-inflammatory properties might reduce its incidence. The use of ultra-potent topical corticosteroids and topical fusidic acid appeared to reduce PIH, possibly reducing postoperative inflammation effectively. Similarly, platelet-containing plasma may be beneficial in reducing CO<sub>2</sub> side effects, including PIH. However, more studies are needed to further establish the influence of skin type on PIH and investigate modalities to reduce PIH occurrence after CO<sub>2</sub> laser use.

Correspondence: Alhanouf Bin Dakhil, Department of Dermatology, College of Medicine, Imam Mohammad Ibn Saud Islamic University, Riyadh, Saudi Arabia.  
Tel.: +966543226826.  
E-mail: alhanoufadk@gmail.com

Key words: CO<sub>2</sub> laser, postinflammatory hyperpigmentation, clobetasol propionate, fusidic acid, review.

Contributions: ABD, conceptualization, design, writing, editing, and literature review; AS, SA, edited and supervised the manuscript.

Conflict of interest: the authors declare no conflict of interest.

Funding: none.

Availability of data and materials: data and materials are available by the authors.

Received: 3 March 2023.  
Accepted: 26 April 2023.  
Early view: 19 May 2023.

This work is licensed under a Creative Commons Attribution-NonCommercial 4.0 International License (CC BY-NC 4.0).

©Copyright: the Author(s), 2023  
Licensee PAGEPress, Italy  
Dermatology Reports 2023; 15:9703  
doi:10.4081/dr.2023.9703

*Publisher's note: all claims expressed in this article are solely those of the authors and do not necessarily represent those of their affiliated organizations, or those of the publisher, the editors and the reviewers. Any product that may be evaluated in this article or claim that may be made by its manufacturer is not guaranteed or endorsed by the publisher.*

## Introduction

With recent advancements in the field of dermatology, lasers have become an important and indispensable treatment modality with common application.<sup>1</sup> One of the first lasers developed was the carbon dioxide (CO<sub>2</sub>) laser, which was created in 1964. Initially, the use of this particular type of laser was delineated to surgical procedures because of its high absorption by water.<sup>2</sup> However, over the years, the CO<sub>2</sub> laser's usage has significantly expanded to include the treatment of both benign and malignant conditions, as well as cosmetic treatments and aesthetic imperfections.<sup>1,2</sup> This is primarily due to the high precision that the CO<sub>2</sub> laser provides, in addition to the reduced presence of side effects like inflammation and slow healing.<sup>1</sup>

CO<sub>2</sub> lasers are divided into two types: fractionated and unfractionated. Fractionated lasers are further separated into two subtypes: ablative and nonablative. Fractionated lasers, both ablative and nonablative, are considered safer than their nonfractionated counterparts due to their smaller columns' microthermal zones. Nevertheless, both types can potentially lead to adverse effects, such as erythema and edema. Postinflammatory hyperpigmenta-

tion (PIH) is another side effect that is seen with the use of several different lasers, including CO<sub>2</sub>.<sup>1</sup> This condition occurs due to hypermelanosis, which results from dermal inflammation. It is known to be the most common side effect of lasers in individuals with darker skin.<sup>3</sup> Therefore, its occurrence in some geographic areas, such as the Middle East, is thought to be more common and severe.<sup>3</sup> Although most cases resolve spontaneously, the duration of PIH varies depending on the patient, and the therapeutic options to accelerate its healing are very limited.<sup>1</sup> Similarly, little is known about preventing PIH after laser treatment, especially CO<sub>2</sub>. To our knowledge, this is the first review to investigate the occurrence of PIH after CO<sub>2</sub> laser therapy, as well as the efficacy of the available modalities in preventing this adverse effect.

## Materials and Methods

A literature search on the PubMed and Embase databases was conducted from the first available date until 30/9/2021. Pre-identified search terms included “carbon dioxide”, “laser”, “resurfaces” “fractional”, “ablation”, “pigmentation”, “hyperpigmentation”, and “postinflammatory”. Inclusion criteria is comprised of prospective studies investigating carbon dioxide (CO<sub>2</sub>) lasers and addressing PIH. Case reports, case series, letters, comments, reviews, and non-English articles – or those that did not discuss carbon dioxide (CO<sub>2</sub>) laser or address PIH – were excluded.

Study characteristics were extracted, including authors' names, year of publication, and study design; participants' age, gender, and skin type; types of interventions to reduce CO<sub>2</sub> side effects; and study outcomes. First, descriptive findings, including age, gender, skin type, types of intervention, and incidence of PIH were reported. When appropriate, the incidence of PIH was compared across possible influencing factors, such as skin type and method of intervention used to reduce PIH.

## Results

Our search revealed a total of 211 records (Appendix 1). After removing duplicates, title and abstract screening were performed and led to the exclusion of 118 records. Full-text screening of the remaining 24 studies was thus completed. Ten records were further excluded for the following reasons: one study did not address PIH;<sup>4</sup> another study did not involve CO<sub>2</sub> laser;<sup>5</sup> others were a case report,<sup>6</sup> and a review article;<sup>7</sup> and six studies were retrospective analyses (Figure 1).<sup>8-13</sup> After these exclusions, fourteen studies met the inclusion criteria. The characteristics of the included studies are shown in (Table 1). The studies included 313 participants, with a ratio of 70% females (n=219) and 30% (n=94) males. The age was recorded in 273 subjects, with a reported mean age of 30 years (SD=8.1). Fitzpatrick skin phototypes were reported individually in 259 participants. The most common skin type was type IV (n=164, 59%) followed by type III (n=70, 25%) (Table 2). The overall incidence of PIH after CO<sub>2</sub> laser treatment significantly varies between the studies, ranging from 0% to 100%. The incidence of PIH differs based on whether a medical intervention was used to decrease side effects of CO<sub>2</sub>; it is also dependent upon the type of the intervention. Eight studies including 258 participants examined the efficacy of medical interventions in the prevention of PIH.<sup>3,11,14-19</sup> These include the topical use of Fusidic acid compared to topical erythromycin (n=60);<sup>14</sup> clobetasol propionate 0.05% compared to petroleum jelly (n=40);<sup>3</sup> an experimental moisturizer containing 5% panthenol, madecassoside, and copper-

zinc-manganese (PMCZ) compared to triamcinolone acetonide 0.02% (n=20);<sup>16</sup> MAS063DP (Atopiclair) cream compared to triamcinolone acetonide 0.02% (n=16);<sup>19</sup> platelet-poor plasma gel compared to saline (n=36),<sup>11</sup> platelet-rich plasma (PRP) (n=30);<sup>17</sup> epidermal growth factor compared to petroleum jelly (n=19);<sup>15</sup> and multi-growth factor (MGF)-containing cream compared to placebo (n=20).<sup>18</sup> Six studies did not use any adjunctive or postoperative interventions.<sup>20-25</sup>

Topical corticosteroids were used by three studies.<sup>3,16,19</sup> This involved an ultra-potent corticosteroid (clobetasol propionate 0.05%), and a mid-strength treatment (triamcinolone acetonide 0.02%), either as an experimental intervention or as a control. When topical clobetasol propionate 0.05% was used, the incidence of PIH was 39%.<sup>3</sup> However, the PIH incidence was with triamcinolone acetonide 0.02% was 55% and 43.7%.<sup>16,19</sup> Topical antimicrobials, fusidic acid cream erythromycin ointment, were examined by one study.<sup>14</sup> The incidence of PIH with fusidic acid cream was 53.3%, while it was 91.1% with the use of erythromycin ointment. What's more, PIH incidence was 52.6% with topical epidermal growth factor, and 60% with the use of PMCZ.<sup>26</sup> With MAS063DP, the incidence of PIH was recorded in 50% of the participants.<sup>19</sup> Two studies examined concurrent injection of platelet-containing plasma.<sup>11,17</sup> With PRP, the incidence of PIH was only 16%, while it was 36% with platelet-poor plasma injection. The incidence of PIH based on gender and Fitzpatrick skin phototypes (FSP) were reported in 101 subjects. Ultimately, the difference in PIH incidence based on skin type was not significant in any study.

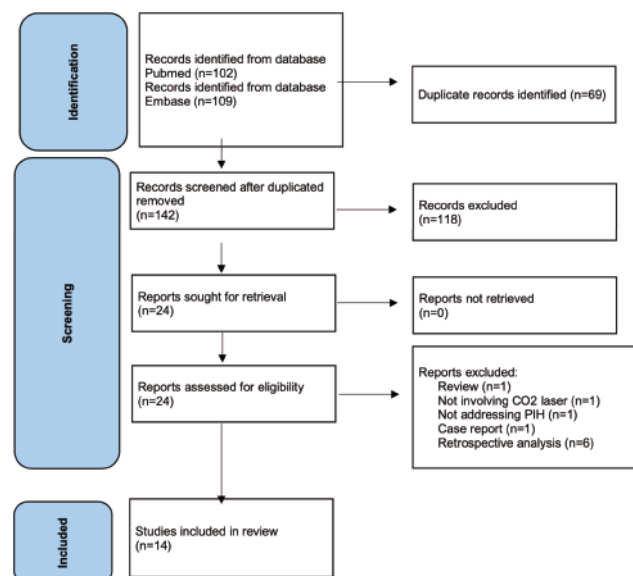


Figure 1. Diagram of the included studies.

Table 2. Fitzpatrick skin phototypes.

Type	N (%)
Not reported	18 (6.5)
Type I	3 (1.1)
Type II	6 (2.2)
Type III	70 (25.3)
Type IV	164 (59.2)
Type V	16 (5.8)

Table 1. Characteristics of the included studies.

Study	Study design	Type of control	Year	Subjects	Skin type	Laser indication	Intervention to reduce side effects	Comparison	PIH incidence
Alster <i>et al.</i> <sup>20</sup>	Randomized clinical trial	Self-control; quadrant face	1999	7	I-II	Rhytids and scars	None	NA	100%
Tan <i>et al.</i> <sup>22</sup>	Randomized clinical trial	Self-control; both sides of the face	2008	7	IV and V	Photodamaged skin	None	NA	0%
Al Mohizea <sup>21</sup>	Randomized clinical trial	Self-control; right inner arm	2013	7	III-V	Right inner arms test areas	None	NA	57%
Cheyasak <i>et al.</i> <sup>3</sup>	Randomized clinical trial	Self-control; both sides of the face	2015	40	IV	Atrophic acne scars	Clobetasol propionate 0.05% ointment	Petrolatum jelly	39% with intervention. 75% with comparison.
Shin <i>et al.</i> <sup>18</sup>	Randomized clinical trial	Self-control; split face	2016	20	III-IV	Split-face study to assess the effects of a multigrowth factor-containing cream	Multigrowth factor-containing cream	Control cream (growth factors were excluded)	NR, but PIH index scores obtained from the study group and the control was not different between the two groups.
Techapichetvanich <i>et al.</i> <sup>15</sup>	Randomized clinical trial	Self-control; split face	2018	19	III-V	Wound healing	Topical epidermal growth factor	Petrolatum jelly	52.6% with intervention. 57.9% with comparison.
Lueangarun <i>et al.</i> <sup>19</sup>	Randomized clinical trial	Self-control; split face	2018	16	III-IV	Atrophic acne scars	MAS063DP	Triamcinolone acetamide 0.02% cream	50% with intervention. 43.7 % with comparison.
Lueangarun <i>et al.</i> <sup>16</sup>	Randomized clinical trial	Self-control; split face	2019	20	III-V	Atrophic acne scars	PM CZ cream	Triamcinolone acetamide 0.02% cream	60% with intervention. 55% with comparison.
Suh <i>et al.</i> <sup>24</sup>	Pilot study	Self-control; warts affected area	2020	17	Not reported	Periungual warts	Topical bleomycin	None	5.8%
Al-Murtesh <i>et al.</i> <sup>25</sup>	Randomized clinical trial	Self-control; right and left abdomen	2020	14	III-IV	Striae distensae	No	No	42.8%
Wei <i>et al.</i> <sup>14</sup>	Randomized clinical trial	Experimental group vs control group; both sides of the face	2021	60	III-V	Atrophic acne scars	Fusidic acid cream	Erythromycin ointment	53.3% with intervention 93.1% with comparison
Neinaa <i>et al.</i> <sup>17</sup>	Randomized clinical trial	Self-control; right and left abdomen	2021	30	II-IV	Striae distensae	PRP	None	16.6%
Gad <i>et al.</i> <sup>11</sup>	Randomized clinical trial	Self-control	2021	36	III-IV	Striae distensae	Platelet-poor plasma gel	Saline	36% with intervention. 61% with comparison.

PIH, postinflammatory hyper pigmentation; PM CZ, 5% panthenol, madecassoside, and copper-zinc-manganese; PRP, platelet-rich plasma; NR, not reported; NA, not applicable.



## Discussion

The development of PIH after CO<sub>2</sub> laser treatment has been postulated as a melanocyte response to inflammation, resulting from the thermal damage caused by irradiation.<sup>3</sup> During the inflammatory phase, prostanoids, cytokines, chemokines, and other inflammatory mediators lead to the overproduction of melanin by melanocytes. This melanin is then transferred to the surrounding keratinocytes, thus leading to irregular dispersion of pigment.<sup>3,27</sup> Nonetheless, the fundamental processes in the development and variability of PIH in individuals are not fully understood – particularly the risk factors for the occurrence and severity of PIH. Some theorists propose that PIH incidence is somewhat related to the functionality and ability of an individual's melanocytes to respond to inflammation with hyperpigmentation. In this assessment, they refer to the patient's melanocytes as “weak” or “strong”.<sup>3,28</sup> In this review, the incidence of PIH after CO<sub>2</sub> laser therapy significantly varies in the included studies, between 0% to 100% occurrence.

It has been proposed that PIH is mostly observed in people with darker skin, hastily linking this occurrence to Fitzpatrick skin phototypes.<sup>1</sup> However, it must be noted that none of the included studies found a significant difference in PIH incidence among the participants based on FSP. The incidence was reported to be 0% in the Tan *et al.* study, in which all participants (n=7) had either FSP IV or V.<sup>22</sup> In fact, the authors suggested that FSP IV and V carry a lower risk of the development of PIH after CO<sub>2</sub> laser treatment. On the other hand, all of the participants (n=40) in Cheyasak *et al.*'s study had FSP IV, and the PIH incidence was as high as 75%.<sup>3</sup> The highest reported incidence of PIH (100%) was reported by Alster *et al.*; in this case, all the participants (n=7) had either FSP I or II.<sup>20</sup> Conducted by Wei *et al.*, the study with the largest sample (n=60) reported FSP types ranging from III to IV, with a total incidence of PIH being up to 90%.<sup>14</sup> Lastly, Lueangarun *et al.* reported that in their study, the incidence of PIH in FSP III and IV was identical (50%).<sup>19</sup> These findings indicate that FSP might not be an independent risk factor for the development of PIH following CO<sub>2</sub> laser therapy. However, it should be noted that the inconsistency of these findings has three possible roots: the variation sample size, different PIH evaluation modalities, and the lack of individual PIH reporting based on FSP by all studies. Further studies are necessary to determine the relationship between skin phototype and PIH. The treatment of PIH is broadly challenging and requires patience and compliance. Some treatments – such as topical hydroquinone, tretinoin, glycolic acid, and vitamin C – have been used to remedy this skin reaction. But when PIH occurs, it may last for several months regardless of the use of treatment.<sup>3,29,30</sup>

Therefore, the use of perioperative and postoperative therapies to prevent PIH in dermatologic procedures is viewed as a possible way to overcome this common complication. However, the evidence is still developing. Eight of the included studies examined the efficacy of off-label or investigational use of several treatments in the prevention of PIH after CO<sub>2</sub> laser use.<sup>3,11,14-19,22,24</sup> Among these treatments are topical corticosteroids, antimicrobials, topical growth-factors, and experimental therapies.

### Topical corticosteroids

TC reduce inflammation by inhibiting phospholipase A2 and delaying the release of arachidonic acid from the cell membrane. Because of PIH's inflammatory nature, the use of TC after CO<sub>2</sub> lasers has been proposed as a potential preventative modality to decrease the risk of PIH. Takiwaki *et al.* have previously demonstrated that topical clobetasol propionate and hydrocortisone butyrate decrease the incidence of UVB-induced hyperpigmenta-

tion.<sup>31</sup> Topical corticosteroids (TC) after CO<sub>2</sub> laser therapy was described in two of the included studies.<sup>3,16</sup> Cheyasak *et al.* compared clobetasol propionate 0.05% ointment to petroleum jelly. In this comparison, they found that the use of clobetasol propionate 0.05% significantly decreased PIH incidence to 39%, compared to 75% with petroleum jelly (p<0.001). This finding supports the theory that controlling inflammation at earlier phases may reduce potential consequences like PIH. On the other hand, Lueangarun *et al.*<sup>16</sup> investigated the effect of PMCZ cream on the incidence of CO<sub>2</sub> laser-related side effects. As a comparative tool, they also used triamcinolone acetonide 0.02% cream. The study reported that PIH was recorded in 55% of triamcinolone acetonide 0.02% group participants, compared to 60% with PNCZ cream. In another study by Lueangarun *et al.*,<sup>19</sup> PIH with the use of triamcinolone acetonide 0.02% was recorded at 43.7%. Upon studying these results, it is possible that PIH incidence with triamcinolone acetonide (55% and 47.3%),<sup>16,19</sup> compared to clobetasol propionate (39%)<sup>3</sup> could be related to the corticosteroids potency. Clobetasol propionate 0.05% is an ultra-potent TC; meanwhile, triamcinolone acetonide 0.02% is regarded as a mid-strength TC.<sup>32</sup> Thus, it might be reasonable to postulate that the incidence of PIH with clobetasol propionate 0.05% was lower because of its more potent effect in reducing inflammation. Lueangarun *et al.*<sup>16</sup> reported that PMCZ cream was not superior to triamcinolone acetonide 0.02% in reducing CO<sub>2</sub> laser postoperative downtime; however, both regimens reduced redness and swelling. Nevertheless, PMCZ is still a novel experimental moisturizer, and its anti-inflammatory properties have not yet been adequately studied.

### Topical non-steroidal anti-inflammatory drugs

MAS063DP lotion is a non-steroidal anti-inflammatory moisturizer typically used to treat different forms of dermatitis. Lueangarun *et al.*<sup>19</sup> used MAS063DP lotion (Atopiclair® brand lotion) after CO<sub>2</sub> ablation, in an effort to assess its ability to prevent PIH. The study found that MAS063DP was not superior to triamcinolone acetonide 0.02% in reducing the incidence of PIH after CO<sub>2</sub> ablation (50% vs. 47.3, respectively). The results of this study may endorse the theory that the preventative agent's anti-inflammatory potency is an important factor in controlling PIH. This is supported by the fact that clobetasol propionate 0.05% appeared to successfully reduce PIH, in contrast to triamcinolone acetonide 0.02% and MAS063DP.

### Antimicrobials

The use of topical antimicrobials after laser therapy treatment has been described in the past; however, its effect on PIH development has not been completely established.<sup>33</sup> This rule was examined by Wei *et al.*,<sup>14</sup> and included the use of fusidic acid cream or erythromycin ointment. The authors reported a statistically significant difference in the incidence and severity of PIH with the use of fusidic acid cream compared to erythromycin ointment (p<0.05).<sup>14</sup> Fusidic acid cream (53.3%) appeared to effectively reduce PIH after CO<sub>2</sub> laser therapy more than erythromycin ointment (93.1%). Fusidic acid is the only approved topical antibiotic from the fusidane family.<sup>26</sup> The product has some anti-inflammatory properties, such as inhibiting proinflammatory cytokines of TNF- $\alpha$ , IL-1 $\beta$ , and COX-2.<sup>26</sup> The findings by Wei *et al.*<sup>14</sup> might be due to the fact that fusidic acid reduces postoperative inflammation, and therefore decreased PIH. Nevertheless, more studies are needed to determine the influence of fusidic acid on PIH.

### Platelet-containing plasma

Platelet-containing plasma either PRP or platelet-poor plasma –

has been used in conjunction with CO<sub>2</sub> laser therapy. Two studies have demonstrated this treatment's efficacy in reducing CO<sub>2</sub> laser side effects. Gad *et al.*<sup>11</sup> reported that PIH after CO<sub>2</sub> laser therapy significantly decreased with the use of platelet-poor plasma ( $p=0.021$ ). Furthermore, the incidence of PIH after CO<sub>2</sub> laser treatment was only 16.6% with the use of PRP. The decrease of PIH with platelet-containing plasma could be attributed to its stimulation effect, which impacts the extracellular signal-regulated kinase and the suppressive effect of TGF- $\beta$ 1 on melanin synthesis.<sup>11,34</sup> This is in addition to the basement membrane repair effect by platelet degranulation, and the release of laminin, collagen IV, and tenascin.<sup>11,34</sup>

### Epidermal growth factor

Epidermal growth factor (EGF) plays a crucial role in the wound healing process; yet its external use in the clinical setting has not been well established. Nevertheless, some studies examined the effect of topical EGF on prompting wound healing in acute tissue injuries – such as radiation-induced mucositis – and received positive results.<sup>35</sup> Techapichetvanich *et al.*<sup>15</sup> evaluated the effect of topical EGF on PIH prevention after CO<sub>2</sub> laser therapy. However, the study did not find a statistically significant difference in PIH occurrence with the topical application of EGF. The authors proposed that the positive effect of EGF application on re-epithelialization might be more observed in cases of chronic wounds, rather than post-laser wounds.<sup>15</sup> These findings are in agreement with those reported by Shin *et al.*<sup>18</sup> who did not find significant differences in the incidence of PIH with the multi-growth factor-containing cream compared to the placebo cream.

### Bleomycin solution

In their study, Suh *et al.*<sup>24</sup> used bleomycin solution after CO<sub>2</sub> laser therapy while treating periungual warts. The objective was to evaluate the efficacy and safety of bleomycin solution for treating periungual warts; however, the authors noted that PIH occurred only in one patient with this treatment (5.8%). No other studies examined the effect of bleomycin solution in reducing PIH or inflammation after CO<sub>2</sub> laser therapy. Bleomycin is an antitumor agent with antibacterial and antiviral properties. It has been widely used as primary or adjunctive therapy for various cutaneous conditions.<sup>36</sup> This agent's effect on inflammation have yet to be established, and one of its common side effects is inflammation at the application site. Currently, there is not sufficient evidence to support the use of bleomycin solution to reduce PIH after CO<sub>2</sub> laser therapy.

### Hormonal changes

The effect of hormonal changes on the occurrence of PIH is an under-studied idea. Although most PIH occurs in women, it is likely related to the fact that females undergo laser therapy more often than men. Almohizea investigated the effect of the menstrual cycle on CO<sub>2</sub> laser-induced PIH.<sup>21</sup> The author found that PIH was more severe when CO<sub>2</sub> laser therapy was performed during the patient's menstrual cycle. Despite the limited sample size ( $n=7$ ), the study's findings are highly interesting. Pigmentary conditions, such as melasma, correspond with hormonal changes – those associated with pregnancy and the use of contraceptive medications. It is unclear if PIH severity in Almohizea's study was related to the inflammatory response being affected by menstrual cycle, or if the melanocytes reaction is "strong", as described by Ruiz-Maldonado, during this phase.<sup>28</sup> Puder *et al.*<sup>37</sup> reported that menstrual cycles are associated with changes in plasma inflammatory markers, suggesting that menstruation is linked to low-grade inflammation. The relation between inflammatory response after CO<sub>2</sub> laser therapy and the menstrual cycle begs further elaboration.

### Limitations

Data was reported in a cumulative pattern by many studies, rather than for each participant individually. As a result, evaluating each possible risk factor of PIH using multivariable regression analysis was not viable. Therefore, it was not possible to determine if each factor – such as skin type and type of intervention – were independent of the other factors, such as gender and age. Additionally, the incidence of PIH might also depend on other medical and technical factors, such as the dermatological condition being treated, energy and density of the laser therapy, and sun exposure before and after treatment. This may have led to the variable incidence of PIH reported in the literature. Robust clinical trials with extensive, detailed documentation are needed to properly assess the risk of PIH after CO<sub>2</sub> laser therapy and determine the efficacy of preventative modalities.

### Conclusions

CO<sub>2</sub> laser therapy is widely used in the field of dermatology due to its high precision and short postoperative downtime. However, PIH remains a challenging adverse effect that is frequently observed with this technology. The notion behind PIH occurrence is related to inflammation resulting from thermal damage by the CO<sub>2</sub> laser. Over time, each agent used to decrease the incidence of PIH has received variable results. From this data, the use of ultra-potent TC appeared to reduce PIH, possibly by reducing postoperative inflammation. Antimicrobial therapies with anti-inflammatory properties, such as topical fusidic acid, may also be beneficial in preventing PIH. Similarly, platelet-containing plasma appeared to reduce CO<sub>2</sub> side effects, including PIH, when used in conjunction with CO<sub>2</sub> laser treatment. The patient's FSP did not appear to play a major role in the occurrence of PIH, as per the reporting studies. Further research is required to establish a clearer relation between skin type and PIH, and to examine preventative modalities to reduce PIH after CO<sub>2</sub> laser treatment appropriately.

### References

1. Conforti C, Vezzoni R, Giuffrida R, et al. An overview on the role of CO<sub>2</sub> laser in general dermatology. *Dermatol Ther* 2021;34:e14692.
2. Kaplan I. The CO<sub>2</sub> surgical laser. *Photomed Laser Surg* 2010;28:847-8.
3. Cheyasak N, Manuskiatti W, Maneeprasopchoke P, Wanitphakdeedecha R. Topical corticosteroids minimise the risk of postinflammatory hyper-pigmentation after ablative fractional CO<sub>2</sub> laser resurfacing in Asians. *Acta Derm Venereol* 2015;95:201-5.
4. Kim J, Kim B, Kim S, et al. The effect of human umbilical cord blood-derived mesenchymal stem cell media containing serum on recovery after laser treatment: a double-blinded, randomized, split-face controlled study. *J Cosmet Dermatol* 2020;19:651-6.
5. Moon HR, Yun WJ, Lee YJ, et al. A prospective, randomized, double-blind comparison of an ablative fractional 2940-nm erbium-doped yttrium aluminum garnet laser with a nonablative fractional 1550-nm erbium-doped glass laser for the treatment of photoaged Asian skin. *J Dermatolog Treat* 2015;26:551-7.
6. Rokhsar CK, Ciocon DH. Fractional photothermolysis for the treatment of postinflammatory hyperpigmentation after carbon dioxide laser resurfacing. *Dermatol Surg* 2009;35:535-7.

7. Wat H, Wu DC, Chan HH. Fractional resurfacing in the Asian patient: current state of the art. *Lasers Surg Med* 2017;49:45-59.
8. Kim JS, Ginter A, Ranjit-Reeves R, Woodward JA. Patient satisfaction and management of postoperative complications following ablative carbon dioxide laser resurfacing of the lower eyelids. *Ophthalmic Plast Reconstr Surg* 2021;37:450-6.
9. Sarnoff D, Gotkin H, Doerfler B, et al. The safety of laser skin resurfacing with the microablative carbon dioxide laser and review of the literature. *J Drugs Dermatol* 2018;17:1157-62.
10. Bernstein LJ, Kauvar AN, Grossman MC, Geronemus RG. The short- and long-term side effects of carbon dioxide laser resurfacing. *Dermatol Surg* 1997;23:519-25.
11. Gad SE, Neinaa YME, Rizk OK, Ghaly NER. Efficacy of platelet-poor plasma gel in combination with fractional CO(2) laser in striae distensae: a clinical, histological, and immunohistochemical study. *J Cosmet Dermatol* 2021;20:3236-44.
12. Goh C. Management of post-acne scars in Asians-need for a paradigm shift? In: *Australasian Journal of Dermatology*. Wiley: Hoboken NJ USA; 2017. pp 57-57.
13. Jimenez JC, Montes JR, Maldonado J. Aesthetic benefits of CO2 laser photorejuvenation treatment for malar mounds (festoons). *Invest Ophthalmol Visual Sci* 2015;56:4735.
14. Wei M, Li L, Zhang XF, et al. Fusidic acid cream comparatively minimizes signs of inflammation and postinflammatory hyperpigmentation after ablative fractional CO2 laser resurfacing in Chinese patients: a randomized controlled trial. *J Cosmet Dermatol* 2021;20:1692-9.
15. Techapichetvanich T, Wanitphakdeedecha R, Iamphonrat T, et al. The effects of recombinant human epidermal growth factor containing ointment on wound healing and post inflammatory hyperpigmentation prevention after fractional ablative skin resurfacing: a split-face randomized controlled study. *J Cosmet Dermatol* 2018;17:756-61.
16. Lueangarun S, Srituravanit A, Tempark T. Efficacy and safety of moisturizer containing 5% panthenol, madecassoside, and copper-zinc-manganese versus 0.02% triamcinolone acetonide cream in decreasing adverse reaction and downtime after ablative fractional carbon dioxide laser resurfacing: A split-face, double-blinded, randomized, controlled trial. *J Cosmet Dermatol* 2019;18:1751-7.
17. Neinaa YME, Gheida SF, Mohamed DAE. Synergistic effect of platelet-rich plasma in combination with fractional carbon dioxide laser versus its combination with pulsed dye laser in striae distensae: a comparative study. *Photodermatol Photoimmunol Photomed* 2021;37:214-23.
18. Shin S, Shin JU, Lee Y, et al. The effects of a multigrowth factor-containing cream on recovery after laser treatment: a double-blinded, randomized, split-face controlled study. *J Cosmet Dermatol* 2017;16:76-83.
19. Lueangarun S, Tempark T. Efficacy of MAS063DP lotion vs 0.02% triamcinolone acetonide lotion in improving post-ablative fractional CO2 laser resurfacing wound healing: a split-face, triple-blinded, randomized, controlled trial. *Int J Dermatol* 2018;57:480-7.
20. Alster TS, Nanni CA, Williams CM. Comparison of four carbon dioxide resurfacing lasers. A clinical and histopathologic evaluation. *Dermatol Surg* 1999;25:153-9.
21. Al Mohizea S. The effect of menstrual cycle on laser induced hyperpigmentation. *J Drugs Dermatol* 2013;12:1335-6.
22. Tan KL, Kurniawati C, Gold MH. Low risk of postinflammatory hyperpigmentation in skin types 4 and 5 after treatment with fractional CO2 laser device. *J Drugs Dermatol* 2008;7:774-7.
23. Elmorsy EH, Elgarem YF, Sallam ES, Taha AAA. Fractional carbon dioxide laser versus carboxytherapy in treatment of striae distensae. *Lasers Surg Med* 2021;53:1173-9.
24. Suh JH, Lee SK, et al. Efficacy of bleomycin application on peringual warts after treatment with ablative carbon dioxide fractional laser: a pilot study. *J Dermatolog Treat* 2020;31:410-4.
25. Al-Muriesh M, Huang CZ, Ye Z, Yang J. Dermoscopy and VISIA imager evaluations of non-insulated microneedle radiofrequency versus fractional CO2 laser treatments of striae distensae. *J Eur Acad Dermatol Venereol* 2020;34:1859-66.
26. Wu PP, He H, Hong WD, et al. The biological evaluation of fusidic acid and its hydrogenation derivative as antimicrobial and anti-inflammatory agents. *Infect Drug Resist* 2018;11:1945-57.
27. Grimes PE. Management of hyperpigmentation in darker racial ethnic groups. *Semin Cutan Med Surg* 2009;28:77-85.
28. Ruiz-Maldonado R, Orozco-Covarubias ML. Postinflammatory hypopigmentation and hyperpigmentation. *Semin Cutan Med Surg* 1997;16:36-43.
29. Sriprachya-anunt S, Marchell NL, Fitzpatrick RE, et al. Facial resurfacing in patients with Fitzpatrick skin type IV. *Lasers Surg Med* 2002;30:86-92.
30. West TB, Alster TS. Effect of pretreatment on the incidence of hyperpigmentation following cutaneous CO2 laser resurfacing. *Dermatol Surg* 1999;25:15-17.
31. Takiwaki H, Shirai S, Kohno H, et al. The degrees of UVB-induced erythema and pigmentation correlate linearly and are reduced in a parallel manner by topical anti-inflammatory agents. *J Invest Dermatol* 1994;103:642-6.
32. Singh PK, Singh G. Relative potency of topical corticosteroid preparations. *Indian J Dermatol Venereol Leprol* 1985;51:309-12.
33. Uaboonkul T, Nakakes A, Ayuthaya PK. A randomized control study of the prevention of hyperpigmentation post Q-switched Nd:YAG laser treatment of Hori nevus using topical fucidic acid plus betamethasone valerate cream versus fucidic acid cream. *J Cosmet Laser Ther* 2012;14:145-9.
34. Doghaim NN, El-Tatawy RA, Neinaa YMEH. Assessment of the efficacy and safety of platelet poor plasma gel as autologous dermal filler for facial rejuvenation. *J Cosmet Dermatol* 2019;18:1271-9.
35. Demidova-Rice TN, Hamblin MR, Herman IM. Acute and impaired wound healing: pathophysiology and current methods for drug delivery, part 2: role of growth factors in normal and pathological wound healing: therapeutic potential and methods of delivery. *Adv Skin Wound Care* 2012;25:349.
36. Saitta P, Krishnamurthy K, Brown LH. Bleomycin in dermatology: a review of intralesional applications. *Dermatol Surg* 2008;34:1299-313.
37. Puder JJ, Blum CA, Mueller B, et al. Menstrual cycle symptoms are associated with changes in low-grade inflammation. *Eur J Clin Invest* 2006;36:58-64.

### Online Appendix

Search strategy for PubMed. Search strategy for Embase.