



Received: 2015.05.31  
Accepted: 2015.06.24  
Published: 2015.09.17

**Authors' Contribution:**

- A** Study Design
- B** Data Collection
- C** Statistical Analysis
- D** Data Interpretation
- E** Manuscript Preparation
- F** Literature Search
- G** Funds Collection

## Uterin Lipoleiomyoma: MR Findings

Abdussamet Batur<sup>AB</sup>, Muhammed Alpaslan<sup>B</sup>, Ilyas Dundar<sup>B</sup>, Mesut Ozgokce<sup>B</sup>, Alpaslan Yavuz<sup>A</sup>

Department of Radiology, Yuzuncuyil University Dursun Odabas Medical Center, Van Sehri, Turkey

**Author's address:** Abdussamet Batur, Department of Radiology, Yuzuncuyil University Dursun Odabas Medical Center, Van Sehri, Turkey, e-mail: drsamet56@yahoo.com

**Background:**

Uterine lipoleiomyoma is a rare and specific type of leiomyoma.

**Case Report:**

A 60-year-old postmenopausal woman presented with abdominal pain. Her pelvic ultrasound demonstrated a normal-sized uterus with a well-circumscribed, heterogeneous mass located in the anterior corpus. A pelvic MRI revealed a mass including hyperintense areas on T1-weighted images and hypointense on fat-suppressed T1-weighted images, compatible with lipoleiomyoma.

**Conclusions:**

Uterine lipoleiomyomas are often misdiagnosed pre-operatively and it is important to distinguish leiomyomas from other tumors for prevention from supererogatory surgery. Imaging plays an important role for the exact differentiation.

**MeSH Keywords:**

**Leiomyoma • Magnetic Resonance Imaging • Menopause**

**PDF file:**

<http://www.polradiol.com/abstract/index/idArt/894848>

### Background

Lipoleiomyoma is a rare variant of uterine leiomyoma, composed of an admixture of mature smooth muscle cells and adipocytes, and occurring primarily in obese postmenopausal patients [1,2]. Although most patients are asymptomatic, they can present with symptoms similar to leiomyomas of the same size and location [3]. It is important to differentiate these tumors from other fat-containing gynecologic malignancies, which require surgical excision. In the present study, we report the MR imaging features of a case with uterine lipoleiomyoma.

### Case Report

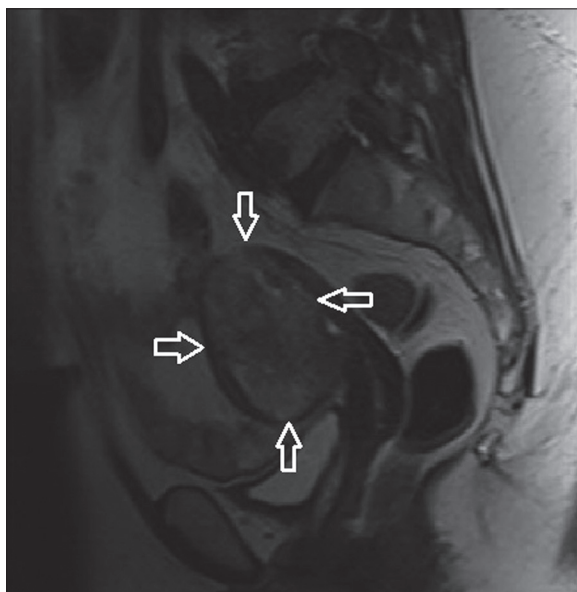
A 60-year-old postmenopausal woman presented with a two-month history of pelvic pain due to inflammation of the vagina. Gynecological examination revealed no other abnormality. The serological and hematological parameters showed no abnormality. Her pelvic ultrasound demonstrated a normal-sized uterus with a well-circumscribed, heterogeneous mass located in the anterior corpus. A pelvic MRI revealed a well-defined T2 heterogeneous hyperintense mass (Figure 1) that included hyperintense areas on T1-weighted images (Figure 2A). The hyperintense area was hypointense on fat-suppressed T1-weighted

images (Figure 2B). It showed heterogeneous enhancement with hypointense areas on contrast-enhanced fat-suppressed T1-weighted images (Figure 3). Both ovaries and tubes were normal. The lesion was evaluated as lipoleiomyoma based on imaging findings, and it was histopathologically confirmed.

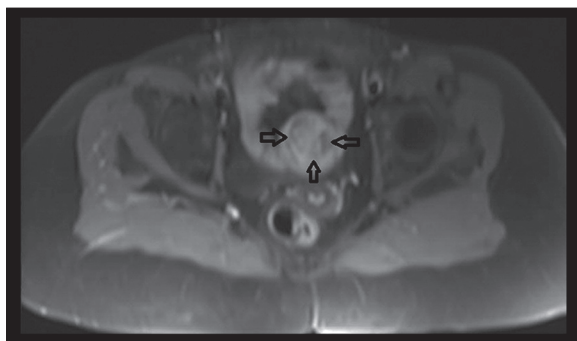### Discussion

Uterine lipoleiomyoma is a rare, benign tumor with an incidence of 0.03% to 0.2% [4]. These tumors show characteristic histological findings, being composed of benign smooth muscle and mature adipose tissue. Several pathological mechanisms may underlie the presence of adipocytes within leiomyomas. Two main theories of them are adipose metaplasia of smooth muscle cells and a multipotential Mullerian cell origin [5].

Although most leiomyomas tend to predominate in women of reproductive age, they are frequently seen in older women. A number of various lipid metabolic disorders or other associated conditions possibly promote abnormal intracellular storage of lipids [6]. Lipoleiomyomas most commonly grow in the uterine corpus at intramural levels, whereas they have been reported at other sites [5].

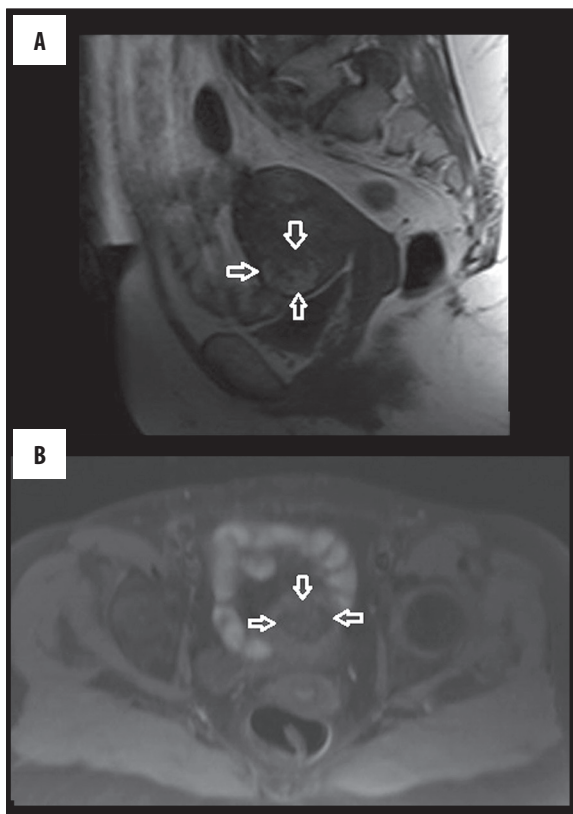


**Figure 1.** Sagittal T2-W MR image shows a well-defined heterogeneous hyperintense mass (arrows).



**Figure 3.** Axial contrast-enhanced T1-W fat-suppressed MR image shows heterogeneous enhancement with hypointense areas (arrows).

The imaging characteristics of lipoleiomyoma afford the radiologist an opportunity to make a specific diagnosis. On sonography, it is a well-defined heterogeneous mass containing hyperechoic areas due to the presence of fat. Similarly, on CT images it shows areas of fat attenuation. Such as in our case, MR imaging reveals a heterogeneous mass with hyperintensity on T1-weighted images, and low



**Figure 2.** (A) Sagittal T1-W MR image shows an isointense mass including hyperintense areas (arrows), and (B) Axial T1-W fat-suppressed MR image shows hypointensity of the same area (arrows).

signal intensity on fat-saturated images. Therefore, in combination with sonography, CT and MRI may assist in the preoperative diagnosis of lipoleiomyoma.

## Conclusions

In conclusion, uterine lipoleiomyomas are often diagnosed pre-operatively as leiomyomas or mature ovarian teratomas [7]. It is essential to distinguish leiomyomas from tumors for prevention from supererogatory surgery, because lipoleiomyomas require no treatment. Imaging plays an important role in preoperatively demonstrating the fatty nature and exact location.

## References:

1. Lin KC, Sheu BC, Huang SC: Lipoleiomyoma of the uterus. *Int J Gynaecol Obstet*, 1999; 67: 47-49
2. Rollason TP, Wilkinson N: Non neoplastic conditions of myometrium and pure mesenchymal tumors of the uterus. In: Fox H, Wells M (eds.), Haines and Taylor Obstetrical and Gynaecological Pathology. 5th ed. Edinburgh: Churchill Livingstone, 2003; 531
3. Ghosh B, Mckeown B, Gumma A: Lipoleiomyoma. *BMJ Case Rep*, 2011; 2011: pii: bcr0820114577
4. Avritscher R, Iyer BB, Ro J et al: Lipoleiomyoma of the uterus. *Am J Roentgenol*, 2001; 177: 856
5. Akbulut M, Gündoğan M, Yörükoğlu A: Clinical and pathological features of lipoleiomyoma of the uterine corpus: a review of 76 cases. *Balkan Med J*, 2014; 31: 224-29
6. Manjunatha HK, Ramaswamy AS, Kumar BS et al: Lipoleiomyoma of the uterus in postmenopausal woman. *J Midlife Health*, 2010; 1(2): 86-88
7. Wahal SP, Mardi K: Lipoleiomyoma of the uterus and lipoma of broad ligament: a rare entity. *J Cancer Res Ther*, 2014; 10(2): 434-36